Iran J Pathol. 2027;22(1):121–127 | ISSN 2345-3656 | MAIN SUBJECTS Diagnostic Pathology

Immunohistochemical Assessment of Mismatch Repair Proteins in Colorectal Adenocarcinoma: Clinicopathological Correlations in a Cohort from Kerman, Iran

Maryam Iranpour[1], Ali Hadipour[1], Fatemeh Khara[2], Shahriar Dabiri[1]*, Maryam Samareh Salavatipour[1]*

1. Pathology and Stem Cell Research Center, Kerman University of Medical Sciences, Kerman, Iran
2. Department of Applied Cell Sciences, School of Advanced Technologies in Medicine, Tehran University of Medical Sciences, Tehran, Iran

RECEIVED 08 Jun 2026 ACCEPTED 03 Nov 2026 PUBLISHED ONLINE 06 Nov 2026 DOI 10.22034/ijp.2026.2088223.3671

ABSTRACT

Background: Colorectal adenocarcinoma (CRC) is a heterogeneous cancer that may arise through defects in the DNA mismatch repair (MMR) system. Immunohistochemical (IHC) testing of MMR proteins is a common screening tool for the detection of tumors with MMR deficiency (dMMR). The current study investigated the expression of MLH1, MSH2, MSH6, and PMS2 and their association with clinicopathological parameters in a selected single-center cohort of CRC cases from Kerman, Iran.

Methods: This retrospective single-center study included 51 selected archival cases of histologically confirmed colorectal adenocarcinoma diagnosed at Afzalipour Hospital, Kerman, Iran, between January 2014 and December 2018. Formalin-fixed paraffin-embedded (FFPE) tumor tissues were stained for MLH1, MSH2, MSH6, and PMS2. IHC-defined MMR-proficient status was defined as intact nuclear expression of all four proteins, whereas IHC-defined dMMR/MSI-suggestive phenotype was defined as complete loss of at least one MMR protein in tumor cells with retained staining in internal positive controls.

Results: The age of patients ranged from 29 to 82 years. IHC-defined pMMR was observed in 30 cases (58.8%), while IHC-defined dMMR/MSI-suggestive phenotype was observed in 21 of 51 cases, corresponding to 41.2% (95% CI: 27.6%–55.8%). Among the five tumors with single-protein loss, all showed isolated PMS2 loss. MMR expression patterns showed associations with age, histological type, tumor grade, and tumor location.

Conclusion: IHC testing for MLH1, MSH2, MSH6, and PMS2 may serve as a feasible screening approach for identifying CRC cases with IHC-defined dMMR/MSI-suggestive phenotype. However, molecular confirmation by PCR or NGS is required to determine MSI status.

KEYWORDS Colorectal adenocarcinoma, Immunohistochemistry, Mismatch repair, Microsatellite instability

Corresponding Information: Shahriar Dabiri, Pathology and Stem Cell Research Center, Kerman University of Medical Sciences, Kerman, Iran, dabiri12@yahoo.com
Maryam Samareh Salavatipour, Pathology and Stem Cell Research Center, Kerman University of Medical Sciences, Kerman, Iran, m.samareh@kmu.ac.ir

Copyright © 2027 The Author(s). This is an open-access article distributed under the terms of the CC BY 4.0, which permits unrestricted use, distribution, and reproduction in any medium, provided the original work is properly cited.

1. INTRODUCTION

Colorectal adenocarcinoma (CRC) is one of the most frequent malignancies worldwide and is a major cause of morbidity and mortality related to cancer. This tumor is driven by several molecular pathways and shows marked heterogeneity in tumor morphology, biological behavior, prognosis, and therapeutic response (1, 2, 3). Among these pathways, mutations in the DNA mismatch repair (MMR) genes represent an important mechanism in CRC pathogenesis (4, 5).

Colorectal carcinogenesis is a heterogeneous molecular process that may develop through several major pathways. These include the chromosomal instability pathway, which is characterized by widespread copy-number alterations and mutations in genes such as APC, KRAS, and TP53; the microsatellite instability (MSI) pathway, which is mainly related to defective DNA mismatch repair; and the CpG island methylator phenotype, which is associated with widespread promoter hypermethylation and may lead to transcriptional silencing of tumor suppressor genes (6, 7). Among these pathways, MMR deficiency and MSI have particular diagnostic and clinical relevance because they can be assessed by immunohistochemistry (IHC) and may guide further molecular or genetic evaluation (8).

The MMR system preserves genomic stability through the detection and correction of DNA base-base mismatches and insertion-deletion loops formed during DNA replication. The major MMR proteins assessed in routine pathology practice are MLH1, MSH2, MSH6, and PMS2. These proteins form heterodimeric complexes: MLH1 primarily associates with PMS2, and MSH2 primarily associates with MSH6. Loss or dysfunction of these proteins leads to accumulation of replication errors, in particular in microsatellite regions, resulting in a microsatellite instability-associated tumor phenotype (9, 10, 11, 12).

The evaluation of MMR status has major diagnostic, prognostic, and therapeutic implications in CRC. MMR-deficient tumors often present with distinct clinicopathological characteristics, including younger age at diagnosis, proximal

tumor location, mucinous or poorly differentiated histology, and prominent tumor-infiltrating lymphocytes. Identification of dMMR is also helpful in identifying patients who can benefit from immune checkpoint inhibitor therapy and for identifying patients who may need further evaluation for Lynch syndrome (13, 14).

There are several different approaches to evaluate dMMR and MSI, including polymerase chain reaction (PCR), next-generation sequencing (NGS), and IHC of MMR proteins (15, 16). Among these approaches, IHC has been widely used in routine pathology practice because of its practicality, cost-effectiveness, and ability to identify the specific MMR protein that is absent (17, 18). Hence, the evaluation of MLH1, MSH2, MSH6, and PMS2 expression in formalin-fixed paraffin-embedded (FFPE) tissue sections is considered a useful screening approach for the detection of dMMR and for the identification of patients who might benefit from additional molecular or genetic analysis, especially for Lynch syndrome (19, 20).

The reported frequency of dMMR and MSI in colorectal cancer varies across studies and populations (21, 22). MSI-H/dMMR colorectal cancers have unique molecular and clinicopathological features; therefore, data from different geographic regions may provide useful descriptive information for local pathological practice (23). In Iran, published data on immunohistochemical MMR protein expression patterns and their association with clinicopathological features in CRC remain limited, particularly in southeastern regions such as Kerman. However, findings from retrospective single-center cohorts should be interpreted as cohort-specific observations rather than population-level prevalence estimates. Therefore, this study aimed to assess the IHC expression of MLH1, MSH2, MSH6, and PMS2 in a selected retrospective cohort of CRC cases diagnosed at Afzalipour Hospital, Kerman, Iran, between January 2014 and December 2018. The study also examined the association between MMR protein expression status and clinicopathological parameters, including age, sex, tumor site, histological type, and tumor grade.

2. MATERIALS AND METHODS

2.1 Study Design and Case Selection

This retrospective single-center study was conducted on selected archival FFPE tissue specimens from patients with histologically confirmed CRC who underwent surgical resection at Afzalipour Hospital, Kerman, Iran, between January 2014 and December 2018. This period was selected to obtain an adequate number of eligible cases with available archival FFPE blocks, sufficient tumor tissue, complete clinicopathological records, and representative H&E sections suitable for MMR immunohistochemistry. In total, 51 cases were included based on the availability of sufficient tumor tissue, complete clinicopathological data, and representative hematoxylin and eosin-stained sections.

Patients with insufficient tumor tissue, unavailable tissue blocks, incomplete clinicopathological records or who received neoadjuvant chemotherapy or radiotherapy before surgery were excluded. Clinicopathological factors including age, sex, tumor location, histological type, and tumor grade were extracted from pathology reports and reviewed records. Two experienced pathologists re-evaluated the tumor type, grade and other histological findings. Histological classification was done by standard pathological criteria which included adenocarcinoma, not otherwise specified and mucinous adenocarcinoma.

This study was approved by the Ethics Committee of Kerman University of Medical Sciences (Ethical code: IR.KMU.AH.REC.1397.124). All procedures were in accordance with the ethical standards of the Declaration of Helsinki. This was a retrospective study on archived anonymized tissue samples, and the ethics committee did not require written informed consent. Patient confidentiality was maintained during the study.

2.2 Immunohistochemical Staining

Four mismatch repair proteins (MLH1, MSH2, MSH6, and PMS2) were evaluated using IHC on tumor blocks. FFPE tissue blocks were cut into 4-µm-thick sections and mounted on appropriate glass slides. All IHC staining procedures were performed manually using the EnVision™ detection system (Dako, Denmark) according to the manufacturer's instructions.

Tissue sections were deparaffinized with xylene and rehydrated through graded alcohols. Slides were placed in citrate buffer (pH 6.0) and heated in a microwave oven for 20 minutes for antigen retrieval. Endogenous peroxidase was blocked using 3% hydrogen peroxide. The sections were then cooled down to room temperature and washed with distilled water and tris-buffered saline (TBS). The slides were incubated overnight at 4°C with primary monoclonal antibodies against MLH1 (BD Biosciences Pharmingen, clone G168-15, dilution 1:100), MSH2 (Calbiochem, Oncogene Science, clone FE11, dilution 1:100), MSH6 (BD Transduction Laboratories, clone 44, dilution 1:1000), and PMS2 (BD Pharmingen, clone A16-4, dilution 1:500). Slides were washed with TBS following each incubation. Detection was carried out with the EnVision™ detection system (Dako, Denmark) and visualized with 3,3′-diaminobenzidine as the chromogen. Finally, the sections were counterstained with Mayer's hematoxylin, dehydrated, cleared and mounted.

For each case, adequate positive internal controls were required for interpretation. These included non-neoplastic colonic mucosa, stromal cells, lymphocytes, and lymphoid follicles present on the same slide. Because this was a retrospective study using archival tissue, detailed documentation of external control procedures was limited; therefore, interpretation relied on the presence of adequate internal positive controls on the same slide.

2.3 Evaluation of Immunohistochemical Staining

The IHC staining was independently assessed by two experienced pathologists blinded to the clinicopathological outcomes. Nuclear staining was evaluated only in viable tumor cells, and cytoplasmic staining alone was disregarded. Positive internal controls, including non-neoplastic colonic mucosa, stromal cells, infiltrating lymphocytes, and lymphoid follicles, were required for interpretation. Cases without adequate internal positive control staining were considered technically inadequate for interpretation.

Any convincing nuclear staining in viable tumor cells was interpreted as retained expression of the corresponding MMR protein, even if the staining was weak, focal, patchy, or heterogeneous. Complete absence of nuclear staining in tumor cells, in the presence of retained nuclear staining in internal positive control cells, was interpreted as loss of expression. Equivocal, patchy, or technically suboptimal staining patterns

doi:10.22034/ijp.2026.2088223.3671

were jointly reviewed by both pathologists, and the final interpretation was reached by consensus.

Cases with retained nuclear expression of all four MMR proteins were classified as IHC-defined pMMR. Cases showing unequivocal complete loss of nuclear expression of at least one MMR protein in tumor cells, with retained nuclear staining in internal positive controls, were classified as IHC-defined dMMR/MSI-suggestive phenotype. No PCR-based MSI testing or next-generation sequencing was performed; therefore, MSI status was not molecularly confirmed. The interpretation criteria were applied in accordance with guideline-based principles for MMR IHC reporting.

2.4 Statistical Analysis

The data were statistically analyzed using SPSS version 25.0. Descriptive statistics were used to summarize clinicopathological variables and IHC results. Associations between MMR protein expression patterns and clinicopathological variables were determined by Chi-square test or Fisher's exact test, as appropriate. In case of small expected cell counts or zero values, Fisher's exact test was used. The level of statistical significance was set at $P < 0.05$. The 95% confidence interval for the observed proportion of IHC-defined dMMR/MSI-suggestive phenotype was calculated using the exact binomial method.

3. RESULTS

3.1 Clinical Features

The age of the patients ranged from 29 to 82 years and the mean age was 55.41 ± 11.32 years. Fifteen patients (29.4%) were 50 years of age or less and 36 patients (70.6%) were more than 50 years. The group of 51 patients included 32 males (62.7%) and 19 females (37.3%).

3.2 Histopathological Features

Tumors showed variable anatomical distribution. The right colon was involved in 17 (33.3%) cases and the left colon in 34 (66.7%) cases. In terms of histological type, 36 (70.6%) tumors were classified as adenocarcinoma, not otherwise specified, and 15 (29.4%) tumors were classified as mucinous adenocarcinoma. Thirty-four cases (66.7%) were low-grade tumors, and 17 cases (33.3%) were high-grade tumors.

3.3 Immunohistochemical Features

IHC evaluation of MMR protein expression showed that 30 cases (58.8%) had retained nuclear expression of all four markers and were classified as IHC-defined pMMR. Loss of nuclear expression of at least one MMR protein was observed in 21 of 51 tumors, corresponding to an observed frequency of IHC-defined dMMR/MSI-suggestive phenotype of 41.2% (95% CI: 27.6%–55.8%). All dMMR cases showed retained nuclear staining in internal positive control cells and were confirmed after pathological re-review. Of the dMMR tumors, 5 cases (9.8% of all tumors) had single MMR protein loss and were classified as dMMR-single protein loss. All five tumors with single-protein loss showed isolated PMS2 loss, defined as loss of PMS2 nuclear expression with retained expression of MLH1, MSH2, and MSH6. Additionally, 16 cases (31.37% of all tumors) had combined loss of two or more MMR proteins and were classified as dMMR-combined protein loss. Figures 1 and 2 show representative patterns of positive and negative staining, respectively. The summary of the relationship between MMR expression pattern and clinicopathological variables is shown in Table 1.

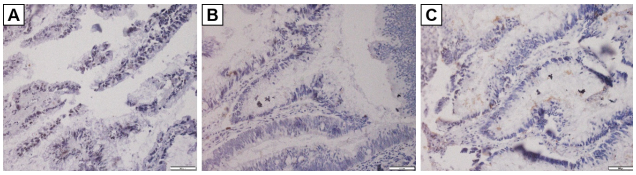

Fig 2. Representative loss of IHC expression of mismatch repair proteins in cases of mucinous adenocarcinoma. (A) Loss of nuclear expression of MLH1. (B) Loss of nuclear expression of MSH2. (C) Loss of nuclear expression of MSH6. The panels are derived from different representative tumors. Loss of expression was interpreted only when there was retained nuclear staining in internal control cells, including adjacent non-neoplastic epithelial cells, stromal cells, or inflammatory cells. Original magnification: ×400.

A statistically significant association was observed between age and MMR expression pattern ($P = 0.012$). Combined MMR protein loss was more common in patients aged 50 years or younger, while retained expression and single-protein loss were more common in older patients.

There was no significant association between the MMR expression pattern and sex ($P = 0.521$). In male patients, we found 20 pMMR, 2 dMMR-single loss, 10 dMMR-combined loss, and in female patients, 10, 3, and 6 cases, respectively.

MMR expression pattern was significantly associated with histological type ($P = 0.002$). Combined loss of MMR proteins was more common in mucinous adenocarcinoma than in adenocarcinoma NOS.

Tumor grade was also significantly associated with the MMR expression pattern ($P = 0.007$). The combined loss of MMR proteins was more often seen in high-grade tumors, whereas low-grade tumors more often showed retained expression of all four MMR proteins.

MMR expression pattern showed a significant association with tumor site ($P = 0.001$). Retained MMR expression was more frequent in left-sided tumors, and combined MMR protein loss was more frequent in right-sided tumors.

4. DISCUSSION

CRC is a heterogeneous malignancy that develops through different molecular pathways and has variable clinicopathological behavior (24). Among these pathways, the impairment of the DNA mismatch repair system is of particular clinical relevance due to its association with distinct pathological features, hereditary cancer syndromes, prognosis and response to immunotherapy (25, 26). In this selected retrospective single-center cohort, we evaluated the IHC expression of four major MMR proteins, including MLH1, MSH2, MSH6, and PMS2, in 51 CRC cases from Afzalipour Hospital, Kerman, Iran, and investigated the association between MMR protein expression patterns and clinicopathological parameters.

In our cohort, 30 cases (58.8%) retained nuclear expression of all four MMR proteins and were classified as pMMR. IHC detected loss of expression of at least one MMR protein in 21 of 51 cases, corresponding to an observed frequency of IHC-defined dMMR/MSI-suggestive phenotype of 41.2% (95% CI: 27.6%–55.8%). Among dMMR tumors, 5 cases showed loss of a single MMR protein and 16 cases showed combined loss of two or more

doi:10.22034/ijp.2026.2088223.3671

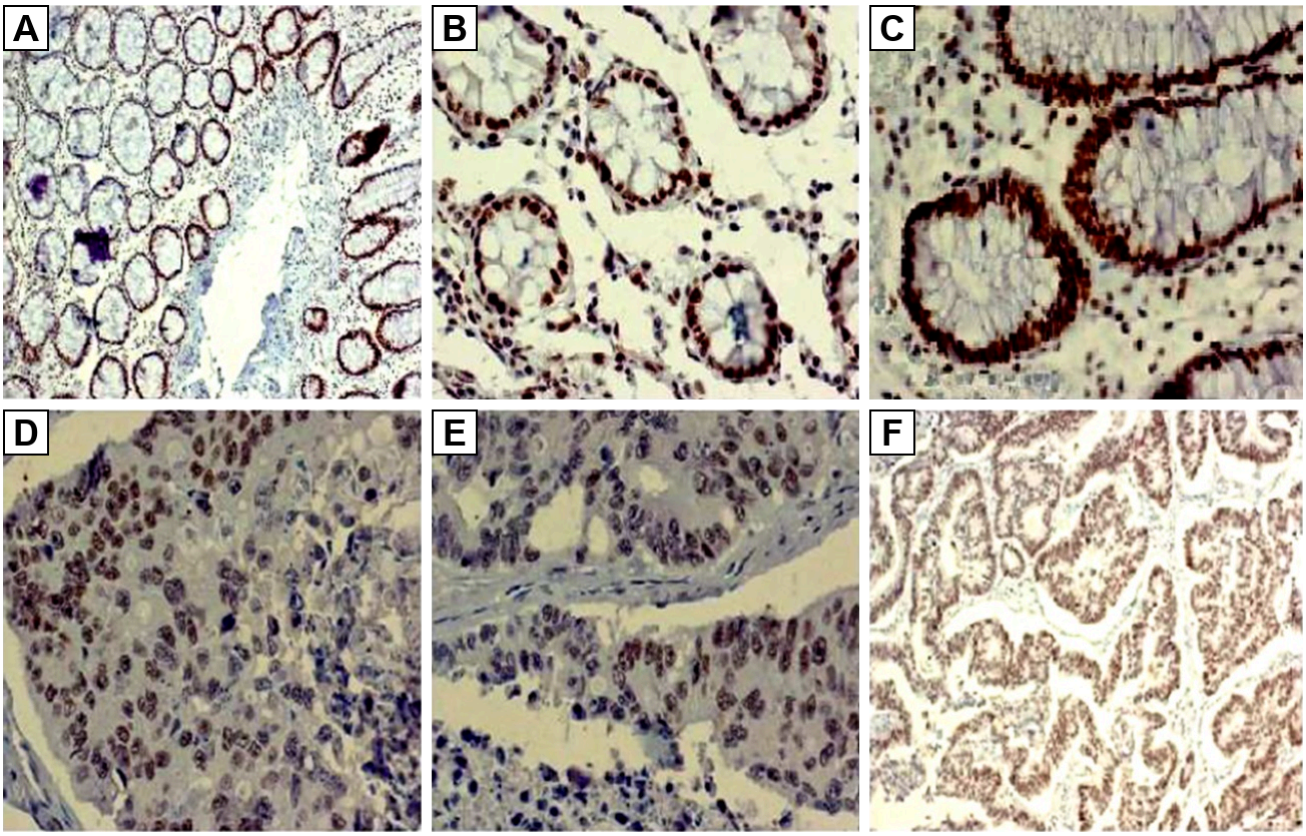

Fig 1. Representative positive immunohistochemical staining for mismatch repair proteins. (A) MLH1 nuclear expression in normal colonic tissue, original magnification: ×100; (B) MSH2 nuclear expression in normal colonic tissue, original magnification: ×400; (C) MSH6 nuclear expression in normal colonic tissue, original magnification: ×400; (D) PMS2 nuclear expression in colorectal adenocarcinoma, original magnification: ×400; (E) MLH1 nuclear expression in colorectal adenocarcinoma, original magnification: ×400; (F) MSH2 nuclear expression in colorectal adenocarcinoma, original magnification: ×100.

Table 1. Association between clinicopathological characteristics and immunohistochemical patterns of MMR protein expression in colorectal adenocarcinoma

Variable		pMMR n (%)	Isolated PMS2 loss n (%)	Combined protein loss n (%)	Total n (%)	P-value
Age	≤50 years	6 (40)	0 (0.0)	9 (60)	15 (100.0)	0.012
	>50 years	24 (66.7)	5 (13.9)	7 (19.4)	36 (100.0)	
Sex	Male	20 (62.5)	2 (6.3)	10 (31.3)	32 (100.0)	0.521
	Female	10 (52.6)	3 (15.8)	6 (31.6)	19 (100.0)	
Histological Type	Adenocarcinoma NOS	26 (72.2)	4 (11.1)	6 (16.7)	36 (100.0)	0.002
	Mucinous Adenocarcinoma	4 (26.7)	1 (6.7)	10 (66.7)	15 (100.0)	
Tumor Grade	Low grade	25 (73.5)	3 (8.8)	6 (17.6)	34 (100.0)	0.007
	High grade	5 (29.4)	2 (11.8)	10 (58.8)	17 (100.0)	
Tumor Site	Right-sided colon	6 (35.3)	0 (0.0)	11 (64.7)	17 (100.0)	0.001
	Left-sided colon	24 (70.6)	5 (14.7)	5 (14.7)	34 (100.0)	

Data are presented as number and row percentage. pMMR: retained nuclear expression of all four MMR proteins; isolated PMS2 loss: loss of PMS2 expression with retained expression of MLH1, MSH2, and MSH6; combined-protein loss: loss of two or more MMR proteins. P values were calculated using the Chi-square test or Fisher's exact test, as appropriate.

MMR proteins. While IHC is not a direct molecular test for MSI, it is commonly used in routine pathology practice as a practical and informative screening modality to identify tumors with dMMR and to select cases for further molecular or genetic evaluation (25).

The relatively high observed frequency of dMMR in this selected single-center cohort should be interpreted cautiously, as large population-based studies have generally reported frequencies of approximately 10-15% in colorectal cancer (22). Previous Iranian studies have reported variable frequencies of abnormal MMR protein expression in colorectal cancer. In a study from Tehran, Molaei et al. evaluated 343 Iranian CRC patients using IHC for MLH1, MSH2, PMS2, and MSH6 and reported abnormal nuclear staining for MMR proteins in 14% of cases. The most frequent abnormal patterns included combined MLH1/PMS2 loss and combined MSH2/MSH6 loss (27). In another study from Isfahan that evaluated 31 early-onset CRC patients from HNPCC families, absent MMR staining was reported in 22.6% of cases, including MSH2/MSH6 loss, MLH1/PMS2 loss, and isolated MSH6 loss (28). A population-based study from Northeastern Iran screened consecutive CRC cases between 2013 and 2016 and reported dMMR in

approximately 10% of both early-onset and late-onset CRC groups (29). Compared with these Iranian reports, the observed frequency of IHC-defined dMMR/MSI-suggestive phenotype in our cohort was higher. This difference may be related to the small sample size, selected single-center archival design, differences in case selection, regional variation, and absence of molecular confirmation in the present study. Therefore, our findings should be interpreted as cohort-specific observations rather than population-level prevalence estimates (30).

Regarding demographic characteristics, our study revealed that dMMR was more common in patients aged 50 years or younger (P = 0.012). This finding is partially in agreement with large-scale studies showing an enrichment of MSI-H/dMMR colorectal cancers among very young patients and potential age-related molecular heterogeneity. Gutierrez et al. reported a bimodal age distribution of MSI-H/dMMR CRC (21). Ugai et al. demonstrated that early-onset tumors are molecularly distinct from later-onset tumors, with a higher prevalence of MSI-H in most colorectal subsites (31). BRAF mutation analysis, MLH1 promoter methylation testing, germline testing, and detailed family history were not available; therefore, the sporadic or hereditary basis of dMMR could not be determined in this cohort. Although dMMR by immunohistochemistry may identify cases that require further molecular or genetic evaluation, the presence of Lynch syndrome cannot be inferred from the available data.

In addition, we did not observe any significant association between sex and MMR status. Although female sex has been reported as an independent predictor of MLH1 promoter methylation among MSI-H colorectal cancers, especially in older sporadic cases, sex was not significantly associated with MMR expression pattern in the present cohort (32).

Histological type was significantly associated with MMR expression pattern. Combined MMR protein loss was more frequently observed in mucinous adenocarcinoma than in adenocarcinoma not otherwise specified (27, 33, 34, 35). This finding is consistent with the well-known association between mucinous histology and MSI-associated colorectal carcinoma/MMR deficiency. Mucinous differentiation is one of the clinicopathological features associated with MMR deficiency/MSI-associated colorectal carcinoma and may prompt careful evaluation of MMR protein expression especially in the setting of young age, right-sided tumor location or other suggestive histological features (34, 36).

Tumor grade was also significantly associated with pattern of MMR protein expression. Combined loss of MMR proteins was more frequent in high-grade tumors and retention of all four MMR proteins was more frequent in low-grade tumors. This observation is in line with several previous studies associating dMMR and MSI-associated phenotypes with poor differentiation or high-grade morphology (37). However, the association between MMR status and grade has not been consistent across all studies (27). This inconsistency may be attributable to differences in sample size, tumor classification, population characteristics, and methods used to define dMMR or MSI.

The present study demonstrated that MMR expression pattern was significantly associated with tumor site. Right-sided tumors more often showed combined loss of MMR proteins, whereas left-sided tumors more often had retained MMR expression. This finding is consistent with the known tendency for MMR-deficient and MSI-associated colorectal carcinomas to arise in the proximal colon (27, 37, 38). Right-sided predominance has been linked to differences in embryological origin, molecular pathways, immune microenvironment and epigenetic alterations, in particular MLH1 promoter hypermethylation in the sporadic cases. However, the mechanism of MMR protein loss could not be ascertained because MLH1 promoter methylation and BRAF mutation testing were not performed in this study (4, 35).

The identification of IHC-defined dMMR/MSI-suggestive phenotype may have clinical implications in CRC. Tumors with loss of MMR protein expression may require additional molecular or genetic evaluation, particularly when accompanied by clinicopathological features suggestive of MMR deficiency. However, IHC findings alone cannot distinguish sporadic from hereditary MMR deficiency. Therefore, routine MMR immunohistochemistry should be considered a screening tool for selecting cases for further evaluation rather than evidence of Lynch syndrome. In addition, molecular confirmation of MSI status is required before drawing therapeutic conclusions related to MSI-H/dMMR colorectal cancer (30, 39).

This study has several limitations. First, it was a retrospective single-center study with a relatively small selected archival cohort. Second, MSI status was not confirmed by PCR or next-generation sequencing. Third, MLH1 promoter methylation analysis, BRAF mutation testing, germline testing, detailed family history, tumor stage, and clinical follow-up data were not available; therefore, the sporadic or hereditary basis and prognostic implications of dMMR could not be determined. Although younger age may support the need for further molecular or genetic evaluation in appropriate clinical settings, Lynch syndrome cannot be inferred from the available data. Fourth, pre-analytical and technical factors related to archival FFPE tissue, including fixation quality, antigen preservation, antibody performance, staining variability, and interpretation-related variability, may also have affected IHC results. Fifth, repeat IHC and molecular correlation were not performed; therefore, equivocal staining patterns could not be correlated with molecular MSI status.

Despite these limitations, this study provides descriptive cohort-based data on IHC-based MMR protein expression patterns in CRC cases from Afzalipour Hospital, Kerman, Iran. The observed associations between MMR protein loss and clinicopathological features should be interpreted as exploratory findings. Larger studies with molecular confirmation, MLH1 methylation analysis, BRAF testing, germline evaluation, and clinical follow-up are required to better define the frequency, molecular basis, and clinical implications of dMMR in this region.

5. CONCLUSION

In this selected single-center cohort, IHC evaluation of MLH1, MSH2, MSH6, and PMS2 identified IHC-defined dMMR/MSI-suggestive phenotype in a relatively high proportion of CRC cases. MMR expression patterns showed associations with age, mucinous histology, tumor grade, and tumor location; however, these findings should be interpreted cautiously because of the small sample size, selected cohort design, and absence of molecular MSI confirmation. Routine MMR immunohistochemistry may be useful as a screening tool to identify cases requiring further molecular or genetic evaluation. Molecular confirmation by PCR or NGS is required to determine MSI status and to distinguish sporadic from hereditary causes of

MMR deficiency. Larger studies with molecular validation are needed to confirm these findings.

Funding

This work was supported by the Kerman University of Medical Sciences.

Conflict of interest

The authors declare that they have no competing interests.

Data Availability

The data that support the findings of this study are available from the corresponding author upon reasonable request.

Ethics Approval

This study was approved by the Ethics Committee of Kerman University of Medical Sciences (Ethics code: IR.KMU.AH.REC.1397.124). All procedures were conducted in accordance with the ethical principles of the Declaration of Helsinki. As this was a retrospective study based on archived anonymized tissue samples, the ethics committee waived the need for written informed consent. Patient confidentiality was strictly maintained throughout the study.

Authors' Contributions

Maryam Iranpour: Conceptualization, data curation, and validation Ali Hadipour: Methodology, writing, and review Fatemeh Khara: Methodology, writing, and editing Shahriar Dabiri: Data curation and validation Maryam Samareh Salavatipour: Conceptualization, writing, and validation

REFERENCES

1. Sung H, Ferlay J, Siegel RL, Laversanne M, Soerjomataram I, Jemal A, et al. Global Cancer Statistics 2020: GLOBOCAN Estimates of Incidence and Mortality Worldwide for 36 Cancers in 185 Countries. CA Cancer J Clin. 2021;71(3):209-249. [DOI:10.3322/caac.21660] [PMID:33538338]
2. Li Q, Geng S, Luo H, Wang W, Mo Y-Q, Luo Q, et al. Signaling pathways involved in colorectal cancer: pathogenesis and targeted therapy. Signal Transduction and Targeted Therapy. 2024;9(1):266. [DOI:10.1038/s41392-024-01953-7] [PMCID:PMC11456611] [PMID:39370455]
3. Blank A, Roberts DE, Dawson H, Zlobec I, Lugli A. Tumor Heterogeneity in Primary Colorectal Cancer and Corresponding Metastases. Does the Apple Fall Far From the Tree?. Front Med (Lausanne). 2018;5:234. [DOI:10.3389/fmed.2018.00234] [PMCID:PMC6128217] [PMID:30234115]
4. Boland CR, Goel A. Microsatellite instability in colorectal cancer. Gastroenterology. 2010;138(6):2073-2087. [DOI:10.1053/j.gastro.2009.12.064] [PMCID:PMC3037515] [PMID:20420947]
5. Grillo F, Paudice M, Gambella A, Bozzano S, Sciallero S, Puccini A, et al. Evaluating mismatch repair deficiency in colorectal cancer biopsy specimens. Histochem Cell Biol. 2023;160(2):113-125. [DOI:10.1007/s00418-023-02202-8] [PMCID:PMC10386921] [PMID:37284845]
6. Kasi A, Handa S, Bhatti S, Umar S, Bansal A, Sun W. Molecular Pathogenesis and Classification of Colorectal Carcinoma. Curr Colorectal Cancer Rep. 2020;16(5):97-106. [DOI:10.1007/s11888-020-00458-z] [PMCID:PMC7469945] [PMID:32905465]
7. Nguyen LH, Goel A, Chung DC. Pathways of Colorectal Carcinogenesis. Gastroenterology. 2020;158(2):291-302. [DOI:10.1053/j.gastro.2019.08.059] [PMCID:PMC6981255] [PMID:31622622]
8. Nádorvári ML, Lotz G, Kulka J, Kiss A, Tímár J. Microsatellite instability and mismatch repair protein deficiency: equal predictive markers?. Pathol Oncol Res. 2024;30:1611719. [DOI:10.3389/pore.2024.1611719] [PMCID:PMC11036414] [PMID:38655493]
9. Tian Z, Yang L, Yang R, Yang W. The prognostic and immunomodulatory role of the MMR system in patients with stomach adenocarcinoma. Scientific Reports. 2025;15(1):180. [DOI:10.1038/s41598-024-84613-8] [PMCID:PMC11695722] [PMID:39748125]
10. DeWitt JT, Jimenez-Tovar D, Mazumder A, Haricharan S. Advances in diagnostic and therapeutic applications of mismatch repair loss in cancer. DNA Repair. 2025;147:103822. [DOI:10.1016/j.dnarep.2025.103822] [PMCID:PMC12817362] [PMID:40068557]
11. Taieb J, Svrcek M, Cohen R, Basile D, Tougeron D, Phelip J-M. Deficient mismatch repair/microsatellite unstable colorectal cancer: Diagnosis, prognosis and treatment. European Journal of Cancer. 2022;175:136-157. [DOI:10.1016/j.ejca.2022.07.020] [PMID:36115290]
12. Fan W-X, Su F, Zhang Y, Zhang X-L, Du Y-Y, Gao Y-J, et al. Oncological characteristics, treatments and prognostic outcomes in MMR-deficient colorectal cancer. Biomarker Research. 2024;12(1):89. [DOI:10.1186/s40364-024-00640-7] [PMCID:PMC11346251] [PMID:39183366]
13. Jin Z, Sinicrope FA. Prognostic and Predictive Values of Mismatch Repair Deficiency in Non-Metastatic Colorectal Cancer. Cancers (Basel). 2021;13(2):300. [DOI:10.3390/cancers13020300] [PMCID:PMC7830023] [PMID:33467526]
14. Lee C-T, Chow N-H, Chen Y-L, Ho C-L, Yeh Y-M, Lin S-C, et al. Clinicopathological features of mismatch repair protein expression patterns in colorectal cancer. Pathology - Research and Practice. 2021;217:153288. [DOI:10.1016/j.prp.2020.153288] [PMID:33276219]
15. Park Y, Nam SK, Seo SH, Park KU, Oh HJ, Park YS, et al. Comprehensive Study of Microsatellite Instability Testing and Its Comparison With Immunohistochemistry in Gastric Cancers. J Gastric Cancer. 2023;23(2):264-274. [DOI:10.5230/jgc.2023.23.e5] [PMCID:PMC10154139] [PMID:37129151]
16. Zhang P, Wang A, Bian C, Zhang J, Jiang C, Zhou H. Evaluation of mismatch-repair and microsatellite-instability status in a Chinese colorectal cancer Cohort. Asian Journal of Surgery. 2024;47(2):959-967. [DOI:10.1016/j.asjsur.2023.12.176] [PMID:38185557]
17. Amemiya K, Hirotsu Y, Nagakubo Y, Watanabe S, Amemiya S, Mochizuki H, et al. Simple IHC reveals complex MMR alternations than PCR assays: Validation by LCM and next-generation sequencing. Cancer Medicine. 2022;11(23):4479-4490. [DOI:10.1002/cam4.4832] [PMCID:PMC9741978] [PMID:35596629]
18. Friker LL, Perwein T, Waha A, Dörner E, Klein R, Blattner-Johnson M, et al. MSH2, MSH6, MLH1, and PMS2 immunohistochemistry as highly sensitive screening method for DNA mismatch repair deficiency syndromes in pediatric high-grade glioma. Acta Neuropathologica. 2025;149(1):11. [DOI:10.1007/s00401-025-02846-x] [PMCID:PMC11788232] [PMID:39894875]
19. Jung J, Kang Y, Lee YJ, Kim E, Ahn B, Lee E, et al. Comparison of the Mismatch Repair System between Primary and Metastatic Colorectal Cancers Using Immunohistochemistry. J Pathol Transl Med. 2017;51(2):129-136. [DOI:10.4132/jptm.2016.12.09] [PMCID:PMC5357758] [PMID:28192899]
20. Lemos Garcia J, Rosa I, Saraiva S, Marques I, Fonseca R, Lage P, et al. Routine Immunohistochemical Analysis of Mismatch Repair Proteins in Colorectal Cancer-A Prospective Analysis. Cancers (Basel). 2022;14(15):3730. [DOI:10.3390/cancers14153730] [PMCID:PMC9367501] [PMID:35954394]

21. Gutierrez C, Ogino S, Meyerhardt JA, Iorgulescu JB. The Prevalence and Prognosis of Microsatellite Instability-High/Mismatch Repair-Deficient Colorectal Adenocarcinomas in the United States. JCO Precis Oncol. 2023;7:e2200179. [DOI:10.1200/po.22.00179] [PMCID:PMC9928756] [PMID:36716414]

22. Ward R, Kirkland L, Chen G, Endicott M, Green HD, Bailey SER, et al. The prevalence of mismatch repair deficiency and microsatellite instability in colorectal cancer. Colorectal Cancer. 2025;14(1):2552102. [DOI:10.1080/1758194x.2025.2552102]

23. Mei WJ, Mi M, Qian J, Xiao N, Yuan Y, Ding PR. Clinicopathological characteristics of high microsatellite instability/mismatch repair-deficient colorectal cancer: A narrative review. Front Immunol. 2022;13:1019582. [DOI:10.3389/fimmu.2022.1019582] [PMCID:PMC9822542] [PMID:36618386]

24. Dunne PD, Arends MJ. Molecular pathological classification of colorectal cancer—an update. Virchows Archiv. 2024;484(2):273-285. [DOI:10.1007/s00428-024-03746-3] [PMCID:PMC10948573] [PMID:38319359]

25. Bateman AC. DNA mismatch repair proteins: scientific update and practical guide. J Clin Pathol. 2021;74(4):264-268. [DOI:10.1136/jclinpath-2020-207281] [PMID:33597222]

26. Parente P, Grillo F, Vanoli A, Macciomei MC, Ambrosio MR, Scibetta N, et al. The day-to-day practice of MMR and MSI assessment in colorectal adenocarcinoma: what we know and what we still need to explore. Digestive Diseases. 2023;41(5):746-756. [DOI:10.1159/000531003] [PMID:37231848]

27. Molaei M, Mansoori BK, Ghiasi S, Khatami F, Attarian H, Zali M. Colorectal cancer in Iran: immunohistochemical profiles of four mismatch repair proteins. Int J Colorectal Dis. 2010;25(1):63-69. [DOI:10.1007/s00384-009-0784-1] [PMID:19707776]

28. Zeinalian M, Emami MH, Naimi A, Salehi R, Hashemzadeh-Chaleshtori M. Immunohistochemical analysis of mismatch repair proteins in Iranian colorectal cancer patients at risk for lynch syndrome. Iranian Journal of Cancer Prevention. 2015;8(1):11-17. [PMCID:PMC4360346] [PMID:25821566]

29. Goshayeshi L, Ghaffarzadegan K, Khooei A, Esmaeilzadeh A, Rahmani Khorram M, Mosannen Mozaffari H, et al. Prevalence and clinicopathological characteristics of mismatch repair-deficient colorectal carcinoma in early onset cases as compared with late-onset cases: a retrospective cross-sectional study in Northeastern Iran. BMJ open. 2018;8(8):e023102. [DOI:10.1136/bmjopen-2018-023102] [PMCID:PMC6119423] [PMID:30166308]

30. Sepulveda AR, Hamilton SR, Allegra CJ, Grody W, Cushman-Vokoun AM, Funkhouser WK, et al. Molecular Biomarkers for the Evaluation of Colorectal Cancer: Guideline From the American Society for Clinical Pathology, College of American Pathologists, Association for Molecular Pathology, and the American Society of Clinical Oncology. J Clin Oncol. 2017;35(13):1453-1486. [DOI:10.1200/jco.2016.71.9807] [PMID:28165299]

31. Ugai T, Haruki K, Harrison TA, Cao Y, Qu C, Chan AT, et al. Molecular Characteristics of Early-Onset Colorectal Cancer According to Detailed Anatomical Locations: Comparison With Later-Onset Cases. Am J Gastroenterol. 2023;118(4):712-726. [DOI:10.14309/ajg.0000000000002171] [PMCID:PMC10065351] [PMID:36707929]

32. Poynter JN, Siegmund KD, Weisenberger DJ, Long TI, Thibodeau SN, Lindor N, et al. Molecular characterization of MSI-H colorectal cancer by MLHI promoter methylation, immunohistochemistry, and mismatch repair germline mutation screening. Cancer Epidemiol Biomarkers Prev. 2008;17(11):3208-3215. [DOI:10.1158/1055-9965.epi-08-0512] [PMCID:PMC2628332] [PMID:18990764]

33. Huang YQ, Yuan Y, Ge WT, Hu HG, Zhang SZ, Zheng S. Comparative features of colorectal and gastric cancers with microsatellite instability in Chinese patients. J Zhejiang Univ Sci B. 2010;11(9):647-653. [DOI:10.1631/jzus.b1000198] [PMCID:PMC2932874] [PMID:20803768]

34. Kakar S, Aksoy S, Burgart LJ, Smyrk TC. Mucinous carcinoma of the colon: correlation of loss of mismatch repair enzymes with clinicopathologic features and survival. Modern Pathology. 2004;17(6):696-700. [DOI:10.1038/modpathol.3800093] [PMID:15017435]

35. Baran B, Mert Ozupek N, Yerli Tetik N, Acar E, Bekcioglu O, Baskin Y. Difference Between Left-Sided and Right-Sided Colorectal Cancer: A Focused Review of Literature. Gastroenterology Res. 2018;11(4):264-273. [DOI:10.14740/gr1062w] [PMCID:PMC6089587] [PMID:30116425]

36. Hashmi AA, Ali R, Hussain ZF, Faridi N, Khan EY, Bakar SMA, et al. Mismatch repair deficiency screening in colorectal carcinoma by a four-antibody immunohistochemical panel in Pakistani population and its correlation with histopathological parameters. World J Surg Oncol. 2017;15(1):116. [DOI:10.1186/s12957-017-1158-8] [PMCID:PMC5485685] [PMID:28651545]

37. Ismael NE, El Sheikh SA, Talaat SM, Salem EM. Mismatch Repair Proteins and Microsatellite Instability in Colorectal Carcinoma (MLH1, MSH2, MSH6 and PMS2): Histopathological and Immunohistochemical Study. Open Access Maced J Med Sci. 2017;5(1):9-13. [DOI:10.3889/oamjms.2017.003] [PMCID:PMC5320899] [PMID:28293308]

38. Faghani M, Fakhrieh Asl S, Mansour-Ghanaei F, Aminian K, Tarang A, Seighalani R, et al. The Correlation between Microsatellite Instability and the Features of Sporadic Colorectal Cancer in the North Part of Iran. Gastroenterol Res Pract. 2012;2012:756263. [DOI:10.1155/2012/756263] [PMCID:PMC3507153] [PMID:23213329]

39. Le DT, Uram JN, Wang H, Bartlett BR, Kemberling H, Eyring AD, et al. PD-1 Blockade in Tumors with Mismatch-Repair Deficiency. N Engl J Med. 2015;372(26):2509-2520. [DOI:10.1056/NEJMoa1500596] [PMCID:PMC4481136] [PMID:26028255]