Iran J Pathol. 2027;22(1):113–120 | ISSN 2345-3656 | MAIN SUBJECTS GI, Liver & Pancreas Pathology

Immunohistochemical Expression of HER2/neu and Programmed Death Ligand-1 (PD-L1) in Gastric and Gastroesophageal Junction Epithelial Malignancies and Association with Clinicopathological Parameters: A Cross-Sectional Study from a Tertiary Care Centre in Eastern India

Parni Verma[1], Tarique Anwer[1], Tarun Kumar[1]*, Surabhi[1], Ruchi Sinha[1], Punam Prasad Bhadani[1], Kunal Parasar[2], Pritanjali Singh[3]

1. Department of Pathology/Lab Medicine, All India Institute of Medical Sciences - Patna, Bihar- 801505, India
2. Department of Surgical Gastroenterology, All India Institute of Medical Sciences - Patna, Bihar- 801505, India
3. Department of Radiation Oncology, All India Institute of Medical Sciences - Patna, Bihar- 801505, India

RECEIVED 16 Jun 2026 ACCEPTED 26 Sep 2026 PUBLISHED ONLINE 22 Oct 2026 DOI 10.22034/ijp.2026.2088020.3674

ABSTRACT

Background & Objective: Gastric carcinoma (GC) is a major cause of cancer-related mortality worldwide. HER2/neu and PD-L1 are clinically relevant biomarkers in advanced gastric and gastroesophageal-junction (GEJ) cancer, although data from the Indian subcontinent remain limited. This study aimed to evaluate HER2/neu and PD-L1 expression in gastric epithelial malignancies and assess their association with clinicopathological parameters.

Methods: This descriptive cross-sectional study was conducted at the Department of Pathology, AIIMS Patna, from December 2021 to June 2023. Ninety-eight histopathologically confirmed cases were included (75 biopsies and 23 resections). HER2/neu was assessed using the 4B5 clone (Ventana) and scored according to the modified Hofmann criteria. PD-L1 was evaluated using the SP263 clone (Ventana) and scored using the combined positive score (CPS), with CPS ≥1 considered positive.

Results: The cohort included 65 men (66.3%) and 33 women (33.7%), with a mean age of 56.3 years. The distal stomach was the predominant site (78.6%), and adenocarcinoma not otherwise specified (NOS) was the most common histological subtype (55.1%). HER2/neu positivity (3+) was observed in 17.3% of cases, including 15 of 17 (88.2%) adenocarcinomas, NOS. HER2/neu expression was statistically significant associations with age group (P = .01) and histological subtype (P = .03), but not with the other clinicopathological parameters examined. PD-L1 was positive in 2 of 98 cases (2.0%); associations with clinicopathological variables were exploratory because of the small number of positive cases.

Conclusion: HER2/neu positivity supports routine HER2 testing in advanced or metastatic gastric and GEJ adenocarcinoma. The low PD-L1 positivity rate should be interpreted cautiously given the small number of positive cases and the use of a single assay.

KEYWORDS Gastric carcinoma, HER2/neu, programmed death ligand-1 (PD-L1), immunohistochemistry

Corresponding Information: Tarun Kumar, Department of Pathology/Lab Medicine, All India Institute of Medical Sciences - Patna, Bihar- 801505, India, drtarunk@aiimspatna.org

Copyright © 2027 The Author(s). This is an open-access article distributed under the terms of the CC BY 4.0, which permits unrestricted use, distribution, and reproduction in any medium, provided the original work is properly cited.

INTRODUCTION

Globally, gastric cancer (GC) continues to be a significant public health issue, ranking as the fifth most common cancer and the fifth leading cause of cancer-related deaths worldwide (1). According to GLOBOCAN 2022, approximately 968,784 new cases and 660,175 deaths occurred globally; the corresponding age-standardized incidence and mortality rates were 9.2 and 6.1 per 100,000, respectively (1). The burden of GC is highest in Asia, representing over two-thirds of all newly diagnosed cases worldwide (1). In 2022, India recorded approximately 65,853 new gastric cancer cases and 48,426 deaths, with an age-standardized incidence rate of 4.6 per 100,000 population, a higher incidence among men, and a disproportionately high disease burden in parts of northeastern and southern India (2).

Conventional management of GC primarily involves surgical resection, chemotherapy, and radiotherapy, with surgery serving as the mainstay of treatment, although its applicability is often limited in advanced-stage disease. Chemotherapy and radiotherapy are administered in the neoadjuvant or adjuvant setting but have variable efficacy and may be associated with significant treatment-related adverse effects (3). Many GC patients are diagnosed at an advanced stage, limiting treatment options and leading to poor survival rates (4, 5). Despite progress in diagnosis and treatment that has resulted in modest survival improvements, the overall prognosis remains dismal because of the high propensity for invasion and metastasis (6). GC is a highly heterogeneous malignancy characterized by diverse histopathological, molecular, and clinical features. This variability greatly affects tumor progression, prognosis, and

patient response to therapy (3, 4). The survival rates for patients with advanced GC undergoing palliative chemotherapy continue to be low, underscoring the need for more effective treatment options. Advances in understanding the molecular mechanisms of carcinogenesis have supported the development of targeted therapies that aim to disrupt signaling pathways responsible for cellular differentiation, growth, and survival (7).

HER2 (ERBB2, also referred to as HER2/neu) is a proto-oncogene located on chromosome 17 that encodes a 185-kDa transmembrane tyrosine kinase receptor belonging to the epidermal growth factor receptor family. Activation and phosphorylation of this receptor initiate downstream signaling pathways that regulate cellular proliferation, differentiation, survival, and apoptosis (8, 9). Although HER2/neu is normally expressed in epithelial cells, gene amplification and protein overexpression have been identified in GC and gastroesophageal junction (GEJ; the anatomical junction between the distal esophagus and the proximal stomach) adenocarcinomas (8, 9). The National Comprehensive Cancer Network (NCCN) guidelines indicate that HER2/neu positivity in GC occurs in about 12%–23% of cases (5). Additionally, joint guidelines from the College of American Pathologists (CAP), the American Society for Clinical Pathology (ASCP), and the American Society of Clinical Oncology (ASCO) state that HER2/neu overexpression or amplification in GEJ adenocarcinomas varies from 7% to 38% (10). HER2/neu overexpression in GC shows significant variation by histological subtype and tumor differentiation, occurring more frequently in the intestinal type than in the diffuse type, and in moderately differentiated tumors compared with poorly differentiated tumors (5). The landmark ToGA (Trastuzumab for Gastric Cancer) trial demonstrated that trastuzumab, an anti-HER2/neu humanized monoclonal antibody, significantly improves overall survival in patients with HER2/neu-positive advanced GC and GEJ adenocarcinoma when combined with chemotherapy (5). The NCCN guidelines now recommend HER2/neu assessment through immunohistochemistry (IHC) or in situ hybridization (ISH) for unresectable, locally advanced, recurrent, or metastatic GC/GEJ adenocarcinoma (5).

HER2/neu is considered an important prognostic marker in GC; however, the literature remains inconclusive, with several studies reporting conflicting findings on the association between HER2/neu expression and clinical outcomes (11, 12). Several studies have demonstrated an association between HER2/neu positivity and adverse clinical outcomes (13–15). In contrast, Fisher et al., Uzun et al., and Shen et al. did not find a significant association between HER2/neu overexpression or amplification and poor prognosis (4, 16, 17). Therefore, the prognostic value of HER2/neu in GC/GEJ adenocarcinoma remains inconclusive and requires further investigation.

Programmed Death Ligand-1 (PD-L1), a type I transmembrane glycoprotein expressed on tumor cells, lymphocytes, and macrophages, mediates immune evasion through the PD-1/PD-L1 checkpoint pathway (18, 19). Recently, checkpoint inhibitors such as nivolumab and pembrolizumab, which block the PD-1/PD-L1 immune checkpoint pathway, have emerged as a promising form of immunotherapy. This blockade promotes T-lymphocyte activation and enhances antitumor immune responses, leading to improved clinical outcomes for GC patients (18–20). Several studies have examined the association between PD-L1 expression and prognosis in GC; however, the findings remain inconsistent and controversial. Böger et al. (21) and Xing et al. (22) demonstrated that high PD-L1/PD-1 expression was associated with significantly improved patient outcomes. In contrast, Eto et al. observed that GC patients with PD-L1-positive tumors who underwent curative gastrectomy had lower overall survival than those without PD-L1 expression (23). NCCN guidelines recommend PD-L1 assessment using the combined positive score (CPS) for patient selection for immunotherapy (5).

Published studies reveal significant variability in HER2/neu and PD-L1 positivity across cohorts because of differences in population, specimen type, antibody clone, and scoring system. We therefore evaluated both biomarkers in a hospital-based cohort from eastern India and examined their clinicopathological associations.

METHODS

Study Design

A prospective, hospital-based, cross-sectional study was conducted in the Department of Pathology at the All India Institute of Medical Sciences (AIIMS), Patna, Bihar, from December 2021 to June 2023. The study was approved by the Institutional Ethics Committee (letter No. AIIMS/Pat/IEC/PGTh/Jan21/35), and written informed consent was obtained from all participants.

Inclusion and Exclusion Criteria

A total of 108 gastric malignant tumors were initially identified, including 82 biopsies and 26 resection specimens. After excluding cases with non-epithelial malignancies, prior chemotherapy, or inadequate tissue for ancillary testing, 98 cases were included in the final analysis, comprising 75 biopsies and 23 resection specimens.

Histopathological Evaluation

Tissues were fixed in 10% neutral-buffered formalin for 6 to 48 hours, routinely processed, and sectioned at 3–4 μm for hematoxylin and eosin (H&E) staining. Data, including clinical, radiological, and histopathological information, were obtained from requisition forms, hospital records, and patient or attendant histories, as available. The variables analyzed included age, sex, tumor site, maximum tumor size, histologic subtype, grade, lymphovascular invasion (LVI), perineural invasion (PNI), tumor-infiltrating lymphocytes (TILs), pT stage, nodal stage, and distant metastasis.

Immunohistochemistry

IHC staining was performed on the Ventana BenchMark automated IHC stainer using prediluted, commercially validated antibodies. HER2/neu was evaluated using the monoclonal rabbit anti-HER2/neu antibody (clone 4B5, Ventana). Scoring was performed using the modified Hofmann criteria, as recommended by the CAP and NCCN guidelines, with separate criteria for biopsy and resection specimens: Score 0 – negative; Score 1+ – negative; Score 2+ – equivocal; Score 3+ – positive (3, 5). PD-L1 expression was assessed using the monoclonal rabbit anti-PD-L1 antibody (clone SP263, Ventana). The Combined Positive Score (CPS) was calculated as: [Number of PD-L1-stained cells (tumor cells + lymphocytes + macrophages) / Total viable tumor cells] × 100. CPS ≥1 was classified as PD-L1 positive per NCCN guidelines (5). Positive controls included a

doi:10.22034/ijp.2026.2088020.3674

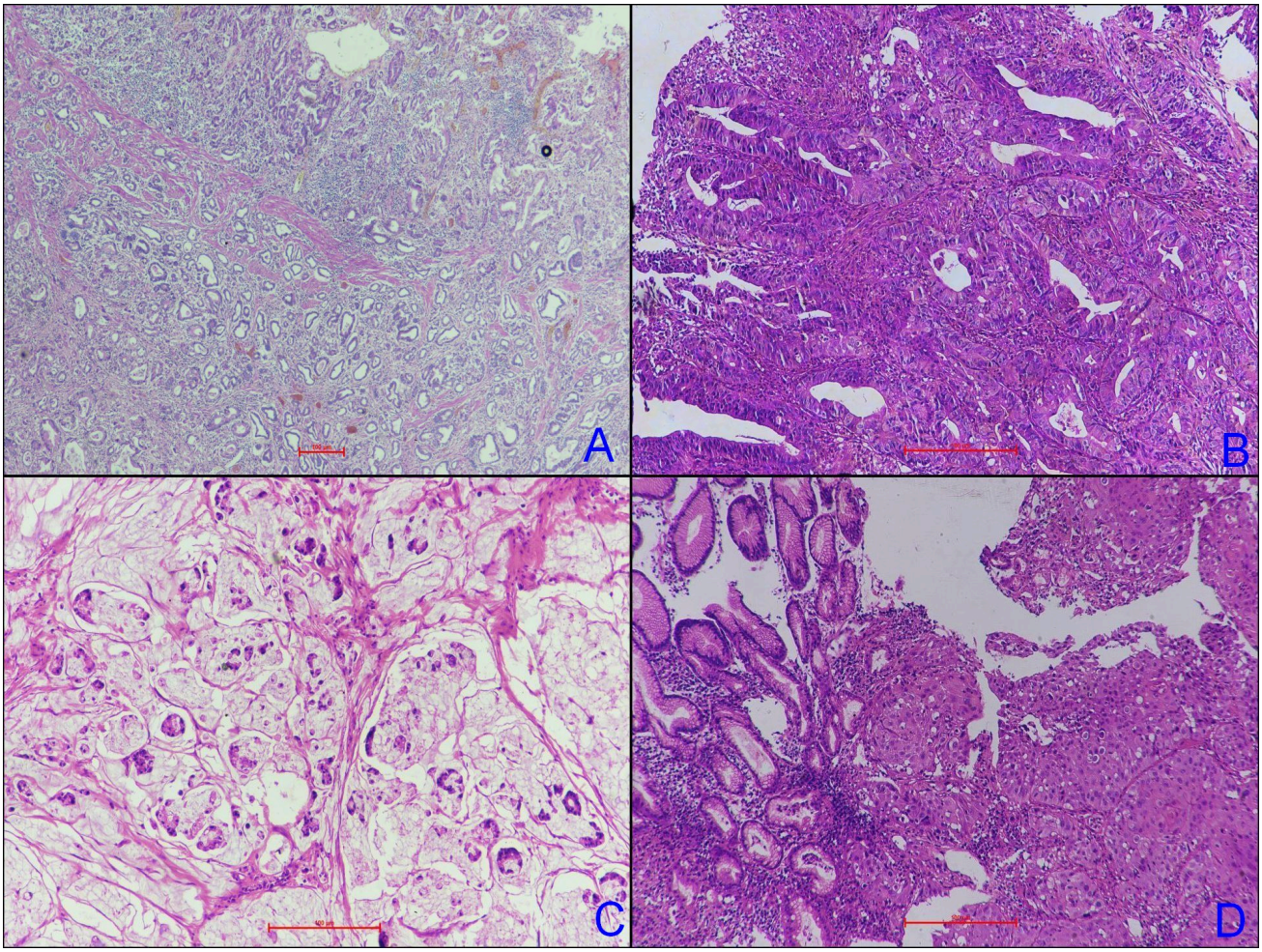

Fig 1. Histopathologic Features of Gastric Carcinoma A. Low-power photomicrograph showing infiltrating tubular adenocarcinoma arranged in irregular glands within a desmoplastic stroma. (H&E;4x). B. Moderately differentiated gastric adenocarcinoma exhibiting complex glandular architecture with nuclear atypia and stromal invasion (H&E;10x). C. Poorly cohesive/signet-ring cell carcinoma composed of discohesive malignant cells with abundant intracytoplasmic mucin displacing the nuclei eccentrically (H&E;10x). D. Gastric Squamous cell carcinoma with solid nests of tumor cells infiltrating the gastric mucosa and submucosa (H&E;10x).

known HER2-positive breast carcinoma (for HER2/neu), tonsil, and placenta (for PD-L1). Appropriate negative controls were also included.

Statistical Analysis

Data were entered and analyzed in Jamovi (version 2.3.18). Descriptive statistics included frequencies, percentages, means, medians, and standard deviations. Associations between IHC marker expression and categorical clinicopathological variables were evaluated using the χ^2 test and Fisher exact test (Fisher-Freeman-Halton exact test for tables larger than 2 × 2), with continuity correction applied when expected cell counts were <5. The Mann-Whitney U test was used to compare continuous variables between groups. No formal correction for multiple comparisons was applied; therefore, analyses involving the 2 PD-L1-positive cases were considered exploratory, and nominal *P* values were interpreted in view of the risk of type I error and sparse-cell bias. A 2-sided $P < .05$ was considered statistically significant.

RESULTS

Clinicopathological Features

The study comprised 98 cases of gastric epithelial malignancy (75 biopsies and 23 resection specimens). Age ranged from 25 to 81 years, with a mean (SD) of 56.3 (12.7) years and a median of 58.0 years. A male predominance was observed (65 men and 33 women; male-to-female ratio, 1.96:1). The distal stomach was the most common location (77 [78.6%]), followed by the proximal stomach (12 [12.2%]). The median maximum tumor dimension was 3.95 cm (range, 1–24 cm). On gross and radiologic evaluation, mural wall thickening was the predominant presentation (85.7%), followed by ulcero-proliferative growth (10.2%) and ulcero-infiltrative growth (4.1%). Distant metastasis was present in 33 cases (33.7%); the liver was the most common site of metastasis (36.4%), followed by the lungs (18.2%) and the bilateral ovaries (12.1%). LVI and PNI, assessed only in the 23 resection specimens, were identified in 15 (65.2%) and 10 (43.5%) cases, respectively (Table 1). Representative histopathologic features are shown in Figure 1.

doi:10.22034/ijp.2026.2088020.3674

Table 1. Clinicopathological characteristics of the study cohort (N = 98)

Clinicopathological Parameters	Category	n (%)
Age (years)	Mean (SD), 56.3 (12.7); range, 25–81	—
	< 40 years	9 (9.2%)
	40–60 years	43 (43.9%)
	> 60 years	46 (46.9%)
Sex	Men	65 (66.3%)
	Women	33 (33.7%)
Tumor Site	Distal stomach	77 (78.6%)
	Proximal stomach	12 (12.2%)
	Diffuse	6 (6.1%)
	Gastroesophageal (GE) junction	3 (3.1%)
Histological Subtype	Adenocarcinoma, NOS	54 (55.1%)
	Poorly cohesive carcinoma (signet-ring cell type)	26 (26.5%)
	Tubular adenocarcinoma	8 (8.2%)
	Mixed (tubular + poorly cohesive)	6 (6.1%)
	Mucinous adenocarcinoma	2 (2.0%)
	Papillary adenocarcinoma	1 (1.0%)
	Squamous cell carcinoma	1 (1.0%)
Tumor Grade	Well differentiated (G1)	5 (5.1%)
	Moderately differentiated (G2)	65 (66.3%)
	Poorly differentiated (G3)	28 (28.6%)
Max. Tumor Size (Median 3.95 cm, range 1–24 cm)	≤ 5 cm	63 (64.3%)
	> 5 cm	35 (35.7%)
Lymphovascular Invasion (LVI) resection specimens only (n=23)	Present	15 (65.2%)
	Absent	8 (34.8%)
Perineural Invasion (PNI) resection specimens only (n=23)	Present	10 (43.5%)
	Absent	13 (56.5%)
Distant Metastasis	Present	33 (33.7%)
	Absent	65 (66.3%)
Site of Metastasis (n=33 patients with distant metastasis)	Liver	12 (36.4%)
	Lung	6 (18.2%)
	Ovary	4 (12.1%)
	Other/multiple sites	11 (33.3%)

GE = gastroesophageal; LVI = lymphovascular invasion; PNI = perineural invasion; SD = standard deviation.

HER2/neu Expression and Clinicopathological Associations

Of 98 cases analyzed, 17 (17.3%) were HER2/neu-positive (IHC score 3+), 4 (4.1%) were equivocal (IHC score 2+), and 77 (78.6%) were negative (Table 2; Figure 2A–C). Among HER2/neu-positive cases, the predominant histological subtype was adenocarcinoma, NOS (15/17 cases, 88.2%), with 2 cases showing poorly cohesive/signet-ring cell morphology (Figure 1C). Well-differentiated tumors were uniformly HER2/neu negative. HER2/neu positivity was more frequent in women (6/33, 18.2%) than in men (11/65, 16.9%); however, this difference was not statistically significant (P > .99, Fisher exact test). The median age was 55.0 years (interquartile range [IQR], 48.0–60.0) in HER2/neu-positive cases versus 59.0 years (IQR, 47.0–65.0) in HER2/neu-negative cases (P = .39, Mann-Whitney U test). Distal tumors had the highest number of HER2/neu-positive cases, with 13 of 77 (16.9%). GEJ adenocarcinomas exhibited the highest proportion of HER2/neu positivity, with 2 of 3 cases (66.7%). No significant association was found between HER2/neu expression and factors such as sex (P > .99), tumor grade (P = .40), tumor site (P = .15), LVI (P > .99), or distant metastasis (P = .26). HER2/neu expression was significantly associated with age group (P = .01) and histological subtype (P = .03). Among resection specimens, HER2/neu positivity was confined to T2 (25.0%) and T3 (22.2%) stage tumors, with no statistically significant association (P = .61).

PD-L1 Expression and Clinicopathological Associations

PD-L1 positivity (CPS ≥1) was observed in only 2 of 98 cases (2.0%; Figure 2D–F). When evaluating cellular compartments separately, immune cell staining was positive in 6 cases (6.1%), whereas tumor cell staining was positive in 2 cases (2.0%). Both PD-L1-positive cases occurred in men. No statistically significant associations were observed between PD-L1 expression and sex (P = .55), age group (P > .99), tumor site (P = .19), LVI, distant metastasis, or tumor stage. Our study found nominally significant associations between PD-L1 expression and histological subtype (P = .006) and tumor grade (P = .002); however, these findings are exploratory and potentially unstable given the very small number of PD-L1-positive cases (n = 2). Therefore, they should be interpreted cautiously, without drawing biological or causal inferences. Both PD-L1-positive cases were HER2/neu negative (P > .99, Fisher exact test); this absence of coexpression is descriptive and does not establish biological mutual exclusivity or have implications for combination therapy.

P values were calculated using the Fisher exact test (2-sided) for 2 × 2 categorical comparisons (*) and the Fisher-Freeman-Halton exact test for categorical variables with more than 2 groups (#). Dashes indicate that *P* values could not be calculated because there were no PD-L1-positive cases in these categories.

P < .05 was considered statistically significant.

DISCUSSION

This study evaluated IHC expression of HER2/neu and PD-L1 in gastric and gastroesophageal epithelial malignancies in an eastern Indian population. The demographic profile of our cohort, including a mean age of 56.3 years, a male predominance (male-to-female ratio, 1.96:1), and distal gastric predilection (78.6%), is broadly consistent with previously reported cohorts. The mean age of our cohort (56.3 years) was slightly lower than in most Western studies (mean 63–65 years), likely reflecting an earlier age of disease onset in the Indian population (6, 7). Multiple studies have reported HER2/neu (3+) positivity rates ranging from 7.5% to 35%, indicating significant variation

doi:10.22034/ijp.2026.2088020.3674

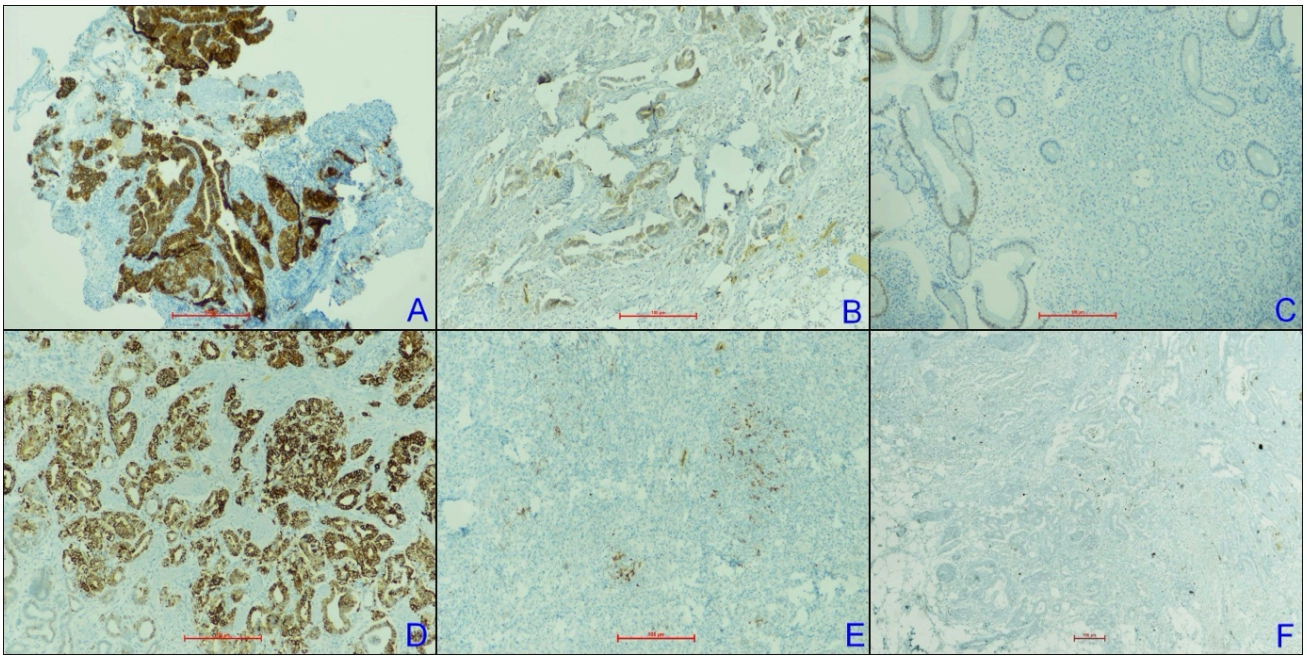

Fig 2. Immunohistochemical Expression of HER2/neu and PD-L1 A. Strong, complete basolateral/lateral membranous HER2/neu positivity in tumor cells (score 3+) (IHC: 10X). B. Weak to moderate incomplete membranous HER2/neu staining in infiltrating tumor glands (score 2+) (IHC: 10X). C. Negative HER2/neu expression with absence of significant membranous staining in tumor cells (score 0) (IHC: 10X). D. PD-L1 positivity in tumor cells showing membranous staining (IHC: 10X). E. Focal/patchy PD-L1 expression in tumor-associated inflammatory cells and tumor cells (IHC: 10X). F. Negative PD-L1 expression in both tumor cells and immune cells (IHC: 4X).

Table 2. Association of clinicopathological features with HER2/neu and PD-L1 expression (N = 98)

Parameter	Category	HER2/neu+, n (%)	P value	PD-L1+, n (%)	P value
Sex	Men	11 (16.9%)	>.99*	2 (3.1%)	.55*
	Women	6 (18.2%)		0 (0.0%)	
Age Group	< 40 yrs	1 (11.1%)	.01#	0 (0.0%)	>.99#
	40–60 yrs	13 (30.2%)		1 (2.3%)	
	> 60 yrs	3 (6.5%)		1 (2.2%)	
Histology (WHO Classification of Tumours of the Digestive System, 5th ed.)	Adenocarcinoma, NOS (n=54)	15 (27.8%)	.03#	0 (0.0%)	.006#
	Poorly cohesive / signet-ring (n=26)	2 (7.7%)		0 (0.0%)	
	Tubular adenocarcinoma (n=8)	0 (0.0%)		2 (25.0%)	
	Other subtypes (n=10)	0 (0.0%)		0 (0.0%)	
Tumor Grade	Well diff. (G1), n=5	0 (0.0%)	.40#	2 (40.0%)	.002#
	Moderately diff. (G2), n=65	14 (21.5%)		0 (0.0%)	
	Poorly diff. (G3), n=28	3 (10.7%)		0 (0.0%)	
Tumor Site	Distal (n=77)	13 (16.9%)	.15#	1 (1.3%)	.19#
	Proximal (n=12)	1 (8.3%)		0 (0.0%)	
	Diffuse (n=6)	1 (16.7%)		1 (16.7%)	
	GE junction (n=3)	2 (66.7%)		0 (0.0%)	
LVI (resections, n=23)	Present (n=15)	1 (6.7%)	>.99*	0	-
	Absent (n=8)	0		0	
Distant Metastasis	Present (n=33)	8 (24.2%)	.26*	0	-
	Absent (n=65)	9 (13.8%)		0	
pT stage (resections, n=23)	T1 (n=2)	0	.61#	0	-
	T2 (n=4)	1 (25.0%)		0	
	T3 (n=9)	2 (22.2%)		0	
	T4 (n=8)	0		0	

reflecting differences in population, tumor composition, specimen type, antibody clone, and scoring criteria (Table 3). In our study, HER2/neu overexpression (3+) was found in 17.3% of cases, aligning with the results of Marx et al. (16%), Yoshida et al.

doi:10.22034/ijp.2026.2088020.3674

Table 3. Prevalence of HER2/neu positivity in patients with gastric cancer

Author (Year)	No. of cases	HER2/neu (3+) %	HER2/neu (2+) %	HER2/neu (0/1+) %
Marx et al. (26) (2009)	166	27 (16%)	NA	NA
Fisher et al. (17) (2013)	111	13 (11.7%)	37 (33.3%)	61 (55%)
Yoshida et al. (24) (2013)	365	61 (17%)	73 (20%)	231 (63%)
Aditi et al. (28) (2016)	58	16 (27.6%)	2 (3.4%)	40 (69%)
Shen et al. (16) (2016)	1562	548 (35%)	NA	1014 (65%)
Rajadurai et al. (29) (2018)	228	56 (24.6%)	NA	172 (75.4%)
Pereira et al. (25) (2019)	282	50 (17.7%)	69 (24.4%)	163 (57.8%)
Soliman et al. (27) (2019)	76	14 (18%)	27 (36%)	35 (46%)
Bermúdez et al. (30) (2021)	142	19 (13.4%)	NA	NA
Bokhary et al. (11) (2025)	122	10 (8.2%)	NA	60 (49.2%)
He et al. (31) (2025)	332	25 (7.5%)	81 (24.4%)	226 (68.1%)
Uzun et al. (4) (2025)	300	48 (16%)	42 (13.7%)	211 (70.3%)
Our study	98	17 (17.3%)	4 (4.1%)	77 (78.6%)

(17%), Pereira et al. (17.7%), Soliman et al. (18%), and Uzun et al. (16%) (4, 24–27). HER2/neu equivocal (2+) expression was seen in 4.1% of cases, whereas 78.6% of tumors were HER2/neu negative (0/1+). These findings are consistent with reports in the literature and demonstrate the variability of HER2/neu expression in gastric carcinoma across different populations and studies.

HER2/neu positivity is more common in moderately differentiated (21.5%) and poorly differentiated (10.7%) types of adenocarcinoma, which is consistent with studies by Kim et al. (32) and Marx et al. (26). In most studies, tumors that are well-differentiated show a very low rate of HER2/neu positivity (26). Most of the positive cases in our study were from biopsy specimens rather than resection specimens. These differences may reflect variations in IHC scoring criteria between biopsy and surgically resected specimens (5). By definition, if at least one cancer cell cluster of 5 neoplastic cells with membranous HER2/neu immunoreactivity was detected, the biopsy specimen was scored 0, 1+, 2+, or 3+. In contrast, for surgically resected specimens, if membranous HER2/neu immunoreactivity comprised less than 10% of the tumor area, irrespective of pattern or intensity, the tumor was assigned a HER2/neu score of 0 (10). Our study does not compare HER2/neu IHC expression between surgical specimens and matched biopsies. Studies show that marked intratumor heterogeneity in HER2/neu expression reduces concordance between biopsy and resection specimens (7). According to Rüschoff et al., biopsy specimens should be obtained from at least eight tumor sites for HER2/neu testing to account for possible tumor heterogeneity (33).

Because ISH was unavailable at our institute, 4 equivocal cases (IHC 2+) could not be further classified. Therefore, the true prevalence of HER2-positive cases is uncertain and may have been underestimated.

In our study, PD-L1 positivity was only 2.0%, substantially lower than that reported in other studies, including Wang L et al. (37.3%, clone 28-8, Abcam), Attia S et al. (43.1%, clone QR001, Quartett), Zhang L et al. (50.8%, ab58810 rabbit polyclonal, Abcam), and Lian J et al. (57.3%, clone 22C3 pharmDx), all of which used similar CPS ≥ 1 criteria (20, 34–36). Significant interassay variability among PD-L1 clones in GC has been well established, which likely explains the inconsistency (37). PD-L1 expression was observed in only 2 cases, both with tubular adenocarcinoma histology and a well-differentiated grade; therefore, this finding must be interpreted cautiously, and no mechanistic inference can be drawn. However, Lian et al. reported that PD-L1 expression was negatively correlated with GC differentiation grade (36). The intriguing link with well-differentiated GC warrants further study in larger cohorts.

In our study, PD-L1 was assessed only with SP263 and was not compared with 22C3 or 28-8 in paired samples. Therefore, the low positivity rate cannot be attributed to SP263, and our findings do not demonstrate that SP263 is inappropriate for gastric cancer. The two PD-L1-positive cases and their nominal associations with histology and grade are descriptive and exploratory. These data do not support mechanistic inference, conclusions about biological mutual exclusivity, or implications for combination therapy. The low number of positive cases and the absence of a formal multiple-comparison correction increase the risk of type I error and limit the stability of the *P* values.

LIMITATIONS

Relatively small sample size (n = 98) limiting statistical power, particularly for subgroup analyses.

Only 2 PD-L1-positive cases

Unavailability of ISH (FISH/SISH) for confirmation of HER2 equivocal (IHC 2+) cases, potentially underestimating the true HER2-positive rate.

Use of clone SP263 (Ventana) for PD-L1 assessment, contributing to low positivity rates, cannot be attributed to the assay because no paired comparison with another validated assay was performed in this cohort

Absence of a paired comparator assay for SP263

Predominance of biopsy specimens (76.5%) limited definitive histological subtyping and TNM staging, available only in resection specimens.

CONCLUSION

HER2/neu positivity was identified in 17.3% of this eastern Indian cohort. This finding supports HER2/neu testing in patients with advanced or metastatic GC or GEJ adenocarcinoma, with interpretation according to current guideline criteria and confirmation of equivocal IHC 2+ cases by ISH when indicated. PD-L1 positivity was observed in 2 of 98 cases (2.0%) using the SP263 clone with a CPS ≥1 threshold. Because only two cases were positive, no statistically reliable or biologically definitive association can be inferred. The low rate cannot be attributed to SP263 without a paired comparison with 22C3 or 28-8. Larger, multicenter studies incorporating specimen type, intratumoral heterogeneity, ISH for HER2-equivocal cases, validated PD-L1 clones, MSI, and EBV testing are needed to fully characterize the molecular landscape of gastric carcinoma in India.

Funding

This research received no specific grant from any funding agency in the public, commercial, or not-for-profit sectors.

Conflict of interest

The authors declare no conflict of interest.

Data Availability

The data that support the findings of this study are available from the corresponding author upon reasonable request.

Ethics Approval

The study was approved by the Institutional Ethics Committee of AIIMS Patna vide letter no. AIIMS/Pat/IEC/PGTh/Jan21/35. Written informed consent was obtained from all participants or their legal guardians. All procedures were in accordance with the ethical standards of the institutional ethics committee and medical research on human participants carried out according to the World Medical Association Declaration of Helsinki.

Authors' Contributions

Conceptualization: PV, TA, TK, SUR, RS, PPB, Methodology: PV, TK, SUR, RS, PPB Investigation: PV, TK, SUR, RS, PPB, KP, PS Original Draft Preparation: PV, TA, TK, SUR, KP, PS Review & Editing: PV, TA, TK, SUR, RS, PPB, KP, PS PV: Dr. Parni Verma, TA: Dr. Tarique Anwer, TK: Dr. Tarun Kumar, SUR: Dr. Surabhi, RS: Dr. Ruchi Sinha, PPB: Dr. Punam Prasad Bhadani, KP: Dr. Kunal Parasar, PS: Dr. Pritanjali Singh All authors have read and agreed to the published version of the manuscript.

Declaration of AI Use

The authors declare that no generative AI or AI-assisted technologies were used in the writing process of this manuscript.

REFERENCES

1. International Agency for Research on Cancer. Global Cancer Observatory: cancer today. Stomach fact sheet [Internet]. Lyon (France): International Agency for Research on Cancer; [cited 2026 May 14]. Available from: https://gco.iarc.who.int/today/en/fact-sheets-cancers/7/stomach
2. International Agency for Research on Cancer. Global Cancer Observatory: cancer today. India fact sheet [Internet]. Lyon (France): International Agency for Research on Cancer; [cited 2026 May 14]. Available from: https://gco.iarc.who.int/media/globocan/factsheets/populations/356-india.
3. Ratti M, Citterio C, Orlandi E, Vecchia S, Anselmi E, Toscani I, et al. Fighting HER2 in gastric cancer: current approaches and future landscapes. Int J Mol Sci. 2025;26(15):7285. [DOI:10.3390/ijms26157285] [PMCID:PMC12346744] [PMID:40806416]
4. Uzun M, Gokcek S, Kilinc M, Ekinci F, Avci T, Erdogan AP, et al. The effect of HER2 status on gastric cancer survival and the clinical implications of the HER2-low definition: a retrospective study. Medicina (Kaunas). 2025;61(9):1675. [DOI:10.3390/medicina61091675] [PMCID:PMC12471298] [PMID:41011066]
5. Ajani JA, D'Amico TA, Bentrem DJ, Chao J, Cooke D, Corvera C, et al. Gastric Cancer, Version 2.2022, NCCN Clinical Practice Guidelines in Oncology. J Natl Compr Canc Netw. 2022;20(2):167-192. [DOI:10.6004/jnccn.2022.0008] [PMID:35130500]
6. Cristescu R, Lee J, Nebozhyn M, Kim KM, Ting JC, Wong SS, et al. Molecular analysis of gastric cancer identifies subtypes associated with distinct clinical outcomes. Nat Med. 2015;21(5):449-456. [DOI:10.1038/nm.3850] [PMID:25894828]
7. Gravalos C, Jimeno A. HER2 in gastric cancer: a new prognostic factor and a novel therapeutic target. Ann Oncol. 2008;19(9):1523-1529. [DOI:10.1093/annonc/mdn169] [PMID:18441328]
8. Ménard S, Pupa SM, Campiglio M, Tagliabue E. Biologic and therapeutic role of HER2 in cancer. Oncogene. 2003;22(42):6570-6578. [DOI:10.1038/sj.onc.1206779] [PMID:14528282]
9. Hu HH, Wang SQ, Zhao H, Chen ZS, Shi X, Chen XB. HER2+ advanced gastric cancer: current state and opportunities (review). Int J Oncol. 2024;64(4):36. [DOI:10.3892/ijo.2024.5624] [PMCID:PMC10901538] [PMID:38391024]
10. Bartley AN, Christ J, Fitzgibbons PL, Hamilton SR, Kakar S, Shah MA, et al. Template for reporting results of HER2 (ERBB2) biomarker testing of specimens from patients with adenocarcinoma of the stomach or esophagogastric junction. Arch Pathol Lab Med. 2015;139(5):618-620. [DOI:10.5858/arpa.2014-0395-CP] [PMID:25275813]
11. Bokhary RY. Prevalence of HER2 expression and its association with clinicopathological parameters in gastric and gastroesophageal junction adenocarcinoma: a 10-year experience of an academic center. Mol Clin Oncol. 2025;22(6):49. [DOI:10.3892/mco.2025.2844] [PMCID:PMC12001012] [PMID:40242368]
12. Guan WL, He Y, Xu RH. Gastric cancer treatment: recent progress and future perspectives. J Hematol Oncol. 2023;16:57. [DOI:10.1186/s13045-023-01451-3] [PMCID:PMC10225110] [PMID:37245017]
13. Li W, Zhang X, Du Y, Zhang Y, Lu J, Hu W, et al. HER2-targeted advanced metastatic gastric/gastroesophageal junction adenocarcinoma: treatment landscape and future perspectives. Biomark Res. 2022;10:71. [DOI:10.1186/s40364-022-00416-x] [PMCID:PMC9524015] [PMID:36175985]
14. Kurokawa Y, Matsuura N, Kimura Y, Adachi S, Fujita J, Imamura H, et al. Multicenter large-scale study of prognostic impact of HER2 expression in patients with resectable gastric cancer. Gastric Cancer. Gastric Cancer. 2015;18(4):691-697. [DOI:10.1007/s10120-014-0430-7] [PMID:25224659]
15. García I, Vizoso F, Martín A, Sanz L, Abdel-Lah O, Raigoso P, et al. Clinical significance of the epidermal growth factor receptor and HER2 receptor in resectable gastric cancer. Ann Surg Oncol. 2003;10(3):234-241. [DOI:10.1245/ASO.2003.05.010] [PMID:12679307]

16. Shen GS, Zhao JD, Zhao JH, Ma XF, Du F, Kan J, et al. Association of HER2 status with prognosis in gastric cancer patients undergoing R0 resection: a large-scale multicenter study in China. World J Gastroenterol. 2016;22(23):5406-5414. [DOI:10.3748/wjg.v22.i23.5406] [PMCID:PMC4910661] [PMID:27340357]

17. Fisher SB, Fisher KE, Squires MH 3rd, Patel SH, Kooby DA, El-Rayes BF, et al. HER2 in resected gastric cancer: is there prognostic value?. J Surg Oncol. 2014;109(2):61-66. [DOI:10.1002/jso.23456] [PMID:24122802]

18. Zhang Y, Yang Y, Chen Y, Lin W, Chen X, Liu J, et al. PD-L1: biological mechanism, function, and immunotherapy in gastric cancer. Front Immunol. 2022;13:1060497. [DOI:10.3389/fimmu.2022.1060497] [PMCID:PMC9729722] [PMID:36505487]

19. Chen XJ, Wei CZ, Lin J, Zhang RP, Chen GM, Li YF, et al. Prognostic significance of PD-L1 expression in gastric cancer patients with peritoneal metastasis. Biomedicines. 2023;11(7):2003. [DOI:10.3390/biomedicines11072003] [PMCID:PMC10377298] [PMID:37509642]

20. Zhang L, Qiu M, Jin Y, Ji J, Li B, Wang X, et al. Programmed cell death ligand 1 (PD-L1) expression on gastric cancer and its relationship with clinicopathologic factors. Int J Clin Exp Pathol. 2015;8(9):11084-11091. [PMCID:PMC4637642] [PMID:26617827]

21. Böger C, Behrens HM, Mathiak M, Krüger S, Kalthoff H, Röcken C. PD-L1 is an independent prognostic predictor in gastric cancer of Western patients. Oncotarget. 2016;7(17):24269-24283. [DOI:10.18632/oncotarget.8169] [PMCID:PMC5029700] [PMID:27009855]

22. Xing X, Guo J, Wen X, Ding G, Li B, Dong B, et al. Analysis of PD1, PDL1, PDL2 expression and T cells infiltration in 1014 gastric cancer patients. Oncoimmunology. 2017;7(3):e1356144. [DOI:10.1080/2162402X.2017.1356144] [PMCID:PMC5790386] [PMID:29399387]

23. Eto S, Yoshikawa K, Nishi M, Higashijima J, Tokunaga T, Nakao T, et al. Programmed cell death protein 1 expression is an independent prognostic factor in gastric cancer after curative resection. Gastric Cancer. 2016;19(2):466-471. [DOI:10.1007/s10120-015-0519-7] [PMID:26210691]

24. Yoshida H, Yamamoto N, Taniguchi H, Oda I, Katai H, Kushima R, et al. Comparison of HER2 status between surgically resected specimens and matched biopsy specimens of gastric intestinal-type adenocarcinoma. Virchows Arch. 2014;465(2):145-154. [DOI:10.1007/s00428-014-1597-3] [PMID:24889042]

25. Pereira MA, Ramos MFKP, Dias AR, Faraj SF, Ribeiro RRE, De Castria TB, et al. Expression profile of markers for targeted therapy in gastric cancer patients: HER-2, microsatellite instability and PD-L1. Mol Diagn Ther. 2019;23(6):761-771. [DOI:10.1007/s40291-019-00424-y] [PMID:31595457]

26. Marx AH, Tharun L, Muth J, Dancau AM, Simon R, Yekebas E, et al. HER-2 amplification is highly homogenous in gastric cancer. Hum Pathol. 2009;40(6):769-777. [DOI:10.1016/j.humpath.2008.11.014] [PMID:19269014]

27. Soliman N, Ibrahim D. Study of expression of programmed death ligand 1 and HER2/neu in gastric carcinoma with clinicopathological correlations, in a plan to validate them in immune and targeted therapies. Egypt J Pathol. 2019;39(2):270-279. [DOI:10.4103/EGJP.EGJP_35_19]

28. Aditi R, Aarathi R, Pradeep R, Hemalatha L, Akshatha C, Amar K. HER2 expression in gastric adenocarcinoma—a study in a tertiary care centre in South India. Indian J Surg Oncol. 2016;7(1):18-24. [DOI:10.1007/s13193-015-0436-6] [PMCID:PMC4811822] [PMID:27065677]

29. Rajadurai P, Fatt HK, Ching FY. Prevalence of HER2 positivity and its clinicopathological correlation in locally advanced/metastatic gastric cancer patients in Malaysia. J Gastrointest Cancer. 2018;49(2):150-157. [DOI:10.1007/s12029-017-9921-1] [PMCID:PMC5948243] [PMID:28124769]

30. Bermúdez A, Arranz-Salas I, Mercado S, López-Villodres JA, González V, Ríus F, et al. Her2-positive and microsatellite instability status in gastric cancer-clinicopathological implications. Diagnostics (Basel). Diagnostics (Basel). 2021;11(6):944. [DOI:10.3390/diagnostics11060944] [PMCID:PMC8228707] [PMID:34070574]

31. He WZ, Yang YZ, Yin CX, Xian XY, Gu JM, Yi JH, et al. Evolution of HER2-low expression from primary to paired metastatic gastric cancer lesions. NPJ Precis Oncol. 2025;9:108. [DOI:10.1038/s41698-025-00881-1] [PMCID:PMC12000306] [PMID:40234621]

32. Kim MA, Jung EJ, Lee HS, Lee HE, Jeon YK, Yang HK, et al. Evaluation of HER-2 gene status in gastric carcinoma using immunohistochemistry, fluorescence in situ hybridization, and real-time quantitative polymerase chain reaction. Hum Pathol. 2007;38(9):1386-1393. [DOI:10.1016/j.humpath.2007.02.005] [PMID:17555797]

33. Rüschoff J, Hanna W, Bilous M, Hofmann M, Osamura RY, Penault-Llorca F, et al. HER2 testing in gastric cancer: a practical approach. Mod Pathol. 2012;25(5):637-650. [DOI:10.1038/modpathol.2011.198] [PMID:22222640]

34. Wang L, Zhang Q, Ni S, Tan C, Cai X, Huang D, et al. Programmed death-ligand 1 expression in gastric cancer: correlation with mismatch repair deficiency and HER2-negative status. Cancer Med. 2018;7(6):2612-2620. [DOI:10.1002/cam4.1502] [PMCID:PMC6010739] [PMID:29673110]

35. Attia S, Abd El Hafez A, Abdel-Aziz A, Elmetwaly S, Mokhtar N. Prognostic value of PD-L1 immunohistochemical marker in gastric carcinoma and its correlation with HER2 status. Asian Pac J Cancer Prev. 2022;23(4):1433-1444. [DOI:10.31557/APJCP.2022.23.4.1433] [PMCID:PMC9375601] [PMID:35485706]

36. Lian J, Zhang G, Zhang Y, Liu H, Zhang J, Nan P, et al. PD-L1 and HER2 expression in gastric adenocarcinoma and their prognostic significance. Dig Liver Dis. Dig Liver Dis. 2022;54(10):1419-1427. [DOI:10.1016/j.dld.2022.01.128] [PMID:35123909]

37. Park Y, Koh J, Na HY, Kwak Y, Lee KW, Ahn SH, et al. PD-L1 testing in gastric cancer by the combined positive score of the 22C3 pharmDx and SP263 assay with clinically relevant cut-offs. Cancer Res Treat. 2020;52(3):661-670. [DOI:10.4143/crt.2019.718] [PMCID:PMC7373862] [PMID:32019283]