Iran J Pathol. 2027;22(1):102–104 | ISSN 2345-3656 | MAIN SUBJECTS Bone & Soft tissue Pathology

Beyond the Usual Site: Fibrous Dysplasia of the Elbow Mimicking Giant Cell Tumor

Gunvanti Rathod[1]*, Srikanth Eppakayala[2], Maheshwar Lakkireddy[2], Akanksha Mahapatra[1]

1. Department of Pathology, All India Institute of Medical Sciences, Bibinagar, India
2. Department of Orthopedics, All India Institute of Medical Sciences, Bibinagar, India

RECEIVED 25 Aug 2026 ACCEPTED 29 Sep 2026 PUBLISHED ONLINE 21 Oct 2026 DOI 10.22034/ijp.2026.2087194.3641

Corresponding Information: Gunvanti Rathod, Department of Pathology, All India Institute of Medical Sciences, Bibinagar, India, neempath@gmail.com

Copyright © 2027 The Author(s). This is an open-access article distributed under the terms of the CC BY 4.0, which permits unrestricted use, distribution, and reproduction in any medium, provided the original work is properly cited.

Fibrous dysplasia (FD) is a benign fibro-osseous lesion characterized by the replacement of normal medullary bone with fibrous tissue and immature woven bone. It is a developmental anomaly caused by postzygotic activating mutations in the *GNAS* gene, leading to abnormal osteoblastic differentiation and disorganized bone formation (1, 2). FD accounts for approximately 5–7% of all benign bone tumors and may present in either monostotic or polyostotic forms, with the former being more common (3). The long bones, particularly the femur and tibia, along with craniofacial bones and ribs, are the most frequently involved sites (2, 3). Involvement of the elbow region is distinctly uncommon, and lesions in this location may pose a diagnostic challenge, especially when they occur near the articular surface in skeletally mature individuals.

We report a rare case of monostotic FD involving the epimetaphyseal region of the elbow in an 18-year-old woman that was initially suspected to be a giant cell tumor (GCT) on the basis of radiological findings. This case highlights the importance of histopathological evaluation in establishing the correct diagnosis, particularly in unusual anatomical locations where clinical and imaging features may be misleading.

The patient presented with pain in the left elbow region that was insidious in onset and gradually progressive. The pain was dull and aching and radiated to the forearm. It was aggravated by physical activity, particularly weight lifting, and responded minimally to analgesics. Within a few days of onset, the patient noticed diffuse swelling over the dorsal aspect of the proximal forearm (Figure 1). There was no history of trauma, fever, weight loss, or other systemic symptoms. On physical examination, a firm, nontender swelling was palpable over the elbow region. The swelling was ill-defined and did not change appreciably with joint movement. Terminal movements of the elbow joint were mildly restricted. There was no local warmth, and neurovascular examination of the limb was unremarkable.

Plain radiographs revealed a well-defined, expansile, lytic lesion in the epimetaphyseal region of the proximal part of ulna bone with cortical thinning but no aggressive periosteal reaction (Figure 2). A core needle biopsy was attempted; however, the specimen was inadequate, containing only hemorrhagic material, and the result was inconclusive.

In view of the clinical and radiological suspicion of GCT, the patient underwent open biopsy followed by intralesional curettage and reconstruction with bone cement (Figure 3). The curetted material consisted of multiple gray-white togray-brown tissue fragments. Histopathological examination revealed a lesion composed of fibrous stroma containing irregular, curvilinear trabeculae of immature woven bone. These trabeculae showed the characteristic “Chinese character-like” pattern and lacked osteoblastic rimming. The intervening stroma consisted of bland spindle-shaped fibroblastic cells without nuclear atypia, mitotic activity, or necrosis. Occasional multinucleated giant cells were present but were unevenly scattered and lacked the uniform distribution typical of GCT. On the basis of these findings, a diagnosis of monostotic FD was established (Figures 4 and 5).

Fibrous dysplasia results from activating mutations in the *GNAS* gene, which encodes the α subunit of the stimulatory G protein (Gsα). These mutations lead to constitutive activation of adenylate cyclase and increased intracellular cyclic adenosine monophosphate levels, disrupting normal bone maturation and resulting in replacement of normal bone with fibro-osseous tissue (1, 2). The mosaic distribution of the mutation accounts for the variability in clinical presentation, ranging from isolated monostotic lesions to widespread polyostotic involvement, sometimes with associated endocrine abnormalities, as in McCune-Albright syndrome.

The radiological appearance of FD is variable but often includes a well-defined intramedullary lesion with a characteristic “ground-glass” matrix and cortical thinning (3). However, lesions in atypical locations, such as the elbow, and particularly those in subarticular regions, may mimic other neoplastic conditions. In skeletally mature individuals, epimetaphyseal lesions are more commonly due to GCT, which may lead to diagnostic confusion (4).

Giant cell tumor of bone is a locally aggressive neoplasm that typically arises in the epiphysis of long bones in young adults after skeletal maturity. Radiologically, it presents as an expansile, lytic lesion with cortical thinning and possible extension to the subarticular region. Histologically, GCT is characterized by numerous uniformly distributed osteoclast-like multinucleated giant cells within a background of mononuclear stromal cells, which represent the neoplastic component (5). In contrast, FD demonstrates irregular woven bone trabeculae without osteoblastic rimming and a fibrous stroma composed of bland spindle cells (6, 7). The presence of multinucleated giant cells in FD, particularly in areas of hemorrhage or microfracture, can

doi:10.22034/ijp.2026.2087194.3641



Fig 1. shows progressive swelling over the left elbow

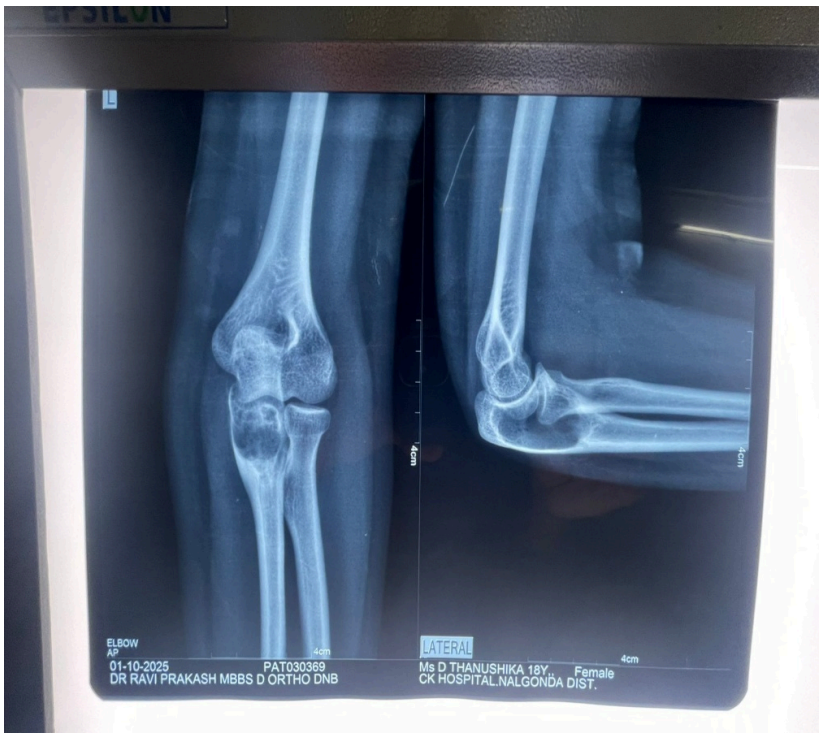

Fig 2. Plain X ray of the swelling showed a well-defined, expansile, and lytic lesion in the epimetaphyseal region of the elbow bone, with thinning of the cortex but no aggressive periosteal reaction



Fig 3. Shows an intraoperative image of open biopsy with intralesional curettage and reconstruction with bone cement

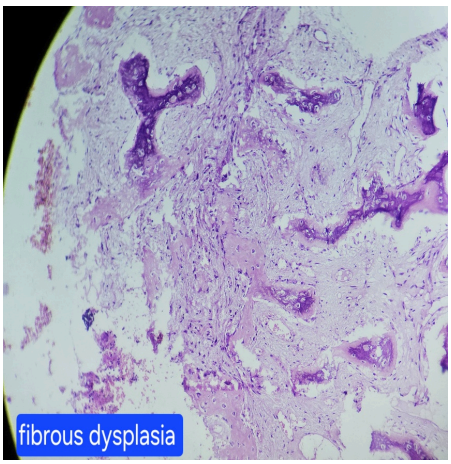

Fig 4. Shows Irregular, C-shaped or Chinese character-like spicules (trabeculae) of woven bone with intervening fibrous stroma composed of bland spindle cells without atypia (Hematoxylin and Eosin stain, ×10).

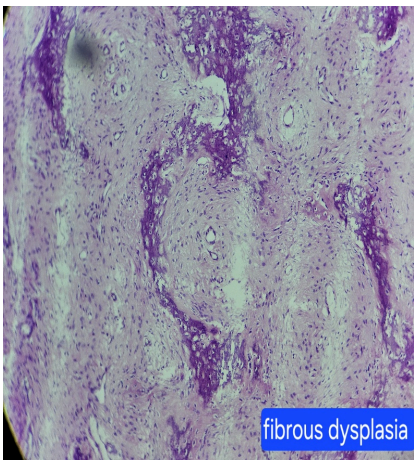

Fig 5. shows the bony trabeculae lack osteoblastic rimming. No cytologic atypia or necrosis is identified (Hematoxylin and Eosin stain, ×40).

further complicate the diagnosis, especially in small or inadequate biopsy specimens. In the present case, the initial core biopsy yielded only hemorrhagic material, highlighting the limitations of needle biopsy in certain bone lesions. Adequate sampling through open biopsy or curettage is often necessary to obtain representative tissue for definitive diagnosis.

Other important differential diagnoses include aneurysmal bone cyst and low-grade central osteosarcoma. Aneurysmal bone cyst is characterized by blood-filled cystic spaces separated by fibrous septa containing osteoclast-type giant cells and reactive bone formation. Low-grade osteosarcoma may closely resemble FD but typically shows permeative growth, mild cytologic atypia, and osteoblastic rimming of malignant osteoid (8). The absence of cytologic atypia, mitotic activity, and malignant osteoid in the present case helped exclude these entities.

Management of FD depends on the clinical presentation. Asymptomatic lesions are often managed conservatively with regular follow-up, as many lesions stabilize after skeletal maturity. Surgical intervention is reserved for patients with pain, deformity, or risk of fracture. Intralesional curettage with or without bone grafting or cementation is a commonly used treatment (4, 9). In the present case, curettage and cement reconstruction provided both diagnostic tissue and therapeutic benefit. The risk of malignant transformation in FD is low (estimated at <1%) and is more commonly associated with polyostotic disease or prior radiation exposure (10).

Nevertheless, long-term follow-up is recommended, particularly for lesions with atypical clinical or radiological features.

This case underscores the diagnostic challenges posed by FD when it occurs in uncommon anatomical locations such as the elbow. The epimetaphyseal location in a skeletally mature individual closely mimicked GCT both clinically and radiologically. Furthermore, the initially inconclusive biopsy highlights the importance of obtaining adequate and representative tissue for histopathological evaluation. Awareness of such atypical presentations is crucial to avoid misdiagnosis and inappropriate management.

In conclusion, monostotic FD of the elbow region is a rare entity that can closely mimic GCT of bone, particularly when it occurs in the epimetaphyseal region of skeletally mature individuals. Histopathological examination remains the gold standard for definitive diagnosis, especially for lesions in unusual locations with overlapping imaging features. Careful assessment of morphological characteristics, combined with adequate and representative tissue sampling, is crucial to avoid misdiagnosis and ensure appropriate management. Awareness of this potential diagnostic pitfall can help pathologists and clinicians make accurate and timely decisions, ultimately improving patient outcomes.

Declaration of generative AI and AI-assisted technologies in the manuscript preparation process

During the preparation of this work, the authors used Grammarly and ChatGPT to correct grammar and edit the article. After using these tools, the authors reviewed and edited the content as needed and take full responsibility for the content of the published article.

Research Ethics and Patient Consent

Single case reports are exempt from institutional ethics committee approval per institutional policy. Written informed consent for publication was obtained from the patient.

Funding

This research received no specific grant from any funding agency in the public, commercial, or not-for-profit sectors. Authorship Contributions Surgical and Medical Practices: GR, SE, ML; Concept, Design, Data Collection: GR, SE, ML, AM; Literature Search, Writing: GR, SE, ML

Conflict of interest

The authors declare no conflicts of interest.

Data Availability

The data that support the findings of this study are available from the corresponding author upon reasonable request.

Ethics Approval

Single case reports are exempt from institutional ethics committee approval per institutional policy. Written informed consent for publication was obtained from the patient.

Authors' Contributions

Surgical and Medical Practices: GR, SE, ML; Concept, Design, Data Collection: GR, SE, ML, AM; Literature Search, Writing: GR, SE, ML

Declaration of AI Use

During the preparation of this work, the authors used Grammarly and ChatGPT to correct grammar and edit the article. After using these tools, the authors reviewed and edited the content as needed and take full responsibility for the content of the published article.

REFERENCES

1. Kransdorf MJ, Moser RP Jr, Gilkey FW. Fibrous dysplasia. *Radiographics*. 1990;10(3):519-537. [DOI:10.1148/radiographics.10.3.2188311] [PMID:2188311]
2. Parekh SG, Donthineni-Rao R, Ricchetti E, Lackman RD. Fibrous dysplasia. *J Am Acad Orthop Surg*. 2004;12(5):305-313. [DOI:10.5435/00124635-200409000-00005] [PMID:15469225]
3. Lee JS, FitzGibbon EJ, Chen YR, Kim HJ, Lustig LR, Akintoye SO, et al. Clinical guidelines for the management of craniofacial fibrous dysplasia. Orphanet J Rare Dis. 2012;7(Suppl 1). [DOI:10.1186/1750-1172-7-S1-S2] [PMCID:PMC3359960] [PMID:22640797]
4. DiCaprio MR, Enneking WF. Fibrous dysplasia: pathophysiology, evaluation, and treatment. *J Bone Joint Surg Am*. 2005;87(8):1848-1864. [DOI:10.2106/JBJS.D.02942] [PMID:16085630]
5. Rekhi B, Dave V. Giant cell tumor of bone: An update, including spectrum of pathological features, pathogenesis, molecular profile and the differential diagnoses. Histol Histopathol. 2023;38(2):139-153. [DOI:10.14670/HH-18-486] [PMID:35766228]
6. Mohan H, Mittal P, Mundi I, Kumar S. Fibrous dysplasia of bone: a clinicopathologic review. Pathol Lab Med Int. 2011;3:31-42. [DOI:10.2147/PLMI.S24866]
7. Muthusamy S, Subhawong T, Conway SA, Temple HT. Locally aggressive fibrous dysplasia mimicking malignancy: a report of four cases and review of the literature. *Clin Orthop Relat Res*. 2015;473(2):742-750. [DOI:10.1007/s11999-014-3926-x] [PMCID:PMC4294916] [PMID:25212962]
8. Malhas AM, Sumathi VP, James SL, Menna C, Carter SR, Tillman RM, Jeys L, Grimer RJ. Low-grade central osteosarcoma: a difficult condition to diagnose. Sarcoma. 2012;2012:764796. [DOI:10.1155/2012/764796] [PMID:22851905]
9. Karimi A, Hasheminasab M, Derakhshan S, Goudarzi Pour D, Khazael Najafabadi M, Hosseininavaz R. Monostotic fibrous dysplasia with rare histopathologic features: a case report. *Iran J Med Sci*. 2024;49(12):808-812. [DOI:10.30476/ijms.2024.101751.3455] [PMCID:PMC11743436] [PMID:39840307]
10. Alkhaibary A, Alassiri AH, Alsalman M, Edrees S. Unusual presentation of fibrous dysplasia in an elderly patient. *J Radiol Case Rep*. 2019;13(2):26-33. [DOI:10.3941/jrcr.v13i2.3379] [PMCID:PMC6743863] [PMID:31565169]