Iran J Pathol. 2027;22(1):91–94 | ISSN 2345-3656 | MAIN SUBJECTS Diagnostic Pathology

Tumor Budding and Worst Pattern of Invasion in Oral Squamous Cell Carcinoma: Distinct Entities or Overlapping Concepts?

Seetu Palo[1*], **Monica Mishra**[1]

1. Department of Pathology and Laboratory Medicine, All India Institute of Medical Sciences, Bibinagar, India

RECEIVED 03 Sep 2025 ACCEPTED 13 Jul 2026 PUBLISHED ONLINE 16 Oct 2026 DOI 10.22034/ijp.2026.2070705.3531

KEYWORDS Oral cancer, Tumor Budding, Worst Pattern of Invasion, Oral Squamous Cell carcinoma

Corresponding Information: Seetu Palo, Department of Pathology and Laboratory Medicine, All India Institute of Medical Sciences, Bibinagar, India, seetu.pearl@gmail.com

Copyright © 2027 The Author(s). This is an open-access article distributed under the terms of the CC BY 4.0, which permits unrestricted use, distribution, and reproduction in any medium, provided the original work is properly cited.

Tumor budding (TB) has gained considerable attention as an emerging histopathological marker in oral squamous cell carcinoma (OSCC). The potential value of TB lies in its simplicity as a morphology-based biomarker, particularly in settings where access to advanced molecular diagnostics remains limited. Multiple studies, including large series from high-incidence regions, have demonstrated significant associations between TB and adverse outcomes, such as lymph node metastasis, disease-free survival, and overall survival (Table 1) (1–6). In a meta-analysis of 22 studies, TB was identified as an independent prognostic factor for overall survival, disease-specific survival, and disease-free survival in oral cancer (7). Another meta-analysis, which synthesized data from 16 studies on the prognostic role of TB in oral cavity cancers, found that TB was significantly associated with poorer overall survival, an increased risk of lymph node metastasis, and poorer disease-free survival (8).

However, it is important to note that most studies reporting the prognostic significance of TB are retrospective and, therefore, inherently susceptible to selection bias, archival tissue degradation, and incomplete clinical follow-up. These limitations may introduce systematic bias into prognostic estimates. Furthermore, many studies did not control for critical confounding factors, including T stage, nodal status, surgical margin status, and adjuvant treatment modality.

Nevertheless, the conceptual distinction between TB and the well-established worst pattern of invasion (WPOI) warrants critical reflection. Both features describe tumor aggressiveness at the invasive front, with WPOI type IV defined by small tumor islands (<15 cells) and type V by tumor satellites ≥1 mm from the main tumor edge. TB is defined as isolated single cells or clusters of fewer than five cells without spatial restriction. Despite these definitional differences, there is morphological overlap between TB and WPOI, especially types IV and V; that is, both WPOI and TB evaluate small, detached tumor clusters at the deep invasive front. Currently, in contrast to WPOI, tumor budding has not yet been incorporated into reporting guidelines or datasets developed by organizations such as the College of American Pathologists (CAP), the Royal College of Pathologists, and the International Consortium for Cancer Reporting (ICCR) and, therefore, is not routinely assessed. Hence, it is critical to determine whether dual assessment confers incremental prognostic benefit or represents redundant evaluation of the same invasive phenotype. To date, few studies have directly evaluated TB and WPOI in the same patient cohort with formal testing for redundancy or incremental predictive value. Narayanan et al reported that TB was the strongest independent prognostic predictor of locoregional recurrence and survival in a series of 333 OSCC cases, while WPOI-5 showed significance only in univariate analysis, suggesting potential superiority of TB in that cohort (6). Conversely, other retrospective studies, predominantly from South and Southeast Asian centers, demonstrate overlapping prognostic associations, with both TB and WPOI independently predicting nodal metastasis without direct comparison of their respective effect sizes (1–5). Critically, no published study has determined whether adding TB to a WPOI-based model significantly improves prognostic performance.

Biologically, TB is thought to represent a histological correlate of epithelial–mesenchymal transition (EMT), characterized by reduced E-cadherin expression, upregulation of vimentin and ZEB1, and elevated matrix metalloproteinase activity (7, 9, 10). This may explain its strong correlation with nodal metastasis and poor outcomes. A recent study by Wang et al demonstrated that CYTOR-mediated FOSL1 phase separation drives a super-enhancer program promoting metastasis specifically in TB cells of head and neck SCC, providing mechanistic support for TB as a biologically distinct invasive phenotype (9). On the other hand, WPOI reflects the spatial distribution and detachment of tumor nests at the advancing edge, reflecting invasive behavior, stromal remodeling, and desmoplastic responses, which may engage distinct signaling cascades (11). Understanding whether TB and WPOI capture overlapping or distinct biological mechanisms could guide their clinical utility. If TB reflects EMT-driven cell detachment and WPOI reflects stromal infiltration patterns, the two may be complementary. If both are driven by the same underlying biology, routine dual assessment may be redundant. Linking TB with molecular alterations (eg, EMT markers, E-cadherin loss, matrix metalloproteinase expression) could help contextualize its biological relevance. Fig. 1 (1–8) compares the clinicopathological correlates of TB and WPOI 4/5 in OSCC.

doi:10.22034/ijp.2026.2070705.3531

Table 1. Summary of recent studies evaluating Tumor Budding and Worst Pattern of Invasion in oral squamous cell carcinoma

Author, Year, Country	Study design	Sample size	Assessment Method of TB*	Key Findings – TB	Key Findings – WPOI	Study limitations
Tan et al, 2023, Turkey (1)	Retrospective study	73	Not specified	TB was significantly associated PNI, extranodal extension, poorer overall survival	WPOI 4 and 5 showed significant relationship with lymph node metastasis.	-Small sample size and retrospective design -Detailed methodology of TB assessment not mentioned -Unclear whether the reporting pathologist was blinded to the clinical details
Khan et al,2023, India (2)	Retrospective study	71	By using a 20x objective TB was calculated and categorized as low (0–4 buds), intermediate (5–9 buds) and high (10 or more buds) in hotspot	Patients with WPOI IV and V had nodal metastasis, a higher histological grade, a high TB count and LVI		-Retrospective study with low sample size -No survival analysis
Badanale et al, 2024, India (3)	Retrospective study	90	Number of TB in one high-power field (40X) was counted at the area of maximum concentration. A cut off point of three buds (≥3) was used to divide cases into high intensity versus low intensity TB	High intensity TB was associated with LN metastasis	WPOI 4,5 were highly significant with LN metastasis.	-Retrospective study with limited cohort -Unclear whether the reporting pathologist was blinded to the clinical details -Short follow-up
Deshpande et al, 2024, India (4)	Cross-sectional study	33	TB assessed using 40x. Stratified as < 5 buds (low TB) and ≥ 5 (high TB)	Tumor staging showed positive association with TB	Tumor staging showed positive association with WPOI	-Retrospective study with very small sample -No survival analysis
Hakim et al, 2024, Germany (5)	Prospective study	129	TB assessed using 20x with field size of 0.795x 0.960 mm2	TB was significantly associated with occult LN metastasis	Not evaluated	-TB was not categorized into 'low' and 'high' -WPOI not evaluated
Narayanan et al,2025, India (6)	Cross-sectional study	333	TB assessed using 20x with field size of 0.785mm2 with highest tumor buds(hotspots). Stratified as low:0-4 buds; intermediate:5-9; high: ≥ 10 buds	TB was the most significant independent prognostic predictor for locoregional recurrence, decreased overall survival and disease free survival	WPOI 5 was associated with locoregional recurrence and decreased survival.	-Included tumors of lip,tongue, buccal mucosa,retromolar trigone, gingivobuccal sulcus, floor of the mouth but no site-specific subanalysis -Lack of stage-specific or grade-specific analysis -Unclear whether the reporting pathologist was blinded to the clinical details

*All above studies defined TB as the presence of isolated single cells or small cell clusters (<5 cells) scattered in stroma at invasive margin.

Abbreviations: TB, tumor budding; WPOI, worst pattern of invasion; PNI, perineural invasion; LN, lymph node; LVI, lymphovascular invasion; HPF, high-power field; OS, overall survival; DFS, disease-free survival; mm^2, square millimetre.

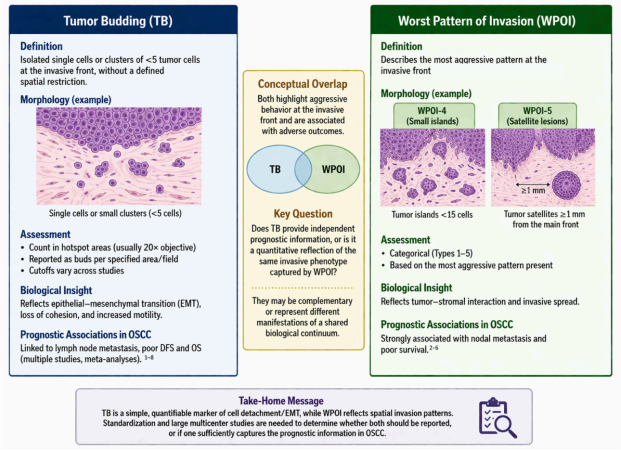

Fig 1. Comparison between tumor budding and the worst pattern of invasion in oral squamous cell carcinoma. Abbreviations: TB, tumor budding; WPOI, worst pattern of invasion; OSCC, oral squamous cell carcinoma; DFS, disease-free survival; OS, overall survival.

Despite the promising prognostic associations reported across multiple studies, important controversies persist regarding TB assessment in OSCC. Substantial heterogeneity exists in TB cutoff definitions (ranging from ≥3 to ≥10 buds), field magnification (20× vs 40×), hotspot selection criteria, and tumor area evaluated, resulting in inconsistent grading thresholds across studies (Table 1). Hence, for TB to achieve clinical applicability, methodological clarity is essential. TB assessment is inherently susceptible to both intraobserver and interobserver variability because it is performed manually and lacks a universally standardized area for evaluation (12). Unlike the worst pattern of invasion (WPOI), which is specifically assessed at the invasive tumor front, TB scoring may vary depending on factors such as slide selection (which tumor block or section is chosen for analysis), criteria for hotspot identification (whether systematic scanning or subjective selection is employed), number and magnification of fields of view analyzed, and the quality of tissue processing (orientation, section thickness, and archival slide fading). Standardized protocols for tissue processing, sectioning, orientation, and hotspot evaluation are essential if TB is to be translated into routine diagnostic practice. Furthermore, the identification of isolated tumor cells or small tumor cell clusters can be challenging on routine hematoxylin and eosin sections, particularly in the presence of a dense peritumoral inflammatory infiltrate, stromal reaction, or tissue artifacts that may obscure the tumor buds. These factors can compromise reproducibility and diagnostic accuracy. Consequently, ancillary techniques such as pancytokeratin immunohistochemistry and emerging digital image analysis or artificial intelligence-assisted methods may improve the detection of tumor buds, enhance interobserver agreement, and facilitate standardized assessment for routine clinical practice.

While existing evidence highlights the prognostic significance of both TB and WPOI, it remains unclear whether TB

provides incremental predictive value when WPOI is already assessed. Clarifying this relationship requires large, multicenter validation studies, ideally incorporating harmonized methodology and robust clinicopathological correlations. In colorectal carcinoma, the International Tumor Budding Consensus Conference (ITBCC) established a standardized framework for TB assessment, recommending H&E-stained sections, a defined field area of 0.785 mm^2, 20× objective magnification, and a three-tier grading system (low budding: 0–4; intermediate budding: 5–9; high budding: ≥10 buds), which has been prospectively validated and incorporated into national reporting guidelines (13). Several OSCC studies have adopted modified ITBCC parameters, but no equivalent oral cancer-specific consensus document currently exists (1–6). The development of an oral cancer tumor budding consensus framework, analogous to ITBCC but incorporating OSCC-specific tissue processing standards, magnification recommendations, and validated cutoff definitions, represents an urgent priority for the field. Furthermore, interpretation of the prognostic significance of TB and WPOI must account for important confounding variables. T stage and overall TNM stage are the most significant predictors of outcomes in OSCC, and studies that do not control for these in multivariate analyses risk attributing prognostic significance to TB or WPOI that may, in fact, reflect stage-specific differences. Treatment heterogeneity, including surgery alone versus surgery with adjuvant radiotherapy or chemoradiotherapy, introduces further confounding, as adjuvant treatment may modify the prognostic impact of histopathological markers. Additionally, anatomical subsite variation (oral tongue, floor of mouth, buccal mucosa, gingiva) is associated with distinct biological behavior and prognostic outcomes, and such subsite-specific analyses are lacking in recently conducted meta-analyses of TB in OSCC (7, 8, 14). Finally, the relationship between TB/WPOI and histological grading systems (WHO conventional grading, Brandwein-Gensler model, lymphovascular invasion) has not been systematically evaluated, making it difficult to isolate their independent contributions to risk stratification.

In conclusion, TB represents a promising, inexpensive, and morphologically accessible prognostic marker in OSCC. However, its practical integration into routine reporting requires clarification of its relationship with the already established WPOI system. Determining whether TB offers independent prognostic information or reflects the same biological process captured by WPOI remains an important unresolved question. Future multicenter prospective studies incorporating standardized assessment protocols are warranted to validate the prognostic utility of TB and its incremental value over WPOI. Furthermore, future studies should adjust for important confounding factors such as tumor stage, anatomical subsite, histological grade, and treatment modality to assess the true prognostic value of TB. Standardized outcome measures, including overall survival, disease-specific survival, disease-free survival, and regional lymph node metastasis, should be consistently reported to help determine whether TB should be incorporated alongside or integrated within existing invasion-based grading frameworks.

Funding

This research received no specific grant from any funding agency in the public, commercial, or non-profit sectors.

Conflict of interest

The authors declare no conflict of interest.

Data Availability

Dat sharing is not applicable to this article as no new data was created or analyzed in this study.

Ethics Approval

This study is a review of previously published literature and did not involve human participants, animals, or identifiable patient data. Therefore, institutional ethics committee approval and patient consent was not required. No individual patient data or identifiable information are included in this review.

Authors' Contributions

Conceptualization: SP; Methodology: SP; Investigation: SP, MM; Resources: SP; Data Curation: SP, MM; Formal Analysis: SP; Writing – Original Draft Preparation: SP, MM; Writing – Review & Editing: SP, MM; All authors have read and agreed to the published version of the manuscript.

Acknowledgments

NA

Declaration of AI Use

The authors declare that no generative AI or AI-assisted technologies were used in the writing of this manuscript. Generative AI (ChatGPT) was used exclusively for the creation of Figure 1, which was subsequently reviewed, verified, and edited by the authors for scientific accuracy and consistency with the published literature. The authors take full responsibility for the content of the figure. Figure 1 was based on published literature (References 1–8), with additional editing performed using Microsoft PowerPoint (Microsoft Corporation, Redmond, WA, USA).

REFERENCES

1. Tan A, Taskin T. Tumor budding should be in oral cavity cancer reporting: a retrospective cohort study based on tumor microenvironment. Cancers. 2023;15(15):3905. [DOI:10.3390/cancers15153905] [PMCID:PMC10416929] [PMID:37568721]
2. Khan AA, Ahuja S, Zaheer S, Mitha M, Ranga S. Association of worst pattern of invasion in oral squamous cell carcinoma with clinicopathological parameters. Journal of Medicine, Surgery, and Public Health. 2023;1:100029. [DOI:10.1016/j.glmedi.2023.100029]
3. Badanale R, Mohta V, Wagh A, Singh K. Prognostic role of tumor budding and worst pattern of invasion in lymph node metastasis and disease-free survival in oral squamous cell cancer patients: result from Central India's Regional Cancer Centre. Indian J Otolaryngol Head Neck Surg. 2024;76(4):3261-3270. [DOI:10.1007/s12070-024-04661-4] [PMCID:PMC11306858] [PMID:39130226]
4. Deshpande NS, Munemane AB, Karle RR, Dongre SD. Relevance of tumor budding and pattern of invasion in oral squamous cell carcinoma. Int J Appl Basic Med Res. 2024;14(1):29-34. [DOI:10.4103/ijabmr.ijabmr_391_23] [PMCID:PMC10947764] [PMID:38504839]
5. Hakim SG, Alsharif U, Falougy M, Tharun L, Rades D, Jensen J. The impact of tumor budding and single-cell invasion on survival in patients with stage III/IV locally advanced oral squamous cell carcinoma: results from a prospective cohort study. Front Oncol. 2024;14:1404361. [DOI:10.3389/fonc.2024.1404361] [PMCID:PMC11089200] [PMID:38741775]
6. Narayanan AV, Umashankar K, Aravind S, Nayanar SK, Vijay S. Tumor budding as an independent prognostic histopathological marker in oral squamous cell carcinoma: an Indian tertiary care center experience. Turk Patoloji Derg. 2025;41(2):31-41. [DOI:10.5146/tjpath.2025.13761] [PMCID:PMC12206397] [PMID:40091314]

7. Feitosa SG, Oliveira RV, Bezerra TMM, Chaves FN, Viana KF, Oliveira DFG, et al. Tumor budding and poor prognosis in oral cancer: a systematic review and meta-analysis. Asian Pac J Cancer Prev. 2023;24(8):2565-2573. [DOI:10.31557/apjcp.2023.24.8.2565] [PMCID:PMC10685247] [PMID:37642041]

8. Almangush A, Pirinen M, Heikkinen I, Mäkitie AA, Salo T, Leivo I. Tumour budding in oral squamous cell carcinoma: a meta-analysis. Br J Cancer. 2018;118:577-586. [DOI:10.1038/bjc.2017.425] [PMCID:PMC5830589] [PMID:29190636]

9. Wang W, Yun B, Hoyle RG, Ma Z, Zaman SU, Xiong G, et al. CYTOR facilitates formation of FOSL1 phase separation and super-enhancers to drive metastasis of tumor budding cells in head and neck squamous cell carcinoma. Adv Sci (Weinh). 2024;11(4):e2305002. [DOI:10.1002/advs.202305002] [PMCID:PMC10811474] [PMID:38032139]

10. Alonso SE, Serrano FA, Cuéllar IN, López AL, Acosta DF, Moure BG, et al. Clinicopathological Relevance of Tumor Budding at the Invasive Tumor Front in Early-Stage Oral Tongue Squamous Cell Carcinoma: Histological and Immunohistochemical Analysis. Head Neck. 2026;48(2):325-338. [DOI:10.1002/hed.28204] [PMID:40534595]

11. Lakhera KK, Nama Y, Maan P, Jindal R, Patel P, Singh S, et al. Worst pattern of invasion as a predictor of nodal metastasis in early-stage oral squamous cell carcinoma. Indian J Surg Oncol. 2023;14(1):160-168. [DOI:10.1007/s13193-022-01639-y] [PMCID:PMC9986178] [PMID:36891424]

12. Jakkulwar S, Vagha S, Chaudhary M. Tumour budding in oral squamous cell carcinoma: a narrative review. Cureus. 2024;16(9):e69624. [DOI:10.7759/cureus.69624] [PMCID:PMC11488996] [PMID:39429322]

13. Studer L, Blank A, Bokhorst JM, Nagtegaal ID, Zlobec I, Lugli A, et al. Taking tumour budding to the next frontier: a post-International Tumour Budding Consensus Conference (ITBCC) 2016 review. Taking tumour budding to the next frontier: a post-International Tumour Budding Consensus Conference (ITBCC) 2016 review. 2021;78(4):476-484. [DOI:10.1111/his.14267] [PMID:33001500]

14. Panchannavar GS, Angadi PV. Tumor budding is a prognostic marker for overall survival and not for lymph node metastasis: systematic review update and meta-analysis. J Oral Biol Craniofac Res. 2024;14(4):362-369. [DOI:10.1016/j.jobcr.2024.04.013] [PMCID:PMC11144740] [PMID:38832296]