Iran J Pathol. 2027;22(1):83–85 | ISSN 2345-3656 | MAIN SUBJECTS Gynecologic Pathology

Bilateral Ovarian Endometrioid Carcinoma Diagnosed in Pregnancy: A Case Report

Mahtab Naseri[1], **Sareh Etemad**[1*], **Golnaz Ghayyem Hassankhani**[2]

1. Department of Pathology, Faculty of Medicine, Mashhad University of Medical Sciences, Mashhad, Iran
2. Mashhad University of Medical Sciences, Mashhad, Iran

RECEIVED 30 Apr 2026 ACCEPTED 13 Oct 2026 PUBLISHED ONLINE 20 Oct 2026 DOI 10.22034/ijp.2026.2087506.3653

ABSTRACT

Background: Ovarian masses during pregnancy are uncommon and usually benign; only a small number are malignant. We report a rare case of bilateral ovarian endometrioid carcinoma with concurrent endometriosis diagnosed during pregnancy.

Case Presentation: A 34-year-old woman (gravida 2, para 1) was diagnosed with bilateral ovarian masses at 16 weeks of gestation during evaluation for pelvic and lower abdominal pain. At 17 weeks of gestation, intraoperative frozen section after exploratory laparotomy and left ovarian cystectomy confirmed endometrioid adenocarcinoma. The patient subsequently received 5 cycles of paclitaxel and carboplatin chemotherapy during pregnancy. At 37 weeks of gestation, she underwent cesarean delivery, hysterectomy, bilateral salpingo-oophorectomy, and pelvic lymphadenectomy. Final histopathology confirmed bilateral grade 1 endometrioid carcinoma with multiple foci of coexisting endometriosis. The patient completed adjuvant chemotherapy after delivery and showed no evidence of recurrence on follow-up.

Conclusion: This case highlights that ovarian carcinoma should be considered in the differential diagnosis of complex adnexal masses found during pregnancy. Early evaluation and multidisciplinary management are key to improving maternal and fetal outcomes.

KEYWORDS Pregnancy, Ovarian cancer, Endometrioid carcinoma, Endometriosis

Corresponding Information: Sareh Etemad, Department of Pathology, Faculty of Medicine, Mashhad University of Medical Sciences, Mashhad, Iran, etemadsr2@mums.ac.ir

Copyright © 2027 The Author(s). This is an open-access article distributed under the terms of the CC BY 4.0, which permits unrestricted use, distribution, and reproduction in any medium, provided the original work is properly cited.

INTRODUCTION

Ovarian masses are found in about 0.1% to 2% of pregnancies (1). In recent years, the incidence of adnexal masses during pregnancy has increased due to the routine use of prenatal ultrasound (2). Most of these adnexal masses are asymptomatic and found incidentally (2). The majority are benign and resolve spontaneously; however, about 2% to 5% are malignant (3–5). The incidence of ovarian carcinoma in pregnancy ranges from 1 in 10,000 to 1 in 50,000 pregnancies (4).

Although ovarian carcinoma rarely complicates pregnancy, it is important to carefully evaluate complex adnexal masses to rule out potential malignancy (6, 7). Here, we report a rare case of bilateral ovarian endometrioid carcinoma with concurrent endometriosis diagnosed during pregnancy and its clinical management.

CASE PRESENTATION

A 34-year-old pregnant woman, gravida 2, para 1, presented with pelvic and lower abdominal pain at 16 weeks of gestation. Her previous pregnancy was uncomplicated and resulted in a term vaginal delivery. She had no significant past medical history and no family history of malignancy.

Pelvic ultrasound showed bilateral ovarian masses. The left ovary contained a multicystic mass with a solid component measuring 118 × 97 mm, and the right ovary showed a cystic lesion with a solid mural nodule measuring 40 × 35 mm. Serum tumor marker evaluation showed a Risk of Ovarian Malignancy Algorithm (ROMA) score of 15.93%, human epididymis protein 4 (HE4) level of 68.1 pmol/L, cancer antigen 125 (CA-125) level of 104 U/mL, and carcinoembryonic antigen (CEA) level of 1.09 ng/mL.

The patient was referred to Ghaem Hospital, Mashhad, Iran, for further assessment. At 17 weeks of gestation, the patient underwent exploratory laparotomy with left ovarian cystectomy. Intraoperative frozen section examination was independently reviewed by 2 experienced pathologists and showed remnants of an endometriotic ovarian cyst with malignant transformation composed of expanded confluent glands with squamous metaplasia and mild cytonuclear atypia without a solid component. Based on these findings, a provisional diagnosis of endometrioid adenocarcinoma stage IB was made.

After multidisciplinary team discussion and patient counseling, the decision was made to continue the pregnancy and initiate chemotherapy. The patient received 5 cycles of paclitaxel and carboplatin during pregnancy. At 37 weeks of gestation, she underwent cesarean delivery followed by hysterectomy, bilateral salpingo-oophorectomy, and bilateral pelvic lymphadenectomy. A healthy neonate weighing 3200 g was delivered with an Apgar score of 10.

Gross examination of the resected specimens showed that the left ovarian mass measured 9.5 × 7 × 5 cm and consisted of a

doi:10.22034/ijp.2026.2087506.3653

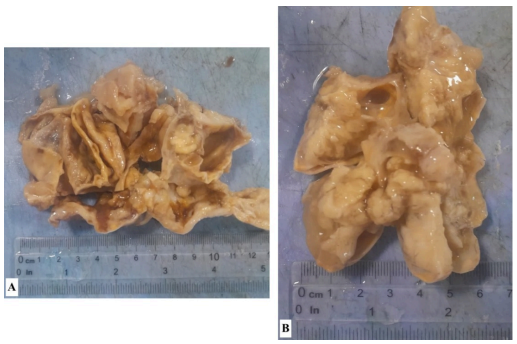

Fig 1. Gross examination of bilateral ovarian masses. (A) The left ovarian mass measuring 9.5 × 7 × 5 cm and showing a multicystic lesion with focal solid areas; the cysts contain brown to black fluid. (B) The right ovary measuring 5.5 × 4.5 × 1 cm and showing mixed solid and cystic areas containing yellow to brown fluid.

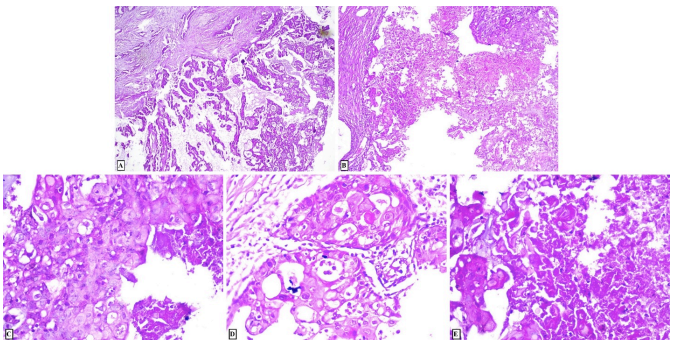

Fig 2. Low power (A, ×4; B, ×10): Sections show a predominantly glandular endometrioid proliferation with closely packed, back-to-back glands exhibiting complex architecture. The tumor is relatively well circumscribed, with minimal intervening stroma and focal cribriform areas. No significant solid growth is identified. High power (C-E, ×40): The glands are lined by columnar endometrioid cells with mild nuclear enlargement, stratification, and pleomorphism. Nuclei are relatively uniform with inconspicuous nucleoli. Mitotic figures are infrequent. Squamous differentiation and focal necrosis are present.

multicystic lesion with a few solid areas. The cystic areas were filled with brown to black fluid (Figure 1A). The right ovarian mass measured 5.5 × 4.5 × 1 cm and showed mixed solid and cystic areas filled with yellow to brown fluid (Figure 1B).

Microscopic examination of both ovarian masses showed confluent (back-to-back) glands lined by pseudostratified columnar epithelium with no intervening stroma, compatible with grade 1 endometrioid carcinoma (Figure 2). Coexisting multifocal endometriosis was also present.

In both ovaries, the ovarian surfaces were not involved, and the ovaries were intact. No lymphovascular invasion was found. Biopsies from the pelvic and bladder peritoneum, as well as from the mesentery of the small intestine and colon, were negative for malignancy. Examination of the uterine endometrium showed hemorrhagic and necrotic decidua, consistent with pregnancy-related changes. No evidence of malignancy, endometrial hyperplasia, or other precursor lesions was identified in the uterus.

Based on these findings, including bilateral ovarian involvement, intact ovarian capsules, no ovarian surface involvement, and no malignant cells in the peritoneal washings, a final diagnosis of endometrioid adenocarcinoma stage IB was confirmed.

Chemotherapy was continued for 1 additional cycle after delivery. During the first year of follow-up, the patient remained in remission and the infant showed normal growth and development.

DISCUSSION

Endometrioid carcinoma is a subtype of epithelial ovarian cancer and accounts for about 10% to 15% of ovarian malignancies (8). These tumors are composed of back-to-back glands lined by pseudostratified columnar epithelium with no intervening stroma, resembling endometrial endometrioid carcinoma (8).

Ovarian endometrioid carcinoma during pregnancy is uncommon and has been reported only in case reports or small case series (9–12). A systematic review of cases reported between 1955 and 2013 found that 10.5% of epithelial ovarian cancers during pregnancy were of the endometrioid subtype (6). A more recent review reported endometrioid adenocarcinoma in 5.4% of pregnant patients with ovarian cancer (13).

Our patient had bilateral ovarian endometrioid adenocarcinoma with synchronous endometriosis in both ovaries. Although ovarian endometrioid carcinoma during pregnancy has been reported previously, these cases did not have concomitant ovarian endometriosis (9–12). To our knowledge, only one previous case specifically reported a well-differentiated endometrioid adenocarcinoma with histologic signs of ovarian endometriosis during pregnancy, and that case was unilateral (14).

The management of ovarian cancers during pregnancy is challenging (11). There are limited data on the optimal treatment of this condition because it is rare (15). Treatment decisions depend on gestational age, histologic subtype, stage at diagnosis, and the patient's preferences (16, 17). A systematic review found that chemotherapy is safe in the second and third trimesters for gestational ovarian malignancies (13). Picone et al. recommended chemotherapy as a therapeutic option for epithelial ovarian cancer diagnosed during the second trimester (10). In our case, the decision to continue the pregnancy and use chemotherapy was based on published data and the patient's preference.

CONCLUSION

We present a rare case of bilateral endometrioid ovarian carcinoma coexisting with endometriosis during pregnancy. Although ovarian cancer is rare during pregnancy, it should be considered in the differential diagnosis of adnexal masses. In such cases, early evaluation and a multidisciplinary approach can improve outcomes for both mother and fetus.

Funding

This research received no specific grant from any funding agency in the public, commercial, or not-for-profit sectors.

Conflict of interest

The authors declare no conflict of interest.

Data Availability

The data that support the findings of this study are available from the corresponding author upon reasonable request.

Ethics Approval

Written informed consent was obtained from the patient for publication of this case report.

Acknowledgments

The authors are grateful to the Department of Pathology at Mashhad University of Medical Sciences and the clinicians who participated in the patient's care.

Declaration of AI Use

The authors declare that no generative AI or AI-assisted technologies were used in the writing process of this manuscript.

REFERENCES

1. Palmer J, Vatish M, Tidy J. Epithelial ovarian cancer in pregnancy: a review of the literature. BJOG. 2009;116(4):480-491. [DOI:10.1111/j.1471-0528.2008.02089.x] [PMID:19250360]
2. Jorgensen JR, Brewer MA, Runowicz CD. Ovarian cancer in pregnancy. Semin Perinatol. 2025;49(2):152043. [DOI:10.1016/j.semperi.2025.152043] [PMID:40089322]
3. Montes De Oca MK, Dotters-Katz SK, Kuller JA, Previs RA. Adnexal masses in pregnancy. Obstet Gynecol Surv. 2021;76(7):437-450. [DOI:10.1097/OGX.0000000000000909] [PMID:34324696]
4. Zhao XY, Huang HF, Lian LJ, Lang JH. Ovarian cancer in pregnancy: a clinicopathologic analysis of 22 cases and review of the literature. Int J Gynecol Cancer. 2006;16(1):8-15. [DOI:10.1136/ijgc-00009577-200601000-00002]
5. Kwon YS, Mok JE, Lim KT, Lee IH, Kim TJ, Lee KH, et al. Ovarian cancer during pregnancy: clinical and pregnancy outcome. J Korean Med Sci. 2010;25(2):230-234. [DOI:10.3346/jkms.2010.25.2.230] [PMCID:PMC2811289] [PMID:20119575]
6. Blake EA, Kodama M, Yunokawa M, Ross MS, Ueda Y, Grubbs BH, et al. Feto-maternal outcomes of pregnancy complicated by epithelial ovarian cancer: a systematic review of literature. Eur J Obstet Gynecol Reprod Biol. 2015;186:97-105. [DOI:10.1016/j.ejogrb.2015.01.010] [PMID:25668134]
7. Gasim T, Al Dakhiel SA, Al Ghamdi AA, Ali MA, Jama FA, Rahman J, et al. Ovarian tumors associated with pregnancy: a 20-year experience in a teaching hospital. Arch Gynecol Obstet. 2010;282(5):529-533. [DOI:10.1007/s00404-009-1346-z] [PMID:20049468]
8. Robinson KA, Menias CO, Chen L, Schiappacasse G, Shaaban AM, Caserta MP, et al. Understanding malignant transformation of endometriosis: imaging features with pathologic correlation. Abdom Radiol (NY). 2020;45(6):1762-1775. [DOI:10.1007/s00261-019-01914-7] [PMID:30941451]
9. Gottheil S, McGee J. Endometrioid ovarian carcinoma during pregnancy presenting with acute rupture. J Obstet Gynaecol Can. 2013;35(11):1020-1022. [DOI:10.1016/S1701-2163(15)30790-8] [PMID:24246402]
10. Picone O, Lhommé C, Tournaire M, Pautier P, Camatte S, Vacher-Lavenue MC, et al. Preservation of pregnancy in a patient with a stage IIIB ovarian epithelial carcinoma diagnosed at 22 weeks of gestation and treated with initial chemotherapy: case report and literature review. Gynecol Oncol. 2004;94(2):600-604. [DOI:10.1016/j.ygyno.2004.05.030] [PMID:15297214]
11. Chen CH, Chiu LH, Chan C, Liu WM. Management of ovarian cancer in 14th gestational week of pregnancy by robotic approach with preservation of the fetus. Gynecol Obstet Invest. 2015;80(2):139-144. [DOI:10.1159/000368231] [PMID:25871638]
12. Hasegawa T, Ishii Y, Yonezawa R, Yoneda N, Shima T, Nakashima A, et al. Stage I ovarian cancer cases during early, mid and late pregnancy periods: three case reports and review of the literature. J Obstet Gynaecol Res. 2011;37(6):650-655. [DOI:10.1111/j.1447-0756.2010.01412.x] [PMID:21159046]
13. Jiang X, Ye Z, Yu W, Fang Q, Jiang Y. Chemotherapy for ovarian cancer during pregnancy: a systematic review and meta-analysis of case reports and series. J Obstet Gynaecol Res. 2021;47(10):3425-3436. [DOI:10.1111/jog.14957] [PMID:34342108]
14. Zivanovic A, Dimitrijevic A, Kastratovic T, Djuric J, Stankovic V, Tanaskovic I. Ovarian endometroid adenocarcinoma in pregnancy. Vojnosanit Pregl. 2011;68(2):181-184. [DOI:10.2298/VSP1102181Z] [PMID:21452675]
15. Minig L, Otaño L, Diaz-Padilla I, Alvarez Gallego R, Patrono MG, Valero De Bernabé J. Therapeutic management of epithelial ovarian cancer during pregnancy. Clin Transl Oncol. 2013;15(4):259-264. [DOI:10.1007/s12094-012-0963-3] [PMID:23180347]
16. Korenaga TRK, Tewari KS. Gynecologic cancer in pregnancy. Gynecol Oncol. 2020;157(3):799-809. [DOI:10.1016/j.ygyno.2020.03.015] [PMCID:PMC7380448] [PMID:32268951]
17. Wang L, Huang S, Sheng X, Ren C, Wang Q, Yang L, et al. Malignant ovarian tumors during pregnancy: a multicenter retrospective analysis. Cancer Manag Res. 2020;12:10841-10848. [DOI:10.2147/CMAR.S271806] [PMCID:PMC7605603] [PMID:33149689]