Iran J Pathol. 2027;22(1):86–90 | ISSN 2345-3656 | MAIN SUBJECTS Microbiology

# Mycotic Abdominal Aortic Aneurysm Associated with Non-Typhoidal *Salmonella* Serogroup C: A Case Report

**Amin Dehghan**[1,2,3*], **Zohre Baseri**[2], **Safa Nourani**[4]

1. *Microbial Biotechnology Research Center, Iran University of Medical Sciences, Tehran, Iran*
2. *Department of Microbiology, School of Medicine, Iran University of Medical Sciences, Tehran, Iran*
3. *Ali Asghar Children's Hospital, School of Medicine, Iran University of Medical Sciences, Tehran, Iran*
4. *Department of Pathology, Sina Hospital, School of Medicine, Tehran University of Medical Sciences, Tehran, Iran*

RECEIVED 29 May 2026 ACCEPTED 26 Sep 2026 PUBLISHED ONLINE 15 Oct 2026 DOI 10.22034/ijp.2026.2088027.3665

## ABSTRACT

***Background & Objective:*** An abdominal aortic aneurysm (AAA) is a life-threatening condition whose irreparable consequences can be prevented with adequate management. In this study, a rare case of AAA associated with non-typhoidal *Salmonella* serogroup C is reported.

***Case Presentation:*** A 69-year-old male patient presented with constipation, low-grade fever, and right flank pain radiating to his right leg and was diagnosed with AAA by computed tomography angiography (CTA). The patient underwent aneurysm repair surgery. Aortic tissue and blood cultures both identified non-typhoidal *Salmonella* serogroup C. Histopathological examination confirmed the diagnosis of a mycotic aneurysm. The patient was treated with 3 weeks of intravenous ceftriaxone followed by 4 weeks of oral ciprofloxacin as suppressive therapy. At 6-month follow-up, clinical and laboratory assessments (WBC, CRP, ESR) remained within normal limits, and CTA showed no evidence of graft infection or aneurysm recurrence.

***Conclusions:*** Although a gastrointestinal source with transient bacteremia is biologically plausible, it could not be definitively confirmed in this case. Nevertheless, individuals with a history of *Salmonella* bacteremia and gastrointestinal infections should be given additional attention for the diagnosis of mycotic aneurysms. Furthermore, it should be considered that *Salmonella* can cause subclinical or asymptomatic gastrointestinal infections, leading to bacteremia and subsequent aneurysm formation. Diagnosis with CTA, appropriate antibiotic treatment, and choosing the correct aneurysm repair method according to the patient's condition play a key role in saving the patient's life.

**KEYWORDS** Abdominal aortic aneurysms, *Salmonella*, Computed tomography angiography, Surgery, Case report

**Corresponding Information:** Amin Dehghan, Microbial Biotechnology Research Center, Iran University of Medical Sciences, Tehran, Iran, Department of Microbiology, School of Medicine, Iran University of Medical Sciences, Tehran, Iran, Ali Asghar Children's Hospital, School of Medicine, Iran University of Medical Sciences, Tehran, Iran, amin_dehghan25@yahoo.com

*Copyright © 2027 The Author(s). This is an open-access article distributed under the terms of the CC BY 4.0, which permits unrestricted use, distribution, and reproduction in any medium, provided the original work is properly cited.*

## INTRODUCTION

Abdominal aortic aneurysm (AAA) is one of the life-threatening factors that can be prevented from its irreparable consequences if adequately managed. AAA causes the aorta to dilate abnormally; when its size exceeds 50 mm, the possibility of rupture increases significantly. An increase of more than 10 mm per year is also another risk factor for rupture (1).

Various risk factors for the development of abdominal aneurysms have been reported. Male gender, family history, high blood pressure, smoking, obesity, infection, and coronary artery disease have been reported as the main factors for its development (2–4).

Common complications of AAA include rupture, aorto-caval fistula, aorto-enteric fistula, and infection. Rupture is the most important complication of abdominal aneurysm and can be fatal if treatment efforts are not performed in time. Infection is one of the complications that causes inflammation and also plays a role in weakening the wall, ultimately causing rupture (4). Inside the aneurysm, blood clots may cause thrombosis and thus in the organs supplied by this vessel causing embolization and ischemia (5). With rapid diagnosis by computed tomography angiography (CTA) and timely treatment, the life-threatening risk factors of AAA can be managed (4).

To manage the developed problem according to the conditions of the patients, two main treatment methods are used. Open repair that requires surgery and therefore has anesthesia and a long treatment period. The endovascular aneurysm repair (EVAR) method, is used by considering the vascular anatomy of the patients and the correct selection for people who are old or have various heart, lung, and kidney disorders (6). In the case of mycotic aneurysms, the intervention procedure for repair is accompanied by antibiotic therapy (7). The criteria for AAA repair do not directly apply to mycotic aneurysms. This particular type certainly requires an intervention as soon as it is discovered, because of its aggressive nature and the risk of rupture (8).

Mycotic aortic aneurysm (AA) is rare but can be life-threatening (9). The most common organisms in mycotic aneurysms are *Staphylococcus* and *Salmonella* species (9, 10).

doi:10.22034/ijp.2026.2088027.3665

The digestive tract is the primary site of *Salmonella* infections (11). Infection can be due to bacteremia caused by gastrointestinal sources (10). Non-typhoidal *Salmonella* can cause this complication after bacteremia. The most common site of creation is the abdominal aorta and the probability of occurrence increases in atherosclerotic patients (12). Also, AA may rarely occur as a complication of sepsis, and therefore awareness in this field can help in diagnosis (9).

By infecting the aortic wall and causing inflammation, *Salmonella* weakens the vessel and leads to aneurysm formation. Therefore, because the signs and symptoms of mycotic aneurysm are non-specific, if not diagnosed and treated in time, it can cause aortic rupture (7).

In this study, a rare case of AAA related to non-typhoidal *Salmonella* is reported with the aim of contributing to knowledge in the field of mycotic aneurysms as a silent threat.

## CASE REPORT

The patient was a 69-year-old man with a history of controlled type 2 diabetes (T2D), and a history of thyroidectomy surgery. For 10 days before admission, he had experienced constipation and abdominal pain in the right flank, spreading to the right leg, and low-grade fever. He was referred to a medical center and hospitalized. During this period, the patient was treated with supportive measures, and improvement of symptoms was noted, the patient was discharged at his own request and recommendation of the attending physician to perform a computed tomography (CT) scan and magnetic resonance imaging (MRI). The patient's first set of admission records was unattainable, thus, information about the interventions carried out as well as the laboratory-scoped data during the episode was unavailable. According to the patient's recollection, blood and stool cultures were not performed during the initial admission of the patient. The patient was conservatively managed.

3 days after discharge, the symptoms started again. The patient's abdominal pain intensified. Therefore, the patient was referred to another hospital with the same but aggravated symptoms. The results of the initial tests of the patient upon arrival, were as follows: leukocytosis (21.88 × $10^9$ cells/L), increased CRP (115 mg/L), and ESR (29 mm/hour).

During the diagnostic workup, CTA revealed a saccular aneurysm measuring 43 mm on the right side of the infrarenal portion of the lower aorta, 23 mm caudal to the renal arteries, with mural thrombosis in the peripheral portion (Figure 1). The distal part of the aneurysm was located 30 mm from the aortic bifurcation. A tubal Dacron polyester graft was surgically implanted during the open surgical repair of the aortic aneurysm. This technique was utilized due to the lack of a necessity to deploy a bifurcated graft on account of the location and the size of the aneurysm. Debridement of the infected area of the aorta was performed alongside the complete removal of the necrotic tissues. Furthermore, an omental wrapping technique was used to support and strengthen the repair, thereby reducing the chance of postoperative infection.

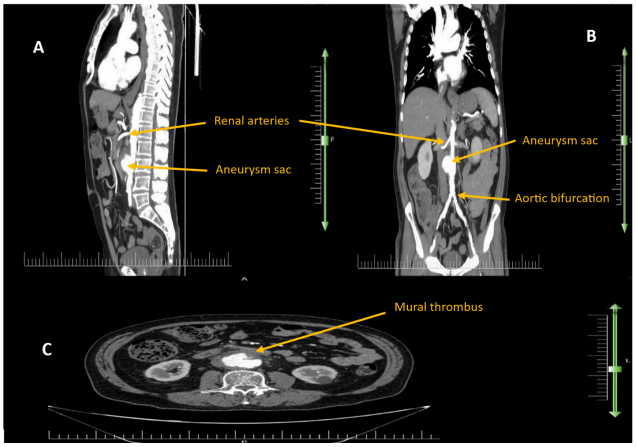


**Fig 1.** Computed tomography angiography (CTA) of the abdominal aorta. (A) Sagittal view confirms the saccular morphology of the aneurysm. (B) Coronal view demonstrates a saccular aneurysm measuring 43 mm on the right side of the infrarenal aorta, located approximately 23 mm caudal to the origin of the renal arteries. The distal extent of the aneurysm is approximately 30 mm proximal to the aortic bifurcation. (C) Axial view clearly shows the saccular aneurysm with a mural thrombus in the peripheral portion of the aneurysm sac.

The aortic tissue sample obtained during surgery was immediately inoculated onto blood agar, MacConkey agar, and thioglycolate broth to support the growth of both aerobic and anaerobic microorganisms. Blood agar and MacConkey agar plates were incubated at 37°C for 24–48 hours under aerobic conditions. Thioglycolate broth was incubated at 37°C for up to 7 days to detect any anaerobic or fastidious organisms. Following the observation of suspicious colonies on solid media, Gram staining was performed from the colonies, which revealed gram-negative bacilli. Subsequently, specific and differential biochemical tests were carried out for definitive identification, including Triple Sugar Iron (TSI) agar, urease, citrate utilization, lysine decarboxylase, indole production, motility, ONPG (β-galactosidase), oxidase, and MR-VP (Methyl Red-Voges Proskauer) tests. The results were consistent with *Salmonella* spp. (TSI: alkaline/acid with $H_2S$ production; urease: negative; citrate: positive; lysine decarboxylase: positive; indole: negative; motility: positive; ONPG: negative; oxidase: negative; MR: positive; VP: negative). Serogrouping was performed by slide agglutination using polyvalent and group-specific O antisera, identifying the isolate as serogroup C.

Blood cultures were collected upon admission to the second hospital, prior to the initiation of antibiotic therapy. Two sets of blood cultures were obtained and processed using the conventional manual method. Blood samples were inoculated into Tryptic Soy Broth (TSB) (Blood culture bottle) and incubated at 37°C for up to 7 days, with daily visual inspection for signs of growth. Subcultures were performed onto blood agar and MacConkey agar whenever growth was suspected or at the end of the incubation period. The blood culture results were positive and consistent with the aortic tissue culture, both identifying *Salmonella* serogroup C.

Antimicrobial susceptibility testing was performed using the disk diffusion (Kirby-Bauer) method, and the results were interpreted according to the Clinical and Laboratory Standards Institute (CLSI) M100 guidelines (36th edition, 2026). The isolate demonstrated susceptibility to ampicillin, trimethoprim-

sulfamethoxazole, ciprofloxacin, ceftriaxone, imipenem, and meropenem.

Stool culture was not performed in this patient, as there was no history of diarrheal illness or other gastrointestinal symptoms, and there was no clinical indication for stool culture at the time of presentation. This is acknowledged as a limitation of the study. Histopathological examination of the resected aortic tissue was performed on formalin-fixed, paraffin-embedded sections stained with hematoxylin and eosin (H&E). Gram staining was also performed on separate sections. Microscopic evaluation (×100, ×200, ×400) revealed transmural neutrophilic infiltrates, destruction and fragmentation of the medial elastic lamina, necrotic debris, and fibrinoid necrosis. Gram staining demonstrated numerous gram-negative bacilli within the necrotic debris and inflammatory exudate (×1000, oil immersion), confirming the diagnosis of a mycotic aneurysm. A limitation of this study is that histopathological images are not currently available, as they were not captured during the routine diagnostic workup. The patient history did not provide information suggestive of previous infection through *Salmonella* or episodes of unexplained fever or gastroenteritis result before this presentation.

At the beginning of hospitalization, the patient was on levothyroxine, empagliflozin, and metformin. Parenteral clindamycin 600 mg was administered every 8 hours, and parenteral cefepime 2 g was administered every 12 hours for the patient from the first day of hospitalization after blood cultures were collected. After the isolation and report of non-typhoidal *Salmonella* serogroup C from the microbial culture of the patient's tissue sample, the antibiotics clindamycin and cefepime were stopped and the treatment with ceftriaxone (2 g intravenous daily) was initiated on day 3 post-surgery (Day 20 from initial symptom onset), immediately after culture results became available. Follow-up blood cultures obtained at 1 week and 2 weeks post-surgery remained negative. Serial inflammatory marker assessments demonstrated normalization of CRP and WBC count by the end of week 2 (CRP: from 115 mg/L to 6 mg/L; WBC: from 21.88 × $10^9$ to 8.2 × $10^9$ cells/L). Transthoracic echocardiography was performed and revealed no evidence of valvular vegetations, consistent with the absence of infective endocarditis. The patient's antibiotic treatment was continued for three weeks provided there was no concurrent endocarditis. Following the completion of a 3-week course of intravenous ceftriaxone, the patient was discharged in good clinical condition with oral ciprofloxacin 500 mg twice daily for 4 weeks, and laboratory findings including white blood cell counts and CRP had returned to normal.

After the patient's discharge, he was monitored in the outpatient clinic for 6 months. Assessments through clinical and laboratory investigations (WBC, CRP, ESR) were done at one month, three months, and six months after discharge. The inflammatory marker results remained within normal limits across all investigations. CTA carried out after 6 months revealed no presence of graft infection, fluid collection around the graft, pseudo-aneurysm, or aneurysm. The patient remained asymptomatic without any sign of infection. The chronological sequence of key clinical events is summarized in Table 1.

**Table 1.** Clinical Timeline of the Case

| Day/Date | Event | Details |
|---|---|---|
| **Day 1** | Symptom Onset | Constipation, right flank pain radiating to right leg, low-grade fever |
| **Day 10** | First Hospital Admission | Supportive treatment initiated; no blood or stool cultures performed; patient discharged at his own request on Day 13 |
| **Day 13** | Discharge from First Hospital | Improvement of symptoms noted; advised to undergo CT/MRI |
| **Day 16** | Second Admission | Symptoms recurred with aggravated abdominal pain |
| **Day 16** | Diagnostic Workup | Laboratory tests: WBC 21.88 × $10^9$ cells/L, CRP 115 mg/L, ESR 29 mm/hr; CTA performed; blood cultures collected (prior to antibiotics) |
| **Day 16** | Antibiotics Initiated | Parenteral clindamycin 600 mg q8h and cefepime 2 g q12h started after blood cultures drawn |
| **Day 17** | Surgery | Open surgical repair with Dacron graft and omental wrapping; aortic tissue sample sent for culture |
| **Day 20** | Culture Results & Antibiotic Switch | Aortic tissue culture and blood cultures both identified non-typhoidal *Salmonella* serogroup C; antibiotics changed from clindamycin/cefepime to ceftriaxone (Day 3 post-surgery) |
| **Day 20–41** | Intravenous Antibiotic Therapy | Ceftriaxone 2 g IV daily for 3 weeks |
| **Day 24 (1 week post-op)** | Interim Monitoring | Follow-up blood cultures obtained; remained negative; clinical condition stable |
| **Day 31 (2 weeks post-op)** | Interim Monitoring | Repeat blood cultures negative; CRP normalized (from 115 mg/L to 6 mg/L) and WBC normalized (from 21.88 × $10^9$ to 8.2 × $10^9$ cells/L); transthoracic echocardiography performed with no evidence of valvular vegetations (endocarditis excluded) |
| **Day 41** | Discharge | Full recovery; normal WBC and CRP maintained; oral ciprofloxacin 500 mg twice daily started (for 4 weeks) as suppressive therapy; outpatient follow-up scheduled |
| **Day 41–69** | Oral Antibiotic Therapy | Ciprofloxacin 500 mg twice daily (4-week course) as suppressive therapy |
| **1 Month Post-discharge** | Follow-up Visit | Clinical exam and laboratory tests (WBC, CRP, ESR) – all within normal limits |
| **3 Months Post-discharge** | Follow-up Visit | Clinical exam and laboratory tests (WBC, CRP, ESR) – all within normal limits |
| **6 Months Post-discharge** | Follow-up Visit & CTA | Clinical exam and laboratory tests normal; CTA showed no evidence of graft infection, perigraft fluid, pseudoaneurysm, or aneurysm recurrence |

## DISCUSSION

Mycotic aneurysms are typically caused by systemic infections, immunosuppression, or bacteremia originating from the urinary or gastrointestinal tract (2, 9, 10). Bacterial infections are often responsible for mycotic aortic aneurysms, with *Staphylococcus* and *Salmonella* spp. being the leading pathogens. (9, 10). Mycotic AAA can rarely be caused by non-typhoidal *Salmonella*, and if not diagnosed in time and properly treated, it can cause vascular weakness and rupture (9). Due to the lack of typical manifestations of non-typhoidal *Salmonella* in mycotic AAA, diagnosis is difficult and always challenging (13). It was shown that because of not paying attention to the uncommon complications of *Salmonella* spp, the patient suffered from AAA during sepsis and then ruptured (9). Rapid diagnosis by CTA as well as timely combined treatment with antibiotics and aneurysm repair can help save the patient's life (4, 7). The patient history did not provide information suggestive of

previous infection through *Salmonella* or episodes of unexplained fever or gastroenteritis. *Salmonella* can cause subclinical or asymptomatic gastrointestinal infections in individuals. Therefore, in patients, the bacteria remain in the body and can enter the bloodstream and reach the aortic wall, causing mycotic AAA (14, 15). Although a gastrointestinal source with transient bacteremia is biologically plausible, it could not be definitively confirmed in this case because stool culture was not performed, and blood cultures from the initial presentation, when the patient might have had an unrecognized enteric infection, were unavailable. However, blood cultures obtained upon the second admission were positive for the same *Salmonella* serogroup C, supporting the occurrence of bacteremia. Therefore, even in patients who do not have symptoms or a history of infection, infectious agents should be clinically suspected as one of the reasons for AAA.

In the presented case, CTA of the abdominal aorta was conducted and a saccular aneurysm measuring 43 mm showed AAA. Fortunately, it was diagnosed at the right time and before more unfavorable results. The patient underwent aneurysm repair surgery. A tubal Dacron polyester graft was surgically implanted during the open surgical repair of the aortic aneurysm. Furthermore, an omental wrapping technique was used to support and strengthen the repair, thereby reducing the chance of postoperative infection. The result of microbial culture from aortic tissue was positive for non-typhoidal *Salmonella* serogroup C. Histopathological examination confirmed the diagnosis of a mycotic aneurysm. The limitation of this work was that the serotype classification of *Salmonella* was not determined. They are reported in the level of serogroup in the routine hospital laboratory (16). Always, there is a consideration between open repair and EVAR technique based on the patient's anatomy and other concurrent medical issues (6). Open repair sustains an advantage for mycotic aneurysms due to the need for infected tissue debridement (17). However, different surgical options exist and can be performed depending on the patient's medical state and institutional expertise. Extra-anatomic bypasses, such as axillo-femoral or femoral bypasses, can be used to relay blood flow near the infected place. Although this procedure reduces the risk of reinfection, it is less durable. However, it is often used for people with extensive infections (17, 18). In-situ repair with antibiotic-impregnated grafts is another option, which significantly reduces the risk of infection. This procedure uses direct repair, which can show good results with long-term antibiotic treatment (17, 19). Autogenous vein repair is a procedure in which femoral veins are used for reconstruction instead of using synthetic materials. Its advantages include high biocompatibility, high resistance to infection, and durability. This procedure is mostly used in young patients, as well as in patients who are allergic to prostheses (17, 18). Other biological options include homografts or bovine pericardium tissues. Homografts are obtained from human donors and are used when needed. Bovine pericardium tissues are another valuable option due to their high resistance to infection, easier access than homografts, and acceptable durability. However, the possibility of immune reactions must be considered (17, 19).

A minimum of 4–6 weeks of intravenous targeted therapy is important, and a longer duration is advised if infection persists or after a planned surgical assault is conducted (17). In this particular case, what was considered a compelling reason for operative intervention was the increased risk of rupture associated with the size and morphological characteristics of the aneurysm. In addition, the presence of infection necessitated surgical debridement, another point in favor of open repair. Although non-typhoidal *Salmonella* has a gastrointestinal source, the bacteremia helps the conditions to reach the abdominal aorta and cause mycotic AAA which can threaten the patient's life (9, 10, 12). After isolation of non-typhoidal *Salmonella* serogroup C, ceftriaxone treatment (2 g intravenous daily) was administered to the patient for three weeks (initiated on day 3 post-surgery). Although current guidelines generally recommend 4–6 weeks of intravenous antibiotics for mycotic aortic aneurysms, the duration was individualized based on several favorable factors. First, aggressive intraoperative debridement of all infected and necrotic tissue was performed, and the repair was reinforced with an omental wrap, which has been shown to reduce the risk of local infection recurrence. Second, the patient demonstrated a rapid and sustained clinical response, with normalization of inflammatory markers (CRP and WBC count) by the end of week 2, and no evidence of infective endocarditis on transthoracic echocardiography. Third, follow-up blood cultures remained negative throughout the hospitalization. This approach was based on our institutional experience and shared decision-making with the patient, taking into account his excellent clinical response and the aggressive surgical source control achieved. Given these factors, and in accordance with institutional experience and shared decision-making with the patient, a 3-week course of intravenous ceftriaxone was deemed sufficient, and the patient was subsequently discharged on oral ciprofloxacin 500 mg twice daily for an additional 4 weeks as suppressive therapy. This combined regimen (3 weeks intravenous + 4 weeks oral) provided a total of 7 weeks of anti-*Salmonella* coverage, with the oral component serving as consolidation/suppressive therapy following initial source control. However, we emphasize that this approach is not a general recommendation and may not be appropriate for patients with extensive infection or prosthetic material in a more contaminated field. The standard of care remains 4-6 weeks of intravenous antibiotics, and our approach should be interpreted with caution. Considering the improvement in his condition, the patient responded positively to the treatment, and the staff monitored the patient for the absence of endocarditis and the effectiveness of the treatment until discharged. Notably, it has been shown that resistance to ceftriaxone in non-typhoidal *Salmonella* is increasing, from 16.1% to 32% between 2011 to 2020 in Thailand, and this issue shows the importance of checking resistance in non-typhoidal *Salmonella* continuously (16).

In summary, AAA is rarely caused by infectious agents. Non-typhoidal *Salmonella* serogroup C can cause mycotic AAA and become life-threatening. Regarding the unusual appearance of non-typhoidal *Salmonella* infection in AAA, it is essential to consider it as one of the causative factors. Although a gastrointestinal source is plausible, it remains unconfirmed in this case. Individuals with a history of *Salmonella* bacteremia and gastrointestinal infections should be given additional attention for the diagnosis of mycotic aneurysms. Furthermore, *Salmonella* can cause subclinical or asymptomatic gastrointestinal infections, leading to bacteremia and subsequent aneurysm formation. Diagnosis with CTA, appropriate antibiotic treatment, and choosing the correct aneurysm repair method according to

the patient's condition play a key role in saving the patient's life. The intervening effort made alongside timely diagnosis can prevent deadly complications of aneurysm ruptures. Proper treatment and follow-up of the process are very effective in obtaining the patient's recovery for discharge and preventing further complications.

## ABBREVIATIONS

**AAA:** abdominal aortic aneurysm
**AA:** aortic aneurysm
**CTA:** computed tomography angiography
**CT:** computed tomography
**EVAR:** endovascular aneurysm repair
**T2D:** type 2 diabetes
**MRI:** magnetic resonance imaging

### Funding

This research did not receive any specific grant from funding agencies in public, commercial, or not-for-profit sectors.

### Conflict of interest

The authors declared no conflict of interest

### Data Availability

All data generated or analysed during this study are included in this published article.

### Ethics Approval

Written informed consent was obtained from the patient for publication of this case report and accompanying images. According to institutional policy, ethics committee approval was not required for this anonymized single case report.

### Authors' Contributions

AD: Writing – review & editing, Writing – original draft, Software, Project administration, Data curation, Conceptualization, Investigation. ZB: Writing – review & editing, Investigation, Data curation, Conceptualization. SN: Data curation, Investigation.

### Acknowledgments

Not applicable.

### Declaration of AI Use

The authors declare that no generative AI or AI-assisted technologies were used in the writing process of this manuscript.

## REFERENCES

1. Hallett RL, Ullery BW, Fleischmann D. Abdominal aortic aneurysms: pre- and post-procedural imaging. Abdom Radiol. 2018;43(5):1044-1066. [DOI:10.1007/s00261-018-1520-5] [PMID:29460048]
2. Altobelli E, Rapacchietta L, Profeta VF, Fagnano R. Risk Factors for Abdominal Aortic Aneurysm in Population-Based Studies: A Systematic Review and Meta-Analysis. Int J Environ Res Public Health. 2018;15(12). [DOI:10.20944/preprints201810.0636.v1]
3. Ullery BW, Hallett RL, Fleischmann D. Epidemiology and contemporary management of abdominal aortic aneurysms. Abdom Radiol. 2018;43(5):1032-1043. [DOI:10.1007/s00261-017-1450-7] [PMID:29313113]
4. Kumar Y, Hooda K, Li S, Goyal P, Gupta N, Adeb M. Abdominal aortic aneurysm: pictorial review of common appearances and complications. Ann Transl Med. 2017;5(12):256. [DOI:10.21037/atm.2017.04.32] [PMCID:PMC5497081] [PMID:28706924]
5. Manenti A, Farinetti A, Manco G, Mattioli AV. Intraluminal Thrombus and Abdominal Aortic Aneurysm Complications. Ann Vasc Surg. 2022;83:e11-e2. [DOI:10.1016/j.avsg.2022.03.007] [PMID:35398377]
6. Bryce Y, Rogoff P, Romanelli D, Reichle R. Endovascular repair of abdominal aortic aneurysms: vascular anatomy, device selection, procedure, and procedure-specific complications. Radiographics. 2015;35(2):593-615. [DOI:10.1148/rg.352140045] [PMID:25763741]
7. Cicconi V, Mannino S, Caminiti G, Cuoco L, Gasbarrini A, Vecchio F, et al. *Salmonella* aortic aneurysm: suggestions for diagnosis and therapy based on personal experience--a case report. Angiology. 2004;55(6):701-705. [DOI:10.1177/00033197040550i613] [PMID:15547658]
8. Khoo GGJ, Ong P, Wong JKW, Muhamad Yazid MAB, Chang CY. Mycotic Aneurysm in *Salmonella enteritidis* Infection: A Fatal Complication. Cureus. 2024;16(12):e75739. [DOI:10.7759/cureus.75739] [PMCID:PMC11731534] [PMID:39811204]
9. Napiórkowska-Baran K, Rosada T, Alska E, Wawrzeńczyk A, Bartuzi Z. Treatment of Ruptured Infected Abdominal Aortic Aneurysm Caused by *Salmonella* spp.: A Case Report. Infect Dis Ther. 2021;10(3):1799-1805. [DOI:10.1007/s40121-021-00492-w] [PMCID:PMC8322186] [PMID:34254250]
10. Coulter I, Virapongse A. Mycotic Aortic Aneurysm in a Patient with Prior Abdominal Aortic Aneurysm Endograft Repair. J Gen Intern Med. 2020;35(11):3372-3373. [DOI:10.1007/s11606-020-06044-1] [PMCID:PMC7661591] [PMID:32705475]
11. Azimi T, Nasser A, Shariati A, Shiadeh SMJ, Safari H, Alizade-Sani M, et al. The Possible Role of Pathogenic and Non-Pathogenic Bacteria in Initiation and Exacerbation of Celiac Disease; A Comprehensive Review. Curr Pharm Biotechnol. 2020;21(6):452-466. [DOI:10.2174/1389201021666191219160729] [PMID:31858910]
12. Sangiorgio M, Choo SZ, Gavaghan D, McDougall K. Case of non-typhoidal *Salmonella* spp mycotic popliteal artery aneurysm with concurrent deep vein thrombosis. BMJ Case Rep. 2023;16(8):e255052. [DOI:10.1136/bcr-2023-255052] [PMCID:PMC10432638] [PMID:37580098]
13. Moole H, Emani VK, Ramsahai S. Mycotic aneurysm in a turtle hunter: brief review and a case report. J Community Hosp Intern Med Perspect. 2015;5(3):27229. [DOI:10.3402/jchimp.v5.27229] [PMCID:PMC4475255] [PMID:26091653]
14. Lv J, Geng L, Ye W, Gong S, Wu J, Ju T, et al. Antimicrobial resistance and genetic relatedness of *Salmonella* serotypes isolated from food, asymptomatic carriers, and clinical cases in Shiyan, China. PLoS One. 2024;19(5):e0301388. [DOI:10.1371/journal.pone.0301388] [PMCID:PMC11081320] [PMID:38722868]
15. Xu H, Zhang W, Zhang K, Zhang Y, Wang Z, Zhang W, et al. Characterization of *Salmonella* serotypes prevalent in asymptomatic people and patients. BMC Infect Dis. 2021;21(1):632. [DOI:10.1186/s12879-021-06340-z] [PMCID:PMC8252320] [PMID:34210275]
16. Hengkrawit K, Tangjade C. Prevalence and Trends in Antimicrobial Susceptibility Patterns of Multi-Drug-Resistance Non-Typhoidal *Salmonella* in Central Thailand, 2012-2019. Infect Drug Resist. 2022;15:1305-1315. [DOI:10.2147/idr.s355213] [PMCID:PMC8976529] [PMID:35378891]
17. Heinola I, Sörelius K, Wyss TR, Eldrup N, Settembre N, Setacci C, et al. Open Repair of Mycotic Abdominal Aortic Aneurysms With Biological Grafts: An International Multicenter Study. J Am Heart Assoc. 2018;7(12). [DOI:10.1161/jaha.117.008104] [PMCID:PMC6220543] [PMID:29886419]
18. Lin R, He HP, Zhao Y, Lv JB, Peng JX, Yin HH. Outcomes Following Different Management of Mycotic Infrarenal Abdominal Aortic Aneurysms. J Endovasc Ther. 2024:15266028241253128.
19. Zhu C, Zhao J, Huang B, Yuan D, Yang Y, Wang T. Long-term outcome of endovascular aortic repair for mycotic abdominal aortic aneurysm. ANZ J Surg. 2020;90(7-8):1376-1380. [DOI:10.1111/ans.16122] [PMID:32648327]