Iran J Pathol. 2027;22(1):95–101 | ISSN 2345-3656 | MAIN SUBJECTS Oral Pathology

Fibrolipoma of the Oral Cavity: A Case Report and Review of the Literature

Shanmuha Priya S[1], **Pallavi Sabarad**[1*], **Sudeendra Prabhu**[1], **Riaz Abdulla**[1]

1. Department of Oral Pathology and Microbiology, Yenepoya Dental College, Yenepoya (Deemed to be University), Mangalore, Karnataka, India

RECEIVED 19 May 2026 ACCEPTED 12 Oct 2026 PUBLISHED ONLINE 15 Oct 2026 DOI 10.22034/ijp.2026.2087867.3659

ABSTRACT

Background: Lipomas are benign mesenchymal tumors composed of mature fat cells (adipocytes). Intraoral lipomas are rare, accounting for 2.4% of all benign oral cavity tumors, with the fibrolipoma subtype being particularly uncommon. This case report describes a case of intraoral fibrolipoma in the retromolar region, emphasizing its clinical presentation, histopathologic features, differential diagnosis, and management.

Case Presentation: A 42-year-old woman presented with a painless, gradually enlarging growth in the left lower retromolar region. Clinical examination revealed a solitary, sessile, lobulated lesion measuring 1.5 × 1.5 cm, firm in consistency, and nontender. A provisional diagnosis of fibroma was made. An excisional biopsy revealed lobules of mature adipocytes interspersed with dense collagen bands, confirming fibrolipoma. The lesion was surgically excised.

Conclusion: Intraoral fibrolipoma, though rare, should be considered in the differential diagnosis of oral soft tissue lesions. Histopathological evaluation remains the gold standard for accurate diagnosis, aiding in differentiation from malignant entities such as liposarcoma. Early recognition and treatment are essential to prevent functional complications and misdiagnosis.

KEYWORDS Adipocytes, Fibrolipoma, Liposarcoma, Mesenchymal tumors

Corresponding Information: Pallavi Sabarad, Department of Oral Pathology and Microbiology, Yenepoya Dental College, Yenepoya (Deemed to be University), Mangalore, Karnataka, India, drpallavisabarad@yenepoya.edu.in

Copyright © 2027 The Author(s). This is an open-access article distributed under the terms of the CC BY 4.0, which permits unrestricted use, distribution, and reproduction in any medium, provided the original work is properly cited.

INTRODUCTION

The term lipoma originates from the Greek words lipos (meaning fat) and oma (meaning tumor) (1). A lipoma is a benign mesenchymal tumor composed of mature fat cells (adipocytes) (2). It is the most common benign mesenchymal tumor. It accounts for approximately 4% to 5% of all benign tumors in the body and 2.4% of all benign tumors of the oral cavity. The trunk, shoulder, neck, and axilla are the most common sites involved (3). It is widely distributed in the body and is known as a universal or ubiquitous tumor. Its occurrence in the oral cavity is rare, with an incidence of approximately 1 in 5000 individuals (4). Buccal mucosa, tongue, floor of the mouth, buccal sulcus, palate, lips, and gingiva are the most common intraoral sites involved. In 1848, Roux was the first to describe intraoral lipoma, calling it “yellow epulis” (5).

Intraoral lipomas most commonly occur in the submucosal tissue. They are asymptomatic, slow-growing lesions that are soft in consistency, with a characteristic yellow color. They have no sex predilection and are commonly seen in the fourth and fifth decades of life. Despite its benign nature, lipomas can interfere with speech and mastication because of their progressive growth and size (6). Based on histologic characteristics, several subtypes of intraoral lipomas have been described. One of the rare histologic variants is fibrolipoma, in which lobules of fat cells are embedded in dense fibrous collagen (7).

This report describes a case of intraoral fibrolipoma clinically mimicking fibroma and discusses its clinical and histopathologic features, differential diagnosis, and management.

CASE PRESENTATION

A 42-year-old woman presented to the outpatient department of our institution with a growth in the left lower posterior jaw region of 3 months’ duration. The growth was asymptomatic and had gradually increased in size. There was no relevant medical history, and the patient reported no deleterious habits. There was a history of denture wear for the past 5 years. On general examination, the patient was well nourished, and vital signs were normal. The extraoral examination revealed no significant findings. On intraoral examination, a solitary, sessile, exophytic growth measuring 1.5 × 1.5 cm was noted in the left lower retromolar region (Figure 1). The surface of the lesion was smooth, lobulated, and normal in color. On palpation, the lesion was nontender, firm, and freely mobile. Based on these findings, a provisional diagnosis of fibroma was considered. The lesion was surgically excised, and the specimen was sent for histopathological evaluation to confirm the diagnosis.

Grossly, the specimen was firm in consistency, oval in shape with a smooth surface, and grayish white in color, and it measured approximately 1.5 × 1.5 cm. Gross examination of the excised specimen revealed a soft tissue mass with a yellowish hue on the cut surface. Microscopic examination of the specimen showed a well-circumscribed lesion lined by keratinized stratified squamous epithelium with a densely collagenous connective tissue stroma (original magnification ×4). The connective tissue stroma showed lobules of mature fat cells interspersed by bands of dense fibrous connective tissue

doi:10.22034/ijp.2026.2087867.3659



Fig 1. Solitary sessile growth in the left retromolar region

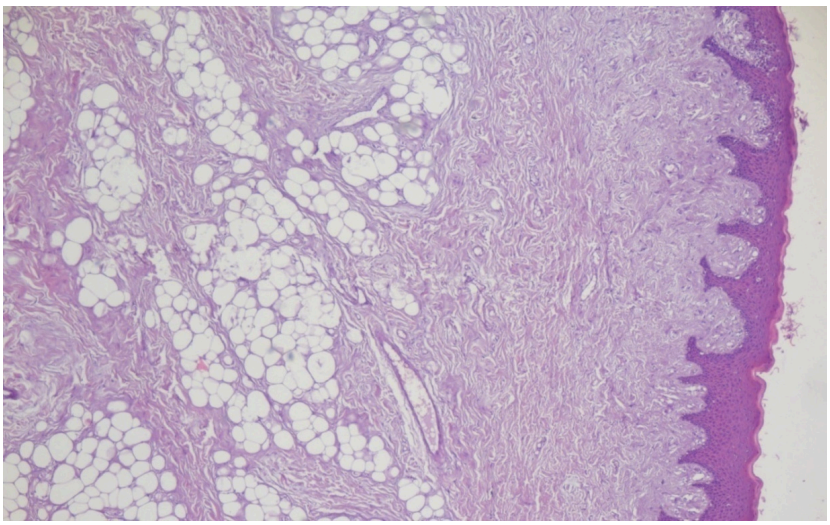

Fig 2. Keratinized stratified squamous epithelium with lobules of mature adipocytes interspersed with dense fibrous tissue (hematoxylin-eosin, original magnification ×4)

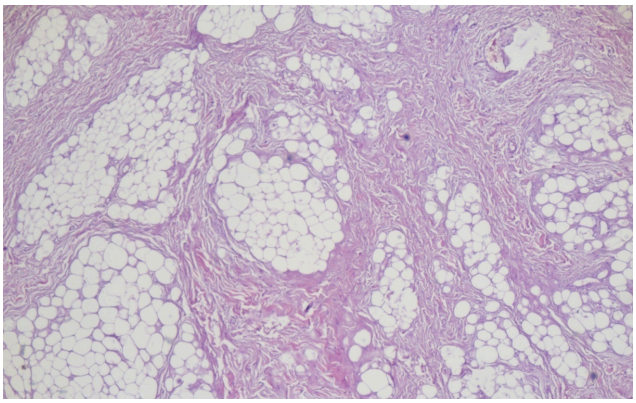

Fig 3. Lobules of mature adipose tissue interspersed with dense bands of fibrous connective tissue (hematoxylin-eosin, original magnification ×10)

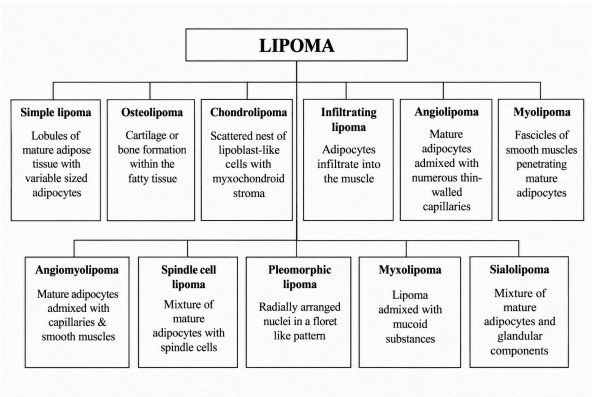

Fig 4. Histological subtypes of lipoma with key distinguishing features

(Figures 2 and 3). Lipoblasts were absent. There was no evidence of cellular atypia, mitosis, necrosis, or an infiltrative growth pattern. Mild inflammatory cell infiltration, blood vessels, and extravasated red blood cells were also seen. The surgical margins were free of the lesion.

Based on the clinical presentation and characteristic histopathological findings, a final diagnosis of fibrolipoma was established. Immunohistochemical analysis was not performed, as the histopathological features were sufficiently diagnostic. The patient was followed up for 1 year, during which no evidence of recurrence was observed.

This case report was prepared in accordance with the CARE (CAse REport) guidelines.

DISCUSSION

Lipomas are benign, slow growing tumors composed of mature adipocytes (8, 9). Based on histologic features, the World Health Organization (WHO) classifies lipomas as follows: conventional lipoma, fibrolipoma, myxolipoma, chondrolipoma, osteolipoma, angiolipoma, spindle cell/pleomorphic lipoma, lipomatosis, lipomatosis of nerve, lipoblastoma, and hibernoma (10).

Fibrolipoma is a rare histologic variant. The mean age at occurrence is 49 years, with a slight female predominance. Fibrolipomas are soft to firm in consistency (11). The most common site is the buccal mucosa, followed by the tongue, lips, buccal sulcus, floor of the mouth, palate, and retromolar area (12). The esophagus, colon, pharynx, trachea, and larynx are the most common extraoral sites involved (12). In the present case, the fibrolipoma in a 42-year-old woman involved the retromolar area and was firm in consistency.

Diagnosis of intraoral lipoma is made clinically by inspection and palpation. Clinically, fibrolipoma can mimic fibroma, as both lesions commonly present as slow-growing, painless, well-circumscribed nodular swellings covered by normal mucosa (13). In the present case, the lesion clinically resembled fibroma because of its sessile appearance and history of chronic local irritation associated with denture wear. Although the exact pathogenesis of oral fibrolipoma remains unclear, chronic mechanical irritation from an ill-fitting denture has been suggested as a possible contributing factor. Repeated microtrauma may induce persistent low-grade inflammation, leading to the release of growth factors and cytokines that stimulate fibroblast proliferation, collagen deposition, and adipocyte differentiation or proliferation. These reactive changes may promote the development of a fibrolipoma, characterized histologically by mature adipocytes interspersed within dense fibrous connective tissue. However, the association between chronic denture irritation and fibrolipoma remains speculative,

Table 1. Fibrolipoma cases retrieved from the institutional archives, 1999 to 2025

Year	Age/Sex	Location	Type of lesion	Provisional diagnosis	Histopathologic features	Final diagnosis
Present Case 2025	42/F	Retromolar region	Growth	Fibroma	Lobules of mature adipose tissue separated by dense bands of fibrous connective tissue	Fibrolipoma
2023	46/F	Dorsum of tongue	Growth	Fibroma	Presence of mature adipocytes within dense collagen fibers.	Fibrolipoma
2010	56/F	Left buccal mucosa	Growth	Fibroma	Fat cells admixed with dense collagenous stroma.	Fibrolipoma
2008	60/M	Left buccal mucosa	Swelling	Fibroma	Mature adipocytes with fibrous stroma.	Fibrolipoma
2004	48/M	Left buccal mucosa	Pedunculated lesion	Fibroma	Lobules of fat cells in a fibrous stroma.	Fibrolipoma
1999	40/F	Left buccal mucosa	Pedunculated growth	Fibroma	Fibrous tissue intermixed with lobules of fat cells.	Fibrolipoma

and further studies are needed to establish a definitive causal relationship. Histopathology remains the gold standard for the diagnosis of lipoma. Histologically, fibrolipoma is composed of lobules of mature adipocytes intermixed with broad bands of dense collagen, giving a "chicken wire" appearance. It is often well circumscribed and thinly encapsulated. The adipocytes are uniform in size and shape, with peripherally placed nuclei and clear cytoplasm. The fibrous component consists of varying amounts of collagenized connective tissue interspersed among the adipose tissue. Cellular atypia, mitotic figures, and necrosis are absent, supporting its benign nature (14). These features correlated with those of the present case, confirming the diagnosis of fibrolipoma.

The histopathologic differential diagnosis of fibrolipoma includes liposarcoma, lymphangioma, pyogenic granuloma, and schwannoma. Although liposarcoma is a rare occurrence in the oral cavity, distinguishing it from fibrolipoma on clinical grounds alone can be challenging. Hence, careful histological examination is required to rule out malignancy (15). Histologic subtypes of lipoma and their distinguishing features are summarized in Figure 4.

Surgical excision is the treatment of choice for all types of lipoma, including fibrolipoma. Recurrence of intraoral lipoma is rare, but extraoral lipomas have a higher recurrence rate. Rarely, intraoral intramuscular lipomas recur after complete excision (16).

Cases from the archives of the Department of Oral Pathology and Microbiology at our institute from 1999 to 2025 were retrieved and analyzed (Table 1). A total of six cases were found including the present case. Of the six cases, four involved the buccal mucosa, and four occurred in female patients. Clinically, the lesions presented as slow-growing soft-tissue masses. Histopathologically, all cases exhibited similar features, characterized by lobules of mature adipocytes interspersed with dense collagenous connective tissue and an absence of cellular atypia.

A review of previously reported cases of intraoral fibrolipoma was also performed. Table 2 presents a detailed review of the literature on fibrolipoma from 1954 to 2025. To the best of our knowledge, a total of 65 cases, including the present case, have been reported to date.

CONCLUSION

Intraoral fibrolipoma is a rare histological variant of lipoma. Fibrolipoma typically presents as a slow-growing, asymptomatic tumor, but it may occasionally infiltrate adjacent tissues, mimicking liposarcoma. Histopathological examination remains the gold standard for the diagnosis of lipoma. Malignant transformation of intraoral fibrolipoma is extremely rare. Although rare, recognition of this tumor is important to avoid misdiagnosis and ensure appropriate management.

Funding

No external funding was received for this case report.

Conflict of interest

The authors declare no conflict of interest.

Data Availability

The data that support the findings of this study are available from the corresponding author upon reasonable request.

Ethics Approval

Written informed consent was obtained from the patient for publication of the case report and accompanying images. Institutional ethics approval was waived by the Yenepoya Ethics Committee 1, operating under Yenepoya (Deemed To Be University), in accordance with institutional policy for single-case reports.

Authors' Contributions

All authors have read and agreed to the published version of the manuscript.

Acknowledgments

The authors sincerely thank the Department of Oral Pathology and Microbiology, Yenepoya Dental College, for its support in the diagnosis and management of the case.

Declaration of AI Use

The authors declare that no generative AI or AI-assisted technologies were used in the writing process of this manuscript.

REFERENCES

1. Vinod SV, George A, Thomas N, Paulose DE, Joy A. Oral lipoma: report of two cases with different clinical appearance and review. IOSR J Dent Med Sci. 2016;15(3):120-124.
2. Ghanchi M, Bhakar V, Saxena K, Jani D. Fibrolipoma of the oral mucosa: a review of literature. Sch J Dent Sci. 2016;3(9):269-271.
3. Bataineh AB, Mansour MJ, Abalkhail A. Oral infiltrating lipomas. Br J Oral Maxillofac Surg. 1996;34(6):520-523. [DOI:10.1016/s0266-4356(96)90249-1] [PMID:8971447]
4. Rao GS, Chatra L, Shenai P. Intra-oral lipoma: a rare entity. Int J Anat Radiol Surg. 2013;2(2):1-3.

doi:10.22034/ijp.2026.2087867.3659

Table 2. Review of the literature on intraoral fibrolipoma cases from 1954 to 2025

Author/Year	No. of cases	Age/Sex	Site	Size	Treatment	Follow-up with no evidence of recurrence
Bruce and Royer/1954 (17)	2	43/M 44/M	Left buccal mucosa Buccal gingiva	2 cm 1 cm	Surgical excision Surgical excision	6 months 2 years
Vazirani and DeVore/1958 (18)	1	42/F	Left buccal mucosa	2.5×1.5×1 cm	Surgical excision	3 years
Blake and Blake/1959 (19)	1	50/F	Floor of the mouth	NA	Surgical excision	NA
Marfino/1959 (20)	1	35/F	Gingiva	NA	Surgical excision	NA
MacGregor and Dyson/1966 (21)	5	58/F 58/F 55/M 68/F 57/M	Floor of the mouth Left buccal sulcus Gingiva Lower lip Right buccal sulcus	NA	Surgical excision	NA
Panders et al/1967 (22)	5	71/F 61/F 66/F 60/M 53/F	Right cheek Left buccal sulcus Right buccal sulcus Right buccal sulcus Floor of the mouth	NA	Surgical excision	NA
Horton/1968 (23)	1	45/M	Tongue	5 mm	Surgical excision	1 year
Kiehl/1980 (24)	1	65/F	Alveolar mucosa	15 mm	Surgical excision	1 year
Gallagher et al/1982 (25)	1	9/M	Right buccal mucosa	5×3×2.3 cm	Surgical excision	NA
de Visscher/1982 (26)	8	45/M 75/F 43/M 11/F 68/F 57/F 41/M 63/M	Buccal sulcus Floor of the mouth Buccal sulcus Tongue Retromolar area Buccal sulcus Tongue Upper lip	10 mm 30 mm 5 mm 10 mm 15 mm 25 mm 20 mm 10 mm	Surgical excision	NA
Dattilo et al/1996 (27)	1	44/M	Tongue	NA	Surgical excision	NA
Biswas and Kundu/2004 (28)	1	50/F	Right buccal vestibule	5 cm	Surgical excision	NA
Bandéca et al/2007 (29)	1	42/M	Lower lip	5 cm	Surgical excision	60 months
Capodiferro et al/2008 (30)	1	43/M	Lower lip	NA	Surgical excision	10 months
Manjunatha et al/2010 (31)	3	75/M 55/M 70/M	Right buccal mucosa Right buccal mucosa Soft palate	3 cm 1 cm 1.5 cm	Surgical excision	6 months 6 months 6 months
Studart-Soares et al/2010 (32)	4	53/F 57/F 45/F 42/M	Buccal mucosa Gingiva Buccal mucosa Buccal mucosa	1.5 cm 1 cm 1 cm 2 cm	Surgical excision	60 months 48 months 86 months 18 months
Kumaraswamy et al/2010 (33)	1	30/M	Right buccal mucosa	0.5×0.5 cm	Surgical excision	NA
Khubchandani et al/2012 (6)	1	10/F	Left buccal mucosa	2.5×3 cm	Surgical excision	1 year
Shi et al/2013 (34)	1	6 mo/M	Dorsum of tongue	1.5×4 cm	Surgical excision	NA
Pereira et al/2014 (35)	1	35/F	Lingual to left third molar	1.5×2 cm	Surgical excision	6 months
Iaconetta et al/2015 (7)	1	71/F	Ventral surface of tongue	4 mm	Surgical excision	NA
Naruse et al/2015 (36)	2	76/F 70/M	Floor of the mouth Palate	3 cm 1.5 cm	Surgical excision	NA NA
Amale et al/2015 (37)	2	19/F 41/M	Right buccal mucosa Pterygomandibular raphe	4×3 cm 2×2 cm	Surgical excision	6 months 4 months
Iwase et al/2016 (38)	1	71/M	Left buccal mucosa	25×15 mm	Surgical excision	6 months
Devi et al/2017 (39)	1	50/F	Left retromolar region	1.5×1 cm	Surgical excision	5 years

Author/Year	No. of cases	Age/Sex	Site	Size	Treatment	Follow-up with no evidence of recurrence
Phulari et al/2018 (40)	2	16/F 60/M	Left retromolar region Maxillary right edentulous area	2×2 cm 1.8×0.9 cm	Surgical excision	NA NA
Hayashi et al/2020 (41)	1	85/F	Hard palate	16×14×9 mm	Surgical excision	18 months
Kamil et al/2020 (42)	1	68/M	Right buccal vestibule	7×5 cm	Surgical excision	6 months
Salih et al/2021 (43)	1	53/F	Tongue	2×2 cm	Surgical excision	2 months
Mansoor et al/2022 (44)	1	18/F	Dorsum of tongue	3×3 cm	Surgical excision	NA
Shah et al/2022 (45)	1	42/F	Maxillary alveolus	2×2 cm	Surgical excision	1 year
Nagar et al/2022 (46)	1	36/F	Tongue	1.4×1.2 cm	Surgical excision	NA
Rezazadeh et al/2022 (47)	1	26/F	Gingiva	1.5×1×0.7 cm	Surgical excision	3 months
Nunes et al/2023 (48)	1	71/F	Right buccal mucosa	2×2 cm	Surgical excision	6 months
Zouaghi et al/2023 (49)	1	49/M	Buccal mucosa	2 cm	Surgical excision	Under follow-up
Shah et al/2023 (50)	1	84/F	Floor of the mouth	2 cm	Surgical excision	6 months
Keerthana and Angadi/2023 (51)	1	29/M	Left buccal mucosa	2×1 cm	Surgical excision	Under follow-up
Tandon et al/2023 (52)	1	44/M	Gingiva	0.5×0.5 cm	Surgical excision	NA
Torsakul et al/2024 (53)	1	4/F	Gingiva	6×2×2 mm	Surgical excision	Recurrence noted at 16-month follow-up
Wang et al/2024 (54)	1	54/F	Lower lip	2×2.5×1 cm	Surgical excision	6 months
Present Case	1	42/F	Left lower retromolar region	1.5×1.5 cm	Surgical excision	1 year

Abbreviations: F, female; M, male; NA, not available.

5. Manjunatha BS, Pateel GD, Shah V. Oral fibrolipoma—a rare histological entity: report of 3 cases and review of literature. J Dent (Tehran). 2010;7(4):226.
6. Khubchandani M, Thosar NR, Bahadure RN, Baliga MS, Gaikwad RN. Fibrolipoma of buccal mucosa. Contemp Clin Dent. 2012;3(Suppl 1):S112-S114. [DOI:10.4103/0976-237X.95119] [PMCID:PMC3354812] [PMID:22629049]
7. Iaconetta G, Friscia M, Cecere A, Romano A, Orabona GD, Califano L. Rare fibrolipoma of the tongue: a case report. Journal of medical case reports. 2015;9(1):177. [DOI:10.1186/s13256-015-0653-1] [PMCID:PMC4546142] [PMID:26293242]
8. Neville BW, Damm DD, Allen CM, Bouquot JE. Soft tissue tumors. Oral and maxillofacial pathology. 2009:521-523.
9. Girish KL, Joseph TI, Sathyan P, Akhil S. Oral fibrolipoma: a rare histological variant. Oral Maxillofac Pathol J. 2017;8(1):56-9.
10. Jotdar A, Soni A, Paswan V, Singh A. Pedunculated Origin of Intraoral Fibrolipoma–Report of A Rare Case and Systematic Quantitative Literature Review. Egyptian Journal of Ear, Nose, Throat and Allied Sciences. 2024;25(25):1-7. [DOI:10.21608/ejentas.2024.169210.1570]
11. Gujjari SK, Shah M, Hegde U, Doddawad VG. Fibrolipoma: report of two intraoral cases. J Clin Diagn Res. 2012;6(3):524-526.
12. Mishra R, Bhasin N, Sahu A, Ghate S. Oral fibrolipoma: a rare presentation case report and review of literature. J Adv Med Med Res. 2017;23(10):1-5. [DOI:10.9734/JAMMR/2017/35854]
13. Naik R, Nithin K, Mujib AB, Kumar RK. Fibrolipoma of buccal mucosa: a rare entity. J Adv Med Dent Sci Res. 2015;3(2):97.
14. Chavan S, Ingle Y, Deshmukh R, Kulkarni VV. Fibrolipoma—a rare intraoral tumor: a case report. J Dent Allied Sci. 2013;2(2):83. [DOI:10.4103/2277-4696.159294]
15. Bancroft LW, Kransdorf MJ, Peterson JJ, O'Connor MI. Benign fatty tumors: classification, clinical course, imaging appearance, and treatment. Skeletal Radiol. 2006;35:719-733. [DOI:10.1007/s00256-006-0189-y] [PMID:16927086]
16. Santos AM, Mendonça KV, Araújo JC, Barbosa JA, Santana SF, Lima AV, et al. Histopathological aspects of oral cavity fibrolipoma: a case report. Histopathological aspects of oral cavity fibrolipoma: a case report. Oral Surg Oral Med Oral Pathol Oral Radiol. 2020;130(3):e209. [DOI:10.1016/j.oooo.2020.04.469]
17. Bruce KW, Royer RQ. Lipoma of the oral cavity: report of three cases. Lipoma of the oral cavity: report of three cases. Oral Surg Oral Med Oral Pathol. 1954;7(9):930-938. [DOI:10.1016/0030-4220(54)90290-X] [PMID:13194297]
18. Vazirani SJ, DeVore DT. Fibrolipoma of the oral cavity: report of a case. Fibrolipoma of the oral cavity: report of a case. Oral Surg Oral Med Oral Pathol. 1958;11(4):355-358. [DOI:10.1016/0030-4220(58)90071-9] [PMID:13553282]
19. Blake H, Blake FS. Lipoma in the floor of the mouth: report of a case. Lipoma in the floor of the mouth: report of a case. Oral Surg Oral Med Oral Pathol. 1959;12(12):1436-1438. [DOI:10.1016/0030-4220(59)90263-4] [PMID:13801259]

20. Marfino NR. Developing fibrolipoma of the free gingiva. Developing fibrolipoma of the free gingiva. Oral Surg Oral Med Oral Pathol. 1959;12(4):489-492. [DOI:10.1016/0030-4220(59)90060-X] [PMID:13644909]

21. MacGregor AJ, Dyson DP. Oral lipoma: a review of the literature and report of twelve new cases. Oral lipoma: a review of the literature and report of twelve new cases. Oral Surg Oral Med Oral Pathol. 1966;21(6):770-777. [DOI:10.1016/0030-4220(66)90100-9] [PMID:5219667]

22. Panders AK, Scherpenisse LA. Oral lipoma. British Journal of Oral Surgery. 1967;5(1):33-41. [DOI:10.1016/S0007-117X(67)80051-9] [PMID:5231475]

23. Horton JE. Lipomas of the tongue: report of a fibrolipoma. Lipomas of the tongue: report of a fibrolipoma. Oral Surg Oral Med Oral Pathol. 1968;25(6):914-918. [DOI:10.1016/0030-4220(68)90170-9] [PMID:5239745]

24. Kiehl R L. Oral fibrolipoma beneath complete mandibular denture. J Am Dent Assoc. 1980;100(4):561-562. [DOI:10.14219/jada.archive.1980.0139] [PMID:6928897]

25. Gallagher DM, Goldman E, Schaffer SD. Fibrolipoma of the cheek in a child. J Oral Maxillofac Surg. 1982;40(12):824-826. [DOI:10.1016/0278-2391(82)90184-7] [PMID:6958847]

26. de Visscher JG. Lipomas and fibrolipomas of the oral cavity. J Maxillofac Surg. 1982;10(3):177-181. [DOI:10.1016/S0301-0503(82)80036-2] [PMID:6957523]

27. Dattilo DJ, Ige JT, Nwana EJ. Intraoral lipoma of the tongue and submandibular space: report of a case. J Oral Maxillofac Surg. 1996;54(7):915-917. [DOI:10.1016/S0278-2391(96)90549-2] [PMID:8676242]

28. Biswas S, Kundu IN. Giant fibrolipoma of the oral cavity. Indian J Otolaryngol Head Neck Surg. 2004;56(2):118. [DOI:10.1007/BF02974311] [PMCID:PMC3451317] [PMID:23120046]

29. Bandéca MC, De Pádua JM, Nadalin MR, Ozório JE, Silva-Sousa YT, Perez DE. Oral soft tissue lipomas: a case series. Journal of the Canadian Dental Association. 2007;73(5):431.

30. Capodiferro S, Maiorano E, Scarpelli F, Favia G. Fibrolipoma of the lip treated by diode laser surgery: a case report. J Med Case Rep. 2008;2:301. [DOI:10.1186/1752-1947-2-301] [PMCID:PMC2547114] [PMID:18789134]

31. Manjunatha BS, Pateel GD, Shah V. Oral fibrolipoma-a rare histological entity: report of 3 cases and review of literature. Journal of Dentistry (Tehran, Iran). 2010 Sep 30;7(4):226. https://pmc.ncbi.nlm.nih.gov/articles// [PMCID:PMC3184759]

32. Studart-Soares EC, Costa FW, Sousa FB, Alves AP, Osterne RL. Oral lipomas in a Brazilian population: a 10-year study and analysis of 450 cases reported in the literature. Medicina Oral, Patologia Oral y Cirugia Bucal. 2010;15(5):691-696. [DOI:10.4317/medoral.15.e691] [PMID:20383107]

33. Kumaraswamy SV, Madan N, Keerthi R, Shakti S. Lipomas of oral cavity: case reports with review of literature. Lipomas of oral cavity: case reports with review of literature. Journal of maxillofacial and oral surgery. 2009;8(4):394-397. [DOI:10.1007/s12663-009-0096-6] [PMCID:PMC3454095] [PMID:23139554]

34. Shi J, Zhang J, Ding M, Cao Q. Lower lip cleft, bifid tongue and fibrolipoma: a case report of rare congenital anomaly. Br J Oral Maxillofac Surg. 2014;52(7):36-38. [DOI:10.1016/j.bjoms.2014.04.003] [PMID:24834810]

35. Pereira T, Shetty S, Sapdhare S, Tamgadge A. Oral fibrolipoma: a rare histological variant. Indian J Dent Res. 2014;25(5):672-674. [DOI:10.4103/0970-9290.147123] [PMID:25511072]

36. Naruse T, Yanamoto S, Yamada SI, Rokutanda S, Kawakita A, Takahashi H, et al. Lipomas of the oral cavity: clinicopathological and immunohistochemical study of 24 cases and review of the literature. Indian J Otolaryngol Head Neck Surg. 2015;67. [DOI:10.1007/s12070-014-0765-8] [PMCID:PMC4298617] [PMID:25621257]

37. Amale KA, Chaudhari NT, Bafna SS, Umarji HR. Fibrolipoma: a rare entity—case series. J Indian Acad Oral Med Radiol. 2015;27(4):588-592. [DOI:10.4103/0972-1363.188769]

38. Iwase M, Saida N, Tanaka Y. Fibrolipoma of the buccal mucosa: a case report and review of the literature. Case Rep Pathol. 2016;2016:5060964. [DOI:10.1155/2016/5060964] [PMCID:PMC4739214] [PMID:26885425]

39. Devi AN, Sowbhagya MB, Balaji P, Kumar TM. An uncommon case of fibrolipoma. Indian J Dent Res. 2017;28(6):699-701. [DOI:10.4103/ijdr.IJDR_718_16] [PMID:29256473]

40. Phulari RG, Soni V, Talegaon TP, Bakutra G. Oral fibrolipoma: a report of two cases and review of literature. Indian J Dent Res. 2018;29(4):513-516. [DOI:10.4103/ijdr.IJDR_730_16] [PMID:30127204]

41. Hayashi K, Yamada S, Onda T, Shibahara T. A case of fibrolipoma of the hard palate. Bull Tokyo Dent Coll. 2020;61(1):53-60. [DOI:10.2209/tdcpublication.2019-0010] [PMID:32074588]

42. Kamil WN, Zainal M, Omar AF, Jamaluddin TI, Ahmad MS. Speech and mastication difficulties following treatment by a "street dentist": a case of oral lipoma. Spec Care Dentist. 2021;41(1):129-134. [DOI:10.1111/scd.12536] [PMID:33128415]

43. Salih AM, Abdullah AM, Fatah ML, Abdulla BA, Mohammed SH. Fibrolipoma of the tongue: a case report with literature review. Ann Med Surg (Lond). 2021;72:102985. [DOI:10.1016/j.amsu.2021.102985] [PMCID:PMC8637185] [PMID:34888039]

44. Mansoor S, Yaqoob N, Haneef A, Sham S, Arain AA. Fibrolipoma of tongue: a rare entity. J Coll Physicians Surg Pak. 2022;32(6):814-816. [DOI:10.29271/jcpsp.2022.06.814] [PMID:35686419]

45. SHAH SN, JAIN GS, Patel U, Shah A. Oral Fibrolipoma Arising from Maxillary Alveolus: A Rare Case Entity. Journal of Clinical & Diagnostic Research. 2022;16(8). [DOI:10.7860/jcdr/2022/58028.16797]

46. Nagar SR, D'souza ZI, Priyadharsini J, Rajpari KN. Fibrolipoma of the Tongue: a Rare Entity With Literature Review. [DOI:10.21203/rs.3.rs-1161275/v1]

47. Rezazadeh F, Jaafari-Ashkavandi Z, Afshari A, Tarjan A. Rare fibrolipoma of attached gingiva: a case report and review of the literature. Clin Case Rep. 2022;10(11):e6643. [DOI:10.1002/ccr3.6643] [PMCID:PMC9702344] [PMID:36447670]

48. Nunes JS, da Silva EL, de Bem Prunes B, Visioli F. Oral fibrolipoma in the buccal mucosa. Oral fibrolipoma in the buccal mucosa. Oral Surg Oral Med Oral Pathol Oral Radiol. 2023;136(1):63-64. [DOI:10.1016/j.oooo.2023.03.214]

49. Zouaghi H, Chokri A, Bouguezzi A, Abdeljelil NB, Sioud S, Hentati H, et al. Oral fibrolipoma. Oral fibrolipoma. Autops Case Rep. 2023;13:e2023431. [DOI:10.4322/acr.2023.431] [PMCID:PMC10243747] [PMID:37287567]

50. Shah SP, Verma O, Kothari JV. Oral fibrolipoma: An uncommon occurrence. A case report [Internet]. *J Oral Med Oral Surg Oral Pathol Oral Radiol*. 2023 [cited 2026 Oct 15];9(4):233-235. [DOI:10.18231/j.jooo.2023.049]

51. Keerthana DR, Angadi PV. Fibrolipoma of the buccal mucosa: A rare case report. Indian Journal of Health Sciences and Biomedical Research kleu. 2023;16(1):171-174. [DOI:10.4103/kleuhsj.kleuhsj_580_22]

52. Tandon A, Srivastava A, Jaiswal R, Gaur A. Oral fibrolipoma: A rare clinicopathological entity. Journal of Oral and Maxillofacial Pathology: JOMFP. 2023;27(3):537. [DOI:10.4103/jomfp.jomfp_105_23] [PMCID:PMC10683883] [PMID:38033946]

53. Torsakul P, Rirattanapong P, Phimonsri R. Fibroepithelial hyperplasia and fibrolipoma in a 4-year-old patient: a rare case report. Mahidol Dent J. 2024;44(2):113-120.

54. Wang D, Yu H, Gao T, Lu H, Wang YE. Fibrolipoma of the lower lip: a case report and review of the literature. Medicine (Baltimore). 2024;103(25):e38543. [DOI:10.1097/md.0000000000038543] [PMCID:PMC11192005] [PMID:38905431]