Iran J Pathol. 2027;22(1):71–77 | ISSN 2345-3656 | MAIN SUBJECTS Gynecologic Pathology

Comparison of the Relative Frequency of Nuclear Beta-Catenin Immunostaining in Normal Endometrium, Atypical Endometrial Hyperplasia, and Endometrioid Carcinoma of the Endometrium

Amin Shameli[1], **Fereshteh Mohammadizadeh**[2], **Parisa Adelnia**[2]*, **Mitra Heidarpour**[2]

1. Faculty of Medicine, Isfahan University of Medical Sciences, Isfahan, Iran
2. Department of Pathology, Faculty of Medicine, Isfahan University of Medical Sciences, Isfahan, Iran

RECEIVED 27 Feb 2026 ACCEPTED 04 Aug 2026 PUBLISHED ONLINE 15 Oct 2026 DOI 10.22034/ijp.2026.2086831.3635

ABSTRACT

Background & Objective: Accurate distinction between endometrioid intraepithelial neoplasia (EIN) and normal endometrium can be challenging because of morphologic overlap. Nuclear β-catenin has been proposed as an adjunctive marker in this setting. To evaluate nuclear β-catenin expression in normal endometrium, EIN, and endometrioid carcinoma, and to assess its potential diagnostic and prognostic relevance.

Materials and Methods: In this comparative cross-sectional study, 120 formalin-fixed, paraffin-embedded endometrial specimens were examined, including 40 normal endometria, 40 EIN cases, and 40 endometrioid carcinomas. Immunohistochemistry was performed using a monoclonal anti-β-catenin antibody. Nuclear positivity was defined as strong nuclear staining in glandular epithelial cells. Group comparisons were performed using chi-square/Fisher's exact tests, and odds ratios (ORs) with 95% confidence intervals (CIs) were estimated for pairwise comparisons.

Results: Nuclear β-catenin expression was absent in all normal samples, whereas positivity was observed in 23/40 EIN cases (57.5%) and 29/40 carcinomas (72.5%) (overall $p < 0.001$). Compared with normal endometrium, EIN showed markedly higher odds of β-catenin positivity (corrected OR 108.24, 95% CI 6.21–1887.42). Compared with EIN, positivity was numerically higher in carcinoma, but the pairwise comparison was not statistically significant after adjustment for sample type (adjusted OR 2.58, 95% CI 0.72–9.25). Within the carcinoma group, nuclear β-catenin expression was not significantly associated with tumor grade, tumor size, or lymph node involvement.

Conclusion: Nuclear β-catenin expression was absent in normal endometrium and present in EIN and endometrioid carcinoma, supporting its role as an adjunctive diagnostic marker, although its prognostic significance remains uncertain.

KEYWORDS Carcinoma, Endometrioid, CTNNB1 Protein, Human, Endometrial Hyperplasia, beta Catenin

Corresponding Information: Parisa Adelnia, Department of Pathology, Faculty of Medicine, Isfahan University of Medical Sciences, Isfahan, Iran, Parisaadelnia@gmail.com

Copyright © 2027 The Author(s). This is an open-access article distributed under the terms of the CC BY 4.0, which permits unrestricted use, distribution, and reproduction in any medium, provided the original work is properly cited.

INTRODUCTION

Endometrial cancer arises from the epithelial lining of the endometrium and ranks as the sixth most common malignancy among women worldwide. In 2020, more than 417,000 new cases were reported globally, with over 97,000 deaths recorded in the same year (1). The overall 5-year survival rate is approximately 76%, rising to over 90% in patients with low-risk, early-stage disease. In contrast, outcomes are markedly poorer in advanced settings, with median survival for recurrent or metastatic disease only slightly exceeding 12 months (2).

The pathological classification of endometrial carcinomas by the World Health Organization (WHO) has traditionally relied on morphological characteristics. Endometrioid carcinoma is the most prevalent subtype, making up 80% of all cases. These tumors are graded based on architectural complexity, with low-grade lesions (grades 1 and 2) generally associated with more favorable outcomes compared with high-grade (grade 3) tumors (3, 4). Endometrial hyperplasia is recognized as the precursor lesion of endometrioid carcinoma. It is a noninvasive condition characterized by abnormal proliferation of the endometrial lining (5). The WHO has proposed a framework that distinguishes between hyperplasia without atypia and atypical hyperplasia/endometrioid intraepithelial neoplasia (EIN) (6).

One of the challenges faced by pathologists is the great similarity between well-differentiated endometrioid carcinoma and atypical hyperplasia, and the possibility of overdiagnosis of atypical hyperplasia in the context of endometrial polyps, endometritis, and various types of metaplasia (7). Furthermore, treatment of abnormal uterine bleeding (AUB) with exogenous hormones can alter the morphology of lesions. Technical errors such as small sample volume, fixation and staining defects, performing curettage at an inappropriate time, and the pathologist's lack of experience can limit the use of the diagnostic criteria (8). Distinction of real cellular atypia from changes caused by hormone use and metaplastic changes is

problematic in some cases and sometimes leads to overdiagnosis of benign lesions. Considering the diagnostic challenges and the completely different treatment approach to precancerous lesions compared with benign lesions, finding reliable solutions with high reproducibility is essential to minimize diagnostic errors (9).

Experts have noted that traditional histological classification systems often lack reproducibility and precision. Consequently, in 2013, The Cancer Genome Atlas (TCGA) project represented a hallmark shift in cancer classification, moving from conventional morphology-based approaches toward a molecular framework (10). Recent guidelines from ESGO, ESTRO, ESP, and FIGO recommend that, where feasible, molecular characterization of tumors should be incorporated into clinical practice (2, 11). The WHO Classification of Tumours (5th edition) lists four molecular subtypes of endometrial cancer (EC). These are POLE (DNA polymerase epsilon)–ultramutated tumors, mismatch repair–deficient (MMRd) tumors, p53-mutant (p53abn) tumors, and tumors of no specific molecular profile (NSMP). When correlated with histopathological subtypes, endometrioid tumors are more frequently associated with POLE-ultramutated, MMRd, or NSMP categories, whereas non-endometrioid histological subtypes are more commonly classified within the p53-abnormal group (6).

It has been reported that endometrioid endometrial carcinoma cases harboring exon 3 mutations in CTNNB1 (catenin β1) are associated with increased recurrence rates and poorer clinical outcomes (12).

Recent literature suggests that nuclear beta-catenin expression by immunohistochemistry is highly sensitive and specific for beta-catenin mutations. The significance of beta-catenin expression in EIN/atypical hyperplasia and its relationship to altered differentiation patterns in EIN has yet to be fully explored (13). Beta-catenin is a key protein in the Wnt signaling pathway and is normally expressed on the cellular membrane, where it links cell-cell adherens junctions to the cytoskeleton. When the Wnt pathway is activated, beta-catenin accumulates in the cytoplasm and then migrates into the nucleus, where it binds to transcription factors of the LEF/TCF family. While the Wnt/β-catenin pathway plays a physiological role in embryonic development and cell proliferation, its pathologic activation can lead to cancerous transformation (14–16). In this respect, the Wnt/β-catenin pathway is known to be involved in endometrial carcinogenesis, with specific regard to endometrioid adenocarcinoma and its precursor atypical endometrial hyperplasia. In this field, the scientific interest in beta-catenin has recently increased, since mutations in its encoding gene CTNNB1 have shown an independent prognostic value in endometrial cancer, delineating a separate molecular subgroup (12, 17).

However, genome sequencing is a costly and technically complex procedure, which limits the broad implementation of molecular classification in routine clinical practice. In this context, immunohistochemical assessment of nuclear β-catenin expression may serve as a practical diagnostic surrogate for identifying patients with CTNNB1 mutations (18).

Given the limited data on nuclear β-catenin expression in normal endometrium, endometrioid intraepithelial neoplasia, and endometrioid endometrial carcinoma, we aimed to evaluate differences in its expression across these entities and its association with clinicopathological parameters in endometrioid carcinoma. We hypothesized that nuclear β-catenin expression differs among normal, premalignant, and malignant endometrial tissues and is associated with adverse pathological features in endometrioid endometrial carcinoma.

METHODS

This comparative cross-sectional study was conducted on paraffin blocks of formalin-fixed tissue samples, including samples from curettage and hysterectomy specimens of patients diagnosed with normal endometrium, atypical endometrial hyperplasia, and endometrioid carcinoma of the endometrium, at Alzahra and Beheshti educational hospitals in Isfahan between 2023 and 2025.

Inclusion criteria:

Endometrial samples from hysterectomy and curettage of all age groups with diagnoses of normal endometrium (proliferative or secretory), atypical endometrial hyperplasia/EIN, and endometrioid carcinoma of the endometrium having sufficient tissue for IHC staining.

Exclusion criteria:

Patients who had received hormones prior to endometrial curettage or hysterectomy;

Cases that did not meet the complete diagnostic criteria for atypical endometrial hyperplasia/EIN; Cases of normal endometrium that were in the interval phase, because previous studies have shown that interval phase endometrium may exhibit nuclear staining for beta-catenin; Patients with a prior diagnosis of endometrial carcinoma who had undergone medical treatment for carcinoma prior to endometrial curettage or hysterectomy (17).

The sample size was estimated using a two-group proportion comparison formula, referenced from Xiong et al. (2010), which reported beta-catenin nuclear expression frequencies. Assuming a two-sided significance level (α) of 0.01, 90% statistical power (1–β), and expected proportions of 10% and 50% in the study groups, a minimum of 40 participants per group was required to detect a statistically significant difference (19).

$$n = \frac{(Z_{1-\frac{\alpha}{2}} + Z_{1-\beta})^2 [P_1(1-P_1) + P_2(1-P_2)]}{[P_1 - P_2]^2} = 40 \text{ per-group}$$

$$\alpha = 0.05 \quad \beta = 0.2 \quad P_1 = 10\% \quad P_2 = 50\%$$

Hematoxylin and eosin (H&E)–stained slides of all samples were re-examined independently by two pathologists, blinded to clinical data, to confirm the diagnosis. Discordant cases were reviewed jointly to reach consensus. Because full consensus was reached after joint review, formal inter-observer agreement statistics (e.g., Cohen's κ) were not calculated.

The total number of samples was 120, including 40 normal endometria, 40 atypical endometrial hyperplasias, and 40 endometrioid endometrial carcinomas.

In this study, according to the WHO 2014 classification, the diagnostic criteria for atypical endometrial hyperplasia/EIN were as follows: increased gland-to-stroma ratio (greater than one) with glandular crowding/cytological atypia in the form of nuclear enlargement, nuclear pleomorphism, and loss of nuclear polarity compared with normal endometrium/minimum lesion diameter of 1 mm/exclusion of endometrioid carcinoma/exclusion of lesions mimicking atypical endometrial hyperplasia. Samples lacking all the criteria and cases that had received hormonal treatment were excluded from the study.

The diagnostic criteria for endometrioid endometrial carcinoma were as follows: back-to-back (confluent) glands/villous, cribriform, labyrinthine, and solid patterns/desmoplastic stromal reaction/myometrial invasion.

Normal endometrium samples were selected from endometria showing a normal cyclic pattern (proliferative or secretory phase).

Paraffin blocks and microscopic slides of formalin-fixed endometrial curettage and hysterectomy specimens, diagnosed as normal endometrium, atypical hyperplasia, and endometrioid carcinoma of the endometrium, which met the inclusion criteria, were retrieved from the pathology department archives of Beheshti and Alzahra educational hospitals based on archive numbers available in the hospital information system and included in the study.

Hematoxylin-eosin slides and β-catenin immunostained slides were reviewed independently by two pathologists blinded to clinical data. Discordant cases were subsequently reviewed jointly to obtain a final consensus diagnosis and staining classification for analysis. Because only the final consensus classifications were retained in the study dataset, formal interobserver agreement statistics (e.g., Cohen's κ) could not be calculated retrospectively.

Tissue sections with a thickness of 4 µm were prepared from 120 blocks containing suitable tissue for immunohistochemical (IHC) staining, and nuclear expression of beta-catenin was evaluated by IHC. Beta-catenin antibody (mouse monoclonal antibody; clone: CTNNB1/1508; Long Island Antibody Diagnostica Inc.) was used for IHC staining. Sections were baked in a dehydration oven at 60°C for 60 min and dewaxed, then hydrated using xylene and graded alcohol washes. Antigen retrieval and deparaffinization were performed using EnVision™ FLEX Target Retrieval Solutions (Dako, Glostrup, Denmark). Sections were cooled to room temperature for 5 min using TBST washing buffer and then incubated with the primary antibody. DAB chromogen was used for Beta-catenin detection, and hematoxylin was applied for counterstaining the slides.

Nuclear β-catenin expression in glandular epithelium was the prespecified criterion for aberrant staining (17). After immunohistochemical staining, cases were classified as positive or negative based on the presence of unequivocal strong nuclear staining in endometrial glandular epithelial cells. Diffuse staining of all cells in a gland was not required; focal strong nuclear staining was sufficient for a positive designation. Cytoplasmic or membranous staining without convincing nuclear staining was not considered positive. If nuclear, cytoplasmic, and membranous staining were simultaneously present, a case was considered positive only when nuclear staining was at least as strong as membranous staining in the same cells. Because the primary aim of the study was to detect aberrant nuclear localization rather than staining burden, staining was analyzed as a dichotomous variable rather than by H-score or percentage-based extent scoring. A structured semi-quantitative scoring system had not been prospectively recorded in the study dataset (20).

Data Analysis

Statistical analysis was performed using SPSS version 25. Quantitative data were summarized as mean ± standard deviation or median [interquartile range], and qualitative data as number (%). Overall group differences in nuclear β-catenin positivity were assessed using chi-square or Fisher's exact tests, as appropriate. Pairwise associations were summarized using odds ratios (ORs) with 95% confidence intervals (CIs). Because no normal endometrial sample showed nuclear β-catenin positivity, comparisons involving the normal group were not suitable for standard logistic regression and were therefore evaluated using Fisher's exact test and continuity-corrected OR estimation. The carcinoma-versus-EIN comparison was further examined using binary logistic regression, first unadjusted and then adjusted for sample type (curettage vs hysterectomy). In addition, a sensitivity analysis restricted to curettage specimens was performed for the EIN-versus-normal comparison. A two-sided p-value <0.05 was considered statistically significant.

RESULTS

Study characteristics and sample distribution

The study population comprised 120 cases, balanced across three diagnostic groups: normal endometrium (Normal), atypical endometrial hyperplasia (EIN), and endometrioid carcinoma (Carcinoma), with 40 cases (33.3%) in each group (Table 1).

The method of tissue sampling differed significantly across groups. Curettage was the predominant sampling technique in the Normal group (40/40, 100%) and in the EIN group (38/40, 95.0%), whereas hysterectomy was more common in the Carcinoma group (26/40, 65.0%) (Table 1). This distribution was significantly associated with diagnostic group ($p < 0.001$). Because specimen type differed across groups, additional adjusted and sensitivity analyses were performed to evaluate its potential confounding effect on the association between pathology group and nuclear β-catenin positivity.

Data presented as Number (%).

Chi-square Test: $\chi^2 = 58.509$, $df = 2$, $p < 0.001$

Nuclear β-catenin expression across diagnostic groups

Nuclear β-catenin expression showed distinct patterns across the three diagnostic groups (Table 2, Fig. 1A–C). No normal endometrial sample showed nuclear positivity (0/40, 0.0%). For comparison, typical (simple) endometrial hyperplasia showed a predominantly membranous staining pattern (Fig. 2). In contrast, nuclear β-catenin positivity was observed in 23/40 EIN cases (57.5%) and in 29/40 carcinoma cases (72.5%) (Table 2).

Table 1. Distribution of Diagnostic Groups and Sample Types

Group	Number	Percent	Sample type	
			Hysterectomy	Curettage
EIN (Atypical Endometrial Hyperplasia)	40	33.3%	2 (5.0)	38 (95.0)
Endometrioid Carcinoma	40	33.3%	26 (65.0)	14 (35.0)
Normal Endometrium	40	33.3%	0	40 (100.0)
Total	120	100.0%	28 (23.3)	92 (76.7)

doi:10.22034/ijp.2026.2086831.3635

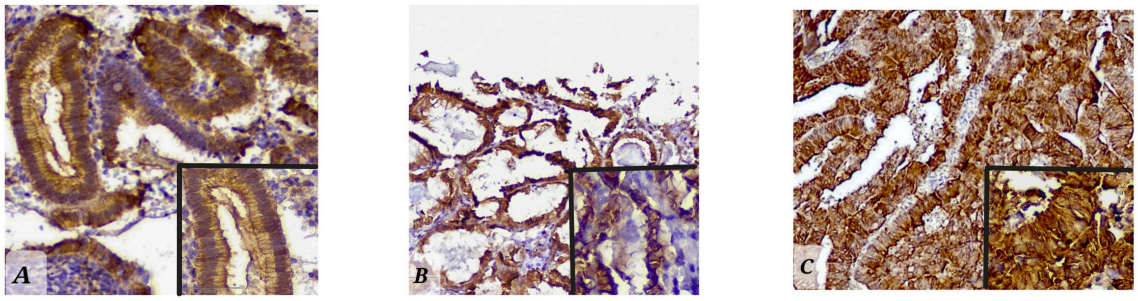

Fig 1. Patterns of Beta-catenin expression. Each panel represents a separate case. Enlarged views are provided in the insets. A: Membranous staining in normal endometrium. Predominant nuclear localization of Beta-catenin in B: atypical endometrial hyperplasia/EIN and C: endometrioid carcinoma (FIGO grade 1).

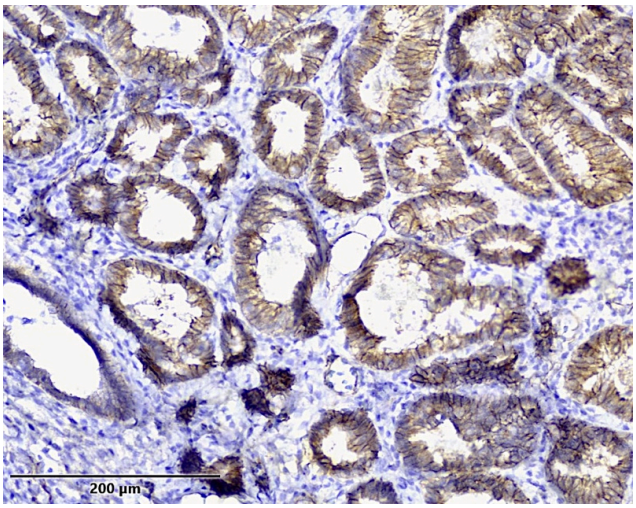

Fig 2. Predominant membranous localization of Beta-catenin in typical (simple) endometrial hyperplasia.

Table 2. Nuclear Beta-catenin Expression by Groups

Group	Positive	Negative
EIN	23 (57.5)	17 (42.5)
Carcinoma	29 (72.5)	11 (27.5)
Normal	0	40 (100.0)
Total	52 (43.3)	68 (56.7)

Data presented as Number (%).

Chi-square Test: $\chi^2 = 47.715$, $df = 2$, $p < 0.001$

Overall, nuclear β-catenin expression differed significantly across the three groups ($\chi^2 = 47.71$, $p < 0.001$), with a substantial association size (Cramér's V = 0.63). Pairwise and adjusted effect estimates are presented in Table 3. EIN showed markedly higher odds of nuclear β-catenin positivity than normal endometrium (corrected OR 108.24, 95% CI 6.21–1887.42). In contrast, carcinoma was not significantly associated with higher odds of positivity than EIN in the unadjusted logistic model (OR 1.95, 95% CI 0.76–4.96) or in the model adjusted for sample type (adjusted OR 2.58, 95% CI 0.72–9.25) (Table 3).

To further address the imbalance in specimen type, a sensitivity analysis restricted to curettage specimens was performed. In this analysis, EIN remained strongly associated with nuclear β-catenin positivity compared with normal endometrium (corrected OR 122.67, 95% CI 7.00–2150.37) (Table 3).

Pathological features of the carcinoma group

Within the carcinoma cohort, grade 1 tumors were the most frequent (24/40, 60.0%), followed by grade 2 (13/40, 32.5%) and grade 3 (3/40, 7.5%) (Table 4). Among cases with available hysterectomy-based pathologic assessment, the mean tumor size was 3.53 ± 1.65 cm (median 3.35 cm, IQR 2.00–4.27 cm), and lymph node involvement was present in 4/26 cases (15.4%) (Table 4). Given the predominance of low-grade tumors and the limited number of adverse pathologic events, analyses of prognostic associations should be interpreted cautiously.

Table 4. Distribution of Pathological Variables in Carcinoma Group

Variable	Category	Number (percent) or mean ± SD
Carcinoma grade	Grade 1	24 (60)
	Grade 2	13 (32.5)
	Grade 3	3 (7.5)
Tumor size (cm)		3.53±1.65
Lymph node involvement	N0	22 (84.6)
	N1/N2	4 (15.4)

Nuclear β-catenin expression and carcinoma grade

Within the carcinoma group, nuclear β-catenin positivity was observed in 20/24 grade 1 tumors (83.3%), 7/13 grade 2 tumors

Table 3. Pairwise and adjusted analyses of nuclear β-catenin positivity across diagnostic groups

Comparison	Analysis population	Method	OR	95% CI	P- value
EIN vs Normal	All cases	Fisher's exact test with continuity-corrected OR*	108.24	6.21–1887.42	<0.001
Carcinoma vs EIN	All cases	Unadjusted binary logistic regression	1.95	0.76–4.96	0.241
Carcinoma vs EIN	All cases	Multivariable binary logistic regression adjusted for sample type	2.58	0.72–9.25	0.146
EIN vs Normal	Curettage-only sensitivity analysis	Fisher's exact test with continuity-corrected OR*	122.67	7.00–2150.37	<0.001

* Because no normal endometrial sample showed nuclear β-catenin positivity, standard logistic regression was not appropriate for comparisons involving the normal group; therefore, Fisher's exact test and continuity-corrected odds-ratio estimation were used.

Table 5. Association Between Nuclear Beta-catenin Expression and Carcinoma Grade

Carcinoma grade	Positive	Negative	Total
Grade 1	20 (83.3)	4 (16.7)	24
Grade 2	7 (53.8)	6 (46.2)	13
Grade 3	2 (66.7)	1 (33.3)	3
Total	29 (72.5)	11 (27.5)	40

Table 6. Association of Nuclear Beta-catenin Expression with Prognostic Factors in Hysterectomy Subgroup

Variable	beta-catenin positive	beta-catenin negative	p-value
Tumor Size (cm)	3.56 ± 1.76	3.43 ± 1.43	0.858
Lymph Node Involvement			0.925
N0	16 (72.7)	6 (27.3)	
N1/N2	3 (75.0)	1 (25.0)	

(53.8%), and 2/3 grade 3 tumors (66.7%) (Table 5). Although positivity appeared numerically highest in grade 1 tumors, no statistically significant association was observed between nuclear β-catenin expression and tumor grade (χ^2 = 3.73, p = 0.155) (Table 5). This analysis was limited by the predominance of grade 1 tumors and the small number of grade 3 cases.

Data presented as Number (%).

Chi-square Test: χ^2 = 3.733, *df* = 2, p = 0.155

Prognostic factors in the hysterectomy subgroup of carcinoma cases

In the hysterectomy subgroup of carcinoma cases, tumor size did not differ significantly between nuclear β-catenin-positive and β-catenin-negative tumors (3.56 ± 1.76 cm vs 3.43 ± 1.43 cm, respectively; p = 0.858) (Table 6). With respect to lymph node status, nuclear β-catenin positivity was observed in 16/22 N0 cases (72.7%) and 3/4 N1/N2 cases (75.0%), with no statistically significant association between β-catenin expression and nodal status (p = 0.925) (Table 6). Interpretation of these findings is limited by the small number of node-positive cases in this subgroup.

Data presented as Mean ± SD, Number (%), and Median [IQR].

p-values were calculated using the independent-samples t-test and chi-square test.

DISCUSSION

The present study evaluated nuclear β-catenin expression across normal endometrium, endometrioid intraepithelial neoplasia (EIN), and endometrioid carcinoma, and explored whether nuclear β-catenin positivity was associated with tumor grade or other pathologic parameters within the carcinoma group. Nuclear β-catenin expression was absent in normal endometrium and was observed in both EIN and carcinoma, indicating that aberrant nuclear localization is associated with endometrial neoplastic lesions. Although positivity was numerically more frequent in carcinoma than in EIN, pairwise analysis did not demonstrate a statistically significant difference between these two groups. Therefore, the clearest distinction in our data was between normal endometrium and pathologic lesions rather than between EIN and carcinoma.

This pattern is broadly consistent with previous literature. Aguilar et al. reported that nuclear β-catenin, particularly when interpreted together with PTEN and PAX2, may help distinguish precancerous lesions from benign mimics, which is in line with the sharp contrast observed in our study between normal endometrium and pathologic lesions (20). Similarly, Ruz-Caracuel et al. showed that CTNNB1-mutated carcinomas are often low-grade and early-stage, which is compatible with our finding that nuclear β-catenin positivity was common in carcinomas without a clear association with adverse pathologic features. Together, these observations support the potential adjunctive diagnostic value of nuclear β-catenin rather than a definitive prognostic role (21). In both studies, β-catenin serves as a molecular surrogate for underlying Wnt pathway dysregulation, reinforcing the biological rationale for the escalating positivity seen across the diagnostic continuum.

Other studies have reported findings that help contextualize our results. De Leo et al. suggested that CTNNB1 molecular status may refine prognostic classification in selected endometrial carcinoma subgroups, whereas we did not observe significant associations between nuclear β-catenin expression and the prognostic parameters evaluated here. One likely explanation is methodological: their study incorporated molecular profiling, whereas our study relied on immunohistochemical nuclear localization alone. Similarly, Wright et al. found that nuclear β-catenin expression in EIN did not predict carcinoma on subsequent hysterectomy. This difference may reflect differences in study design, as their work evaluated longitudinal outcomes, whereas our study was cross-sectional and focused on staining patterns at the time of diagnosis.

The observed staining pattern is compatible with prior evidence linking nuclear β-catenin localization to Wnt/β-catenin pathway activation in endometrial neoplasia (22, 23). Aberrant activation of this pathway has also been implicated in endometrial precancer and early neoplastic progression (24, 25). However, because the present study was cross-sectional and did not include molecular confirmation of CTNNB1 status, our findings should be interpreted as associative rather than mechanistic. The absence of a significant difference between carcinoma and EIN in pairwise analysis further suggests that nuclear β-catenin positivity may be more useful as an indicator of pathologic endometrium than as a marker of progressive biologic severity (26).

Several limitations should be acknowledged. First, the cross-sectional design precludes assessment of progression from EIN to carcinoma over time. Second, molecular confirmation of CTNNB1 mutation status was not available, so nuclear β-catenin staining could not be directly correlated with genotype. Third, although slides were reviewed independently and discordances

were resolved by consensus, formal interobserver agreement statistics were unavailable because only final consensus classifications were retained. Fourth, β-catenin staining was assessed dichotomously, and no semi-quantitative extent or intensity score was prospectively recorded. In addition, specimen type differed across groups, with normal and most EIN cases obtained by curettage and carcinoma cases more often obtained by hysterectomy, which may have introduced residual confounding despite adjusted and sensitivity analyses. Finally, the carcinoma cohort was dominated by low-grade tumors and included few node-positive cases, limiting the power to detect associations with prognostic variables.

Despite these limitations, the results suggest that nuclear β-catenin may have adjunctive diagnostic value in selected histopathologic settings. In this cohort, the complete absence of nuclear staining in normal endometrium together with incomplete positivity in EIN and carcinoma suggests greater rule-in than rule-out value. Accordingly, β-catenin may be most useful when interpreted alongside morphology and, where available, other ancillary markers rather than as a standalone discriminator.

Future studies should incorporate molecular genotyping to clarify the relationship between CTNNB1 alterations and immunohistochemical nuclear localization. Longitudinal studies of EIN with and without nuclear β-catenin positivity would help determine whether this marker has predictive value for progression. In addition, larger and more balanced carcinoma cohorts are needed to evaluate possible associations with prognostic features. Comparative studies integrating β-catenin with other markers such as PTEN and PAX2 may further define its role in diagnostic algorithms.

CONCLUSION

In summary, nuclear β-catenin expression was associated with endometrial neoplastic lesions, being absent in normal endometrium and present in a subset of EIN and endometrioid carcinoma cases. In this cohort, the staining pattern suggests that β-catenin may have adjunctive diagnostic value, particularly as a rule-in marker in challenging histopathologic evaluations. However, its prognostic significance could not be reliably determined because of the predominance of low-grade tumors and the limited number of adverse pathologic events in the carcinoma group. Further studies integrating morphologic, immunohistochemical, and molecular data are needed to clarify its diagnostic and biological significance.

Abbreviations:
AUB: abnormal uterine bleeding;
CTNNB1: catenin beta 1;
DAB: diaminobenzidine;
EC: endometrial carcinoma;
EIN: endometrioid intraepithelial neoplasia;
H&E: hematoxylin and eosin;
IHC: immunohistochemistry;
LEF/TCF: lymphoid enhancer factor/T-cell factor;

AI ASSISTANCE DISCLOSURE

ChatGPT (OpenAI) was used for language editing only. The entire work, including study design, analysis, and writing, was conducted by the authors, who take full responsibility for its content.

Funding

This study did not receive any specific grant from funding agencies in the public, commercial, or not-for-profit sectors.

Conflict of interest

The authors declare no conflict of interest.

Ethics Approval

The study was approved by the Ethics Committee of Isfahan University of Medical Sciences (ethics code: IR.MUI.MED.REC.1402.363).

Authors' Contributions

M.H. and F.M. conceptualized and designed the study. P.A. was responsible for data collection. A.S. performed the statistical analysis. P.A. and A.S. drafted the manuscript. All authors contributed to the interpretation of the data and the critical revision of the manuscript.

REFERENCES

1. Sung H, Ferlay J, Siegel RL, Laversanne M, Soerjomataram I, Jemal A, et al. Global Cancer Statistics 2020: GLOBOCAN Estimates of Incidence and Mortality Worldwide for 36 Cancers in 185 Countries. CA Cancer J Clin. 2021;71(3):209-249. [DOI:10.3322/caac.21660] [PMID:33538338]
2. Concin N, Matias-Guiu X, Vergote I, Cibula D, Mirza MR, Marnitz S, et al. ESGO/ESTRO/ESP guidelines for the management of patients with endometrial carcinoma. Int J Gynecol Cancer. 2021;31(1):12-39. [DOI:10.1136/ijgc-2020-002230] [PMID:33397713]
3. Crosbie EJ, Kitson SJ, McAlpine JN, Mukhopadhyay A, Powell ME, Singh N. Endometrial cancer. Lancet. 2022;399(10333):1412-1428. [DOI:10.1016/s0140-6736(22)00323-3] [PMID:35397864]
4. Feinberg J, Albright B, Black J, Lu L, Passarelli R, Gysler S, et al. Ten-Year Comparison Study of Type 1 and 2 Endometrial Cancers: Risk Factors and Outcomes. Gynecol Obstet Invest. 2019;84(3):290-297. [DOI:10.1159/000493132] [PMID:30602164]
5. Nees LK, Heublein S, Steinmacher S, Juhasz-Böss I, Brucker S, Tempfer CB, et al. Endometrial hyperplasia as a risk factor of endometrial cancer. Arch Gynecol Obstet. 2022;306(2):407-421. [DOI:10.1007/s00404-021-06380-5] [PMCID:PMC9349105] [PMID:35001185]
6. Höhn AK, Brambs CE, Hiller GGR, May D, Schmoeckel E, Horn LC. 2020 WHO Classification of Female Genital Tumors. Geburtshilfe Frauenheilkd. 2021;81(10):1145-1153. [DOI:10.1055/a-1545-4279] [PMCID:PMC8494521] [PMID:34629493]
7. Lax SF. Pathology of Endometrial Carcinoma. Adv Exp Med Biol. 2017;943:75-96. [DOI:10.1007/978-3-319-43139-0_3] [PMID:27910065]
8. Zheng W. Molecular Classification of Endometrial Cancer and the 2023 FIGO Staging: Exploring the Challenges and Opportunities for Pathologists. Cancers (Basel). 2023;15(16). [DOI:10.3390/cancers15164101] [PMCID:PMC10452831] [PMID:37627129]
9. Llobet D, Pallares J, Yeramian A, Santacana M, Eritja N, Velasco A, et al. Molecular pathology of endometrial carcinoma: practical aspects from the diagnostic and therapeutic viewpoints. J Clin Pathol. 2009;62(9):777-785. [DOI:10.1136/jcp.2008.056101] [PMID:18977806]
10. Kandoth C, Schultz N, Cherniack AD, Akbani R, Liu Y, Shen H, et al. Integrated genomic characterization of endometrial carcinoma. Nature. 2013;497(7447):67-73. [DOI:10.1038/nature12113] [PMCID:PMC3704730] [PMID:23636398]
11. Berek JS, Matias-Guiu X, Creutzberg C, Fotopoulou C, Gaffney D, Kehoe S, et al. FIGO staging of endometrial cancer: 2023. Int J Gynaecol Obstet. 2023;162(2):383-394. [DOI:10.1002/ijgo.14923] [PMID:37337978]

12. Travaglino A, Raffone A, Raimondo D, Reppuccia S, Ruggiero A, Arena A, et al. Prognostic significance of CTNNB1 mutation in early stage endometrial carcinoma: a systematic review and meta-analysis. Arch Gynecol Obstet. 2022;306(2):423-431. [DOI:10.1007/s00404-021-06385-0] [PMCID:PMC9349085] [PMID:35034160]

13. Wright MF, Fitzlaff S, Wyeth A, Zaragoza-Watkins M, Podoll MB, Quick CM, et al. Nuclear Beta-Catenin Expression in Endometrioid Intraepithelial Neoplasia (Atypical Hyperplasia) Does Not Predict Carcinoma on Subsequent Hysterectomy. Int J Gynecol Pathol. 2021;40(3):240-247. [DOI:10.1097/pgp.0000000000000695] [PMID:32897964]

14. Behrens J. Control of beta-catenin signaling in tumor development. Ann N Y Acad Sci. 2000;910:21-33. [DOI:10.1111/j.1749-6632.2000.tb06698.x] [PMID:10911903]

15. Wang Y, van der Zee M, Fodde R, Blok LJ. Wnt/B-catenin and sex hormone signaling in endometrial homeostasis and cancer. Oncotarget. 2010;1(7):674-684. [DOI:10.18632/oncotarget.201] [PMCID:PMC3248134] [PMID:21317462]

16. Travaglino A, Raffone A, Saccone G, De Luca C, Mollo A, Mascolo M, et al. Immunohistochemical Nuclear Expression of β-Catenin as a Surrogate of CTNNB1 Exon 3 Mutation in Endometrial Cancer. Am J Clin Pathol. 2019;151(5):529-538. [DOI:10.1093/ajcp/aqy178] [PMID:30715091]

17. McAlpine J, Leon-Castillo A, Bosse T. The rise of a novel classification system for endometrial carcinoma; integration of molecular subclasses. J Pathol. 2018;244(5):538-549. [DOI:10.1002/path.5034] [PMID:29344951]

18. Han O, Alci A, Yildirim HT, Gokkaya M, Yalcin N, Kandemir S, et al. β-catenin expression in endometrioid type endometrial cancer: Expression patterns and impact on disease outcomes. Oncol Lett. 2024;28(6):580. [DOI:10.3892/ol.2024.14713] [PMCID:PMC11484180] [PMID:39421318]

19. Xiong Y, Xiong YY, Zhou YF. Expression and significance of beta-catenin, Glut-1 and PTEN in proliferative endometrium, endometrial intraepithelial neoplasia and endometrioid adenocarcinoma. Eur J Gynaecol Oncol. 2010;31(2):160-164. [PMID:20527231]

20. Aguilar M, Chen H, Rivera-Colon G, Niu S, Carrick K, Gwin K, et al. Reliable Identification of Endometrial Precancers Through Combined Pax2, β-Catenin, and Pten Immunohistochemistry. Am J Surg Pathol. 2022;46(3):404-414. [DOI:10.1097/pas.0000000000001810] [PMCID:PMC8860214] [PMID:34545858]

21. Ruz-Caracuel I, López-Janeiro Á, Heredia-Soto V, Ramón-Patino JL, Yébenes L, Berjón A, et al. Clinicopathological features and prognostic significance of CTNNB1 mutation in low-grade, early-stage endometrial endometrioid carcinoma. Virchows Arch. 2021;479(6):1167-1176. [DOI:10.1007/s00428-021-03176-5] [PMCID:PMC8724178] [PMID:34420090]

22. Shi Q, Kang K, Chen YG. Liquid-liquid phase separation drives the β-catenin destruction complex formation. Bioessays. 2021;43(10):e2100138. [DOI:10.1002/bies.202100138] [PMID:34418117]

23. Stamos JL, Weis WI. The β-catenin destruction complex. Cold Spring Harb Perspect Biol. 2013;5(1):a007898. [DOI:10.1101/cshperspect.a007898] [PMCID:PMC3579403] [PMID:23169527]

24. van der Zee M, Jia Y, Wang Y, Heijmans-Antonissen C, Ewing PC, Franken P, et al. Alterations in Wnt-β-catenin and Pten signalling play distinct roles in endometrial cancer initiation and progression. J Pathol. 2013;230(1):48-58. [DOI:10.1002/path.4160] [PMID:23288720]

25. Pijnenborg JM, Kisters N, van Engeland M, Dunselman GA, de Haan J, de Goeij AF, et al. APC, beta-catenin, and E-cadherin and the development of recurrent endometrial carcinoma. Int J Gynecol Cancer. 2004;14(5):947-956. [DOI:10.1136/ijgc-00009577-200409000-00031] [PMID:15361208]

26. Parrish ML, Broaddus RR, Gladden AB. Mechanisms of mutant β-catenin in endometrial cancer progression. Front Oncol. 2022;12:1009345. [DOI:10.3389/fonc.2022.1009345] [PMCID:PMC9556987] [PMID:36248967]