Iran J Pathol. 2027;22(1):78–82 | ISSN 2345-3656 | MAIN SUBJECTS Endocrine Pathology

Invasive Encapsulated Follicular Variant of Papillary Thyroid Carcinoma (IEFVPTC) with Angioinvasion: A Case Report and Management Implications

Gunvanti Rathod[1#], Venkateshwar Reddy Doodipala[2#], Chandramouli Ramalingam[3], Swarnalatha Seelam[4], Snigdha Pothapragada[2], Samarth Sahoo[2], NagaSai Divya Kari[3], Pragnahitha Neerudu[3], Ajay Kumar Kondeti[3*]

1. *Department of Pathology and Lab Medicine, All India Institute of Medical Sciences (AIIMS), Bibinagar, Hyderabad, India*
2. *Department of General Surgery, All India Institute of Medical Sciences (AIIMS), Bibinagar, Hyderabad, India*
3. *Department of Radiation Oncology, All India Institute of Medical Sciences (AIIMS), Bibinagar, Hyderabad, India*
4. *Department of Radiodiagnosis, All India Institute of Medical Sciences (AIIMS), Bibinagar, Hyderabad, India*

RECEIVED 15 Apr 2026 ACCEPTED 25 Jun 2026 PUBLISHED ONLINE 01 Aug 2026 DOI 10.22034/ijp.2026.2087283.3646

ABSTRACT

Background & Objective: IEFVPTC is a rare subtype of differentiated thyroid carcinoma, which presents diagnostic challenges due to its benign-like radiological appearance and indeterminate cytology, often leading to under-treatment. The presence of capsular and vascular invasion impacts its prognosis and requires a more aggressive therapeutic approach. The 2025 American Thyroid Association (ATA) guidelines provide a revised framework, which has major implications for its management.

Case Presentation: A 36-year-old female presented with a gradually enlarging thyroid swelling over four years. Ultrasound showed a TI-RADS 4 lesion, and FNAC was Bethesda III (AUS). The right hemithyroidectomy was performed. Histopathology revealed a well-defined and encapsulated neoplasm characterized mainly by microfollicular and normofollicular patterns. Nuclear characteristics of papillary thyroid carcinoma were present among the tumor cells with enlarged nuclei, nuclear elongation, nuclear atypia, chromatin clearing (known as "Orphan Annie eye" appearance), nuclear grooves, and pseudo-intranuclear cytoplasmic inclusion in a few cells. Capsular invasion was present with definitive evidence of tumor penetration through the complete capsule thickness. Furthermore, there was vascular invasion in less than four fields characterized by presence of tumor cells in the vessel wall that was covered with endothelial cells. The final pathological diagnosis was IEFVPTC (pT2 Nx Mx). She was stratified as intermediate risk as per ATA guidelines. Postoperative CT imaging showed no residual disease. A completion thyroidectomy revealed no residual malignancy. Adjuvant radioiodine and TSH suppression were advised.

Conclusion: This case underscores the importance of detailed histopathological evaluation and ATA 2025 risk-adapted management in IEFVPTC to guide appropriate therapy and follow-up.

KEYWORDS Thyroid carcinoma, Thyroid Cancer, Papillary, IEFVPTC, Carcinoma, Follicular, Practice Guidelines as Topic

Corresponding Information: Ajay Kumar Kondeti, Department of Radiation Oncology, All India Institute of Medical Sciences (AIIMS), Bibinagar, Hyderabad, India, ajaykumar.kondeti@gmail.com

[#] Gunvanti Rathod & Venkateshwar Reddy Doodipala contributed equally. GR and VRD are joint first authors

Copyright © 2027 The Author(s). This is an open-access article distributed under the terms of the CC BY 4.0, which permits unrestricted use, distribution, and reproduction in any medium, provided the original work is properly cited.

INTRODUCTION

Papillary thyroid carcinoma (PTC) is the most common differentiated thyroid cancer, accounting for nearly 90% of cases (1). The follicular variant of papillary thyroid carcinoma (FVPTC) constitutes 9%–22% of PTCs and consists of follicular architecture with papillary-type nuclear features (2). The 2022 WHO classification recognized invasive encapsulated follicular variant of PTC (IEFVPTC) as a separate entity under encapsulated follicular-derived thyroid neoplasms (3). Histologically, IEFVPTC is characterized by a well-formed capsule with capsular and/or vascular invasion, distinguishing it from noninvasive follicular neoplasms and classical PTC (4, 5).

With the recognition of RAS-driven molecular alterations, IEFVPTC behaves closer to follicular thyroid carcinoma (FTC) rather than classic PTC, which is often driven by the BRAF V600E mutation (6). In the presence of angioinvasion, IEFVPTC demonstrates a propensity for hematogenous spread (7). Preoperative diagnosis is often challenging due to benign-like ultrasonography and indeterminate cytology, leading to underdiagnosis (8).

The 2025 American Thyroid Association (ATA) guidelines represent a paradigm shift in management, with inclusion of molecular stratification, individualized surgical planning, dynamic response-based surveillance, and clearly defined indications for RAI therapy. The DATA (Diagnosis–Assessment–Treatment–Response) model streamlines clinical decision-making (9). IEFVPTC is now classified as intermediate risk if vascular invasion is present.

This case is notable because limited angioinvasion (<4 foci) lies at an evolving treatment crossroads; some centers consider observation, while ATA 2025 recommends escalation. This case

emphasizes the clinical importance of accurate histopathological assessment and guideline-driven management in IEFVPTC. The objective of this manuscript is to report a surgical case and correlate outcomes with the updated ATA 2025 guidelines to provide clarity on management strategies.

CASE PRESENTATION

A 36-year-old female presented with gradually progressive anterior neck swelling for four years. The swelling began as a small pea-sized lump and steadily enlarged to the current size. There was no pain, dysphagia, hoarseness of voice, or dyspnea. She also reported no systemic symptoms, such as weight loss, tremors, menstrual changes, or signs of hyperthyroidism or hypothyroidism. She was diagnosed last year with hypothyroidism and advised on levothyroxine supplementation. There was no history of prior neck irradiation, menstrual abnormalities, or malignancy in the family.

On neck examination, a right thyroid lobe swelling was present, measuring 4 × 3 × 2 cm. It was well encapsulated and firm in consistency, moved with deglutition, and had no tenderness or visible pulsation. No palpable cervical lymphadenopathy was present. The systemic examination was unremarkable. Laboratory examinations revealed that complete blood count (CBC), renal function tests (RFTs), liver function tests (LFTs), and HbA1c were within normal limits. Viral markers (HIV, HBsAg, HCV) were negative. Regarding thyroid function status, T3/T4/TSH levels were 3.48/1.14/1.66 mIU/mL, respectively, suggesting a euthyroid status.

An ultrasound (USG) thyroid was performed, which showed a well-defined hypoechoic lesion in the right thyroid lobe, with a TI-RADS 4 category lesion. The size of the right lobe was 3.7 × 2.8 × 4.5 cm, left lobe: 1.1 × 0.9 × 1.4 cm, with no focal lesion, and isthmus: 1.5 mm, normal. No significant cervical lymphadenopathy was seen. Guided FNAC showed a Bethesda III–AUS (Atypia of Undetermined Significance) lesion. The differentials of a simple goiter vs thyroid malignancy were made for this solitary thyroid nodule, and it was planned for diagnostic hemithyroidectomy. A right hemithyroidectomy was performed uneventfully. The specimen was sent to the pathology department for histopathological examination.

HISTOPATHOLOGICAL FINDINGS

Grossly, the specimen showed a well-encapsulated nodular lesion measuring 3.2 × 2 × 1.8 cm with a smooth external surface. The cut section revealed a tan-brown, homogeneous appearance without areas of necrosis or hemorrhage. Recurrent laryngeal nerves and parathyroids were preserved (Fig. 1).

Microscopically, the tumor was completely surrounded by a thick fibrous capsule. The neoplasm predominantly displayed a follicular growth pattern composed of microfollicles and occasional normofollicles, with an absence of well-formed papillae. The tumor cells demonstrated characteristic nuclear features of papillary thyroid carcinoma, including nuclear enlargement, elongation, overlapping, irregular nuclear membranes, chromatin clearing, nuclear grooves, and occasional intranuclear cytoplasmic inclusions.

Capsular invasion was identified as unequivocal full-thickness penetration of the tumor through the capsule with extension into adjacent thyroid parenchyma. Vascular invasion was carefully assessed and confirmed by the presence of tumor emboli within capsular and extracapsular vessels, adherent to the vessel wall and lined by endothelial cells. Fewer than four foci of vascular invasion were identified, qualifying as focal angioinvasion. No tumor necrosis, increased mitotic activity, or high-grade features were observed. There was no evidence of extrathyroidal extension. Surgical margins were free of tumor. These features were diagnostic of IEFVPTC (Fig. 2). No IHC was performed. The stage, as per AJCC 8th edition, was pT2 Nx Mx –



Fig 1. Gross specimen of the right thyroid lobe following hemithyroidectomy, showing a well-circumscribed, encapsulated nodular lesion with a smooth external surface and tan-brown cut surface.

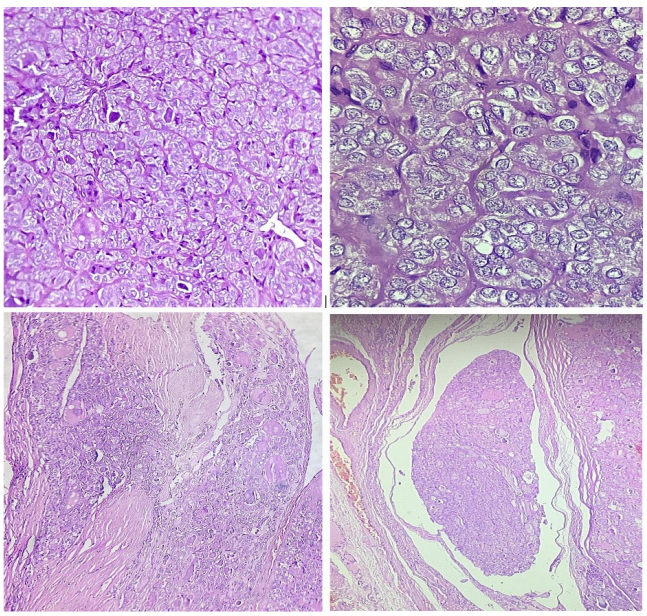

Fig 2. Photomicrographs of the thyroid tumor demonstrating encapsulated follicular-patterned neoplasm with microfollicular architecture and papillary thyroid carcinoma–type nuclear features, including nuclear enlargement, chromatin clearing, nuclear grooves, and focal intranuclear cytoplasmic inclusions. Areas of capsular and vascular invasion are highlighted.

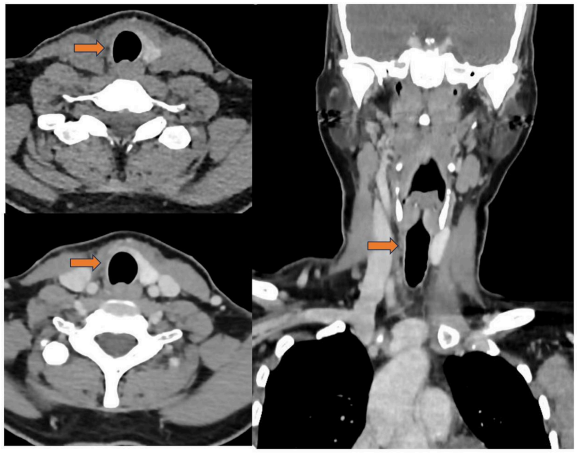

Fig 3. Contrast-enhanced CT scan of the neck following right hemithyroidectomy

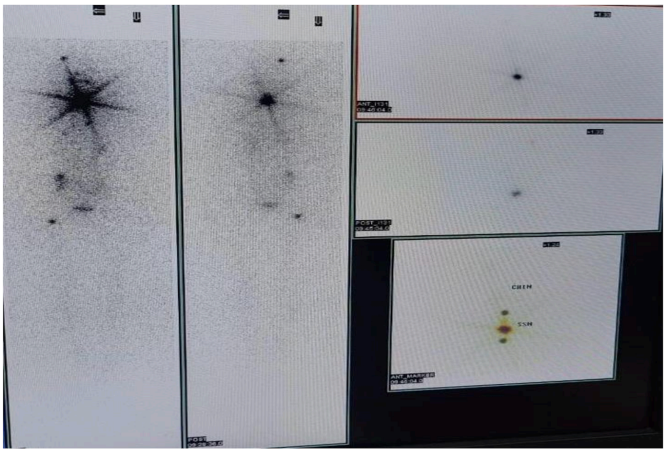

Fig 4. Whole-body radioiodine scan performed with low-dose I-131 (3 mCi), demonstrating abnormal radioiodine uptake suggestive of residual and metastatic thyroid tissue.

Stage I (age <55 years). The ATA 2025 risk category was assigned as intermediate risk (intermediate-low, in view of vascular invasion).

A postoperative CT neck scan, plain and contrast-enhanced, was performed, which showed findings of posthemithyroidectomy status, with subcentimetric lymph nodes noted at levels I–IV (largest lymph node: 6.7 mm, left level IIa). No gross metastasis or airway compromise was noticed (Fig. 3).

Accordingly, based on ATA 2025, a completion thyroidectomy with central neck dissection was performed. The postoperative histopathology report showed findings of no residual malignancy in the remaining thyroid, and one lymph node showed adipocyte metaplasia. Two parathyroid glands were identified, which were unremarkable, with no evidence of regional nodal involvement.

Based on the ATA 2025 intermediate-risk category and evidence of vascular invasion, a multidisciplinary tumor board discussion was held. A whole-body thyroid scan with a low dose of I-131 (3 mCi) was advised. The thyroid scan showed abnormal intense focal tracer uptake in the thyroid bed region, with additional focal faint tracer uptake noted in the skull (right postero-parietal region) and right thigh regions (Fig. 4).

Additional imaging with a CT scan showed correlation with the I-131 scan and revealed subtle lytic lesions in the proximal shaft of the right femur and the right frontal bone. The patient was subsequently treated with high-dose therapy with 200 mCi of I-131. Further, TSH suppression (target, 0.1–0.5 mIU/L), regular follow-up with serum thyroglobulin (Tg)/anti-Tg, ultrasound, and dynamic response-based surveillance were advised.

DISCUSSION

Invasive encapsulated follicular variant of papillary thyroid carcinoma (IEFVPTC) is a diagnostically challenging subtype of differentiated thyroid carcinoma with unique papillary-type nuclear, molecular, and clinical features (2). Although encapsulated, the presence of vascular and/or capsular invasion significantly alters prognosis and management (10). Misdiagnosis is common due to benign-appearing features on ultrasonography and indeterminate FNAC categories such as Bethesda III or IV (8). Our case demonstrates similar diagnostic ambiguity, with TI-RADS 4 ultrasound and Bethesda III cytology ultimately requiring postoperative confirmation of IEFVPTC.

DIFFERENTIAL DIAGNOSIS

The principal histopathological differentials in this case include noninvasive follicular thyroid neoplasm with papillary-like nuclear features (NIFTP) and follicular thyroid carcinoma (FTC). NIFTP is characterized by an encapsulated follicular-patterned lesion with papillary-like nuclear features but crucially lacks capsular and vascular invasion. In the present case, the unequivocal demonstration of both capsular and vascular invasion excludes NIFTP (5).

Follicular thyroid carcinoma (FTC), on the other hand, may show similar follicular architecture and invasive features; however, it lacks the diagnostic nuclear features of papillary thyroid carcinoma. The presence of classical PTC-type nuclear features, such as nuclear clearing, grooves, and pseudo-inclusions, in this tumor supports classification as IEFVPTC rather than FTC. Thus, the combined assessment of architectural patterns, nuclear morphology, and invasion criteria is essential for accurate classification (3).

Existing literature emphasizes that early-stage IEFVPTC without invasion behaves indolently, similar to benign nodules, and may not require aggressive therapy (11). However, vascular invasion—especially beyond one focus—confers a higher risk of hematogenous metastasis, analogous to follicular thyroid carcinoma (12, 13). Strict histological criteria for vascular invasion, including endothelial lining and attachment of tumor thrombus to the vessel wall, were applied to avoid overdiagnosis, as recommended in contemporary thyroid pathology guidelines (3).

A study analyzed the Surveillance, Epidemiology, and End Results (SEER) database and demonstrated no significant overall survival difference between IEFVPTC and classical PTC following propensity score matching, suggesting that with appropriate management, long-term outcomes remain favorable (14). However, the recurrence rates are higher in angioinvasive subtypes, justifying guideline-based therapeutic escalation (9).

RELEVANCE OF ATA 2025 GUIDELINES TO THIS CASE

The American Thyroid Association 2025 guidelines represent an evolution toward a more biologically driven and risk-adapted approach compared to earlier frameworks. Rather than relying predominantly on tumor size and nodal status, current recommendations emphasize invasion patterns, particularly vascular invasion, in guiding management decisions (9).

In this context, our patient was categorized as intermediate risk based on histopathological features, notably focal angioinvasion. This supported the decision for completion thyroidectomy, followed by consideration of radioactive iodine (RAI) therapy and TSH suppression, in line with contemporary risk-adapted principles. The emphasis on dynamic response-based follow-up, including thyroglobulin monitoring and imaging, further allows individualized surveillance and potential de-escalation of therapy over time.

The WHO 2022 classification (3) and existing literature also suggest that IEFVPTC shares biological behavior closer to follicular thyroid carcinoma, supported by its association with RAS-type mutations (6). Although molecular testing was not performed in our case, the presence of angioinvasion alone was sufficient to guide risk stratification and management.

There remains some debate regarding the need for RAI in cases with limited vascular invasion (<4 foci), with some advocating selective use. However, given the patient's age and risk profile, RAI was considered appropriate.

LIMITATIONS OF ATA 2025 GUIDELINES

The ATA 2025 guidelines are recent and not yet widely validated across diverse clinical settings. Therefore, their application should be interpreted cautiously, and management decisions should continue to integrate clinical judgment and existing evidence.

PROGNOSIS AND FOLLOW-UP

IEFVPTC generally demonstrates an excellent prognosis when treated appropriately. However, recurrences, although uncommon, may occur several years later. Thus, ATA 2025 emphasizes individualized surveillance guided by postoperative response. Serum thyroglobulin and anti-Tg levels, alongside periodic ultrasound, form the backbone of surveillance strategies. Follow-up after RAI includes serial Tg/TgAb measurements and neck ultrasound at months 3, 6, 9, and 12, followed by response-based interval extensions. TSH suppression will be maintained at 0.1–0.5 mIU/L for at least 12–24 months, depending on the dynamic response category.

NOVELTY AND EMERGING DISCUSSION

This case is notable because limited angioinvasion (<4 foci) lies at an evolving treatment crossroads; some centers consider observation, while ATA 2025 recommends escalation. It represents a real-world application of new guideline-driven decision-making, demonstrating how staging thresholds and management pathways have shifted. This case reinforces an updated paradigm in which pathological invasion characteristics supersede size in determining treatment intensity.

CONCLUSION

IEFVPTC is a distinct pathological entity requiring accurate histological diagnosis and guideline-oriented management. Vascular invasion pushes risk to the intermediate category, warranting completion thyroidectomy and RAI. ATA 2025 enables structured management based on surgical, pathological, and molecular markers. This case underscores the impact of evidence-based decision-making and reinforces the role of dynamic follow-up strategies for long-term control. The ATA 2025 provides clarity in managing this rare entity and supports evidence-based, risk-adapted, personalized care, which is particularly relevant in resource-limited settings where molecular testing is unavailable.

ABBREVIATIONS

DTC: Differentiated Thyroid Carcinoma
PTC: Papillary Thyroid Carcinoma
FTC: Follicular Thyroid Carcinoma
FVPTC: Follicular Variant of Papillary Thyroid Carcinoma
NIFTP: Non Invasive Follicular Thyroid neoplasm with Papillary-like nuclear features
IEFVPTC: Invasive Encapsulated Follicular Variant of Papillary Thyroid Carcinoma
ATA: American Thyroid Association
AJCC: American Joint Committee on Cancer
DATA: Diagnosis–Assessment–Treatment-Assessment of Response (ATA framework)
TI-RADS: Thyroid Imaging Reporting and Data System
FNAC: Fine-Needle Aspiration Cytology
AUS: Atypia of Undetermined Significance
RAI: Radioactive Iodine Therapy
TSH: Thyroid-Stimulating Hormone
Tg: Thyroglobulin
TgAb: Anti-Thyroglobulin Antibodies

Funding

This research received no specific grant from any funding agency in the public, commercial, or not-for-profit sectors.

Conflict of interest

The authors declared no conflict of interest.

Data Availability

The data that support the findings of this study are available from the corresponding author upon reasonable request.

Ethics Approval

This study was conducted in accordance with the Declaration of Helsinki. Institutional Review Board (IRB) approval was waived at the time the study was conducted. Written informed consent was obtained from all patients for the publication of their clinical details and any accompanying images. All patient data were anonymized to ensure confidentiality.

Authors' Contributions

Conceptualization: D.V.R.; Methodology: G.R., D.V.R.; Investigation: D.V.R., C.R., S.S., N.D.K., P.N.; Resources: D.V.R.; Data curation: D.V.R., C.R., S.S., N.D.K., P.N.; Writing – Original Draft Preparation: A.K.K.; Writing – Review & Editing: G.R., A.K.K., C.R., S.S., N.D.K., P.N.; Supervision: G.R., D.V.R. All authors have read and agreed to the published version of the manuscript.

Acknowledgments

NA

Declaration of AI Use

The authors declare that no generative AI or AI-assisted technologies were used in the writing process of this manuscript.

REFERENCES

1. Zhang J, Xu S. High aggressiveness of papillary thyroid cancer: from clinical evidence to regulatory cellular networks. Cell Death Discov. 2024;10(1):378. [DOI:10.1038/s41420-024-02157-2] [PMCID:PMC11347646] [PMID:39187514]
2. Thompson LD. Ninety-four cases of encapsulated follicular variant of papillary thyroid carcinoma: A name change to Noninvasive Follicular Thyroid Neoplasm with Papillary-like Nuclear Features would help prevent overtreatment. Mod Pathol. 2016;29(7):698-707. [DOI:10.1038/modpathol.2016.65] [PMID:27102347]
3. Jung CK, Bychkov A, Kakudo K. Update from the 2022 World Health Organization Classification of Thyroid Tumors: A Standardized Diagnostic Approach. Endocrinol Metab (Seoul). 2022;37(5):703-718. [DOI:10.3803/EnM.2022.1553] [PMCID:PMC9633223] [PMID:36193717]
4. Tallini G, Tuttle RM, Ghossein RA. The History of the Follicular Variant of Papillary Thyroid Carcinoma. J Clin Endocrinol Metab. 2017;102(1):15-22. [DOI:10.1210/jc.2016-2976] [PMID:27732333]
5. Kholová I, Haaga E, Ludvik J, Kalfert D, Ludvikova M. Noninvasive Follicular Thyroid Neoplasm with Papillary-like Nuclear Features (NIFTP): Tumour Entity with a Short History. A Review on Challenges in Our Microscopes, Molecular and Ultrasonographic Profile. Diagnostics (Basel). 2022;12(2):250. [DOI:10.3390/diagnostics12020250] [PMCID:PMC8871310] [PMID:35204341]
6. George N, Agarwal A, Kumari N, Agarwal S, Krisnani N, Gupta SK. Molecular Profiling of Follicular Variant of Papillary Thyroid Cancer Reveals Low-Risk Noninvasive Follicular Thyroid Neoplasm with Papillary-Like Nuclear Features: A Paradigm Shift to Reduce Aggressive Treatment of Indolent Tumors. Indian J Endocrinol Metab. 2018;22(3):339-346. [DOI:10.4103/ijem.IJEM_86_18] [PMCID:PMC6063167] [PMID:30090725]
7. Baloch ZW, LiVolsi VA. Encapsulated follicular variant of papillary thyroid carcinoma with bone metastases. Mod Pathol. 2000;13(8):861-865. [DOI:10.1038/modpathol.3880153] [PMID:10955452]
8. Valderrabano P, McIver B. Evaluation and Management of Indeterminate Thyroid Nodules: The Revolution of Risk Stratification Beyond Cytological Diagnosis. Cancer Control. 2017;24(5):1073274817729231. [DOI:10.1177/1073274817729231] [PMCID:PMC5937245] [PMID:28975825]
9. Ringel MD, Sosa JA, Baloch Z, Bischoff L, Bloom G, Brent GA, et al. 2025 American Thyroid Association Management Guidelines for Adult Patients with Differentiated Thyroid Cancer. Thyroid. 2025;35(8):841-985. Erratum in: Thyroid. 2025;35(11):841-985. [DOI:10.1177/10507256251363120] [PMCID:PMC13090833] [PMID:40844370]
10. Xu B, Teplov A, Ibrahim K, Inoue T, Stueben B, Katabi N, et al. Detection and assessment of capsular invasion, vascular invasion and lymph node metastasis volume in thyroid carcinoma using microCT scanning of paraffin tissue blocks (3D whole block imaging): a proof of concept. Mod Pathol. 2020;33(12):2449-2457. [DOI:10.1038/s41379-020-0605-1] [PMCID:PMC7688566] [PMID:32616872]
11. Aburjania Z, Jang S, Montemayor-Garcia C, Lloyd RV, Schneider DF, Sippel RS, et al. Encapsulated follicular variant of papillary thyroid cancer: are these tumors really benign?. J Surg Res. 2017;216:138-142. [DOI:10.1016/j.jss.2017.04.020] [PMCID:PMC5608032] [PMID:28807198]
12. Ganly I, Wang L, Tuttle RM, Katabi N, Ceballos GA, Harach HR, et al. Invasion rather than nuclear features correlates with outcome in encapsulated follicular tumors: further evidence for the reclassification of the encapsulated papillary thyroid carcinoma follicular variant. Hum Pathol. 2015;46(5):657-664. [DOI:10.1016/j.humpath.2015.01.010] [PMCID:PMC4981329] [PMID:25721865]
13. Dong Y, Tang F, Hu J, Zhang J. The diagnostic and therapeutic process of invasive encapsulated follicular variant of papillary thyroid carcinoma with lung metastasis: a case report. Am J Transl Res. 2025;17(5):3560-3564. [DOI:10.62347/LROE2153] [PMCID:PMC12170433] [PMID:40535669]
14. Jin S, Xie L, Zhang G, Liu L, Xia K, Liu H, et al. Prognosis of invasive encapsulated follicular variant and classical papillary thyroid carcinoma: a propensity score-matched study using the SEER database. Sci Rep. 2025;15(1):413. [DOI:10.1038/s41598-024-84425-w] [PMCID:PMC11696095] [PMID:39747560]
15. Haugen BR, Alexander EK, Bible KC, Doherty GM, Mandel SJ, Nikiforov YE, et al. 2015 American Thyroid Association Management Guidelines for Adult Patients with Thyroid Nodules and Differentiated Thyroid Cancer: The American Thyroid Association Guidelines Task Force on Thyroid Nodules and Differentiated Thyroid Cancer. Thyroid. 2016;26(1):1-133. [DOI:10.1089/thy.2015.0020] [PMCID:PMC4739132] [PMID:26462967]