Iran J Pathol. 2027;22(1):42–50 | ISSN 2345-3656 | MAIN SUBJECTS Hematopathology

p53 Immunohistochemical Expression in Non-M3 Acute Myeloid Leukemia and Its Association with Induction Response and One-Year Outcomes

Muhammad Ishaque Faizee[1], Farid Kosari[2], Dorsa Ghasemi[1], Fatemeh Nili[1], Salma Sefidbakht[2], Fereshteh Ameli[1]*

1. Department of Pathology, Cancer Institute, Imam Khomeini Complex Hospital, Tehran University of Medical Sciences, Tehran, Iran
2. Department of Pathology, Shariati Hospital, Tehran University of Medical Sciences, Tehran, Iran

RECEIVED 09 Jul 2026 ACCEPTED 26 Sep 2026 PUBLISHED ONLINE 14 Oct 2026 DOI 10.22034/ijp.2026.2088774.3689

ABSTRACT

Background & Objective: TP53 alterations define a high-risk molecular subset of acute myeloid leukemia (AML) and are associated with chemoresistance and poor survival. Because molecular testing is not universally available, p53 immunohistochemistry (IHC) has been proposed as an indicator of possible TP53 pathway abnormalities. This study evaluated the frequency of abnormal p53 IHC expression patterns and their association with induction response and 1-year clinical outcomes in non-M3 AML.

Methods: This retrospective exploratory cohort study included 50 adults with newly diagnosed non-M3 AML and complete 1-year follow-up. p53 expression was assessed by IHC and classified as abnormal patterns (overexpression or null pattern) or wild-type staining patterns based on predefined criteria. Associations between p53 expression patterns, induction response, 1-year overall survival, relapse, FAB subtype, and ELN cytogenetic risk category were analyzed.

Results: Abnormal p53 IHC expression patterns were identified in 11 patients (22.0%), including diffuse nuclear overexpression in 7 (14.0%) and a null staining pattern in 4 (8.0%). No statistically significant associations were found between p53 expression patterns and induction response, 1-year overall survival, relapse, FAB subtype, or ELN cytogenetic risk category.

Conclusion: Abnormal p53 IHC expression patterns were detected in approximately one-fifth of patients with non-M3 AML but were not significantly associated with short-term clinical outcomes in this cohort. The limited sample size and small number of abnormal cases may have reduced statistical power, and clinically meaningful associations cannot be excluded. Larger studies incorporating molecular TP53 validation are warranted.

KEYWORDS Acute myeloid leukemia, TP53, p53 immunohistochemistry, biomarker, prognosis, overall survival, relapse

Corresponding Information: Fereshteh Ameli, Department of Pathology, Cancer Institute, Imam Khomeini Complex Hospital, Tehran University of Medical Sciences, Tehran, Iran, f-ameli@sina.tums.ac.ir

Copyright © 2027 The Author(s). This is an open-access article distributed under the terms of the CC BY 4.0, which permits unrestricted use, distribution, and reproduction in any medium, provided the original work is properly cited.

INTRODUCTION

Acute myeloid leukemia (AML) is a clonal hematopoietic malignancy characterized by uncontrolled proliferation of myeloid precursor cells and impaired differentiation, leading to bone marrow failure and systemic complications. It is the most common acute leukemia in adults and exhibits marked biological and clinical heterogeneity. Despite substantial advances in diagnostic techniques and therapeutic strategies, clinical outcomes remain highly variable, ranging from long-term remission to primary treatment failure and early mortality (1–3).

The clinical behavior of AML is largely determined by its cytogenetic and molecular landscape. Recurrent chromosomal abnormalities and somatic mutations have become the cornerstone of contemporary AML classification and risk stratification, replacing morphology as the principal determinant of prognosis. Consequently, current European LeukemiaNet (ELN) recommendations integrate cytogenetic and molecular findings to guide therapeutic decision-making and predict clinical outcomes (5–9).

Diagnosis of AML relies on an integrated evaluation of bone marrow morphology, immunophenotyping by flow cytometry, cytogenetic analysis, and molecular testing (10). Acute promyelocytic leukemia (APL) represents a biologically distinct subtype with unique molecular characteristics and highly effective targeted therapy; therefore, it is considered separately from other AML subtypes in both clinical practice and research (1, 2). In contrast, non-APL AML remains associated with substantial morbidity and mortality despite improvements in supportive care, intensive chemotherapy, hematopoietic stem cell transplantation, and, more recently, targeted therapies and venetoclax-based regimens (11–18).

Among the molecular abnormalities associated with adverse prognosis, TP53 alterations represent one of the strongest predictors of treatment resistance and poor survival (5, 6). TP53 encodes a critical tumor suppressor protein involved in DNA damage response, cell-cycle regulation, apoptosis, and

maintenance of genomic stability. TP53 alterations are particularly enriched in therapy-related AML and AML with complex or monosomal karyotypes and are consistently associated with low complete remission rates, resistance to conventional chemotherapy, and lower survival irrespective of treatment modality (19–22).

Although molecular testing remains the gold standard for assessing TP53 status, comprehensive genomic profiling is not universally available, particularly in resource-limited settings. Consequently, immunohistochemical (IHC) assessment of p53 protein expression has emerged as an accessible surrogate approach for identifying potential TP53 pathway abnormalities (23). Missense TP53 mutations may result in protein stabilization with diffuse nuclear overexpression, whereas truncating or frameshift mutations may produce complete loss of detectable staining, giving rise to a null pattern (23). Nevertheless, interpretation of p53 immunohistochemistry remains challenging because wild-type p53 may accumulate in response to cellular stress, while some pathogenic TP53 alterations may produce little or no detectable protein. In addition, copy-number loss and loss of heterozygosity may further influence p53 protein expression (23).

Published studies evaluating p53 immunohistochemistry in AML have reported considerable variability in positivity rates and inconsistent associations with treatment response and survival. Differences in patient populations, antibody clones, technical protocols, scoring systems, positivity thresholds, and the lack of parallel molecular validation have contributed to these discrepant findings. Consequently, the clinical utility of p53 immunohistochemistry as a prognostic or predictive biomarker in non-APL AML remains uncertain.

To address this knowledge gap, we conducted a retrospective exploratory cohort study to determine the frequency of abnormal p53 immunohistochemical expression in adult patients with non-M3 AML and to investigate its association with induction therapy response and 1-year clinical outcomes. By correlating p53 staining patterns with clinicopathologic characteristics, we sought to clarify the potential utility and limitations of p53 immunohistochemistry as an indicator of possible TP53 pathway abnormalities in routine clinical practice.

METHODS

Study Design and Study Cohort

This retrospective exploratory cohort study was conducted at Imam Khomeini Hospital Complex and Shariati Hospital, Tehran University of Medical Sciences, Tehran, Iran. Adult patients (≥18 years) diagnosed with non-acute promyelocytic acute myeloid leukemia (non-M3 AML) between January 2021 and December 2024 were screened for eligibility.

During the study period, 300 consecutive adult patients with non-M3 AML were identified. Because this retrospective study required complete clinicopathologic characterization and reliable outcome assessment, only patients with available diagnostic formalin-fixed paraffin-embedded (FFPE) bone marrow tissue, complete morphologic evaluation, flow cytometric immunophenotyping, cytogenetic analysis, treatment records, and 1-year clinical follow-up were eligible for inclusion. Based on these predefined eligibility criteria, 50 patients constituted the final study cohort.

AML diagnosis was established using routine morphologic examination, flow cytometric immunophenotyping, cytogenetic evaluation, and available molecular studies according to contemporary diagnostic recommendations. Immunohistochemical evaluation of p53 was performed retrospectively on archived diagnostic bone marrow specimens for research purposes and was not part of the routine diagnostic workup.

Inclusion Criteria

Patients were eligible for inclusion if they:

were ≥18 years of age;

had newly diagnosed non-M3 AML;

had a complete diagnostic evaluation, including morphology, flow cytometry, cytogenetic analysis, and available clinical records;

received induction therapy according to institutional treatment protocols; and

had available archived FFPE bone marrow tissue together with 1-year clinical follow-up.

Exclusion Criteria

Patients were excluded if they:

had acute promyelocytic leukemia (AML-M3);

were younger than 18 years;

had incomplete clinical, pathological, flow cytometric, cytogenetic, treatment, or follow-up data;

received low-intensity induction therapy;

were lost to follow-up within 1 year after diagnosis;

had concurrent active malignancy;

were pregnant or lactating;

had isolated myeloid sarcoma without bone marrow involvement; or

had an uncertain diagnosis after clinicopathologic review.

Clinical and Pathological Data Collection

Clinical and pathological information was retrospectively extracted from institutional medical records and pathology archives.

Clinical variables included age at diagnosis, sex, AML subtype, induction chemotherapy regimen, treatment response, 1-year overall survival, and relapse status. Treatment response was retrospectively classified according to the European LeukemiaNet (ELN) 2022 response criteria and categorized as complete remission (CR), complete remission with incomplete hematologic recovery (CRi), or treatment failure. Complete remission was defined according to ELN criteria as achievement of a morphologic leukemia-free state with a bone marrow blast percentage below 5%, absence of circulating blasts and extramedullary disease, together with hematologic recovery when applicable.

Pathological variables included bone marrow morphology, blast percentage, lineage assessment, flow cytometric immunophenotype, cytogenetic abnormalities, and available molecular genetic findings.

Immunohistochemistry

Archived FFPE bone marrow biopsy and clot-section specimens obtained at diagnosis were sectioned at 4 µm and mounted on positively charged glass slides. Specimens demonstrating marked fixation artifacts, prolonged fixation (>48 hours), extensive decalcification-related artifacts, or insufficient evaluable leukemic tissue were excluded from immunohistochemical analysis.

Manual immunohistochemical staining was performed using a mouse monoclonal anti-human p53 antibody (GeneAb™, GenomeMe, clone IHC053) at a working dilution of 1:200.

Antigen retrieval was performed manually using Tris buffer (pH 7.3–7.7) according to the manufacturer's recommended protocol. Immunoreactivity was detected using the UltraView DAB detection system with 3,3′-diaminobenzidine (DAB) as the chromogen, followed by hematoxylin counterstaining.

High-grade serous ovarian carcinoma served as the external positive control. Negative controls were prepared by omission of the primary antibody. Non-neoplastic bone marrow stromal cells served as internal positive controls and were expected to demonstrate weak, patchy nuclear staining. Cases lacking adequate internal positive control staining were considered noninterpretable and were excluded from final scoring.

Interpretation of p53 Immunostaining

Only nuclear staining within leukemic blasts was evaluated. Cytoplasmic staining, nonspecific background staining, and staining of non-neoplastic hematopoietic cells were not considered for interpretation.

Abnormal p53 immunohistochemical expression patterns were defined according to previously published criteria (24, 25) as either:

strong, diffuse nuclear staining with moderate-to-strong intensity (2–3+) involving >10% of leukemic blasts or >10 leukemic blasts per ×400 high-power field (HPF) (overexpression pattern); or

complete absence of nuclear staining in leukemic blasts in the presence of preserved nuclear staining in internal positive control cells (null pattern).

A semiquantitative scoring system was applied as follows:

Score 0: Complete absence of nuclear staining in leukemic blasts with preserved staining in internal positive control cells, or 0–1 cell with weak (1+) staining per ×400 HPF (null pattern).

Score 1: Weak, scattered nuclear staining in leukemic blasts, or 1–5 cells with strong (2–3+) staining per ×400 HPF (wild-type staining pattern).

Score 2: Moderate, focal nuclear staining involving ≤10% of leukemic blasts, or 5–10 cells with strong (2–3+) staining per ×400 HPF (wild-type staining pattern).

Score 3: Moderate-to-strong, diffuse nuclear staining involving >10% of leukemic blasts, or more than 10 cells with strong (2–3+) staining per ×400 HPF (overexpression pattern).

For statistical analysis, Scores 1 and 2 were classified as wild-type staining patterns, whereas Scores 0 and 3 were classified as abnormal p53 immunohistochemical expression patterns. Scores 0 and 3 were categorized as abnormal p53 immunohistochemical expression patterns because complete absence of nuclear staining (null pattern) and diffuse, strong nuclear accumulation have been associated with possible underlying TP53 abnormalities in previous studies. Cases lacking adequate internal positive control staining were considered noninterpretable and were excluded from final scoring.

Scores 1 and 2 were classified as wild-type staining patterns, representing low-level or heterogeneous intermediate staining patterns generally observed with preserved p53 regulatory function. However, this classification represents an immunohistochemical interpretation approach and does not imply direct confirmation of TP53 mutations.

The p53 immunohistochemical scoring system used in this study was adapted from previously described criteria for the interpretation of p53 expression patterns in hematologic malignancies and solid tumors. Although similar approaches have been applied in AML cohorts, p53 IHC remains an indirect assessment of TP53 pathway abnormalities rather than a direct molecular evaluation. Therefore, staining patterns were interpreted cautiously and in conjunction with available cytogenetic and clinical findings.

All immunostained slides were independently reviewed by two board-certified hematopathologists who were blinded to all clinicopathologic variables and clinical outcomes. Discordant interpretations were resolved by simultaneous review using a multiheaded microscope until consensus was achieved. A third senior hematopathologist subsequently confirmed the final classification of all cases. Cohen's kappa coefficient was not calculated because the final interpretation used for analysis was based on consensus review rather than independent categorical assessments.

Clinical Outcome Assessment

Clinical outcomes were assessed during a 1-year follow-up period after AML diagnosis. Induction response was assessed according to the ELN response criteria. Complete remission was defined as achievement of a morphologic leukemia-free state with a bone marrow blast percentage below 5%, absence of circulating blasts and extramedullary disease, together with recovery of peripheral blood counts. Response assessment was performed after induction therapy based on bone marrow examination, laboratory findings, and clinical documentation.

Overall survival was defined as the time from AML diagnosis to death from any cause or the last documented follow-up. One-year overall survival was determined based on survival status at 12 months after diagnosis. Relapse was defined as recurrence of leukemia after achievement of complete remission according to established AML response criteria. Clinical outcomes were determined through review of medical records, laboratory findings, and follow-up documentation.

Statistical Analysis

Statistical analyses were performed using IBM SPSS Statistics version 28.0 (IBM Corp., Armonk, NY, USA).

Categorical variables were summarized as frequencies and percentages. Associations between p53 immunohistochemical expression patterns and clinicopathologic variables were analyzed using Pearson's chi-square test or Fisher's exact test, as appropriate. Fisher's exact test was applied whenever the expected cell count was fewer than five.

All statistical tests were two-sided, and a P value <0.05 was considered statistically significant.

Because this was a retrospective exploratory study based on the availability of complete clinicopathologic information and archived tissue specimens, no formal sample size calculation was performed.

Due to the exploratory nature of the study and the limited sample size, multivariable regression analyses were not performed. Associations between p53 immunohistochemical expression patterns and clinical outcomes were evaluated using appropriate univariate statistical tests. Potential confounding effects of age, baseline disease characteristics, cytogenetic risk category, and treatment-related factors were considered during interpretation of the results.

RESULTS

Baseline Clinicopathologic Characteristics

The study cohort consisted of 50 adult patients with newly diagnosed non-M3 AML. The mean age was 37.1 ± 12.1 years (range, 18–65 years), and 32 patients (64.0%) were male.

The predominant FAB subtypes were M1 and M4 (30.0% each), followed by M2 (26.0%), M5 (10.0%), M5b (2.0%), and M7 (2.0%) (Table 1). The mean bone marrow blast percentage at diagnosis was 69.7 ± 24.0%.

Table 1. AML Distribution of FAB Subtypes

	Frequency	Percent
M1	15	30.0
M2	13	26.0
M4	15	30.0
M5	5	10.0
M5b	1	2.0
M7	1	2.0
Total	50	100.0

According to the ELN 2022 risk classification (9), 38.0% of patients were categorized as favorable risk, 36.0% as intermediate risk, and 16.0% as adverse risk, whereas cytogenetic risk stratification was unavailable in 10.0% of cases.

Treatment and Response

Most patients (47/50, 94.0%) received standard 7+3 induction therapy (Table 2). Among the 47 patients receiving standard 7+3 induction therapy, 32 (68.1%) had no primary refractory disease, whereas 15 (31.9%) had primary refractory disease. At 1-year follow-up, relapse occurred in 15 patients (30.0%), and 8 patients (16.0%) had died.

Table 2. Distribution of Induction Therapy Regimens

Induction regimen	n (%)
7+3	47 (94.0)
7+3+imatinib	1 (2.0)
Azacitidine	1 (2.0)
V+A	1 (2.0)
Total	50

p53 Immunohistochemical Expression Patterns

Abnormal p53 immunohistochemical expression patterns were identified in 11 of 50 patients (22.0%), whereas the remaining 39 patients (78.0%) exhibited wild-type staining patterns based on immunohistochemical classification. Among the cases with abnormal p53 immunohistochemical expression patterns, 7 (14.0%) demonstrated diffuse, moderate-to-strong nuclear overexpression, whereas 4 (8.0%) showed a complete absence of nuclear staining (null pattern). Wild-type staining patterns consisted of weak, patchy nuclear staining, which was observed in 37 cases (74.0%), as well as moderate, patchy staining, which was noted in 2 cases (4.0%). The distribution of p53 immunohistochemical staining patterns and their corresponding semiquantitative scores are summarized in Table 3. Representative H&E-stained bone marrow sections and corresponding p53 immunostaining patterns are presented in Figures 1-5.

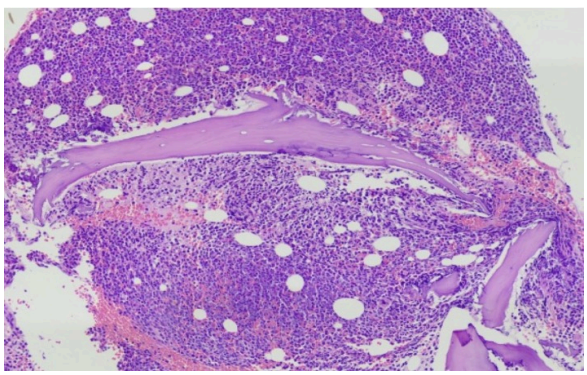

Fig 1. Representative bone marrow biopsy section from a patient with non-M3 acute myeloid leukemia stained with hematoxylin and eosin (H&E), showing diffuse infiltration by leukemic blasts (original magnification ×40).

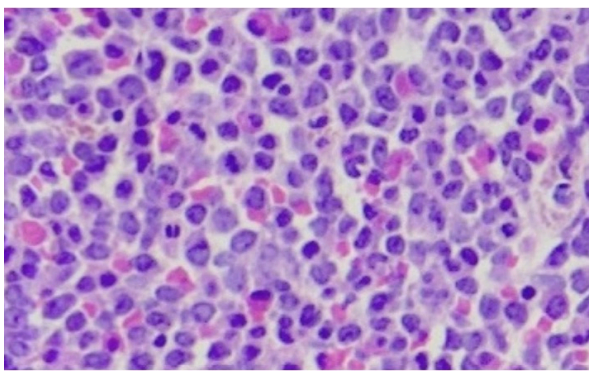

Fig 2. High-power view of the same bone marrow biopsy demonstrating diffuse proliferation of leukemic blasts with a high nuclear-to-cytoplasmic ratio and fine chromatin, stained with hematoxylin and eosin (H&E) (original magnification ×400).

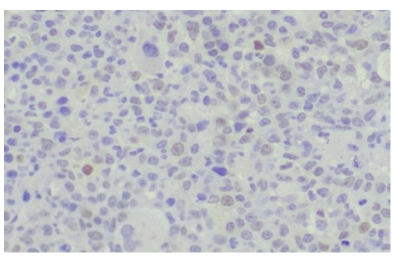

Fig 3. Representative p53 immunohistochemical staining showing weak scattered nuclear staining (Score 1), consistent with the wild-type expression pattern (original magnification ×400).

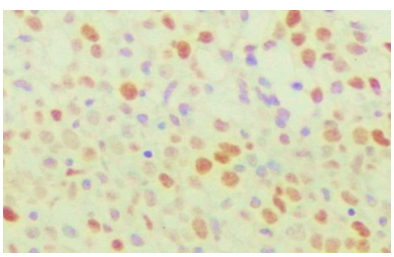

Fig 4. Representative p53 immunohistochemical staining demonstrating diffuse moderate-to-strong nuclear overexpression (Score 3), consistent with the mutant-type expression pattern (original magnification ×400).

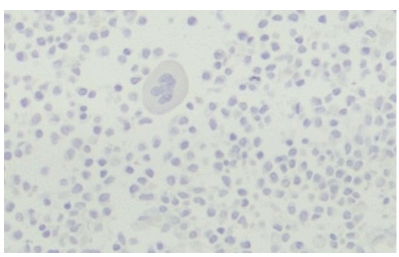

Fig 5. Representative p53 immunohistochemical staining showing complete absence of nuclear staining in leukemic blasts (Score 0, null pattern) (original magnification ×400). Internal positive control staining was confirmed during full-slide evaluation but is not clearly visible in this selected photomicrograph.

Table 4. Association Between p53 Immunohistochemical Expression and Adverse Cytogenetic Risk

p53 IHC expression	Non-adverse cytogenetic risk	Adverse cytogenetic risk	P value
Wild-type	31	8	0.174
Mutant-type	11	0	

The p-value was calculated using Fisher's exact test.

Table 3. Distribution and Semi-quantitative Scoring of p53 Immunohistochemical Expression

p53 IHC Pattern	Score	n (%)
Null pattern (mutant type)	0	4 (8.0)
Weak scattered (wild-type)	1	37 (74.0)
Moderate focal (wild-type)	2	2 (4.0)
Diffuse overexpression (mutant type)	3	7 (14.0)
Total		50 (100)

p53 Expression and Adverse Cytogenetic Risk

According to the ELN 2022 risk classification (9), 8 patients (16.0%) were categorized as having adverse cytogenetic risk. None of these patients demonstrated abnormal p53 immunohistochemical expression patterns. No statistically significant association was observed between p53 immunohistochemical expression patterns and adverse cytogenetic risk (Fisher's exact test, P = 0.174) (Table 4).

Association Between p53 Immunohistochemical Expression and Clinical Outcomes

Forty-seven of the 50 patients received standard 7+3 induction chemotherapy and were included in the analysis of induction treatment response. The remaining 3 patients received alternative induction regimens and were excluded from this analysis. No statistically significant association was observed between p53 immunohistochemical expression patterns and induction treatment response (Fisher's exact test, P > 0.999).

One-year overall survival and relapse outcomes were analyzed in relation to p53 immunohistochemical expression patterns. No statistically significant association was observed between p53 immunohistochemical expression patterns and 1-year overall survival or relapse (all P > 0.999). The associations between p53 immunohistochemical expression patterns and clinical outcomes are summarized in Table 5.

P-values were calculated using Fisher's exact test.

Association Between p53 Immunohistochemical Expression and FAB Classification

AML cases were classified according to the FAB system. Because only 1 case was classified as M5b, this subtype was combined with the M5 category for statistical analysis. No statistically significant association was observed between p53 immunohistochemical expression patterns and FAB subtype distribution (P = 0.576) (Table 6).

Association Between p53 Immunohistochemical Expression and Flow Cytometric Classification

p53 immunohistochemical expression patterns were further analyzed in relation to flow cytometric AML classification. No statistically significant association was observed between p53 immunohistochemical expression patterns and flow cytometric AML subtype (P = 0.550) (Table 7).

Concordance Between FAB Morphology and Flow Cytometric Classification

Concordance between FAB morphology and flow cytometric classification was observed in 36 of 50 cases (72.0%). Overall

Table 5. Association Between p53 Immunohistochemical Expression and Clinical Outcomes

Outcome	Wild-type p53	Mutant-type p53	P value
Response to standard 7+3 induction therapy, n = 47			
Primary refractory disease: No	24	8	
Primary refractory disease: Yes	12	3	>0.999
One-year overall survival, <35 years			
Alive	17	7	
Deceased	2	0	>0.999
One-year overall survival, ≥35 years			
Alive	15	3	
Deceased	5	1	>0.999
Relapse, <35 years			
No relapse	11	5	
Relapse	7	2	>0.999
Relapse, ≥35 years			
No relapse	14	3	
Relapse	6	1	>0.999

Table 6. Association Between p53 Immunohistochemical Expression and FAB Classification

p53 immunohistochemical expression	M1	M2	M4	M5	M7	P value
Wild-type	11	12	10	5	1	0.576
Mutant-type	4	1	5	1	0	

M5 includes one case originally classified as M5b.

Table 7. Association Between p53 Immunohistochemical Expression and Flow Cytometric AML Classification

p53 immunohistochemical expression	M1	M2	M4	M5	NS	P value
Wild-type	10	15	7	5	1	0.550
Mutant-type	4	2	4	1	0	

NS, not specified. The p-value was calculated using the chi-square test. One patient with unavailable flow cytometric classification was excluded from this analysis (n = 49).

Table 8. Agreement Between FAB Morphologic and Flow Cytometric Classification of AML

		Flow cytometric classification							
		NA	M1	M2	M4	M4Eo	M5	M5b	NS
AML Subtype (FAB Classification)	M1	0	11	3	1	0	0	0	0
	M2	1	2	10	0	0	0	0	0
	M4	0	1	3	9	1	0	0	1
	M5	0	0	0	0	0	5	0	0
	M5b	0	0	0	0	0	0	1	0
	M7	0	0	1	0	0	0	0	0

NA, not available; NS, not specified; M4Eo, acute myelomonocytic leukemia with eosinophilia; M5b, acute monoblastic/monocytic leukemia subtype.

Table 9. Association Between Flow Cytometric AML Classification and Cytogenetic Risk Category

Flow cytometric classification	Intermediate	Favorable	Adverse	P value
Normal / Not specified	1	1	0	0.786
M1	9	2	3	
M2	11	4	2	
M4	7	4	0	
M5	4	1	1	

The p-value was calculated using the chi-square test.

agreement between the two classification methods was moderate (κ = 0.476, P < 0.001) (Table 8).

Association Between Flow Cytometric Classification and Cytogenetic Risk Category

No statistically significant association was observed between flow cytometric AML classification and cytogenetic risk category after combining M4/M4Eo and M5/M5b subtypes and grouping normal with not-specified cytogenetic findings (P = 0.786) (Table 9).

DISCUSSION

In the present study, abnormal p53 immunohistochemical expression patterns were identified in 22.0% of adults with newly diagnosed non-M3 AML, whereas 78.0% of cases demonstrated wild-type staining patterns based on immunohistochemical classification. The observed frequency is comparable with previously reported rates of abnormal p53 immunohistochemical expression in AML, although considerable variation has been described across different studies. This variability is largely attributable to differences in patient populations, disease characteristics, and methodological approaches, particularly with respect to the prevalence of therapy-related AML and AML with complex cytogenetic abnormalities, in which TP53 alterations are substantially more frequent (5, 19, 23). Our findings indicate that abnormal p53 immunohistochemical expression patterns are detectable in a clinically relevant subset of patients with non-M3 AML; however, their clinical significance should be interpreted in conjunction with cytogenetic and molecular findings.

Reported frequencies of abnormal p53 immunohistochemical expression vary considerably among published studies owing to differences in patient populations, disease biology, antibody clones, staining protocols, scoring systems, and positivity thresholds (23, 26, 27). Higher frequencies have generally been reported in cohorts enriched for therapy-related AML, complex karyotypes, or older patients, all of which are associated with a greater prevalence of TP53 alterations (5, 6, 19). These methodological and biological differences should be considered when comparing the prevalence of abnormal p53 immunohistochemical expression across published studies.

An additional finding of the present study was the identification of a p53 null staining pattern in 8% of cases. This pattern, characterized by complete absence of nuclear staining in leukemic blasts despite preserved staining in internal control cells, has been reported to be associated with possible underlying truncating or frameshift TP53 alterations that result in unstable or undetectable protein products (4, 23). However, interpretation of p53 immunohistochemistry remains challenging. Wild-type p53 protein may accumulate transiently in response to cellular stress or DNA damage, producing increased nuclear staining in the absence of a TP53 mutation, whereas certain TP53 alterations may generate little or no detectable protein, resulting in a null staining pattern despite underlying genomic abnormalities (4, 7, 23).

Importantly, abnormal p53 immunohistochemical patterns should be interpreted as suggestive of possible TP53 pathway abnormalities rather than definitive evidence of TP53 mutations. Therefore, although p53 immunohistochemistry provides valuable supportive information in routine diagnostic practice, it should not be considered a substitute for molecular TP53 testing when accurate characterization of TP53 status is required (23).

Our study did not demonstrate a statistically significant association between abnormal p53 immunohistochemical

expression patterns and response to standard 7+3 induction chemotherapy. Similarly, no significant associations were observed between p53 immunohistochemical expression patterns and 1-year overall survival or relapse. Collectively, these findings indicate that p53 immunohistochemical patterns alone were not significantly associated with 1-year clinical outcomes in this exploratory cohort.

These findings appear to differ from those reported in molecular studies evaluating TP53 alterations in AML. TP53-mutated AML has consistently been associated with primary chemoresistance, lower complete remission rates, increased relapse risk, and inferior overall survival (5, 19–21). However, the majority of these investigations evaluated TP53 mutations using molecular techniques, whereas the present study assessed p53 protein expression by immunohistochemistry. Accordingly, direct comparison between molecular studies and immunohistochemical investigations should be interpreted cautiously because protein expression does not invariably reflect the underlying TP53 genotype (23).

Several biological and methodological factors may explain the lack of significant associations observed in our study. First, p53 immunohistochemistry cannot identify all functionally relevant TP53 alterations, and protein expression does not invariably reflect the underlying TP53 genotype. Consequently, discordance between immunohistochemical staining patterns and molecular findings may occur despite standardized interpretation criteria (4, 7, 23). Second, clinical outcomes in AML are determined by the combined effects of multiple genetic, cytogenetic, and patient-related factors rather than TP53 status alone. Therefore, evaluation of a single immunohistochemical biomarker is unlikely to fully capture the biological complexity that influences treatment response and survival (5, 6, 9).

In the present study, no significant association was observed between abnormal p53 immunohistochemical expression patterns and adverse-risk cytogenetic abnormalities according to the ELN classification. This finding appears inconsistent with previous molecular studies demonstrating a strong association between TP53 alterations and adverse-risk AML, particularly in cases with complex or monosomal karyotypes (5, 19, 20). Several factors may explain this discrepancy. First, the limited sample size and the relatively small number of patients with both abnormal p53 expression and adverse-risk cytogenetic features may have reduced the statistical power to detect an association. Second, p53 immunohistochemistry reflects patterns of protein accumulation or absence rather than directly identifying TP53 genomic alterations; therefore, discordance between IHC findings and molecular abnormalities may occur. Moreover, adverse cytogenetic abnormalities represent a heterogeneous group of biological alterations, and their relationship with TP53 abnormalities may not always be captured by IHC-based classification alone. Therefore, this negative finding should be interpreted cautiously and requires confirmation in larger cohorts incorporating molecular TP53 analysis.

No significant association was identified between p53 immunohistochemical expression patterns and FAB subtype in the present study. This finding is biologically plausible because the FAB classification is primarily based on morphologic and cytochemical characteristics, whereas contemporary AML classification and risk stratification rely predominantly on recurrent genetic and molecular abnormalities (9). Although TP53 alterations have been reported more frequently in certain morphologic subtypes, particularly acute erythroid leukemia, these associations have not been consistently demonstrated across the full spectrum of AML (7, 8, 30). In addition, the small number of patients within several FAB subgroups in our cohort limited the ability to detect subtype-specific differences.

Similarly, no significant association was observed between p53 immunohistochemical expression patterns and flow cytometric AML classification. This finding is biologically plausible because flow cytometry primarily supports lineage assignment, disease classification, and measurable residual disease assessment, whereas TP53 alterations represent molecular events that are not necessarily reflected by immunophenotypic characteristics (10). Consequently, the absence of a significant correlation between p53 immunohistochemical expression patterns and flow cytometric subtype is not unexpected and further emphasizes the complementary roles of immunophenotyping, cytogenetics, and molecular testing in the contemporary diagnostic evaluation of AML.

The present study has several strengths. All included patients had newly diagnosed adult non-M3 AML and underwent a comprehensive diagnostic evaluation, including morphologic assessment, flow cytometry, cytogenetic analysis, and p53 immunohistochemistry. In addition, all p53 immunohistochemical slides were independently reviewed by two hematopathologists, with discrepant cases resolved by consensus, thereby minimizing interobserver variability. The use of predefined interpretation criteria and a uniform immunohistochemical protocol further enhanced the reproducibility and internal validity of p53 assessment.

Nevertheless, several limitations should be considered when interpreting the present findings. First, the retrospective study design may have introduced unavoidable selection bias and limited the availability of complete clinical and laboratory data.

Second, the relatively small sample size, particularly the limited number of patients with abnormal p53 immunohistochemical expression patterns, reduced the statistical power to detect clinically meaningful associations, particularly for induction response and survival outcomes. Accordingly, the possibility of a type II error cannot be excluded.

Third, molecular TP53 sequencing was not available, precluding direct comparison between p53 immunohistochemical staining patterns and the underlying TP53 mutation status. Consequently, the diagnostic performance of p53 immunohistochemistry as an indicator of possible TP53 alterations could not be formally evaluated. Therefore, abnormal p53 immunohistochemical patterns in this study should not be interpreted as equivalent to confirmed TP53 genomic alterations.

Although independent review by two hematopathologists and consensus resolution were performed to minimize interpretation variability, formal interobserver agreement analysis was not available and should be considered in future validation studies.

In addition, the limited sample size precluded robust multivariable adjustment for potential confounding factors, including age, baseline disease characteristics, cytogenetic risk groups, and treatment-related variables. Therefore, residual confounding cannot be excluded.

Treatment heterogeneity among the small number of patients who received alternative induction regimens may also have influenced outcome analyses. Finally, the single-center design and the relatively short follow-up period may limit the external validity and generalizability of the present findings, particularly with respect to long-term survival and relapse outcomes.

Despite these limitations, the present study provides clinically relevant information for routine hematopathology practice. In many institutions, particularly in resource-limited settings where comprehensive molecular testing or next-generation sequencing is not routinely available, p53 immunohistochemistry remains an inexpensive, rapid, and widely accessible ancillary technique that may provide supportive evidence of TP53 pathway abnormalities (31). However, the present findings indicate that p53 immunohistochemistry should be interpreted as a complementary diagnostic tool rather than a substitute for molecular TP53 testing when prognostic stratification or therapeutic decision-making is required.

Future prospective multicenter studies incorporating larger patient cohorts, standardized immunohistochemical scoring systems, parallel molecular characterization, and longer clinical follow-up are needed to better define the relationship between p53 immunohistochemical expression patterns, TP53 genomic alterations, and clinical outcomes. Future studies should also evaluate the concordance between p53 immunohistochemical staining patterns and TP53 mutation status using next-generation sequencing in prospectively collected cohorts (32). Integration of p53 immunohistochemistry with contemporary molecular risk stratification may further clarify the role of p53 assessment in modern AML diagnostics.

CONCLUSION

In conclusion, abnormal p53 immunohistochemical expression patterns, including both overexpression and null staining patterns, were observed in 22% of adults with newly diagnosed non-M3 AML. Although no statistically significant associations were identified between p53 immunohistochemical expression patterns and induction treatment response, adverse-risk cytogenetic abnormalities, relapse, or 1-year overall survival in this retrospective, single-center, exploratory cohort, these findings should be interpreted cautiously in view of the limited sample size and the absence of molecular TP53 testing. p53 immunohistochemistry may serve as an ancillary tool for identifying potential TP53 pathway abnormalities but should not be considered a replacement for molecular TP53 assessment. Future prospective multicenter studies integrating immunohistochemistry with comprehensive molecular profiling are needed to further clarify the clinical utility and prognostic significance of p53 assessment in AML.

Funding

Tehran University of Medical Sciences provided financial support for the study.

Conflict of interest

The authors declare no conflict of interest.

Data Availability

The data that support the findings of this study are available from the corresponding author upon reasonable request.

Ethics Approval

The study was approved by the Ethics Committee of Tehran University of Medical Sciences (Approval No. IR.TUMS.IKHC.REC.1404.412) and was conducted in accordance with the ethical principles of the Declaration of Helsinki. Patient identifiers were removed before data extraction to ensure confidentiality. Written informed consent was obtained from all participants before enrollment. Participants were informed of their right to withdraw from the study at any time without affecting their medical care. All data were analyzed anonymously and reported in aggregate.

Authors' Contributions

Conceptualization: F.A. and F.K.; Methodology: F.K. and S.S.; Investigation: M.I.F., F.N., and F.A.; Writing – Original Draft: M.I.F. and D.Gh.; Writing – Review & Editing: D.Gh. and F.A. All authors have read and agreed to the published version of the manuscript.

Acknowledgments

None

Declaration of AI Use

During the preparation of this manuscript, the authors used ChatGPT and Gemini for language editing, improving clarity, and refining the written presentation of the manuscript. The authors have reviewed and revised all AI-assisted content and take full responsibility for the accuracy, integrity, and originality of the published work. Generative AI tools were not used for data analysis, interpretation of results, or generation of scientific conclusions.

REFERENCES

1. Döhner H, Weisdorf DJ, Bloomfield CD. Acute myeloid leukemia. N Engl J Med. 2015;373(12):1136-1152. [DOI:10.1056/NEJMra1406184] [PMCID:PMC9481238] [PMID:26376137]
2. Khwaja A, Bjorkholm M, Gale RE, Levine RL, Jordan CT, Ehninger G, et al. Acute myeloid leukaemia. Nat Rev Dis Primers. 2016;2:16010. [DOI:10.1038/nrdp.2016.10] [PMID:27159408]
3. Siegel RL, Miller KD, Fuchs HE, Jemal A. Cancer statistics, 2022. CA Cancer J Clin. 2022;72(1):7-33. [DOI:10.3322/caac.21708] [PMID:35020204]
4. Juliusson G, Lazarevic V, Hörstedt AS, Hagberg O, Höglund M. Acute myeloid leukemia in the real world: why population-based registries are needed. Blood. 2012;119(17):3890-3899. [DOI:10.1182/blood-2011-12-379008] [PMCID:PMC3358248] [PMID:22383796]
5. Grimwade D, Hills RK, Moorman AV, Walker H, White S, Gourley B, et al. Refinement of cytogenetic classification in acute myeloid leukemia: determination of prognostic significance of rare recurring chromosomal abnormalities among 5876 younger adult patients treated in the United Kingdom Medical Research Council trials. Blood. 2010;116(3):354-365. [DOI:10.1182/blood-2009-11-254441] [PMID:20385793]
6. Papaemmanuil E, Gerstung M, Bullinger L, Gaidzik VI, Paschka P, Roberts ND, et al. Genomic classification and prognosis in acute myeloid leukemia. N Engl J Med. 2016;374(23):2209-2221. [DOI:10.1056/NEJMoa1516192] [PMCID:PMC4979995] [PMID:27276561]
7. Döhner H, Estey E, Grimwade D, Amadori S, Appelbaum FR, Büchner T, et al. Diagnosis and management of AML in adults: 2017 ELN recommendations from an international expert panel. Blood. 2017;129(4):424-447. [DOI:10.1182/blood-2016-08-733196] [PMCID:PMC5291965] [PMID:27895058]
8. Arber DA, Orazi A, Hasserjian R, Thiele J, Borowitz MJ, Le Beau MM, et al. The 2016 revision to the World Health Organization classification of myeloid neoplasms and acute leukemia. Blood. 2016;127(20):2391-2405. [DOI:10.1182/blood-2016-03-643544] [PMID:27069254]

9. Döhner H, Wei AH, Appelbaum FR, Craddock C, DiNardo CD, Dombret H, et al. Diagnosis and management of AML in adults: 2022 recommendations from an international expert panel on behalf of the ELN. Blood. 2022;140(12):1345-1377. [DOI:10.1182/blood.2022016867] [PMID:35797463]

10. Ayala F, Dewar R, Kieran M, Kalluri R. Contribution of bone microenvironment to leukemogenesis and leukemia progression. Leukemia. 2009;23(12):2233-2241. [DOI:10.1038/leu.2009.175] [PMCID:PMC4313556] [PMID:19727127]

11. Estey EH. Acute myeloid leukemia: 2021 update on risk-stratification and management. Am J Hematol. 2020;95(11):1368-1398. [DOI:10.1002/ajh.25975] [PMID:32833263]

12. Oberoi S, Lehrnbecher T, Phillips B, Hitzler J, Ethier MC, Beyene J, et al. Leukapheresis and low-dose chemotherapy do not reduce early mortality in acute myeloid leukemia hyperleukocytosis: a systematic review and meta-analysis. Leuk Res. 2014;38(4):460-468. [DOI:10.1016/j.leukres.2014.01.004] [PMID:24472688]

13. Jongen-Lavrencic M, Grob T, Hanekamp D, Kavelaars FG, Al Hinai A, Zeilemaker A, et al. Molecular minimal residual disease in acute myeloid leukemia. N Engl J Med. 2018;378(13):1189-1199. [DOI:10.1056/NEJMoa1716863] [PMID:29601269]

14. Short NJ, Rytting ME, Cortes JE. Acute myeloid leukaemia. Lancet. 2018;392(10147):593-606. [DOI:10.1016/S0140-6736(18)31041-9] [PMCID:PMC10230947] [PMID:30078459]

15. Estey E, Döhner H. Acute myeloid leukaemia. Lancet. 2006;368(9550):1894-1907. [DOI:10.1016/S0140-6736(06)69780-8] [PMID:17126723]

16. Yates J, Glidewell O, Wiernik P, Cooper MR, Steinberg D, Dosik H, et al. Cytosine arabinoside with daunorubicin or adriamycin for therapy of acute myelocytic leukemia: a CALGB study. Blood. 1982;60(2):454-462. [DOI:10.1182/blood.V60.2.454.454] [PMID:6953986]

17. Cornelissen JJ, Blaise D. Hematopoietic stem cell transplantation for patients with AML in first complete remission. Blood. 2016;127(1):62-70. [DOI:10.1182/blood-2015-07-604546] [PMID:26660427]

18. DiNardo CD, Pratz K, Pullarkat V, Jonas BA, Arellano M, Becker PS, et al. Venetoclax combined with decitabine or azacitidine in treatment-naive, elderly patients with acute myeloid leukemia. Blood. 2019;133(1):7-17. [DOI:10.1182/blood-2018-08-868752] [PMCID:PMC6318429] [PMID:30361262]

19. Bowen D, Groves MJ, Burnett AK, Patel Y, Allen C, Green C, et al. TP53 gene mutation is frequent in patients with acute myeloid leukemia and complex karyotype, and is associated with very poor prognosis. Leukemia. 2009;23(1):203-206. [DOI:10.1038/leu.2008.173] [PMID:18596741]

20. Rücker FG, Schlenk RF, Bullinger L, Kayser S, Teleanu V, Kihm H, et al. TP53 alterations in acute myeloid leukemia with complex karyotype correlate with specific copy number alterations, monosomal karyotype, and dismal outcome. Blood. 2012;119(9):2114-2121. [DOI:10.1182/blood-2011-08-375758] [PMID:22186996]

21. Kim K, Maiti A, Loghavi S, Pourebrahim R, Kadia TM, Rausch CR, et al. Outcomes of TP53-mutant acute myeloid leukemia with decitabine and venetoclax. Cancer. 2021;127(20):3772-3781. [DOI:10.1002/cncr.33689] [PMCID:PMC10462434] [PMID:34255353]

22. Steensma DP, Bejar R, Jaiswal S, Lindsley RC, Sekeres MA, Hasserjian RP, et al. Clonal hematopoiesis of indeterminate potential and its distinction from myelodysplastic syndromes. Blood. 2015;126(1):9-16. [DOI:10.1182/blood-2015-03-631747] [PMCID:PMC4624443] [PMID:25931582]

23. Wong TN, Ramsingh G, Young AL, Miller CA, Touma W, Welch JS, et al. Role of TP53 mutations in the origin and evolution of therapy-related acute myeloid leukaemia. Nature. 2015;518(7540):552-555. [DOI:10.1038/nature13968] [PMCID:PMC4403236] [PMID:25487151]

24. Brar N, Greenberg PL, Wang SA, Bodo J, Hsi ED, Surti U, et al. p53 immunohistochemistry as an ancillary tool for rapid assessment of residual disease in TP53-mutated acute myeloid leukemia and myelodysplastic syndromes. Am J Clin Pathol. 2024;162(3):269-281. [DOI:10.1093/ajcp/aqae034] [PMID:38643353]

25. Fang H, Wang SA, Khoury JD. Pure erythroid leukemia is characterized by biallelic TP53 inactivation and abnormal p53 expression patterns in de novo and secondary cases. Haematologica. 2022;107(9):2232-2237. [DOI:10.3324/haematol.2021.280487] [PMCID:PMC9425316] [PMID:35511670]

26. Yang G, Zhang Y, Tan Y, Xu J, Lu H, Chen Z, et al. Immunohistochemistry screening for TP53 mutation in myeloid neoplasms in AZF-fixed bone marrow biopsies. Pathology. 2024;56(3):404-412. [DOI:10.1016/j.pathol.2023.11.009] [PMID:38341302]

27. Seifert H, Mohr B, Thiede C, Oelschlägel U, Schäkel U, Illmer T, et al. The prognostic impact of 17p (p53) deletion in 2272 adults with acute myeloid leukemia. Leukemia. 2009;23(4):656-663. [DOI:10.1038/leu.2008.375] [PMID:19151774]

28. Tashakori M, Kadia T, Loghavi S, Daver N, Bueso-Ramos C, Borthakur G, et al. TP53 copy number and protein expression inform mutation status across risk categories in acute myeloid leukemia. Blood. 2022;140(1):58-72. [DOI:10.1182/blood.2021013983] [PMCID:PMC9346958] [PMID:35390143]

29. Medinger M, Passweg JR. Acute myeloid leukaemia genomics. Br J Haematol. 2017;179(4):530-542. [DOI:10.1111/bjh.14823] [PMID:28653397]

30. Shallis RM, Wang R, Davidoff A, Ma X, Zeidan AM. Epidemiology of acute myeloid leukemia: Recent progress and enduring challenges. Blood Rev. 2019;36:70-87. [DOI:10.1016/j.blre.2019.04.005] [PMID:31101526]

31. Arber DA, Orazi A, Hasserjian RP, Borowitz MJ, Calvo KR, Kvasnicka HM, et al. International Consensus Classification of Myeloid Neoplasms and Acute Leukemias: integrating morphologic, clinical, and genomic data. Blood. 2022;140(11):1200-1228. [DOI:10.1182/blood.2022015850] [PMCID:PMC9479031] [PMID:35767897]

32. Xiao W, Nardi V, Stein E, Hasserjian RP. A practical approach on the classifications of myeloid neoplasms and acute leukemia: WHO and ICC. J Hematol Oncol. 2024;17(1):56. [DOI:10.1186/s13045-024-01571-4] [PMCID:PMC11287910] [PMID:39075565]