Iran J Pathol. 2027;22(1):35–41 | ISSN 2345-3656 | MAIN SUBJECTS Diagnostic Pathology

Clinicopathological Association of Placental Chorangiosis with Adverse Perinatal Outcomes in Gestational Diabetes Mellitus Pregnancies: An Observational Study

Supriya NovelTony[1]*, Shilpa M Bhimalli[2], Ganga S Pilli[3], Hemalatha K R[4], Prajna K Shetty[5]

1. *Anatomy, KLE Jagadguru Gangadhar Mahaswamigalu Moorusavirmath Medical College and Hospital, Hubballi, KLE Academy of Higher Education and Research Deemed to be University, Belagavi, Karnataka, India- 590010, Medicine*
2. *Anatomy, J.N Medical College and Hospital, Belagavi, Medicine, KLE Academy of Higher Education and Research Deemed to be University, Belagavi, Karnataka, India- 590010*
3. *Pathology, Zydus Medical College and Hospital, Dahod, Medicine, Shri Govind Guru University, Godhra, Gujarat, India*
4. *Obstetrics and Gynecology, Karnataka Medical College and Research Institute, Hubballi, Medicine, RGUHS, Hubballi, India*
5. *Pathology, KLE Jagadguru Gangadhar Mahaswamigalu Moorusavirmath Medical College and Hospital, Hubballi, KLE Academy of Higher Education and Research Deemed to be University, Belagavi, Karnataka, India- 590010, Medicine*

RECEIVED 30 May 2026 ACCEPTED 13 Jul 2026 PUBLISHED ONLINE 10 Oct 2026 DOI 10.22034/ijp.2026.2088019.3667

ABSTRACT

Background & Objective: Placental chorangiosis is a common histological lesion in Gestational Diabetes Mellitus (GDM) pregnancies. It is related to increased fetal morbidity and mortality. The study aims to evaluate the prevalence of chorangiosis and its association with placental dimensions and fetomaternal outcomes in term placentas of GDM and control groups.

Methods: This is an observational, comparative cross-sectional study. A total of 120 placentae, 60 each from women with GDM and from women with normal pregnancies without GDM, were included in the current study. Placentas from women other than GDM condition were excluded from the study. The presence of chorangiosis and its clinical association were assessed.

Results: A marked increase in placental chorangiosis was reported in GDM compared with control pregnancies. Chorangiosis-positive placentas were significantly associated with placenta dimensions, adverse fetomaternal outcomes in GDM compared with control group. Binary logistic regression demonstrated GDM status as an independent and significant predictors of chorangiosis occurrence and NICU admission.

Conclusion: The significant prevalence of placental chorangiosis in GDM pregnancies and a marked association of chorangiosis-positive GDM placentas with placental dimensions, maternal conditions, and fetal morbidity might serve as a clinical indicator of chronic fetal hypoxia and fetal morbidity. Comprehensive maternal care in GDM pregnancies can reduce fetal hypoxia, chorangiosis, and adverse pregnancy outcomes. Therefore, postnatal diagnosis of placental chorangiosis should be essentially reported in histopathological evaluation. However, further prospective longitudinal studies are needed to establish predictive validity for type 2 diabetes mellitus risk in GDM women in future pregnancies.

KEYWORDS Placenta size, vascular pathology, glycosylated hemoglobin, NICU admissions

Corresponding Information: Supriya NovelTony, Anatomy, KLE Jagadguru Gangadhar Mahaswamigalu Moorusavirmath Medical College and Hospital, Hubballi, KLE Academy of Higher Education and Research Deemed to be University, Belagavi, Karnataka, India- 590010, Medicine, supriyapremkumar21@gmail.com

Copyright © 2027 The Author(s). This is an open-access article distributed under the terms of the CC BY 4.0, which permits unrestricted use, distribution, and reproduction in any medium, provided the original work is properly cited.

INTRODUCTION

Maternal diabetes exposes the fetus to fetal hypoxia and increases the risk of adverse fetal outcomes (1). Gestational diabetes mellitus (GDM) is known as a variable degree of impaired glucose tolerance detected during pregnancy for the first time (2). The GDM placentas differ from normal placentas by histopathological changes like chorangiosis, villous immaturity, etc. Early onset of maternal diabetes leads to marked structural placental changes, while gestational diabetes developing in late pregnancy produces functional placental alterations (3). Increased glycaemia in GDM conditions might not be the only factor responsible for placental morphological changes, but certain alterations may still continue despite adequate maternal blood glucose levels (4). Vascularity of placental chorionic villi can be assessed for diagnostic purposes. Two to 6 fetal capillaries in terminal villi refers to hypervascularity, whereas extreme villous hypervascularity is known as chorangiosis (5). Placental chorangiosis is an indicator of low-grade chronic fetal hypoxia in association with various placental, maternal, and fetal conditions during maternal diabetes (6, 7). The occurrence of chorangiosis is 5–7% of placentas from newborns admitted to the Neonatal Intensive Care Unit (NICU) (8). Chorangiosis is linked with increased fetal morbidity and mortality, with reported rates of up to 42% (6). However, despite its clinical significance, few studies have assessed the association between placental chorangiosis and fetomaternal outcomes in GDM pregnancies within the Indian

population. Therefore, the present study determines the prevalence of placental chorangiosis and its association with placental size, maternal condition, and fetal outcome in GDM pregnancies and compares the findings with control pregnancies.

METHODS

Study Design and Centre

This is an observational, comparative cross-sectional study carried out at a tertiary care hospital at the Obstetrics and Gynecology Department, Karnataka Medical College and Research Institute (KMC-RI), and Department of Anatomy, KLE JGMM Medical College and Hospital, Hubballi, after approval from the ethics committee with Reg No: ECR/486/Inst/KA/2013/RR-16/04:2023-2024 and the Clinical Trials Registry India (CTRI) No: CTRI/2024/09/073403. Informed consent from mothers was obtained before the collection of placentas.

Study Size

No formal prior sample size calculation was performed for the present study. Placental specimens were collected using convenience sampling based on feasibility. A total of 120 placentae, comprising 60 placentae from GDM and 60 from normal pregnancies, from eligible women fulfilling the inclusion and exclusion criteria delivering at the study centre during the study period of 1 year from September 2024 to September 2025 were collected for the study.

Study Population

One hundred and twenty placentas from women aged between 15 and 50 years, with gestational age of 37–42 weeks and singleton pregnancies, were collected from both vaginal and caesarean deliveries. Sixty placentas from women already diagnosed with GDM, according to institutional diagnostic criteria—Diabetes in Pregnancy Study Group India (DIPSI) (9)—at the study centre who were on dietary modifications, oral hypoglycaemic agents, or insulin therapy were included as the study group. While sixty placentas from healthy women with normal pregnancies without GDM were collected during the same period at the study centre and included as the control group in the study. The placentas from both groups were matched with placental dimensions like weight, diameter, area, and circumference, maternal conditions, and fetal outcomes such as maternal age, maternal weight, gestational age, primigravida, multigravida, vaginal and caesarean deliveries, glycosylated hemoglobin, diet, oral, insulin, fetal weight, Apgar scores at 1 and 5 minutes, appropriate and low birth weight, fetal distress, IUGR, male and female babies, and NICU admissions. The complete maternal and fetal outcomes were available for all the participants. Therefore, there were no missing data. The placentas from women with pregnancies complicated by preeclampsia, overt diabetes, and potential confounding factors like gestational hypertension, maternal anaemia, twin pregnancies, preterm (<37 weeks), and post-term (>42 weeks) deliveries were excluded from the present study.

Gross Examination

The placentas were collected soon after delivery; the membranes of the placentas were trimmed, and the umbilical cord was cut. According to Saha S *et al.* (10) and Pryse-Davies J *et al.* (11), the placentas were subjected to gross examination, including weight, diameter, circumference, and area. A full-thickness tissue sample was obtained within the central two-thirds of the placenta (12). The tissue was fixed in 10% formalin, embedded in paraffin blocks, and 5-µm-thick sections were obtained and stained using hematoxylin and eosin.

Histopathological Examination

Evaluation of chorangiosis was carried out in GDM and control placentas by 2 independent pathologists blinded to the clinical data. Common agreement from both pathologists was noted. The chorangiosis-positive placentas from both the GDM and control groups were then associated with placental dimensions and perinatal outcomes. Chorangiosis is defined as more than 10 fetal capillaries in more than 10 terminal villi, observed in more than 10 microscopic fields from at least 3 random non infarcted placental areas. In contrast, normal terminal villi typically contain no more than 5 fetal capillaries (13).

Statistical Analysis

SPSS software version 25 was used. The outcomes were presented as means, standard deviations, numbers, and percentages. Chi-square test and Fisher exact test were applied to find the association of chorangiosis with perinatal outcomes in placentas of the GDM group and compared with placentas of the control group. The Shapiro-Wilk test was applied to test normality. For the qualitative data, chi-square test and Fisher exact test were performed, and for the quantitative data, independent sample *t* test and Mann-Whitney *U* test were applied. P value < 0.05 was considered statistically significant.

RESULTS

The present study found a significant prevalence of chorangiosis in the GDM placentas compared with the control group (Table 1). The chorangiosis-positive placentas were significantly related to placental dimensions like placental weight, diameter, area, and circumference in the GDM placentas compared with the control group (Table 2). The current study found clinically significant association of chorangiosis-positive placentas with fetomaternal outcomes such as maternal weight, glycosylated hemoglobin, fetal weight, Apgar scores, fetal distress, and NICU admissions in the GDM group compared with the control group (Table 3). Binary logistic regression (Table 4) demonstrated GDM status as an independent and significant predictors of chorangiosis occurrence (Model 1) and NICU admission (Model 2).

Table 1 Demonstrates a statistically significant difference in the prevalence of placental chorangiosis between the GDM and control groups (P = 0.001) (Figs. 1 and 2). Chorangiosis was

Table 1. Chorangiosis in placentas of GDM and control groups.

PARAMETER	GDM (60)	CONTROL (60)	p-value	OR (95% CI)
Chorangiosis	25 (41.7%)	09 (15.0%)	0.001*	4.05 (1.69-9.71)

GDM- Gestational diabetes mellitus. *P value < 0.05 was considered as statistically significant. OR = Odds Ratio; CI = Confidence Interval computed using Woolf logit method.

Table 2. Association of chorangiosis-positive placentas with placental dimensions in GDM and control groups.

PARAMETER	GDM (25)	CONTROL (09)	p-value	Cohen's d (Effect Size)
Placental Weight (g)	518.44 (67.55)	446.89 (111.98)	0.012*	0.88(Large effect)
Placental Diameter (cm)	20.52 (2.86)	14.94 (2.28)	<0.001*	2.05 (Large effect)
Placental Area (cm2)	339.99 (80.49)	176.99 (52.46)	<0.001*	2.19 (Large effect)
Placental Circumference (cm)	64.31 (9.03)	46.95 (7.18)	<0.001*	2.02 (Large effect)

GDM- Gestational diabetes mellitus. *P value < 0.05 was considered as statistically significant. Cohen's d: Small = 0.2–0.49, Medium = 0.5–0.79, Large ≥ 0.80.

Table 3. Association of chorangiosis-positive placentas with fetomaternal outcomes in GDM and control groups.

Fetomaternal outcomes	GDM (25)	CONTROL (09)	p-value	OR (95% CI) / Cohen's d
Maternal Age (Yrs)	27.80 (4.23)	25.44 (2.88)	0.102	0.60 (Medium)
Maternal weight(kg)	71.32 (10.25)	55.00 (5.00)	<0.001*	1.77 (Large)
Gestational age (weeks)	38.16 (0.75)	38.22 (0.67)	0.788	0.08 (Negligible)
Primi gravida	09 (36.0%)	03 (33.3%)	1.000	OR = 1.12 (0.23 - 5.62)
Multi gravida	16 (64.0%)	06 (66.7%)	1.000	OR = 0.89 (0.18 – 4.44)
Vaginal delivery	08 (32.0%)	02 (22.2%)	0.692	OR = 1.65 (0.28 – 9.79)
Caesarean delivery	17 (68.0%)	07 (77.8%)	0.692	OR = 0.61 (0.10 – 3.61)
Glycosylated hemoglobin%	5.30 (0.64)	4.61 (0.59)	0.007*	1.10 (Large)
Diet	17 (68.0%)	-	-	-
Oral	06 (24.0%)	-	-	-
Insulin	02 (8.0%)	-	-	-
Fetal weight (kg)	3.09 (0.66)	2.63 (0.46)	0.027*	0.75 (Medium)
Apgar score at 1min	6.76 (1.59)	8.56 (1.01)	0.008*	1.23 (Large)
Apgar score at 5min	7.48 (1.36)	8.67 (1.00)	0.027*	0.93 (Large)
Appropriate birth weight	19 (76.0%)	09 (100.0%)	0.162	OR = 0.16 (0.01 – 3.11)
Low birth weight	06 (24.0%)	00 (0.0%)	0.162	OR = 6.33 (0.32 – 124.6)
Fetal distress	14 (56.0%)	01 (11.1%)	0.047*	OR = 10.18 (1.10 – 94.1)
IUGR	00 (0.0%)	01 (11.1%)	0.256	OR = 0.11 (0.00 – 2.99)
Male babies	10 (40.0%)	05 (55.6%)	0.462	OR = 0.53 (0.11 – 2.49)
Female babies	15 (60.0%)	04 (44.4%)	0.462	OR = 1.88 (0.40 – 8.74)
NICU admission	20 (80.0%)	02 (22.2%)	0.004*	OR = 14.00 (2.20 – 89.2)

GDM- Gestational diabetes mellitus, IUGR- Intrauterine Growth Retardation, NICU- Neonatal Intensive Care Unit. *P value < 0.05 was considered as statistically significant. OR = Odds Ratio with 95% CI; Variables surviving False Discovery Rate (FDR) correction: Maternal Weight, Glycosylated hemoglobin%, Apgar Score 1 min, and NICU Admission.

Table 4. Binary Logistic Regression

Variable	Beta	Adjusted OR	95% CI	p-value
Model 1: Predictors of Chorangiosis (Outcome = Presence of Chorangiosis; n = 120)				
GDM (vs. Control)	1.358	3.89	1.58-9.57	0.003*
Maternal age	0.041	1.04	0.89-1.22	0.601
Gestational age	-0.107	0.90	0.36-2.21	0.811
Model 2: Predictors of NICU Admission among Chorangiosis-positive cases (n=34)				
GDM (vs. Control)	2.653	14.20	2.10-96.30	0.006*
Maternal Weight	0.063	1.06	0.97-1.17	0.187
HbA1c (%))	0.821	2.27	0.49-10.56	0.294

identified in 25 of the 60 GDM placentas (41.7%), compared with only 9 of the 60 control placentas (15.0%). The odds ratio for chorangiosis in GDM compared with control pregnancies was 4.05 (95% CI, 1.69–9.71), indicating that women with GDM had approximately 4 times greater odds of developing placental chorangiosis relative to women without GDM. The chi-square test and Fisher exact test were applied for the proportions. Values were represented as numbers and percentages.

Table 2 Presents a comparison of placental dimensions between chorangiosis-positive GDM placentas (n = 25) and chorangiosis-positive control placentas (n = 9). All measured placental dimensions—weight, diameter, area, and circumference—were significantly greater in the chorangiosis-positive GDM group compared with the chorangiosis-positive control group, with large effect sizes observed across all parameters.

The exceptionally large effect sizes observed for placental diameter, area, and circumference (d > 2.0) indicate that the differences between chorangiosis-positive GDM and chorangiosis-positive control placentas are not only statistically significant but also clinically meaningful. Quantitative data such as placental weight, diameter, area, and circumference were represented as means and standard deviations. For the

doi:10.22034/ijp.2026.2088019.3667

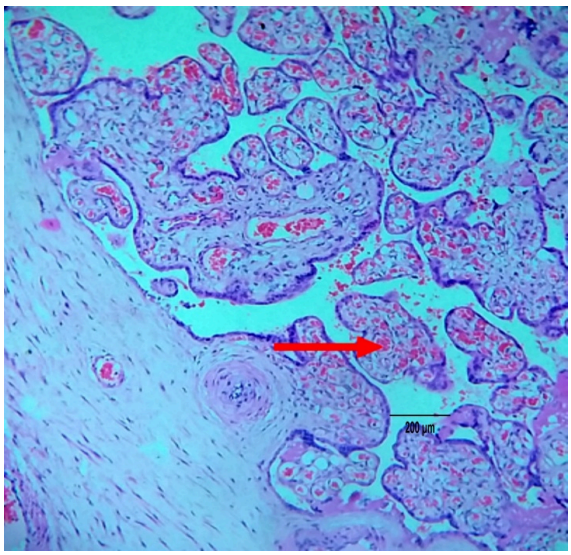

Fig 1. A Photomicrograph of the Gestational Diabetes Mellitus placenta showing chorangiosis (red arrow) within terminal chorionic villi (10x, H&E, Scale bar=200µm)

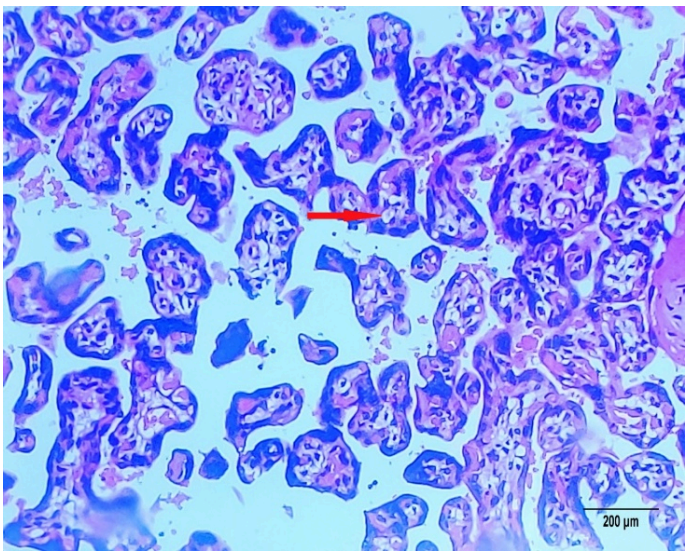

Fig 2. A Photomicrograph of the control placenta showing normal fetal capillaries (red arrow) within terminal chorionic villi (10x, H&E, Scale bar=200µm)

parametric data, an independent-samples *t* test and, for the nonparametric data, the Mann-Whitney *U* test were applied.

Table 3 Presents the fetomaternal outcomes among chorangiosis-positive GDM cases (n = 25) and chorangiosis-positive controls (n = 9). Only significant findings are mentioned. Maternal weight was significantly higher in the GDM chorangiosis compared with the control chorangiosis group (P < 0.001; Cohen's d = 1.77, large effect; BH-adjusted P = 0.009). Glycosylated hemoglobin% was significantly elevated in the GDM chorangiosis compared with controls chorangiosis group (P = 0.007; Cohen's d = 1.10, large effect; BH-adjusted P = 0.036). Fetal weight was higher in the GDM chorangiosis compared with controls chorangiosis group (P = 0.027; Cohen's d = 0.75, medium effect); however, this difference did not survive FDR correction (adjusted P = 0.081) and should be interpreted cautiously. Apgar scores at 1 minute were significantly lower in the GDM chorangiosis compared with the control chorangiosis group (P = 0.008; Cohen's d = 1.23, large effect; BH-adjusted P = 0.036), indicating significantly compromised neonatal adaptation at birth. Apgar scores at 5 minutes were also lower in the GDM group (P = 0.027; Cohen's d = 0.93, large effect); however, this difference did not survive FDR correction (adjusted P = 0.081). Fetal distress was more prevalent in the GDM chorangiosis compared with the control chorangiosis group (OR = 10.18 [95% CI, 1.10–94.1]; P = 0.047); however, after FDR correction, this association did not reach adjusted significance (adjusted P = 0.121). NICU admission was significantly more frequent in the GDM chorangiosis compared with the control chorangiosis group (22.2%) (OR = 14.00 [95% CI, 2.20–89.2]; P = 0.004; BH-adjusted P = 0.036). Table 3 indicates that chorangiosis occurrence in the GDM context is associated with significantly worse neonatal outcomes, particularly with respect to neonatal adaptation at birth (Apgar score at 1 minute) and requirement for NICU admission. No cases of respiratory distress, intrauterine fetal deaths, congenital anomaly, babies with high birth weight, or neurological disorders were found in the present study.

The chi-square test and Fisher exact test were used to determine the association between chorangiosis-positive placentas from both the GDM and control groups with perinatal outcomes. Quantitative data such as maternal age, maternal weight, gestational age, glycosylated hemoglobin, fetal weight, and Apgar scores at 1 minute and 5 minutes were indicated as means and standard deviations. For the parametric data, the independent-samples *t* test and, for the nonparametric data, the Mann-Whitney *U* test were used. Qualitative data such as primigravida, gravida, vaginal and caesarean deliveries, diet, oral, insulin, appropriate birth weight, low birth weight, fetal distress, IUGR, male babies, female babies, and NICU admission were indicated as numbers and percentages.

Table 4 Presents the results of 2 binary logistic regression models examining the independent predictors of chorangiosis occurrence (Model 1) and NICU admission (Model 2).

Model 1: Outcome = presence of chorangiosis; n = 120 placentas (60 GDM + 60 control). Covariates: GDM status, maternal age, gestational age. GDM was independently associated with chorangiosis (adjusted OR = 3.89). Model 1 (β = 1.358) revealed that GDM status was a significant and independent predictor of placental chorangiosis after adjusting for maternal age and gestational age (adjusted OR = 3.89, 95% CI, 1.58–9.57, *P* = 0.003). Neither maternal age (β = 0.041; adjusted OR = 1.04, 95% CI, 0.89–1.22, *P* = 0.601) nor gestational age (β = −0.107; adjusted OR = 0.90, 95% CI, 0.36–2.21, *P* = 0.811) were significant predictors of chorangiosis in the adjusted model. Together, these findings demonstrate that GDM independently contributes to the pathological environment promoting placental chorangiosis, and that this relationship is not confounded by maternal age or gestational age.

Model 2: Outcome = NICU admission; restricted to chorangiosis-positive cases (n = 34: GDM = 25, control = 9). GDM group remained a significant predictor of NICU admission after adjustment. OR = adjusted odds ratio; CI = 95% confidence interval; β = unstandardized logistic regression coefficient. *P* < 0.05. Model 2, demonstrated that GDM group status was a significant independent predictor of NICU admission after

adjustment for maternal weight and HbA1c (adjusted OR = 14.20, 95% CI, 2.10–96.30, P = 0.006; β = 2.653). The large magnitude of this odds ratio underscores the substantially elevated risk of neonatal morbidity among infants born to GDM women with placental chorangiosis compared with non-GDM women with the same placental finding. Maternal weight (β = 0.063; adjusted OR = 1.06, 95% CI, 0.97–1.17, P = 0.187) and HbA1c (β = 0.821; adjusted OR = 2.27, 95% CI, 0.49–10.56, P = 0.294) were not independently significant predictors of NICU admission in the adjusted model, suggesting that the GDM disease state—rather than a single metabolic marker—mediates the elevated risk of adverse neonatal outcomes when chorangiosis is present.

DISCUSSION

GDM is caused by dysfunction of insulin receptors. It may be associated with histomorphological and fetal outcomes (14–16, 1). Maternal disease impacts placental angiogenesis (17). Insufficient supply of oxygen causes intrauterine hypoxia, which influences angiogenesis, resulting in increased capillarization in the chorionic villi and causing harm to the growing fetus (18, 17). Intrauterine hypoxia is related to placental factors and adverse perinatal outcomes (18). Chorangiosis has not been studied extensively, so its cause remains undetermined, but it is believed that chorangiosis develops due to chronic placental hypoperfusion or reduced oxygen supply at the tissue level in combination with placental, maternal, and fetal factors (5, 7). It is seen in term placentas related to enlarged placentas, delayed villous maturation, gestational diabetes, fetal intrauterine growth retardation, low Apgar scores, nervous system injuries, congenital anomalies, and neonatal death (19, 6).

The present study noticed a remarkable increase in chorangiosis in the GDM placentas (Table 1; Fig. 1). Comparable results were observed by Sethy PP *et al.* (20) and Bayramoglu D *et al.* (21) in the GDM placentas. On the contrary to our findings, Rudge MVC *et al.* (22) and Dairi AS *et al.* (23) reported no significant difference between the GDM and control placentas. In our study, women with various treatment modalities among the GDM group (Table 3) gave similar results as those of Molitierno R *et al.* (24) and Natarajan L *et al.* (25).

Murugavel V *et al.* (6) in their study stated that chorangiosis is commonly linked with heavy placentas. The present study found an association of chorangiosis with increased placental weight in the GDM placentas (Table 2). A comparable observation was made by Sethy PP *et al.* (20) and Anjum S *et al.* (16) in GDM placentas, but with no note on its association with chorangiosis. Hiden U *et al.* (26) highlighted that the development of the placenta and fetus is impacted by insulin. Any changes in insulin concentration may result in placental structural alterations. In placentas with diabetes, decreased oxygen transport and increased placental tissue elements cause enlargement of the placental chorionic villi, which may result in increased placental weight (17, 16).

The current study showed an association of chorangiosis with increased placental diameter in the GDM placentas (Table 2). Similar results were found by RafahHadyLateef *et al.* (17) and Karmakar MK *et al.* (27), but without reporting an association of chorangiosis with placental diameter. Anjum S *et al.* (16) in their study stated that increased placental diameter indicates a rise in placental surface area for fetomaternal exchange in GDM placentas.

This study noted that chorangiosis was related to increased placental area in the GDM placentas (Table 2). Comparable findings were reported by Augustine G *et al.* (18) and Elsawy NA *et al.* (28); however, no note on the association of placental area with chorangiosis was reported. In our study, chorangiosis was linked with increased placental circumference in the GDM placentas (Table 2). Alike findings were observed by Karmakar MK *et al.* (27) and Elsawy NA *et al.* (28), but with no report of its association with chorangiosis.

The current study reported a relation of chorangiosis with increased maternal weight in the GDM group (Table 2). Tayel SM *et al.* (29) found a similar association; however, no note of chorangiosis was reported in their study. Whereas, Krstevska SS *et al.* (30) and Alayed N *et al.* (31) recorded no relation between maternal weight and gestational diabetes irrespective of chorangiosis. Kaaja R *et al.* (32) in their study stated that higher maternal body mass is a significant predisposing factor causing GDM. It is unlikely that increased maternal weight may have reflected placental chorangiosis.

Chorangiosis in GDM pregnancies is hypothesized to be caused by insulin and insulin-like growth factor-1 receptor-mediated angiogenesis (25). Our study recorded that chorangiosis was significantly associated with increased glycosylated hemoglobin in the GDM group (Table 3). Edu A *et al.* (33) reported a similar observation but without chorangiosis. Hiden U *et al.* (34) in their study stated that elevated glycaemic blood levels in diabetic mothers lead to decreased arterial oxygen saturation, resulting in a pronounced rise in glycosylated hemoglobin.

Our study observed that chorangiosis was not significantly associated with caesarean deliveries in the GDM group (Table 3). Our findings are consistent with the report of Alayed N *et al.* (31). Our study also found that chorangiosis was associated with elevated fetal birth weight in the GDM group (Table 3). RafahHadyLateef *et al.* (17) and Sethy PP *et al.* (20) found a similar association; however, no relation with chorangiosis was reported. Anjum S *et al.* (16) in their study stated that fetal birth weight may indicate the intrauterine condition experienced by the fetus during development.

The present study found that chorangiosis was associated with decreased Apgar scores at 1 and 5 minutes in the GDM group (Table 3). Similar association was observed by Murugavel V *et al.* (6), Alayed N *et al.* (31), and Dogan Gun B *et al.* (35) in non-GDM placentas. Ogino S *et al.* (36) and Murugavel V *et al.* (6) in their studies stated an association of chorangiosis with immature villi and maternal diabetes (25).

Homogenous placental tissue was recruited from a single tertiary care centre in our study, ensuring consistency in diagnostic criteria and clinical management, which strengthens our findings. A significant prevalence of placental chorangiosis was found in the GDM pregnancies. Chorangiosis-positive placentas were significantly associated with adverse perinatal outcomes in GDM pregnancies. This contrasts with earlier GDM studies in which only the presence of placental chorangiosis was reported. Our study clinically implies that chorangiosis-positive placentas were significantly associated with GDM pregnancies and adverse perinatal outcomes compared with chorangiosis-positive placentas from control pregnancies.

Despite demonstrating significant associations of chorangiosis-positive placentas with placental dimensions and fetomaternal outcomes, our study has several limitations.

Convenience sampling technique, no formal prior sample size calculation, and the cross-sectional study design restrict the ability to establish a causal relationship between observed associations. The relatively smaller sample and residual confounders such as variations in glycemic control and duration of GDM may still persist. The lack of longitudinal neonatal follow-up may affect the reliability of the findings. The subgroup analyses in Tables 2 and 3 compare only chorangiosis-positive cases (GDM n = 25 vs control n = 9), and these small subgroup sizes reduce statistical power for individual comparisons and increase the risk of instability in some P values. Findings from Tables 2 and 3 must be interpreted with caution due to multiple comparisons, and only results surviving FDR correction should be considered robust. Future prospective, multicentric studies with large sample sizes, longitudinal follow-up, and a formal prior sample size calculation are recommended.

CONCLUSION

The current study concludes that significant prevalence of placental chorangiosis in GDM pregnancies and a marked association of chorangiosis-positive GDM placentas with placental dimensions, maternal conditions, and fetal morbidity compared with chorangiosis-positive control placentas might serve as a clinical indicator of chronic fetal hypoxia and fetal morbidity. Comprehensive maternal care in GDM pregnancies can reduce fetal hypoxia, chorangiosis, and adverse pregnancy outcomes. Therefore, postnatal diagnosis of placental chorangiosis should be essentially reported in histopathological evaluation. It provides a pathological basis for retrospective assessment of adverse neonatal outcomes, helps clinicians in planning better management and strategies to improve neonatal care in GDM pregnancies. However, further prospective longitudinal studies are needed to establish predictive validity for type 2 diabetes mellitus risk in GDM women in future pregnancies.

Funding

This research received no specific grant from any funding agency in the public, commercial, or not-for-profit sectors.

Conflict of interest

The authors declare no conflict of interest.

Data Availability

The data that support the findings of this study are available from the corresponding author upon reasonable request

Ethics Approval

This is an observational, comparative cross-sectional study carried out at a tertiary care hospital at the Obstetrics and Gynecology Department, Karnataka Medical College and Research Institute (KMC-RI), and Department of Anatomy, KLE JGMM Medical College and Hospital, Hubballi, after approval from the ethics committee with Reg No: ECR/486/Inst/KA/2013/RR-16/04:2023-2024 and the Clinical Trials Registry India (CTRI) No: CTRI/2024/09/073403. Informed consent from mothers was obtained before the collection of placentas.

Authors' Contributions

Conceptualization: [SN]; Methodology: [SN]; Investigation: [SN]; Writing – Original Draft Preparation: [SN]; Writing – Review & Editing: [SN, SB,GP,HR,PS].

Acknowledgments

We express our gratitude to the mothers who generously provided their placental tissue for this research.

Declaration of AI Use

The authors declare that no generative AI or AI-assisted technologies were used in the writing process of this manuscript.

REFERENCES

1. Madazli R, Tuten A, Calay Z, Uzun H, Uludag S, Ocak V. The incidence of placental abnormalities, maternal and cord plasma malondialdehyde and vascular endothelial growth factor levels in women with gestational diabetes mellitus and nondiabetic controls. Gynecol Obstet Invest. 2008;65(4):227-232. [DOI:10.1159/000113045] [PMID:18196904]
2. Rani PR, Begum J. Screening and diagnosis of gestational diabetes mellitus, where do we stand. J Clin Diagn Res. 2016;10(4):E01-E04. [DOI:10.7860/JCDR/2016/17588.7689] [PMCID:PMC4866200] [PMID:27190902]
3. Ben-Haroush A, Yogev Y, Hod M. Gestational diabetes as one of the "great obstetrical syndromes"--the maternal, placental, and fetal dialog. Best Pract Res Clin Obstet Gynaecol. 2015;29(2):150-155. [DOI:10.1016/j.bpobgyn.2014.04.025] [PMID:25225057]
4. Raj LS, Vasudevan S, Jayalakshmi. A morphological study of placenta in normal and diabetic pregnancies and its foetal implications. Ann Pathol Lab Med. 2019;6(2):113-119. [DOI:10.21276/APALM.2416]
5. Stanek J. Chorangiosis of chorionic villi: what does it really mean?. Arch Pathol Lab Med. 2016;140(6):588-593. [DOI:10.5858/arpa.2015-0160-OA] [PMID:27232351]
6. Murugavel V, Sulochana S, Salin MM. Study of placental chorangiosis in various pregnancy outcomes in a tertiary care centre. Saudi J Pathol Microbiol. 2021;6(10):401-405. [DOI:10.9734/jpri/2021/v33i63b35256]
7. Gupta D, Singh P. Chorangiosis of the placenta: association with maternal profile and neonatal outcome, experience at our centre. JMSCR. 2018;6(2):1184-1187. [DOI:10.18535/jmscr/v6i2.186]
8. Vafaei H, Karimi Z, Akbarzadeh-Jahromi M, Asadian F. Association of placental chorangiosis with pregnancy complication and prenatal outcome: a case-control study. BMC Pregnancy Childbirth. 2021;21(1):99. [DOI:10.1186/s12884-021-03576-0] [PMCID:PMC7847032] [PMID:33516193]
9. Seshiah V, Balaji V, Balaji MS, Sekar A, Sanjeevi CB, Green A. One step procedure for screening and diagnosis of gestational diabetes mellitus. J Obstet Gynecol India. 2005;55(6):525-529.
10. Saha S, Biswas S, Mitra D, Adhikari A, Saha C. Histologic and morphometric study of human placenta in gestational diabetes mellitus. Ital J Anat Embryol. 2014;119(1):1-9. [DOI:10.13128/IJAE-14634] [PMID:25345070]
11. Pryse-Davies J, Beazley JM, Leach G. A study of placental size and chorio-amnionitis in a consecutive series of hospital deliveries. J Obstet Gynaecol Br Commonw. 1973;80(3):246-251. [DOI:10.1111/j.1471-0528.1973.tb02193.x] [PMID:4703264]
12. Khong TY, Mooney EE, Ariel I, Balmus NC, Boyd TK, Brundler MA, et al. Sampling and definitions of placental lesions: Amsterdam Placental Workshop Group consensus statement. Arch Pathol Lab Med. 2016;140(7):698-713. [DOI:10.5858/arpa.2015-0225-CC] [PMID:27223167]
13. Altshuler G. Chorangiosis. An important placental sign of neonatal morbidity and mortality. Arch Pathol Lab Med. 1984;108(1):71-74. [DOI:10.1097/00006254-198408000-00008]

14. Shao J, Catalano PM, Yamashita H, Ruyter I, Smith S, Youngren J, et al. Decreased insulin receptor tyrosine kinase activity and plasma cell membrane glycoprotein-1 overexpression in skeletal muscle from obese women with gestational diabetes mellitus (GDM): evidence for increased serine/threonine phosphorylation in pregnancy and GDM. Diabetes. 2000;49(4):603-610. [DOI:10.2337/diabetes.49.4.603] [PMID:10871198]

15. Dharmalingam M, Murugan T, Rajamani P. Placental abnormalities and neonatal outcomes in gestational diabetes: a case-control study in Northeast Tamil Nadu. SSR Inst Int J Life Sci. 2024;10(5):6145-6154. [DOI:10.21276/SSR-IIJLS.2024.10.5.5]

16. Anjum S. Histomorphological alterations of placenta in normal vs gestational diabetes mellitus subjects: a case-control study. Int J Anat Radiol Surg. 2021;10(4):20-25. [DOI:10.7860/IJARS/2021/48786:2698]

17. Lateef RH, Abdalzahra JM. Placental vasculogenesis and angiogenesis related to GDM and the possible affect on the placenta and the fetus outcome. Medico-Legal Update. 2020;20(4):1962-1969. [DOI:10.37506/mlu.v20i4.2132]

18. Augustine G, Pulikkathodi M, Renjith S, Jithesh TK. A study of placental histological changes in gestational diabetes mellitus on account of fetal hypoxia. Int J Med Sci Public Health. 2016;5(12):2457-2460. [DOI:10.5455/ijmsph.2016.29042016494]

19. Singla S, Kaushik A, Ahluwalia C, Singla G, Mandal AK. Chorangioma with chorangiosis, placenta: a rare entity of clinical significance. Ann Pathol Lab Med. 2016;3(3):146-148.

20. Sethy PP, Ghosh S, Nanda S, Sahu M. Clinicopathological comparison of histopathology of placentae in GDM compared with that of uncomplicated pregnancy and perinatal outcome in GDM mothers in different interventions in pregnancy. J Pharm Negative Results. 2024;31(5):1285-1294.

21. Bayramoglu D, Akdemir C, Ozler S, Bayramoglu Z. The role of immune cells in the placenta of gestational diabetes patients: does it offer hope for targeted treatment?. Arch Gynecol Obstet. 2026;313(1):18. [DOI:10.1007/s00404-025-08289-9] [PMCID:PMC12779683] [PMID:41498786]

22. Rudge MV, Lima CP, Damasceno DC, Sinzato YK, Napoli G, Rudge CV, et al. Histopathological placental lesions in mild gestational hyperglycaemic and diabetic women. Diabetol Metab Syndr. 2011;3(1):19. [DOI:10.1186/1758-5996-3-19] [PMCID:PMC3174871] [PMID:21831283]

23. Dairi AS, Himayda AS, Moulana AA, Bukhari HS, Hakeem IM, Elaraby WG. The effect of gestational diabetes mellitus on the chorionic villi of human placenta among Saudi Arabian mothers: a quantitative and comparative study. Cureus. 2020;12(10):e11130. [DOI:10.7759/cureus.11130] [PMCID:PMC7586374] [PMID:33133792]

24. Molitierno R, Imparato A, Iavazzo N, Salzillo C, Marzullo A, Laganà AS, et al. Microscopic changes and gross morphology of placenta in women affected by gestational diabetes mellitus in dietary treatment: a systematic review. Open Med (Wars). 2025;20(1):20251142. [DOI:10.1515/med-2025-1142] [PMCID:PMC11826244] [PMID:39958976]

25. Natarajan L, Maheswari GU. Gestational hyperglycemia on diet and medication: impact on placental pathology and pregnancy outcomes. Int J Reprod Contracept Obstet Gynecol. 2019;8(8):3350-3356. [DOI:10.18203/2320-1770.ijrcog20193564]

26. Hiden U, Glitzner E, Hartmann M, Desoye G. Insulin and the IGF system in the human placenta of normal and diabetic pregnancies. J Anat. 2009;215(1):60-68. [DOI:10.1111/j.1469-7580.2008.01035.x] [PMCID:PMC2714639] [PMID:19467150]

27. Karmakar MK, Kumar SM, Chattopadhyay SK, Kar S, Vaid LK, Sen S. A study on the morphology and the morphometry of the human placenta and its clinical significance in rural population in Eastern India. Asian Pac J Health Sci. 2018;5(2):202-209. [DOI:10.21276/apjhs.2018.5.2.38]

28. ElSawy NA, Iqbal MS, Alkushi AG. Histomorphological study of placenta in gestational diabetes mellitus. Int J Morphol. 2018;36(2):687-692. [DOI:10.4067/S0717-95022018000200687]

29. Tayel SM, Zaki MG, Metwally ES. Morphometric and structural changes of the placenta of gestational diabetics. Am J Clin Anat Physiol. 2021;3(1):5-9.

30. Krstevska SS, Nakova VV, Samardziski I, Bosku AA, Todorovska I, Sima A, et al. Perinatal outcome in gestational diabetes mellitus vs normoglycemic women. Biomed J Sci Tech Res. 2020;26(2):19882-19888. [DOI:10.26717/BJSTR.2020.26.004338]

31. Alayed N, Arafah MA, Alkhamis WH, Akkour K, Almalki GA, Alomari MA, et al. Placental chorangiosis: clinical risk factors and pregnancy outcomes. Clin Exp Obstet Gynecol. 2024;51(4):79. [DOI:10.31083/j.ceog5104079]

32. Kaaja R, Rönnemaa T. Gestational diabetes: pathogenesis and consequences to mother and offspring. Rev Diabet Stud. 2008;5(4):194-202. [DOI:10.1900/RDS.2008.5.194] [PMCID:PMC2664679] [PMID:19290380]

33. Edu A, Teodorescu C, Dobjanschi CG, Socol ZZ, Teodorescu V, Matei A, et al. Placenta changes in pregnancy with gestational diabetes. Rom J Morphol Embryol. 2016;57(2):507-512.

34. Desoye U, G. The Placenta in Diabetes in Pregnancy. A Practical Manual of Diabetes in Pregnancy. 2010. [DOI:10.1002/9781444315196.ch3]

35. Dogan Gun B, Barut F, Tanriverdi A, Ozdamar SO, Barut A. Placental chorangiosis: an important pattern of placental injury. Gynecol Obstet Reprod Med. 2006;12(3):176-179.

36. Ogino S, Redline RW. Villous capillary lesions of the placenta: distinctions between chorangioma, chorangiomatosis, and chorangiosis. Hum Pathol. 2000;31(8):945-954. [DOI:10.1053/hupa.2000.9036] [PMID:10987255]