Iran J Pathol. 2027;22(1):11–21 | ISSN 2345-3656 | MAIN SUBJECTS GI, Liver & Pancreas Pathology

Assessment of EMT in Colorectal Carcinoma Using E-cadherin, Vimentin, and Oct-4: Correlation with Histological Grade and Regional Lymph Node Metastasis

Alka Yadav[1]*, Shalini Yadav[1], Roopak Aggarwal[1], Anupriya Singh[1], Sharif Ur Rahaman Chowdhury[1], Aakar Bansal[1], Sanjana Singhania[1]

1. Department of Pathology, Uttar Pradesh University of Medical Sciences, Saifai, India

RECEIVED 21 Mar 2026 ACCEPTED 12 Jul 2026 PUBLISHED ONLINE 29 Sep 2026 DOI 10.22034/ijp.2026.2087080.3637

ABSTRACT

Background & Objective: Epithelial–mesenchymal transition (EMT) is a key biological process involved in tumor invasion, progression, and metastasis. In colorectal carcinoma (CRC), EMT-associated alterations such as loss of E-cadherin and gain of Vimentin and Oct-4 expression are linked with aggressive tumor behavior and stemness characteristics. To evaluate the proportion of colorectal carcinomas showing EMT using E-cadherin, Vimentin, and Oct-4 expression and to correlate EMT with histological grade and regional lymph node metastasis.

Methods: This analytical cross-sectional study was conducted in the Department of Pathology, Uttar Pradesh University of Medical Sciences, Saifai, over a 1-year period (January 2025–January 2026). Thirty histologically confirmed cases of colorectal carcinoma were included. Immunohistochemistry for E-cadherin, Vimentin, and Oct-4 was performed on tumor sections. EMT positivity was defined as reduced/lost E-cadherin expression with gain of Vimentin and/or Oct-4 expression. Correlation with tumor grade and lymph node metastasis was analyzed using appropriate statistical tests.

Results: EMT phenotype was observed in a significant proportion of cases. Correlation analysis showed no significant association between Vimentin and Oct-4 expression (P=0.151) or between E-cadherin and Oct-4 expression (P=0.06). However, a significant inverse correlation was noted between E-cadherin and Vimentin expression (P=0.001). Significant association was also observed between altered E-cadherin/Vimentin expression and regional lymph node metastasis as well as higher tumor grades (Grade II and III combined) (P=0.001).

Conclusion: EMT-associated marker alterations correlate with tumor aggressiveness and lymph node metastasis in CRC, highlighting their potential prognostic significance.

KEYWORDS Colorectal Neoplasm, Epithelial–Mesenchymal Transition, E-cadherin, Vimentin, Octamer Binding Transcription -4

Corresponding Information: Alka Yadav, Department of Pathology, Uttar Pradesh University of Medical Sciences, Saifai, India, dr.alkayadav080989@gmail.com

Copyright © 2027 The Author(s). This is an open-access article distributed under the terms of the CC BY 4.0, which permits unrestricted use, distribution, and reproduction in any medium, provided the original work is properly cited.

INTRODUCTION

Colorectal cancer (CRC) remains one of the most prevalent malignancies globally and a principal contributor to cancer-associated deaths (1). Despite advances in early detection and treatment, metastatic CRC presents formidable therapeutic challenges, with a 5-year survival rate of approximately 14% for distant metastases, highlighting an urgent need for innovative interventions (2).

Epithelial-mesenchymal transition (EMT), a dynamic cellular reprogramming process fundamental to embryogenesis and tissue regeneration, promotes tumor dissemination and metastasis when aberrantly activated in cancer (3).

The inherent plasticity of EMT allows tumor cells to adapt to varying microenvironmental challenges during metastasis (4). The heterogeneity of EMT expression patterns across distinct cancer categories underscores its complex role in tumor biology (5), necessitating a comprehensive understanding of its effectors to delineate its precise contributions.

In CRC, EMT has emerged as a central mechanism driving progression and metastasis (6, 7). Evidence indicates EMT is intricately connected to other tumor hallmarks, including stem cell-like properties, metabolic reprogramming, and alterations in the TME (8–10). These interconnected mechanisms synergistically regulate CRC progression and metastatic potential, presenting both challenges and opportunities for therapeutic intervention. Notably, EMT signatures show promise as prognostic biomarkers, particularly concerning circulating tumor cells and metastatic disease (11). Therefore, E-cadherin is expected to be a useful biomarker associated with invasiveness, poor differentiation, and malignant phenotype in CRC.

However, the correlation between the expression of E-cadherin detected by immunohistochemistry and patient survival remains controversial, and the number of cases enrolled in numerous published studies was not large enough. Therefore, it is necessary to analyze the data of E-cadherin systematically in CRC to draw a reasonable conclusion about its prognostic significance.

Epithelial-mesenchymal transition (EMT) is a multistep morphogenetic process during which epithelial cells downregulate their epithelial properties and upregulate mesenchymal characteristics. Namely, static epithelial cells lose cell-to-cell junctions and, as a consequence, they lose apicobasal polarity to become migratory mesenchymal-like cells. This process is therefore aptly called the epithelial-mesenchymal transition, which is currently classified into three subtypes (12).

Type 1 EMT is associated with original embryonic development and also occurs during postnatal growth. Type 2 EMT is initiated by injury and results in the generation of fibroblasts to rebuild wounded tissues (12).

The process of epithelial-mesenchymal transition (EMT) is essential for embryonal development, but it also occurs during the development of epithelial tumors, causing cellular transmigration that eventually leads to metastasis. E-cadherin and vimentin are widely regarded as key markers for EMT (13, 14). E-cadherin, typically expressed in epithelial cells, is a hallmark of the epithelial phenotype, and its loss is associated with EMT (14). On the other hand, vimentin is a mesenchymal marker, and its expression is indicative of the mesenchymal phenotype, which cells acquire during EMT (14, 15). In general, EMT is characterized by a decrease in the function of epithelial markers such as E-cadherin, which plays an important role in epithelial cell adhesion and tissue architecture, and an increase in the expression of mesenchymal markers such as vimentin, which is important for maintaining cell shape and integrity (13). Loss of E-cadherin leads to a loss of epithelial differentiation and the acquisition of motility and an invasive phenotype, and its loss is associated with progression and poor prognosis of CRC, tumor invasiveness, metastases, and increased resistance to apoptosis. The EMT process is mediated and orchestrated by various transcription modulators and a number of signaling intermediates, including mucins that play a significant role in the process of cell differentiation and are associated with the aggressive behavior of metastatic tumor cells (16, 17).

OCT-4 (octamer-binding transcription factor 4) is a nuclear transcription factor of the POU homeodomain family. The acronym POU is derived from the names of three transcription factors: the pituitary-specific Pit-1, the octamer transcription factor proteins Oct-1 and Oct-2, and the neural Unc-86. OCT-4 has a critical role in several aspects of embryonic stem cell (ESC) maintenance, including ESC self-renewal, pluripotency, and lineage commitment (18–20). A transient increase in OCT-4 levels can induce lineage commitment to the primitive endoderm and mesoderm, whereas repression of OCT-4 leads to trophoectoderm differentiation (21, 22). These induced pluripotent stem cells have characteristics similar to ESCs (embryonic stem cells) (23). It was recently proposed that OCT-4 acts as a multifunctional factor during cancer development. In addition, OCT-4 has been detected in germ cell tumors and various human somatic tumors, including hepatoma, breast cancer, and bladder cancer, suggesting that OCT-4 functions in both the embryo and the adult. However, few studies have defined a potential function for OCT-4 in colorectal cancer (24–26). The aim of this study was to study the proportion of colorectal carcinomas showing E-cadherin, vimentin, and OCT-4 expression and their correlation with histological tumor grade and regional lymph node metastases.

MATERIALS AND METHODS

This analytical cross-sectional study was carried out in the Department of Pathology, Uttar Pradesh University of Medical Sciences, Saifai, from January 2025 to January 2026. Institutional Ethics Committee approval and informed consent were obtained to perform this study.

Inclusion and Exclusion Criteria

Patients with colorectal carcinomas who underwent colectomy were included in the study, and biopsies were excluded from the study.

A total of 30 consecutive colectomy specimens histopathologically diagnosed as adenocarcinoma over the past 1 year were included in the study. Clinical details such as age, sex, site, and size of lesion were noted (Table 1). Detailed gross examination (Fig. 1) of the specimen was done. The tissue was routinely processed and stained with hematoxylin and eosin (H&E). Detailed microscopic grading, American Joint Committee on Cancer (AJCC) TNM classification, Astler-Coller modification of Dukes classification, and nodal status were done.

Table 1. Clinicopathological characteristics of the study population

Clinicopathological parameter	Findings
Age	Mean ± SD: 51.56 ± 12.94 years; range: 20–78 years
Sex distribution	Male: 63.33% Female: 36.67%
Side of lesion	Left: 32.33% Right: 67.67%
Size	Mean ± SD: 4.66 ± 1.81
Cut surface	Greyish white: 83% Greyish white with areas of haemorrhage: 10% Soft mucoid cut surface: 7%
Histological grading	Well differentiated: 56% Moderately differentiated: 36% Poorly differentiated: 8%
Lymph node involvement	Positive: 20% Negative: 80%
AJCC stage (TNM)	IIA: 20% IIB: 60% IIIA: 0% IIIB: 10% IIIC: 3% IV: 7%
E-cadherin expression	Loss of expression: 14 cases (46.6%) Positive: 16 cases (53.3%)
Vimentin expression	Positive: 9 cases (30%) Negative: 21 cases (70%)
OCT-4 expression	Positive: 14 cases (46.67%) Negative: 16 cases (53.33%)

E-cadherin, vimentin, and OCT-4 staining was done by immunohistochemistry. Immunohistochemistry was done using a polymer-HRP (horseradish peroxidase) detection kit (Biogenex, USA).

Histological Tumor Grade

Grade I: Cancers are composed mainly of simple tubules, in which the nuclear polarity is easily discerned and the nuclei are of uniform size.

Grade II: Cancers are composed of tubules that may be simple, complex, or slightly irregular, in which the nuclear polarity is barely discernible or is lost.



Fig 1. Photograph of the gross specimen of a case of colonic adenocarcinoma showing a solid gray-white area.

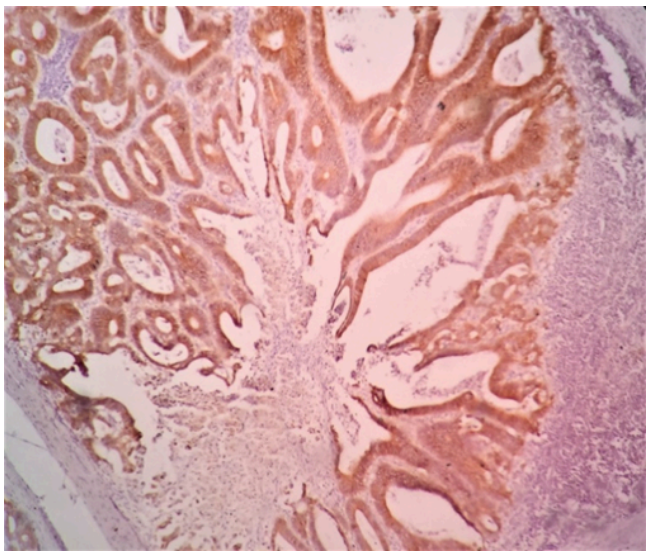

Fig 2. Photomicrograph of a well-differentiated colonic adenocarcinoma case with E-cadherin positivity (combined score of intensity × percentage score of cells showing positivity = 12) (original magnification ×100).

Grade III: Tumors are characterized by a predominance of the absence of glandular differentiation (solid-like pattern), as well as by loss of nuclear polarity.

Scoring of Histological Grade

Grade I (well differentiated): 1

Grade II (moderately differentiated): 2

Grade III (poorly differentiated): 3

Scoring for Lymph Node Metastasis

CASES

Cases with metastasis: 1

Cases without metastasis: 0

Scoring of E-Cadherin Expression

Staining intensity was scored on a scale of 0 to 3:

0 = no staining

1 = weak staining

2 = moderate staining

3 = strong staining

The percentage of positive tumor cells was scored as five subgroups, 0 to 4:

0 = <10% positive tumor cells

1 = 10%–25% positive tumor cells

2 = 25%–75% positive tumor cells

3 = 75% to <100% positive tumor cells

4 = 100% positive tumor cells

Immunoreactive score (IP) = score of intensity × score of percentage of positive tumor cells

A score of 8 or less was considered aberrant expression and was considered loss of E-cadherin expression.

Scoring of Vimentin Expression

Staining intensity was scored on a scale of 0 to 3:

0 = no staining

1 = weak staining

2 = moderate staining

3 = strong staining

The percentage of positive tumor cells was scored on all sections.

Immunoreactive score = percentage of positive cells × staining intensity

A score of more than 30 was considered positive.

Scoring of OCT-4 Expression

Primary Tumor OCT-4 Expression

The level of expression was evaluated using a semiquantitative method with regard to the percentage of positive tumor cells:

score 0 if less than 1% of cells expressed OCT-4

score 1 if at least 1% and less than 10% of cells expressed OCT-4

score 2 if at least 10% of cells expressed OCT-4

Samples scored as 1 and 2 were considered OCT-4 positive, whereas those scoring 0 were considered OCT-4 negative.

Sample size calculation

Sample size was calculated using a prevalence-based formula considering the expected EMT positivity rate of 28% in colorectal carcinoma from previously published studies (27, 28). At a confidence level of 95% and allowable error of 15%, the minimum calculated sample size was approximately 34 cases. Due to limited availability of eligible cases fulfilling inclusion criteria and adequate tissue preservation for immunohistochemistry, 30 cases were included in the final study.

For prevalence-based studies, the common formula is:

$n = Z^2 \times p \times q / d^2$

n = sample size

Z = 1.96 at 95% confidence interval

p = 28%

q = 1 − p = 72%

d = 15%

$n = (1.96)^2 \times 0.28 \times 0.72 / (0.15)^2$

So, the minimum sample size is approximately 34 cases.

Table 2. Comparison of Vimentin and OCT-4 expression in tumor cells

OCT-4 Expression	Vimentin		Total	p value
	Negative	Positive		
Negative	13	3	16	0.151 Not significant
Positive	8	6	14	
Total	21	9	30	
*				

RESULTS

A total of 30 histopathologically confirmed cases of colorectal carcinoma were included during the study period. After complete histopathological examination, immunohistochemical staining of the following markers was done: E-cadherin, vimentin, and OCT-4 antibodies.

Correlation between E-cadherin, vimentin, and OCT-4 expression was also assessed using chi-square analysis. A P value of <0.05 was considered statistically significant. A significant association was observed between E-cadherin and vimentin expression (P = 0.001). In addition, E-cadherin and vimentin expression showed statistically significant correlation with regional lymph node metastasis when Grade I was compared with combined Grades II and III metastasis (P = 0.001). However, the association between OCT-4 and vimentin (P = 0.151), and OCT-4 and E-cadherin (P = 0.06) was not statistically significant.

American Joint Committee on Cancer (AJCC) Stage

TNM staging was done taking tumor size in cm, nodal status, and distant metastasis. Out of 30 colectomy specimens, 6 cases (20%) were categorized as stage IIA, 18 cases (60%) as stage IIB, 3 cases (10%) as stage IIIB, 1 case (3%) as stage IIIC, and 2 cases (7%) as stage IV. No cases were stage 0, I, or IIIA.

Analysis of Markers

Comparison of OCT-4 With Vimentin, E-Cadherin, and Vimentin With E-Cadherin

Comparison of OCT-4 expression with positive vimentin expression (Table 2) by chi-square test yielded a P value of 0.151, which was not statistically significant. Comparing OCT-4 expression with positive E-cadherin expression (Table 3) in tumor cells, the chi-square test yielded a P value of 0.063, which was not statistically significant. However, on comparison of the expression of vimentin and E-cadherin (Table 4), a significant association was seen, with a P value = 0.001.

Statistical Analysis

Statistical analysis was performed using SPSS software version 25 (IBM Corp., Armonk, NY, USA). The expression of E-cadherin, vimentin, and OCT-4 in colorectal carcinoma cases was analyzed and correlated with clinicopathological parameters, including histological grade and regional lymph node metastasis. Categorical variables were expressed as frequencies and percentages. We evaluated the association between immunohistochemical markers and clinicopathological variables using the chi-square test. We applied the Fisher exact test when the expected cell count was less than 5. Correlation between E-cadherin, vimentin, and OCT-4 expression was also assessed using chi-square analysis. A P value of <0.05 was considered statistically significant. We observed a significant association between E-cadherin and vimentin expression (P = 0.001). In addition, E-cadherin and vimentin expression showed statistically significant correlation with regional lymph node metastasis when Grade I was compared with combined Grades II and III metastasis (P = 0.001). However, the association between OCT-4 and vimentin (P = 0.151), and OCT-4 and E-cadherin (P = 0.06) was not statistically significant.

Comparison of E-Cadherin with Histopathological Grade

Histological tumor grading was done in all the cases of colorectal carcinoma. Out of these, 17 (56%) cases were categorized as grade I, 11 (36%) cases as grade II, and 2 (8%) cases as grade III. A comparison of E-cadherin expression with histological tumor grade (Table 5) was found to be statistically significant, with a P value = 0.001.

Out of 30 cases, 20% (6/30) showed regional lymph node metastasis. On comparing regional lymph node metastasis with

Table 3. Comparison of E-Cadherin and OCT-4 expression in tumor cells

OCT-4 Expression	E-Cadherin expression		Total
	Loss of expression	Positive	
Negative	10	6	16
Positive	4	10	14
Total	14	16	30
p-value*	0.063 (Not Significant)		

Table 4. Comparison of E-cadherin and Vimentin expression in tumor cells

Vimentin Expression	E-Cadherin expression		Total
	Negative	Positive	
Negative	14	7	Negative
Positive	0	9	Positive
Total	14	16	Total
p-value*	0.001 9Signficant)		

 doi:10.22034/ijp.2026.2087080.3637

Table 5. Comparison of E-Cadherin expression with histological tumor grade

E- Cadherin expression	Histological tumor grade			Total
	Well differentiated Grade I	Moderately differentiated Grade II	Poorly differentiated Grade III	
Loss of expression	14	0	0	14
Positive	3	11	2	16
Total	17	11	2	30
p-value*	0.001 (Significant)			

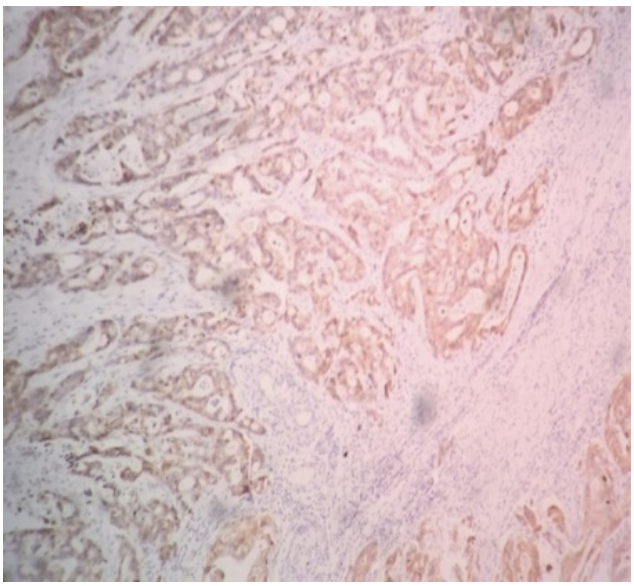

Fig 3. Photomicrograph of a moderately differentiated adenocarcinoma case with marked E-cadherin loss (combined score of intensity × percentage score of cells showing positivity = 3) (original magnification ×400).

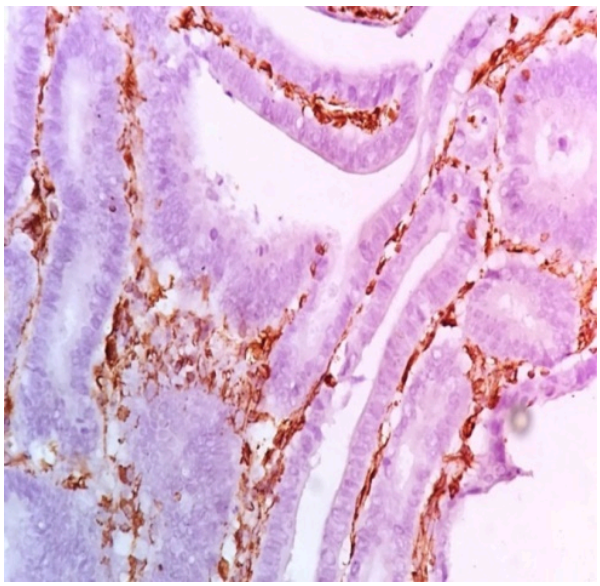

Fig 4. Photomicrograph of moderately differentiated adenocarcinoma with vimentin positivity (combined score of intensity × percentage of cells showing positivity = 30) (DAB, original magnification ×400).

E-cadherin expression (Fig. 2 and Fig. 3), a P value of 0.010 was obtained, which was statistically significant (Table 6).

Comparison of Vimentin with Histopathological Grade

Out of 30 cases, 30% (9/30) showed positive vimentin expression (Fig. 4 and Fig. 5). Of these 9 cases, 1 each was grade I and III, while 7 cases were grade II. Chi-square test was applied to look for an association between histological tumor grade and vimentin expression (Table 6), and it was found to be statistically significant (P value = 0.004).

Comparison of Vimentin With Regional Lymph Node Metastasis

On comparing regional lymph node metastasis with vimentin expression, we found that out of 6 cases with regional lymph node metastasis, 4 cases showed positive staining for vimentin (67%), while 5 cases with no regional metastasis also showed vimentin expression. A statistically significant correlation was found on comparing regional lymph node metastasis with vimentin expression, with a P value = 0.028 (Table 7).

Comparison of OCT-4 With Histopathological Grade

Out of 30 cases, 46.6% (14/30) showed positive OCT-4 expression (Fig. 6 and Fig. 7). Of these, 6 cases were in grades I and II each, while 2 cases were in grade III. Chi-square test was applied to look for an association between histological tumor grade and OCT-4 expression (Table 9), and it was found to be statistically not significant (P value = 0.179).

Comparison of OCT-4 With Regional Lymph Node Metastasis

Out of the 6 cases with regional lymph node metastasis, 4 cases showed positive staining for OCT-4 (67%), while 10 cases having no regional metastasis were also positive for OCT-4 expression. The comparison of regional lymph node metastasis and OCT-4 expression was statistically not significant, with a P value = 0.272 (Table 10).

DISCUSSION

Mean age of patients with colorectal carcinoma (CRC) in our study was 51.56 ± 12.94 years. All 30 cases included in the study

Table 6. Association between E-cadherin expression and regional lymph node metastasis

E- Cadherin expression	Regional lymph node		Total
	Positive	Negative	
Loss of expression	0	14	14
Positive	6	10	16
Total	6	24	30
p value*	0.010 (Significant)		

doi:10.22034/ijp.2026.2087080.3637

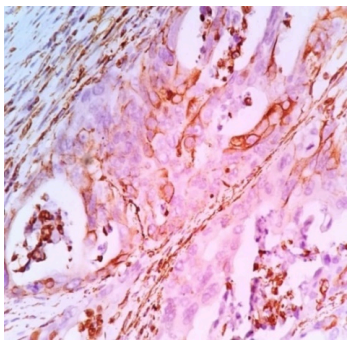

Fig 5. Photomicrograph of a well-differentiated adenocarcinoma case with vimentin negativity (combined score of intensity × percentage of cells showing positivity = 0) (DAB, original magnification ×100).

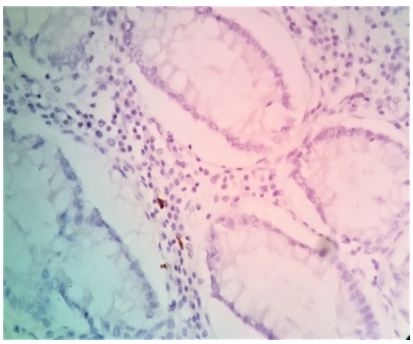

Fig 6. Photomicrograph of another case of moderately differentiated colonic adenocarcinoma with OCT-4 positivity (score = 1) (DAB, original magnification ×100).

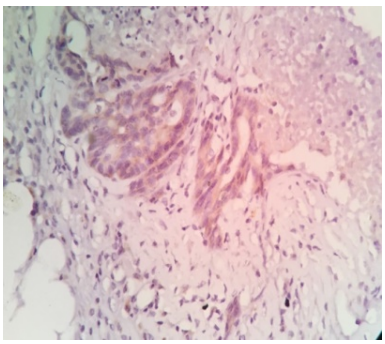

Fig 7. Photomicrograph of a case of well-differentiated colonic adenocarcinoma with OCT-4 negativity (score = 0) (DAB, original magnification ×100).

Table 7. Comparison of Vimentin positive cases with histological tumor grade

Vimentin expression	Regional lymph node		Total
	Positive	Negative	
Negative	16	4	1
Positive	1	7	1
Total	17	11	2
p-value*	0.004 Significant		

Table 8. Comparison of Vimentin expression with regional lymph node metastasis

Vimentin expression	Regional lymph node		Total
	Positive	Negative	
Negative	2	19	21
Positive	4	5	9
Total	6	24	30
p value*	0.028 (Significant)		

Table 9. Comparison of OCT-4 positive cases with histological tumor grade

OCT-4	Histological tumor grade			Total
	Well differentiated Grade I	Moderately differentiated Grade II	Poorly differentiated Grade III	
Negative	11	5	0	16
Positive	6	6	2	14
Total	17	11	2	30
p-value*	0.179 (Not Significant)			

Table 10. Comparison of OCT-4 expression with regional lymph node metastasis

OCT-4	Regional lymph node		Total
	Positive	Negative	
Negative	2	14	16
Positive	4	10	14
Total	6	24	30
p value*	0.272 Not Significant		

underwent colectomy for carcinoma of the colon or rectum and were histopathologically diagnosed as adenocarcinoma.

Out of 30 cases studied by us, 19 cases (63.33%) were males and 11 cases (36.67%) were females. A study conducted by Munesh K Sharma et al. (30) revealed that males constituted 67% of the population with colorectal carcinoma, and the remaining 33% were females. Another study conducted by Rupal Sinha et al. (29) involving 100 cases of CRC found that 77% of these cases were males, and the remaining 23% were females.

In our study of the 30 cases, most of the lesions were right sided, comprising 67% of total cases. Left-sided lesions were seen in 33% of cases. A meta-analytic study conducted by Brungs

D et al. (31) of 9509 cases of CRC reported a right-sided incidence of 53% and left-sided incidence of 47%. Another study conducted by Goh KL et al. (32) of 248 cases of CRC revealed 68.5% right-sided malignancies.

In our study of 30 cases, when the size of the primary tumor was studied, in 53% of cases tumor size was less than 4.5 cm in the largest diameter, and in the remaining 47% of cases it was greater than 4.5 cm in the largest diameter, with a mean of 4.66 ± 1.81.

Kornprat P et al. (33) in their study divided CRC cases into two groups according to size. One was >4.5 cm (group 1), and the other was <4.5 cm (group 2). On analyzing, they found that 44% of their cases were in group 1, and the remaining 56% were in group 2. Another study conducted by Ahmed Ziya Balta et al. (34) involving 439 cases of colorectal carcinoma found that almost 53% of their cases were >4.5 cm, and the remaining 47% were ≤4.5 cm.

In our study, when cut surfaces of the tumors were examined, it was seen that the majority of the specimens 83% of cases, had a grayish-white appearance, followed by grayish white with areas of hemorrhage in 10% of cases, and the least were soft mucoid cut surfaces in 7% of cases.

In our study of 30 adenocarcinoma cases, tumors were graded according to the histological grading system into grade I (well differentiated), grade II (moderately differentiated), and grade III (poorly differentiated). Out of these, 56% of cases were categorized as grade I, 36% of cases as grade II, and 8% of cases as grade III. In the study done by Rupal Sinha et al. (29), they found that the most common tumor grade was grade II (moderately differentiated), accounting for 70% of cases, followed by 23% of cases in grade III and the remaining 7% in grade I. Another study conducted by Ahmed Ziya Balta et al. (34) found 17% well differentiated, 76% moderately differentiated, and 7% poorly differentiated adenocarcinomas in 439 CRC cases.

In our study, TNM staging was applied to all 30 cases. Stage IIA comprised 20% of cases, stage IIB comprised 60% of cases, 10% of cases were stage IIIB, 3% of cases were stage IIIC, and 7% of cases were stage IV. None of the cases was in stage 0, stage I, or stage IIIA. In the study done by Li J et al. (35), 18.94% of cases were in stage I, 39.38% of cases were in stage II, 3.56% of cases were in stage IIIA, 26.88% were in stage IIIB, 6.25% were in stage IIIC, and the remaining 5% were in stage IV.

E-CADHERIN EXPRESSION

Our study showed that loss of E-cadherin expression was seen in 14 (46.67%) cases, with 16 (53.33%) cases showing positive E-cadherin expression.

Correlation of E-cadherin expression with histological tumor grade was done. Out of 17 (57%) cases of well differentiated adenocarcinomas included in our study, positive E-cadherin expression was seen in 14 cases, while 3 cases showed loss of E-cadherin expression. 9 (81.87%) cases of moderately differentiated adenocarcinoma and 2 (100%) cases of poorly differentiated carcinoma showed loss of E-cadherin expression. A correlation of expression of E-cadherin with histological tumor grade was found to be statistically significant (P value <0.05).

E-cadherin expression was also correlated with regional lymph node metastasis. A total of 6 (20%) cases out of 30 studied showed regional lymph node metastasis. Tumor cells showing E-cadherin expression were seen in all cases with regional lymph node metastasis. Correlation of E-cadherin expression with regional lymph node metastasis was found to be statistically significant (P value <0.05).

Histological tumor grading was applied, and out of these, 17 (56%) cases were categorized as grade I, 11 (36%) cases as grade II, and 2 (8%) cases as grade III. Correlation of E-cadherin expression and TNM staging was found to be statistically significant (P < 0.05).

He X, Chen Z, Jia M, and Zhao X (36) did a meta-analysis of 27 studies, which included 4244 cases of CRC. They concluded that downregulated E-cadherin expression was greatly related to differentiation grade, Dukes stages, lymph node status, and metastasis. The pooled OR (odds ratio) was 0.36 (95% CI, 0.19–0.7; Z = 3.03; P = 0.002), 0.34 (95% CI, 0.21–0.55; Z = 6.61; P = 0.000), 0.49 (95% CI, 0.32–0.74; Z = 3.02; P = 0.002), and 0.45 (95% CI, 0.22–0.91; Z = 3.43; P = 0.001), respectively.

Hence, our findings are in agreement with this meta-analytic study, which also found that E-cadherin expression loss was significantly associated with histological tumor grade and lymph node metastasis and epithelial-mesenchymal transition.

Another study done by Dorudi S et al. (37) on E-cadherin expression in colorectal cancer and its correlation with tumor grade and lymph node included a total of 72 cases of colorectal carcinoma. They analyzed the loss of E-cadherin expression in 8 cases of well differentiated, 36 cases of moderately differentiated, and 28 cases of poorly differentiated adenocarcinomas. They found that only 1 case out of 8 well differentiated adenocarcinoma cases showed loss of E-cadherin, 32 out of 36 moderately differentiated cases showed E-cadherin loss, and all 28 poorly differentiated cases showed loss of E-cadherin. This loss of expression was statistically significant by chi-square test (P < 0.05), and they concluded that E-cadherin expression was related inversely to tumor differentiation.While it was not true in our case,may be due to limited sample.

They also compared E-cadherin expression loss in tumor cells with lymph node metastasis. In their study of 72 cases, 36 showed lymph node metastasis. Twenty-nine out of 36 cases showing lymph node metastasis had loss of E-cadherin expression, and 32 out of 36 cases without lymph node metastasis showed normal E-cadherin expression. Fisher exact test P < 0.001 revealed a highly significant correlation.

A study conducted by Matsuoka T et al. (38) did immunohistochemical analysis of claudin-1 and -4, E-cadherin, and β-catenin on a series of 156 cases of CRC. The aim of the study was to assess the relationship between expression of these markers and clinicopathological features of colorectal carcinomas. Significant positive associations (P < 0.05–0.001) were found with immunoreactivity for each, except nuclear β-catenin. Reduced expression was correlated with poor tumor differentiation (claudin-1, P = 0.035; claudin-4, P = 0.011; E-cadherin, P < 0.001; membranous β-catenin, P = 0.002), an advanced TNM stage (claudin-1, P = 0.002; claudin-4, P = 0.008), and a poor prognosis. On multivariate analysis, reduced expression of E-cadherin (P < 0.001) and β-catenin (P = 0.048) at invasive fronts proved to be an independent predictor of short survival. Hierarchical cluster analysis identified 3 distinct groups with good, intermediate, and poor prognosis, having an independent survival outcome by multivariate analysis (good or intermediate vs poor: hazard ratio, 2.66; 95% confidence interval, 1.54–4.60; P < 0.001). Hence, a statistically significant correlation was seen between E-cadherin expression and TNM staging.

VIMENTIN EXPRESSION

In our study, the total number of cases showing vimentin expression was 9 (30%), and the remaining 21 (70%) cases were negative. Of these 9 cases, 1 each was grade I and III, while 7 cases were grade II. Chi-square test was done to look for an association between histological tumor grade and vimentin expression. Correlation of histological tumor grade with vimentin expression was found to be statistically significant (P value <0.05).

Vimentin-positive cases of well differentiated adenocarcinoma (1 case) were compared with moderately and poorly differentiated cases combined (8 cases) by chi-square test. The comparison showed a statistically significant difference for vimentin expression, with P value = 0.001.

Out of the 6 cases of regional lymph node metastasis, 4 cases showed positive staining for vimentin (67%), while 5 cases having no regional metastasis also showed vimentin expression out of a total of 30 cases. The comparison of regional lymph node metastasis and vimentin expression by chi-square test was found to be statistically significant, with P value = 0.028.

So, our study revealed a statistically significant correlation of vimentin expression with tumor grade and regional lymph node metastasis.

A study conducted by Toiyama Y et al. (39) on increased expression of Slug and vimentin as novel predictive biomarkers for lymph node metastasis and poor prognosis in colorectal cancer included 208 CRC cases. Immunohistochemical analysis was performed to investigate the cellular distribution of Slug and vimentin protein expression and evaluate associations between protein expression results and clinicopathological data. The high-staining group of Slug was significantly associated with large tumor size (P = 0.028), serosal invasion (P < 0.0001), metastasis of lymph node (P < 0.0001), liver (P < 0.0001), and peritoneum (P = 0.007). In addition, high vimentin staining was also associated with large tumor size (P = 0.034), serosal invasion (P < 0.0001), and lymph node metastasis (P = 0.0005). Furthermore, Slug and vimentin staining scores were significantly increased according to TNM stage, and showed that the staining score of Slug was significantly correlated with that of vimentin (ρ = 0.405; 95% CI, 0.284–0.513; P < 0.0001). They concluded that patients with increased Slug and vimentin expression had an overall worse prognosis in CRC, their data highlighted that Slug and vimentin as valuable predictive markers of lymph node metastasis, and was increasingly associated with higher tumor stage. Their findings were concurrent with our study with respect to vimentin expression and its correlation with tumor stage and lymph node metastasis.

In our study, we also did a comparison of E-cadherin and vimentin expression in tumor cells of all 30 cases studied. A total number of 16 (53%) cases showed E-cadherin expression, and 9 (30%) cases showed positive expression for vimentin in tumor cells. The expression of E-cadherin and vimentin was found to be statistically significant (P value <0.05).

A study conducted by Zhou J et al. (40) on expression of E-cadherin and vimentin in oral squamous cell carcinoma. The aim of the study was to determine the levels of E-cadherin and vimentin expression in tumor tissues from patients with oral squamous cell carcinoma (OSCC), and the relationship between the expression of E-cadherin, vimentin, and epithelial-mesenchymal transition, in order to explore its values for predicting the invasion and metastasis of oral squamous cell carcinoma and short survival of patients in many types of cancer. E-cadherin and vimentin expression of 10 benign and 42 OSCC tumor tissues was examined by immunohistochemical staining. E-cadherin and vimentin were expressed in 26 of 42 (61.9%) and 16 of 42 (38.1%), respectively. No statistically significant difference was found for E-cadherin and vimentin expression in patients with different age, gender, and tumor location. E-cadherin and vimentin expression was significantly associated with lymph node metastasis and tissue location (P < 0.05); E-cadherin expression was also significantly associated with tumor stage (P < 0.05); there were significant differences between infiltrative margin and central area in patients with oral squamous cell carcinoma for E-cadherin and vimentin positive expression (P < 0.05). E-cadherin and vimentin positive expression was associated with tumor metastasis of oral squamous cell carcinoma. This study preliminarily confirmed that the EMT phenomenon has existed during the development of oral squamous cell carcinoma. Co-evaluation of E-cadherin and vimentin might be a valuable tool for predicting OSCC patient outcome.

Our findings are in agreement with the findings of this study; hence, we can draw a similar conclusion that the process of EMT has existed during the development of colorectal cancers in our study.

OCT-4 EXPRESSION

In our study of 30 cases, 14 cases (46.6%) showed positive OCT-4 expression. Of these, 6 cases each were grade I and II, while 2 cases were grade III. Chi-square test was done to look for an association between histological tumor grade and OCT-4 expression. A P value = 0.179 indicated that the association was statistically not significant.

Out of the 6 cases of regional lymph node metastasis, 4 cases showed positive staining for OCT-4 (67%), while 10 cases having no regional metastasis were also positive for OCT-4 expression out of a total of 30 cases. The comparison of regional lymph node metastasis and OCT-4 expression was done and found to be statistically not significant (P value = 0.272).

Also, OCT-4 expression in tumor cells was compared with E-cadherin and vimentin expressions separately, and we got P values of 0.063 and 0.151, respectively, which were statistically not significant.

Our study suggested that there was no association between OCT-4 and colorectal cancer (CRC) patients. Also, as it had no correlation with known EMT markers (E-cadherin and vimentin), OCT-4 expression might not be related to EMT.

A study conducted by Talebi A et al. (41) included a study sample consisting of 20 patients, including 11 men (55%) and 9 women (45%), with a mean age of 55.6 ± 9.88 years. This cross-sectional study was conducted on 20 patients, and samples of healthy tissue, dysplastic polyp tissue, and colon adenocarcinoma were provided as microscopic sections, and staining on each tissue was performed through the immunohistochemistry method by markers OCT-4 and SOX2. The collected data were entered into SPSS version 18.0 (SPSS Inc., Chicago, IL, USA) software, and the level of significance was considered as <0.05. There was no association between OCT-4 and colorectal cancer (CRC) patients (P > 0.05), but there was a significant correlation between SOX2 expression and CRC (P < 0.05).

This study was in agreement with our findings of OCT-4 showing no significant association with CRC.

Another study conducted by Zhou H, Hu Y, Wang W, et al. (42) on 158 cases of CRC investigated whether OCT-4 expression was associated with CRC. In order to achieve this, primary CRC tissues, matched nontumor tissues, and benign polyp tissues, representing different stages of carcinogenesis, were obtained, and OCT-4 expression was analyzed using reverse transcription-quantitative polymerase chain reaction, flow cytometry analysis, and immunohistochemistry. Furthermore, the medical records of patients with CRC were reviewed, and clinicopathological analysis was performed in order to assess the association between OCT-4 expression and certain clinicopathological parameters. It was shown that the transcription and translation of OCT-4 increased in a stepwise manner, from nontumor to benign polyp tissues and from benign polyps to CRC tissues. OCT-4 expression in CRC was significantly correlated with histological grade (P = 0.007), lymph node metastasis (P = 0.027), distant metastasis (P = 0.017), and TNM stage (P = 0.041). Kaplan-Meier survival curve analysis demonstrated that OCT-4+ cases had a shorter median survival time (37.0 months) compared with OCT-4− cases (76.0 months; P = 0.001). These results indicated that aberrant expression of OCT-4 may be involved in the development of CRC. Thus, OCT-4 may be a biomarker for the prediction, diagnosis, or assessment of prognosis in CRC, in addition to a potential target for the treatment of this disease.

Our findings were in disagreement with this study, wherein they had shown that OCT-4 expression was significantly associated with histological grading, TNM stage, lymph node metastasis, and distant metastasis in CRC. It should be noted that the sample size of this study was 158 cases, while our sample size was only 30 cases; hence, a small sample size may be the cause of the disagreeing result.

CONCLUSION

In our study, positive expression E-cadherin was significantly associated with regional lymph node metastasis. Vimentin expression in tumor cells was also positively associated with histological tumor grade and regional lymph node metastasis. Correlation of E-cadherin and vimentin in our study was also found to be statistically significant; hence, it is suggested that the process of EMT has taken place in the cases included.

OCT-4 expression was found to be statistically not significant when compared to histological tumor grade and regional lymph node metastasis. Larger studies are suggested to further explore the role of OCT-4 in tumor differentiation and regional lymph node metastasis.

Funding

This research received no specific grant from any funding agency in the public, commercial, or not-for-profit sectors.

Conflict of interest

The authors declared no conflict of interest.

Data Availability

The data that support the findings of this study are available from the corresponding author upon request.

Ethics Approval

The study was approved by the Institutional Ethics Committee of Uttar Pradesh University of Medical Sciences.No/HRH/2024/6986. Patient consent were obtained. Due to the retrospective nature of the study.

Authors' Contributions

Conceptualization: A.Y., S.Y.; Methodology: A.Y., S.Y.; Formal analysis: R.A.; Investigation: A.B., S.S., A.S., S.C.; Data curation: A.B., S.S., A.S., S.C.; Writing – Original Draft Preparation: A.Y., S.Y., A.B., S.S., A.S., S.C., R.A.; Writing – Review & Editing: A.Y., S.Y., A.B., S.S., A.S., S.C., R.A. All authors have read and agreed to the published version of the manuscript.

Acknowledgments

We would like to acknowledge the technical support provided by the Department of Pathology, Uttar Pradesh University of Medical Sciences, Saifai.

Declaration of AI Use

The authors declare that no generative AI or AI-assisted technologies were used in the writing process of this manuscript.

REFERENCES

1. Patel SG, Dominitz JA. Screening for colorectal cancer. Ann Intern Med. 2024;177(2):49-64. [DOI:10.7326/AITC202404160] [PMID:38588547]
2. Shin AE, Giancotti FG, Rustgi AK. Metastatic colorectal cancer: mechanisms and emerging therapeutics. Trends Pharmacol Sci. 2023;44(4):222-236. [DOI:10.1016/j.tips.2023.01.003] [PMCID:PMC10365888] [PMID:36828759]
3. Yang J, Antin P, Berx G, Blanpain C, Brabletz T, Bronner M, et al. Guidelines and definitions for research on epithelial-mesenchymal transition. Nat Rev Mol Cell Biol. 2020;21(6):341-352. [DOI:10.1038/s41580-020-0237-9] [PMCID:PMC7250738] [PMID:32300252]
4. Li D, Xia L, Huang P, Wang Z, Guo Q, Huang C, et al. Heterogeneity and plasticity of epithelial-mesenchymal transition (EMT) in cancer metastasis: focusing on partial EMT and regulatory mechanisms. Cell Prolif. 2023;56(4):e13423. [DOI:10.1111/cpr.13423] [PMCID:PMC10280150] [PMID:36808651]
5. Huang Y, Hong W, Wei X. The molecular mechanisms and therapeutic strategies of EMT in tumor progression and metastasis. J Hematol Oncol. 2022;15(1):129. [DOI:10.1186/s13045-022-01347-8] [PMCID:PMC9461252] [PMID:36076302]
6. Lu J, Kornmann M, Traub B. Role of epithelial to mesenchymal transition in colorectal cancer. Int J Mol Sci. 2023;24(19):14815. [DOI:10.3390/ijms241914815] [PMCID:PMC10573312] [PMID:37834263]
7. Sabouni E, Nejad MM, Mojtabavi S, Khoshduz S, Mojtabavi M, Nadafzadeh N, et al. Unraveling the function of epithelial-mesenchymal transition (EMT) in colorectal cancer: metastasis, therapy response, and revisiting molecular pathways. Biomed Pharmacother. 2023;160:114395. [DOI:10.1016/j.biopha.2023.114395] [PMID:36804124]
8. Taki M, Abiko K, Ukita M, Murakami R, Yamanoi K, Yamaguchi K, et al. Tumor immune microenvironment during epithelial-mesenchymal transition. Clin Cancer Res. 2021;27(17):4669-4679. [DOI:10.1158/1078-0432.CCR-20-4459] [PMID:33827891]
9. Verstappe J, Berx G. A role for partial epithelial-to-mesenchymal transition in enabling stemness in homeostasis and cancer. Semin Cancer Biol. 2023;90:15-28. [DOI:10.1016/j.semcancer.2023.02.001] [PMID:36773819]
10. Wang Y, Dong C, Zhou BP. Metabolic reprogram associated with epithelial-mesenchymal transition in tumor progression and metastasis. Genes Dis. 2020;7(2):172-184. [DOI:10.1016/j.gendis.2019.09.012] [PMCID:PMC7083713] [PMID:32215287]

11. Barbazan J, Muinelo-Romay L, Vieito M, Candamio S, Diaz-Lopez A, Cano A, et al. A multimarker panel for circulating tumor cells detection predicts patient outcome and therapy response in metastatic colorectal cancer. Int J Cancer. 2014;135(11):2633-2643. [DOI:10.1002/ijc.28910] [PMID:24752533]

12. Kalluri R, Weinberg RA. The basics of epithelial-mesenchymal transition. J Clin Invest. 2009;119(6):1420-1428. [DOI:10.1172/JCI39104] [PMCID:PMC2689101] [PMID:19487818]

13. Niknami Z, Muhammadnejad A, Ebrahimi A, Harsani Z, Shirkoohi R. Significance of E-cadherin and Vimentin as epithelial-mesenchymal transition markers in colorectal carcinoma prognosis. EXCLI J. 2020;19:917-926. [PMCID:PMC7355153] [PMID:32665775]

14. Brown MS, Muller KE, Pattabiraman DR. Quantifying the Epithelial-to-Mesenchymal Transition (EMT) from Bench to Bedside. Cancers (Basel). 2022;14(5):1138. [DOI:10.3390/cancers14051138] [PMCID:PMC8909103] [PMID:35267444]

15. Usman S, Waseem NH, Nguyen TKN, Mohsin S, Jamal A, Teh MT, et al. Vimentin Is at the Heart of Epithelial Mesenchymal Transition (EMT) Mediated Metastasis. Cancers (Basel). 2021;13(19):4985. [DOI:10.3390/cancers13194985] [PMCID:PMC8507690] [PMID:34638469]

16. Ponnusamy MP, Seshacharyulu P, Lakshmanan I, Vaz AP, Chugh S, Batra SK. Emerging role of mucins in epithelial to mesenchymal transition. Curr Cancer Drug Targets. 2013;13(9):945-956. [DOI:10.2174/15680096113136660100] [PMCID:PMC3924542] [PMID:24168188]

17. Guo M, You C, Dou J. Role of transmembrane glycoprotein mucin 1 (MUC1) in various types of colorectal cancer and therapies: Current research status and updates. Biomed Pharmacother. 2018;107:1318-1325. [DOI:10.1016/j.biopha.2018.08.109] [PMID:30257347]

18. Schöler HR, Ruppert S, Suzuki N, Chowdhury K, Gruss P. New type of POU domain in germ line-specific protein Oct-4. Nature. 1990;344(6265):435-439. [DOI:10.1038/344435a0] [PMID:1690859]

19. Hansis C, Grifo JA, Krey LC. Oct-4 expression in inner cell mass and trophectoderm of human blastocysts. Mol Hum Reprod. 2000;6(11):999-1004. [DOI:10.1093/molehr/6.11.999] [PMID:11044462]

20. Loh YH, Wu Q, Chew JL, Vega VB, Zhang WW, Chen X, et al. The Oct4 and Nanog transcription network regulates pluripotency in mouse embryonic stem cells. Nat Genet. 2006;38(4):431-440. [DOI:10.1038/ng1760] [PMCID:PMC8357150] [PMID:16518401]

21. Palmieri SL, Peter W, Hess H, Schöler HR. Oct4 transcription factor is differentially expressed in the mouse embryo during establishment of the first two extraembryonic cell lineages involved in implantation. Dev Biol. 1994;166(1):259-267. [DOI:10.1006/dbio.1994.1312] [PMID:7958450]

22. Niwa H, Miyazaki J, Smith AG. Quantitative expression of Oct-3/4 defines differentiation, dedifferentiation or self-renewal of ES cells. Nat Genet. 2000;24(4):372-376. [DOI:10.1038/74199] [PMID:10742100]

23. Takahashi K, Tanabe K, Ohnuki M, Narita M, Ichisaka T, Tomoda K, et al. Induction of pluripotent stem cells from adult human fibroblasts by defined factors. Cell. 2007;131(5):861-872. [DOI:10.1016/j.cell.2007.11.019] [PMID:18035408]

24. Cheng L. Establishing a germ cell origin for metastatic tumors using OCT4 immunohistochemistry. Cancer. 2004;101(9):2006-2010. [DOI:10.1002/cncr.20566] [PMID:15386301]

25. Jones TD, Ulbright TM, Eble JN, Baldridge LA, Cheng L. OCT4 staining in testicular tumors: a sensitive and specific marker for seminoma and embryonal carcinoma. Am J Surg Pathol. 2004;28(8):935-940. [DOI:10.1097/00000478-200407000-00014] [PMID:15223965]

26. Looijenga LH, Stoop H, de Leeuw HP, de Gouveia Brazao CA, Gillis AJ, van Roozendaal KE, et al. POU5F1 (OCT3/4) identifies cells with pluripotent potential in human germ cell tumors. Cancer Res. 2003;63(9):2244-2250.

27. Zlobec I, Lugli A. Epithelial mesenchymal transition and tumor budding in aggressive colorectal cancer: tumor budding as oncotarget. Oncotarget. 2010;1(7):651-661. [DOI:10.18632/oncotarget.199] [PMCID:PMC3248128] [PMID:21317460]

28. Hazan RB, Kang L, Whooley BP, Borgen PI. N-cadherin promotes adhesion between invasive breast cancer cells and the stroma. Cell Adhes Commun. 1997;4(6):399-411. [DOI:10.3109/15419069709004457] [PMID:9177902]

29. Sinha R, Doval DC, Hussain S, Kumar K, Singh S, Basir SF, et al. Lifestyle and Sporadic Colorectal Cancer in India. Asian Pac J Cancer Prev. 2015;16(17):7683-7688. [DOI:10.7314/APJCP.2015.16.17.7683] [PMID:26625781]

30. Sharma MK, Singh T, Pandey AK, Kankaria A. Epidemiological Trends of GI Cancers in Patients Visiting a Tertiary Care Hospital in Chandigarh, North India. Asian Pac J Cancer Prev. 2015;16(8):3499-3503. [DOI:10.7314/APJCP.2015.16.8.3499] [PMID:25921168]

31. Brungs D, Aghmesheh M, de Souza P, Anyittah H, Chua W, Ng W, et al. Sidedness is prognostic in locoregional colon cancer: an analysis of 9509 Australian patients. BMC Cancer. 2017;17(1):251. [DOI:10.1186/s12885-017-3255-z] [PMCID:PMC5385038] [PMID:28390415]

32. Goh KL, Khan GI, Abdullah M, Suthasiri P, Ong KK, Rozman S, et al. Colorectal cancer in Asians: a demographic and anatomic survey in Malaysian patients undergoing colonoscopy. Aliment Pharmacol Ther. 2005;22(9):859-864. [DOI:10.1111/j.1365-2036.2005.02646.x] [PMID:16225496]

33. Kornprat P, Pollheimer MJ, Lindtner RA, Schlemmer A, Rehak P, Langner C. Value of tumor size as a prognostic variable in colorectal cancer: a critical reappraisal. Am J Clin Oncol. 2011;34(1):43-49. [DOI:10.1097/COC.0b013e3181cae8dd] [PMID:20101166]

34. Balta AZ, Özdemir Y, Sücüllü İ, Derici ST, Bağcı M, Demirel D, et al. Can horizontal diameter of colorectal tumor help predict prognosis?. Can horizontal diameter of colorectal tumor help predict prognosis? Ulus Cerrahi Derg. 2014;30(3):115-119. [DOI:10.5152/UCD.2014.2701] [PMCID:PMC4379853] [PMID:25931910]

35. Li J, Yi CH, Hu YT, Li JS, Yuan Y, Zhang SZ, et al. TNM Staging of colorectal cancer should be reconsidered according to weighting of the T Stage: Verification Based on a 25-Year Follow-Up. Medicine (Baltimore). 2016;95(6):e2711. [DOI:10.1097/MD.0000000000002711] [PMCID:PMC4753906] [PMID:26871810]

36. He X, Chen Z, Jia M, Zhao X. Downregulated E-cadherin expression indicates worse prognosis in Asian patients with colorectal cancer: evidence from metaanalysis. PLoS One. 2013;8(7):e70858. [DOI:10.1371/journal.pone.0070858] [PMCID:PMC3726621] [PMID:23923027]

37. Dorudi S, Sheffield JP, Poulsom R, Northover JM, Hart IR. E-cadherin expression in colorectal cancer. An immunocytochemical and in situ hybridization study. Am J Pathol. 1993;142(4):981-986.

38. Matsuoka T, Mitomi H, Fukui N, Kanazawa H, Saito T, Hayashi T, et al. Cluster analysis of claudin-1 and -4, E-cadherin, and β-catenin expression in colorectal cancers. J Surg Oncol. 2011;103(7):674-686. [DOI:10.1002/jso.21854] [PMID:21360533]

39. Toiyama Y, Yasuda H, Saigusa S, Tanaka K, Inoue Y, Goel A, et al. Increased expression of Slug and Vimentin as novel predictive biomarkers for lymph node metastasis and poor prognosis in colorectal cancer. Carcinogenesis. 2013;34(11):2548-2557. [DOI:10.1093/carcin/bgt282] [PMID:24001454]

40. Zhou J, Tao D, Xu Q, Gao Z, Tang D. Expression of E-cadherin and vimentin in oral squamous cell carcinoma. Int J Clin Exp Pathol. 2015;8(3):3150-3154.

41. Talebi A, Kianersi K, Beiraghdar M. Comparison of gene expression of SOX2 and OCT4 in normal tissue, polyps, and colon adenocarcinoma using immunohistochemical staining. Adv Biomed Res. 2015;4:234. [DOI:10.4103/2277-9175.167958] [PMCID:PMC4647122] [PMID:26645019]

42. Zhou H, Hu YU, Wang W, Mao Y, Zhu J, et al. Expression of Oct-4 is significantly associated with the development and prognosis of colorectal cancer. Oncol Lett. 2015;10(2):691-696. [DOI:10.3892/ol.2015.3269] [PMCID:PMC4509036] [PMID:26622555]