Iranian Journal of Pathology | ISSN: 2345-3656

Congenital Ectopic Cartilaginous Nodule on the Left Cheek: A Rare Diagnostic Challenge

Zohreh Khodashenas*, Hanieh Pourkalhor, Mehri Vafadar

Department of Dermatology, Faculty of Medicine, Head of Student Research Committee, Research Deputy, Shahed University, Tehran, Iran

KEYWORDS

Ectopic cartilage; congenital skin lesion; connective tissue nevus; chondroma cutis; clinicopathologic correlation

Scan to discover online

Main Subjects:
Endocrine Pathology

Received 19 Dec 2025;
Accepted 18 Feb 2026;
Published Online 10 May 2026;

10.22034/ijp.2026.2078135.3584

ABSTRACT

Background & Objective: Congenital cutaneous lesions containing mature cartilage are exceedingly rare and often of uncertain histogenesis

Case Report: A 17-year-old male with a lifelong left cheek nodule underwent complete excision and histopathologic examination. Microscopy revealed a deep dermal island of mature hyaline cartilage without atypia, associated epithelial components, or adnexal hyperplasia.

Conclusion: The findings represent ectopic cartilage of unclear etiology. Connective tissue nevus with cartilaginous differentiation and chondroma cutis are favored considerations. Complete excision was curative, with an excellent cosmetic outcome at 5-month follow-up.

Corresponding Information: **Zohreh Khodashenas,** Department of Dermatology, Faculty of Medicine, Head of Student Research Committee, Research Deputy, Shahed University, Tehran, Iran Email: z.khodashenas@shahed.ac.ir

Copyright © 2026. This is an open-access article distributed under the terms of the **Creative Commons Attribution 4.0 International License (CC BY 4.0)**, which permits unrestricted use, distribution, and reproduction in any medium, provided the original work is properly cited. The license also allows users to adapt, remix, transform, and build upon the material for any purpose, including commercial use.

Introduction

Congenital skin lesions composed of mature cartilage are rare developmental anomalies that pose significant diagnostic difficulty due to overlapping clinical and histologic features (1,2). Such lesions are most often reported in the neck as chondrocutaneous remnants (wattles) and are considered choristomatous (1,3,4). Facial examples, particularly on the cheek, are exceptional (5,6). Differential diagnoses primarily include connective tissue nevus with cartilaginous differentiation and chondroma cutis (7,8). This report describes a congenital cheek nodule with ectopic cartilage and highlights the limitations of histopathology in achieving a definitive diagnosis.

Case Report

A 17-year-old Iranian male presented with a congenital, slowly enlarging, tan-colored, firm, 1.5 × 0.8 cm elliptical nodule on the left cheek. The lesion was hairless, non-tender, and without ulceration or discharge. There was no family history of similar lesions or syndromic stigmata. Systemic evaluation, including renal, cardiac, and auditory ultrasound examinations, was normal. Clinical differential diagnosis included sebaceous nevus and connective tissue nevus. Complete excision under local anesthesia was performed. At 5-month follow-up (November 2025), the surgical scar was well healed with an excellent cosmetic result and no recurrence (Fig. 1). Written informed consent was obtained from the patient for publication of this case report and accompanying images.

Diagnostic Assessment

Gross Pathology

Elliptical tan skin measuring 1.5 × 0.8 × 0.2 cm with a firm, homogeneous cut surface.

Histopathology

The epidermis and superficial dermis were unremarkable. A discrete focus of mature hyaline cartilage was present in the deep dermis, composed of uniform chondrocytes within lacunae and lacking atypia, mitoses, or necrosis (Fig. 2). Vellus hairs were sparse; sebaceous glands and follicular hyperplasia were absent. No squamous, ciliated, or respiratory-type epithelium was identified. Alcian blue stain confirmed the chondroid matrix (Fig. 2).

Pathologic Diagnosis

Skin, left cheek, excision, ectopic mature cartilaginous tissue in the deep dermis. No evidence of malignancy.



Fig. 1. Clinical photograph at 5-month follow-uppost-excision: well-healed linear scar with excellent cosmetic outcome and no evidence of recurrence. Clinical photograph: tan, firm, hairless elliptical nodule (1.5 × 0.8 cm) on left cheek.

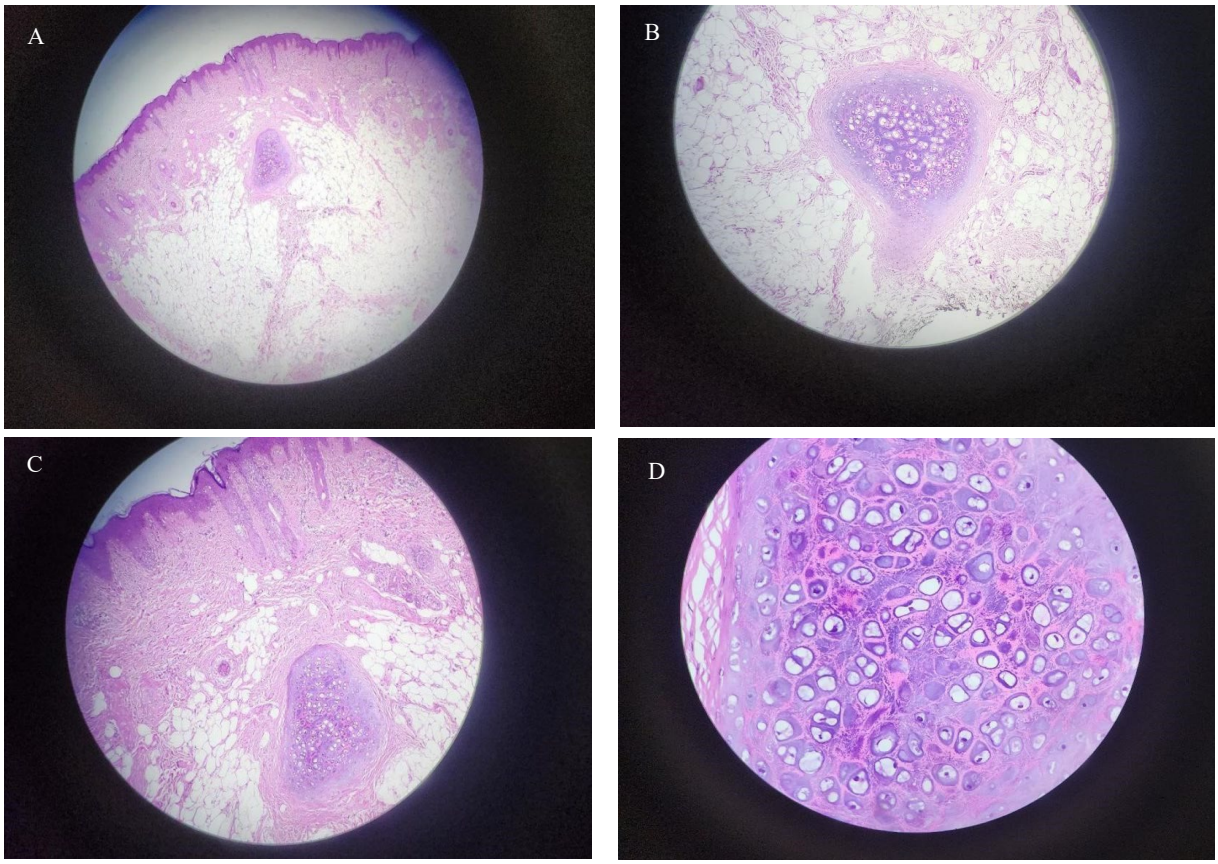

Fig. 2. A) H&E, ×40: Deep dermal island of mature hyaline cartilage. B) H&E, ×100: Chondrocytes in lacunae within chondroid matrix. C) H&E, ×200: Uniform chondrocytes, no atypia or mitoses. D) Alcian blue, ×100: Positive staining of chondroid matrix. (Histology images courtesy of Danesh Pathology Lab, Tehran. Clinical image provided by patients.)

Discussion

The presence of mature hyaline cartilage within the deep dermis of a congenital facial lesion is exceptionally rare (1,2). The absence of associated epithelial lining or adnexal hyperplasia excludes sebaceous nevus and branchial cleft remnants (9,10). Connective tissue nevus with cartilaginous differentiation is the most plausible diagnosis given the bland histology and deep dermal location (7,11). Chondroma cutis, though more common on acral sites, remains a viable alternative (8,12).

Although both cutaneous chondroma and chondroid choristoma feature mature cartilage in the dermis, cutaneous chondroma is typically a solitary neoplasm without congenital onset or pubertal changes, often occurring in adults on acral sites (8,12). In contrast, chondroid choristoma represents heterotopic normal tissue (a developmental anomaly) rather than a true neoplasm, aligning more closely with the congenital presentation and lack of atypia in this case (2). The current lesion's lifelong history and subtle pubertal enlargement favor a choristomatous or metaplastic process within a connective tissue nevus framework.

Comparable congenital cartilaginous lesions are predominantly cervical chondrocutaneous remnants or wattle-like structures (1,3,4,13). Solitary facial examples without cystic or epithelial components are exceedingly uncommon and are best regarded as choristomas (2). Subtle pubertal enlargement may reflect hormonal responsiveness of preexisting cartilaginous rests (14,15). Classic accessory tragus typically shows a more anterior location and pedunculated morphology with vellus hairs, features not observed in the present case (14).

The pathogenesis of solitary ectopic facial cartilage remains unclear but likely involves aberrant migration or persistence of branchial arch-derived cartilaginous rests during embryogenesis, potentially influenced by local hormonal factors during puberty (2,14). Previously reported cervical chondrocutaneous remnants often present as wattle-like pedunculated lesions with elastic cartilage, whereas facial cases, as in the present report, are typically flat, hairless nodules with hyaline cartilage (1,3,4). This distinction may reflect regional variations in embryonic development or tissue differentiation.

Limitations include the absence of immunohistochemical or molecular studies and follow-up beyond 5 months. Complete surgical excision proved both diagnostic and therapeutic, with excellent cosmetic outcome at 5-month follow-up.

Conclusion

This case contributes to the sparse literature on solitary congenital ectopic cartilage of the facial skin. Histopathology alone is non-specific, and a definitive diagnosis cannot be rendered. Connective tissue nevus

with cartilaginous differentiation and chondroma cutis are favored considerations. Complete excision is curative, and extended surveillance is recommended.

Acknowledgments

The authors would like to thank the patient for providing consent for publication of this case and the staff of Danesh Pathology Laboratory, Tehran, for providing the histopathology images.

Authors' Contributors

All authors contributed equally to the conceptualization, design, and execution of this study.

Data Availability

The datasets generated and analyzed during the current study are not publicly available; however, the data can be shared for research and authentication purposes upon reasonable request.

Funding

This research received no specific grant from any funding agency in the public, commercial, or not-for-profit sectors.

Ethics Approval

All identifying patient information was removed to protect privacy. Written informed consent for publication (text and images) was obtained from the patientThe procedures followed were in accordance with the ethical standards of the responsible committee on human experimentation (institutional and national) and with the Helsinki Declaration. Written informed consent was obtained from the patient for publication of this case report and accompanying images. A copy of the written consent is available for review by the Editor-in-Chief of this journal on request. No identifying information is included in the report.

Conflict of Interest

The authors declared no conflict of interest.

References

1. Sabertehrani S, Faramarzirad F, Gheisari M, Zahedi K. Unilateral congenital cartilaginous rests of the neck: A case report and literature review. Clin Case Rep. 2025;13(8):e70668. [DOI:10.1002/ccr3.70668] [PMID] [PMCID]
2. Carvey MT, Ramachandran D, Hage R. Choristoma: Cervical chondrocutaneous branchial remnants. Cureus. 2018;10(8):e3149. [DOI:10.7759/cureus.3149]
3. Park DH, Lee JK, Baik BS, Yang WS, Kim SY. Cervical chondrocutaneous remnant: A case report. Arch Craniofac Surg. 2022;23(5):241-5. [DOI:10.7181/acfs.2022.00920] [PMID] [PMCID]
4. van Kalkeren TA, Frima-van Aarem A, Ahsmann EJM, Mahieu HF. Case report of a unilateral cervical chondrocutaneous branchial remnant. Int J Pediatr Otorhinolaryngol Extra. 2007;2(4):225-227. [DOI:10.1016/j.pedex.2007.06.006]
5. Lee HS, Kim TH, Jang JY, Woo JW, Lee JK, Jeong SH, et al. Bilateral cervical chondrocutaneous branchial remnants. Medicine (Baltimore). 2020; 99(28):e21114. [PMID] [PMCID] [DOI:10.1097/MD.0000000000021114]
6. He Y, Wu Z, Zhu Q, Qi J, Xuan X, Zhang G. A case report of childhood cutaneous cartilaginous tumor located in the neck. Front Pediatr. 2025;13:1607480. [DOI:10.3389/fped.2025.1607480] [PMID] [PMCID]
7. de Moura LA, Diniz LM, Jarske RD, Souza EN, Sabbagh de Azevedo MS. Chondroid syringoma: Unusual presentation of a rare tumor. Surg Cosmet Dermatol. 2019;14. [DOI:10.5935/scd1984-8773.2022140171]
8. Bahnassy M, Abdul-Khalik H. Soft tissue chondroma: A case report and literature review. Oman Med J. 2009;24(4):296-9. [DOI:10.5001/omj.2009.60] [PMID] [PMCID]
9. Singh C, Silky S, Agarwal AC, Gupta T, Sinha M, Sharma P. Perplexing first branchial cleft anomalies: A case series with review of literature. Indian J

Otolaryngol Head Neck Surg. 2024;76(1):1454-60. [DOI:10.1007/s12070-023-04243-w] [PMID] [PMCID]

10. Chavan S, Deshmukh R, Karande P, Ingale Y. Branchial cleft cyst: A case report and review of literature. J Oral Maxillofac Pathol. 2014;18(1):150. [DOI:10.4103/0973-029X.131950] [PMID] [PMCID]
11. Thompson J, Squires S, Machan M, Fraga GR, Aires D. Cutaneous mixed tumor with extensive chondroid metaplasia: A potential mimic of cutaneous chondroma. Dermatol Online J. 2012;18(3):9. [DOI:10.5070/D33ZX859DD] [PMID]
12. Khandelwal V, Banda NR, Nayak UA, Banda VR. Accessory tragus: A dentist's perspective. BMJ Case Rep. 2013;2013:bcr2013008645. [DOI:10.1136/bcr-2013-008645] [PMID] [PMCID]
13. Kono T, Ro H, Murakami N, Kochi M, Kuroki T, Tosa Y, et al. Accessory auricles affecting the tragus and cheek occurring with cervical chondrocutaneous branchial remnants: A case report. JPRAS Open. 2015;6:20-4. [DOI:10.1016/j.jpra.2015.09.002]
14. Asahina A, Mitomi H, Sakurai N, Fujita H. Multiple accessory tragi without cartilage: Relationship with hair follicle naevi? Acta Derm Venereol. 2009;89(3):316-7. [DOI:10.2340/00015555-0617] [PMID]
15. Jansen T, Romiti R, Altmeyer P. Accessory tragus: Report of two cases and review of the literature. Pediatr Dermatol. 2000;17(5):391-4. [DOI:10.1046/j.1525-1470.2000.017005391.x] [PMID]