Iranian Journal of Pathology | ISSN: 2345-3656

# *Vibrio cholerae* and Its CtxA Toxin: A Comparative Study of the Histopathological and Related Changes in Albino Mice

**Khansaa Akram Hasan, Taghreed Khudhur Mohammed*,**

*Department of Medical Laboratory Techniques, Institute of Medical Technology – Al-Mansour, Middle Technical University, Baghdad, Iraq*

**KEYWORDS**

*Vibrio cholerae; Cholera Toxin; ctxA; Intestine, Small; Liver; Mice; Polymerase Chain Reaction; Anti-Bacterial Agents*

Scan to discover online

**Main Subjects:**
Microbiology

Received 22 Nov 2025;
Accepted 27 Apr 2026;
Published Online 10 May 2026;

10.22034/ijp.2026.2078533.3590

**ABSTRACT**

**Background & Objective:** While *V. cholerae* primarily causes massive secretory diarrhea due to CT, whether CT in its purified form inflicts the same injurious effect on tissues seen in the presence of the whole bacteria in vivo is unknown. To examine the histopathological changes caused by different clinical *V. cholerae* isolates and their partially purified enterotoxin in an experimental model of the mouse, and to determine the antimicrobial susceptibility profile of the isolate and ctxA gene carriage.

**Methods:** From 250 clinical samples of 200 stool and 50 rectal samples taken in Baghdad (2022 to 2023), and using culture, biochemical tests, and serotyping methods, *V. cholerae* was isolated. Antimicrobial susceptibility was determined using the disk diffusion method according to the CLSI 2022. ctxA gene was detected by conventional PCR. In the experiment, 6 weeks old mice received intraperitoneal injections of either partially purified toxin (2 dilutions corresponding to 55 and 45 µg/mL), live *V. cholerae* ($10^2$–$10^8$ CFU/mL), or normal saline (control). After 5 days, the liver, small intestine, and lungs were collected and subjected to histological examination.

**Results:** *V. cholerae* was found in 20 of 250 specimens (8%) (18 by stool culture, 2 by rectal swabs). Of these, 8 (40%) were ctxA positive. The most frequent resistances were to ceftriaxone (90%), amoxicillin (90%), tetracycline (85%), gentamicin (80%), while the highest susceptibility was found for ceftazidime (95%), imipenem (90%) and streptomycin (90%). When tested in mice, the purified toxin caused localized injury to mucosa which led to neutrophilic infiltration with patchy ulceration. When the whole bacterium was inoculated, extensive mucosal necrosis and hemorrhage appeared, along with disruption of the intestinal architecture. The livers of mice exposed to either the toxin or the whole bacterium showed inflammatory cell infiltration, congestion of the central vein, patches of necrosis, and vacuolated hepatocytes. The changes in the lungs of both groups were mild (congestion and focal inflammatory infiltrates).

**Conclusion:** Given the conditions of our experiments, the whole *V. cholerae* produced extensive intestinal mucosal damage compared to the purified toxin, while similar effects were seen on the liver in both cases with only slight changes in the lung. These findings are of a descriptive nature and would require a quantitative assessment of tissues and a proper statistical analysis to support them.

**Corresponding Information:** **Taghreed Khudhur Mohammed**, Department of Medical Laboratory Techniques, Institute of Medical Technology - Al-Mansour, Middle Technical University, Baghdad, Iraq. Email: taghreidkheder@mtu.edu.iq

**Copyright © 2026.** This is an open-access article distributed under the terms of the **Creative Commons Attribution 4.0 International License (CC BY 4.0)**, which permits unrestricted use, distribution, and reproduction in any medium, provided the original work is properly cited. The license also allows users to adapt, remix, transform, and build upon the material for any purpose, including commercial use.

## Introduction

*Vibrio cholerae*, the bacterium which causes cholera, is one of the most clinically important species in the Vibrio genus because of its public health significance. *V. cholerae* is highly mobile and is an anaerobic, Gram-negative bacterium. It has a single, polar flagellum, enabling motility (1, 2). It is found in both marine and freshwater environments, and can colonize aquatic life such as plankton, eels, and fish (3, 4). Cholera is an illness with rapidly dehydrating diarrhea and is one of the more severe diseases which remains a global threat to public health after decades of research and control efforts (5, 6).

Since the beginning of the 19th century, seven major pandemics have been documented in the historical record, with the latest being the El Tor biotype of *V. cholerae* O1, which began in 1961 and spread throughout the continents of Asia, Africa, and America, representing the seventh case. (7, 8). A new serogroup, O139, was identified in the 1990s. It produces the same cholera toxin (CT) as the O1 serogroup, though it has

different surface antigens and a different epidemiological profile (9, 10).

In order to infect the intestinal tract, the bacterium has to survive the acidic environment of the stomach and adhere to epithelial cells. Toxin-coregulated pilus (TCP) assists in the delivery of CT to the cells (11, 12). The ctxA gene encodes the A subunit of the CT, which is enzymatically active and causes the secretion of water and chloride by stimulating adenylate cyclase after an ADP-ribosylation of a G protein, which causes an increase in cyclic AMP (13). Detection of ctxA by PCR is an indication of the presence of the pathogenic strain of *V. cholerae* (14, 15).

While it is unquestionable that CT is the main virulence factor, it is unknown whether the toxin, when purified, is capable of reproducing the totality of the damage that the live bacteria are capable of causing. There are very few studies that, in a controlled experimental framework, compare in vivo the exposure of tissues to pathogenic bacteria and the exposure to the toxin.

## Materials and Methods

### Study Design and Ethical Approval

This experimental study was conducted between 2022 and 2023 at Al-Karama Hospital, Baghdad, Iraq. A total of 250 enteric specimens, including 200 stool samples and 50 rectal swabs, were collected from patients with suspected cholera. Written informed consent was obtained from all participants or their guardians before sampling. The experimental design and animal procedures were reviewed and approved by the Institutional Ethics Committee of the Institute of Medical Technology–Al-Mansour (Approval No.: IMT-BIO-2022-17) and performed in accordance with the ARRIVE guidelines for animal research.

### Isolation and Identification of *Vibrio cholerae*

Samples were initially enriched in alkaline peptone water (pH 8.6) for 6 h at 37 °C and then cultured on thiosulfate-citrate-bile-salts-sucrose (TCBS) agar and MacConkey agar. Prior to enrichment, specimens were stored up to 30 days in Cary-Blair transport medium and pre-cultured for three days on sea-salt agar. Colonies with characteristic yellow morphology on TCBS were further subcultured for biochemical and serological testing.

Identification was based on colony morphology, Gram staining, and standard biochemical reactions following Bergey's Manual of Systematic Bacteriology (16). The isolates were oxidase-positive, motile, and facultatively anaerobic. Additional confirmatory tests included indole, methyl red, Voges–Proskauer, citrate utilization, urease, $H_2S$ production, and carbohydrate fermentation (lactose, sucrose, and mannitol). Serotyping was performed using a Combo Rapid Test with monovalent O1 antisera.\

### Antimicrobial Susceptibility Testing

Antibiotic susceptibility of all *V. cholerae* isolates was evaluated by the Kirby–Bauer disk diffusion method on Mueller–Hinton agar (17). The antibiotic panel included gentamicin (10 µg), ceftriaxone (30 µg), imipenem (10 µg), ceftazidime (30 µg), tetracycline (30 µg), amoxicillin (30 µg), and streptomycin (10 µg). *Escherichia coli* ATCC 25922 served as a quality-control strain. Zone diameters were interpreted based on CLSI (18) standards. Each test was replicated three times.

### Preparation of *V. cholerae* for Inoculation Studies

For the animal studies, freshly isolated *V. cholerae* were cultured in LB broth and incubated overnight at 37 °C with shaking. 8000 rpm centrifugation for 10 minutes was followed by two washes in LB broth and resuspension in sterile saline. *V. cholerae* were diluted to a concentration of $10^2$, $10^4$, $10^6$, and $10^8$ CFU/mL (19) based on OD at 600 nm. Counts were confirmed by a TCBS agar plate count.

### Production and Purification of Cholera Enterotoxin

Enterotoxin production followed the protocol of Mekalanos et al (20) Mekalanos et al (21) with modifications. Briefly, 500 mL of Brain-Heart Infusion broth was inoculated with a toxigenic *V. cholerae* isolate and incubated at 37 °C for 24 h. Cultures were centrifuged at 6000 rpm for 30 min at 4 °C, and supernatants were filtered through a 0.22 µm Millipore membrane. Enterotoxin activity was preliminarily screened using the newborn-suckling-mouse assay (22, 23). Crude toxin was further purified by Sephacryl S-6 gel filtration chromatography, and protein concentration was quantified by the bovine serum albumin (BSA) standard curve method (24).

### Experimental Animals and Cytopathic-Effect Study

Healthy albino mice (6 weeks old, 25 ± 2 g) were obtained from the Animal House Unit of the Institute of Medical Technology. Animals were acclimatized for 7 days under controlled temperature (22 ± 2 °C), 12-h light/dark cycle, and ad libitum access to food and water. Mice were randomly allocated into three groups (n = 6 each):

Group I (Control): Received 1 mL of sterile normal saline via intraperitoneal injection.

Group II (Toxin): Received 1 mL of partially purified cholera toxin at two dilutions (1/10 and 1/20), at concentrations of 55 µg/mL and 45 µg/mL, respectively.

Group III (Bacteria): Received 1mL of live *V. cholerae* suspension ($10^6$ CFU/mL).

For the following 5 days, the activity, appetite, diarrhea, and lethargy of the animals were monitored. The remaining mice were euthanized using $CO_2$

inhalation. Tissues from the liver, small intestines, and lungs were collected for histopathological assessment.

### Histopathological Examination

Tissue samples underwent a series of steps including fixation in 10% neutral buffered formalin, a dehydration step using a graded ethanol series, a clearing step using xylene, and embedding in paraffin at 60 °C. A rotary microtome sliced paraffin embedded tissues into 5 µm thick sections which were coated with Myer's albumin and dried at 37 °C overnight. Dry coated slides were stained using the H&E method of Humason (1962). A light microscope at 400× was used to examine each stained tissue section and a qualitative assessment of the lesions was provided by two independent pathologists who were blinded to the study groups. The lesions were assigned a severity score (0 = none, 1 = mild, 2 = moderate, 3 = severe) using a semi-quantitative scale.

### DNA Extraction and PCR Detection of the *ctxA* Gene

The genomic DNA extraction was done using overnight cultures grown on nutrient agar using chloroform phenol method (TransGene, China, kit protocol). The ctx A gene was amplified using standard PCR in an Eppendorf thermocycler (USA). The reaction mixture (25 µL) contained 3 µL template DNA, 0.2 µL (100 µM) forward primer 5'-CGGGCAGATTCTAGACCTCCTG-3' and its reverse complement Aldoori et al (14), 2.5 µL dNTP (2 mM), 0.125 µL Taq polymerase (5 U/µL), 2.5 µL 10× buffer, 1.25 µL $MgCl_2$ (50 mM), and the rest was nuclease free water. The initial denaturation was 95 °C for 5 min followed by 30 cycles of denaturation, annealing, and extension at 95 °C for 30 sec, 65 °C for 30 sec and 72 °C for 1 min respectively. The final extension was done at 72 °C for 5 min. The PCR products were run on 1.5% agarose gel with ethidium bromide. The PCR products were viewed in a UV transilluminator (Labent, USA) with a 100 bp DNA ladder. The amplicon size of ctx A gene was expected to be 565 bp.

### Statistical Analysis

All the experiments were performed in triplicates. The quantitative data (bacterial recovery rates, lesion scores etc.) were analyzed by Graphpad Prism v9.0. The data were shown as the mean ± standard deviation (SD). One way ANOVA with Tukey's post hoc was used for comparisons. p value of $< 0.05$ was viewed as statistically significant.

Diagram summarizing the workflow for bacterial isolation, biochemical and serological identification, antibiotic susceptibility testing, toxin production, animal inoculation, and ctxA gene detection (Fig.1).

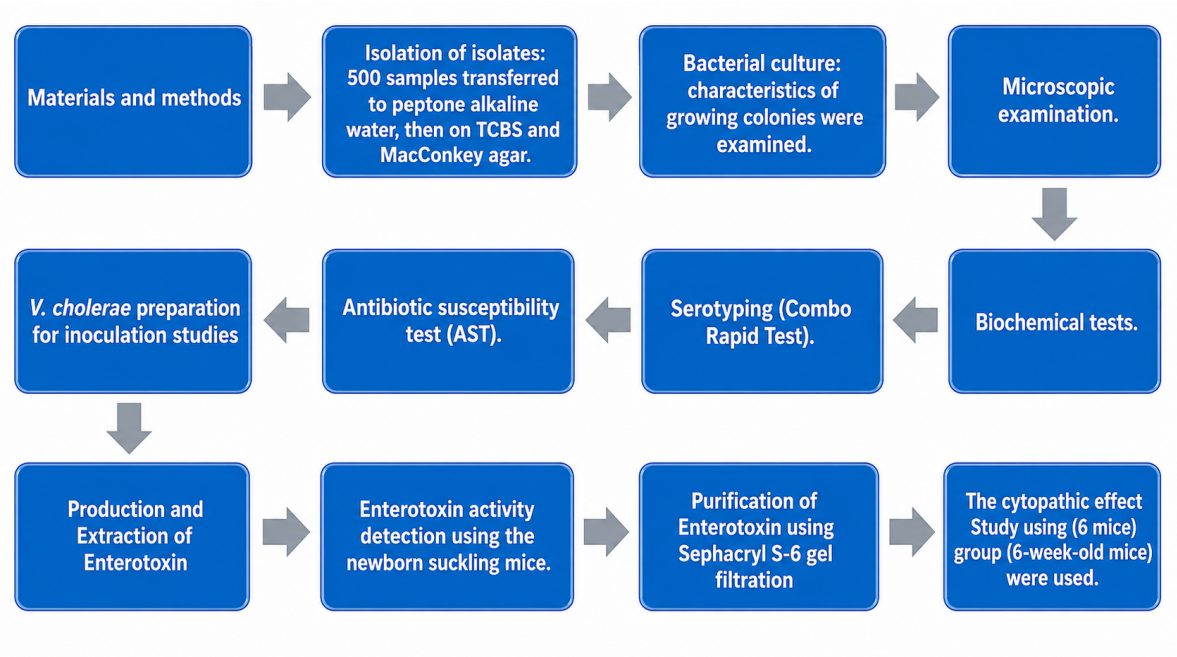


**Fig. 1.** Diagram of methods for isolation, diagnosis, antibiogram for *V. cholerae* and study of the cytopathic effects

## Results

### Isolation and Identification of *Vibrio cholerae*

Out of 250 enteric samples collected from suspected cholera cases (200 fecal and 50 rectal swabs), 20 (8%) yielded *Vibrio cholerae* (18 from fecal samples and 2 from rectal swabs), while 230 (92%) were negative (Table 1, Fig. 2). The isolates formed characteristic yellow colonies on TCBS agar and were Gram-negative, motile, oxidase-positive, and facultatively anaerobic.

**Table 1.** Results of cultures of the study samples

| Samples | Positive (%) | Negative (%) | Total (%) |
|---|---|---|---|
| **Faecal** | 18 (7.2%) | 182 (72.8%) | 200(80%) |
| **Rectal swab** | 2 (0.8%) | 48 (19.2%) | 50(20%) |
| **Total** | 20 (8%) | 230 (92%) | 250 (100%) |

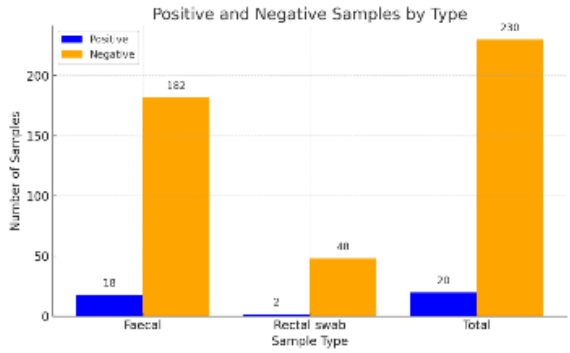


**Fig. 2.** Distribution of positive and negative *V. cholerae* cultures by sample type.

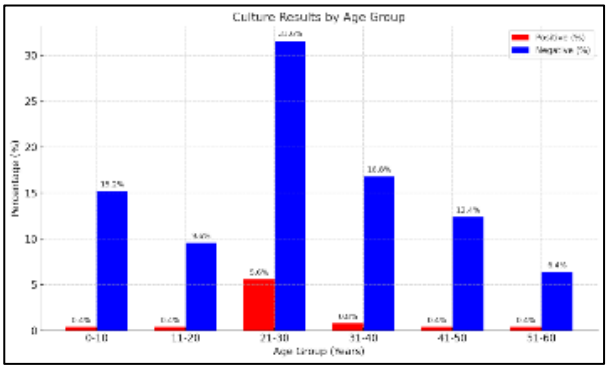


**Fig. 3.** Distribution of *V. cholerae* positive and negative cultures according to patient age group.

## Age Distribution

As shown in Fig. 3, *V. cholerae* infection was most frequent in patients aged 21–30 years (5.6% of total samples), followed by 31–40 years (0.8%) and 0–10 years (0.4%). The lowest detection rates were recorded in older age groups (> 40 years).

## Biochemical and Serological Identification

All isolates were indole-, methyl-red-, oxidase-, urease-, and citrate-positive, with β-hemolytic activity on blood agar. All were negative for $H_2S$ production and lactose fermentation but fermented sucrose and mannitol. The isolates agglutinated with *V. cholerae* O1 antiserum (Table 2).

**Table 2.** Diagnostic characteristics of *Vibrio cholerae* isolates.

| Test | Result | Test | Result |
|---|---|---|---|
| **Gram stain** | Negative | Voges–Proskauer | Variable (+/–) |
| **Indole** | Positive | Urease | Positive |
| **Motility** | Positive | Methyl red | Positive |
| **Oxidase** | Positive | $H_2S$ | Negative |
| **Simmon-citrate** | Positive | Blood hemolysis | β-hemolysis |
| **Serotype** | O1 | Carbohydrate fermentation | Lactose (–); Sucrose (+); Mannitol (+) |

## Antimicrobial Susceptibility

Resistance and sensitivity profiles are summarized in Table 3 and Fig. 4. *V. cholerae* isolates exhibited high resistance to ceftriaxone (90%), amoxicillin (90%), tetracycline (85%), and gentamicin (80%). Conversely, high susceptibility was observed to ceftazidime (95%), imipenem (90%), and streptomycin (90%).

## Clinical Signs and Gross Pathology in Mice

Three days post-injection, mice exposed to purified toxin developed lethargy, diarrhea, and reduced food intake. Gross examination revealed intestinal bloating and hepatic congestion in toxin- and bacterium-treated groups, but no visible abnormalities in controls.

## Histopathological Findings

### Liver

Hepatic architecture in control animals was normal with well-organized cords of hepatocytes with central veins (Fig. 5a). Infected mice had Dilation of the hepatic sinusoids, lymphocytic infiltration, and focal necrosis. Toxin injected animals had hepatocellular swelling, multinucleation and foamy hepatocellular cytoplasm (Fig. 5b–c).

**Table 3.** Antibiotic susceptibility of *Vibrio cholerae* isolates (n = 20).

| Antibiotic (µg/disc) | Sensitive n (%) | Resistant n (%) |
|---|---|---|
| **Gentamicin (10)** | 4 (20) | 16 (80) |
| **Ceftriaxone (30)** | 2 (10) | 18 (90) |
| **Imipenem (10)** | 18 (90) | 2 (10) |
| **Ceftazidime (30)** | 19 (95) | 1 (5) |
| **Tetracycline (30)** | 3 (15) | 17 (85) |
| **Amoxicillin (30)** | 2 (10) | 18 (90) |
| **Streptomycin (10)** | 18 (90) | 2 (10) |

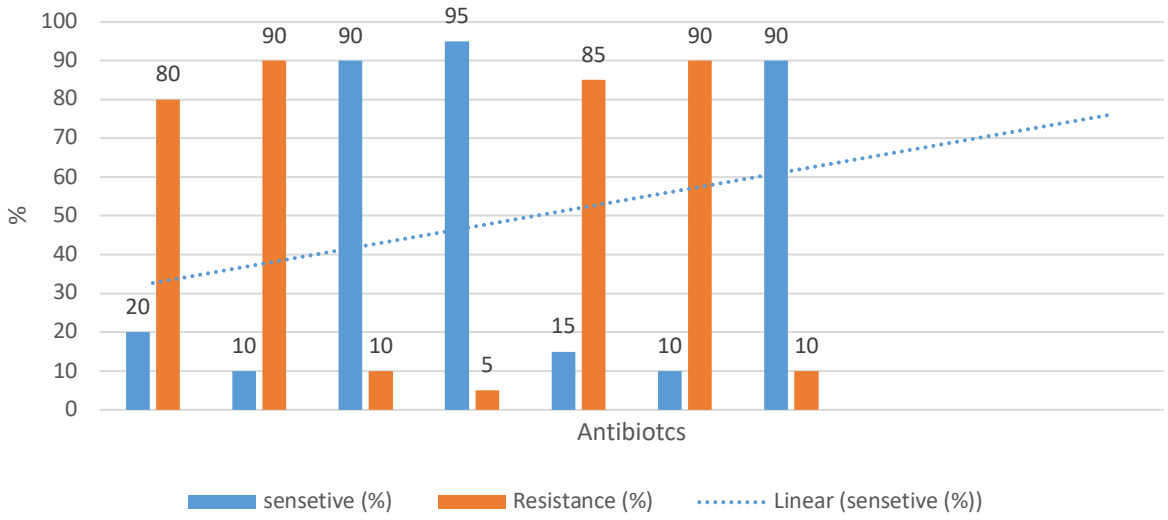


**Fig. 4.** Antibiotic susceptibility profile of *V. cholerae* isolates.

CAZ = ceftazidime; IMP = imipenem; CRO = ceftriaxone; GM = gentamicin; TE = tetracycline; AM = amoxicillin; S = streptomycin.

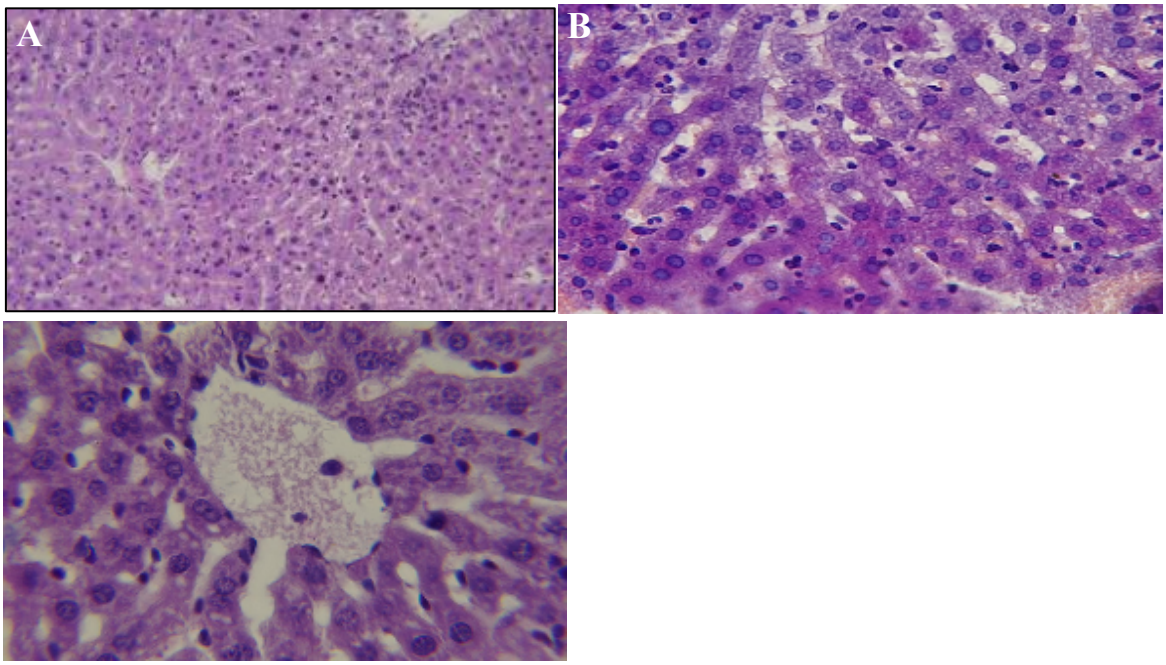


**Fig 5.** Representative histological sections of mouse liver (H&E, 400×): (a) control; (b) *bacterium-inoculated*; (c) *toxin-injected* groups.

### Small Intestine

In control intestinal sections, villi and the epithelium were intact and the architecture of the intestinal crypts was normal. Mice injected with virulent *V. cholerae* had blunt villi, necrosis of the epithelium, and extensive infiltration of neutrophils into the lamina propria. Toxin treated mice had less villous atrophy and infiltrating neutrophils were less (Fig. 6). The extent of injury of the intestinal epithelium was more in the bacterial group than in the toxin group ($p < 0.05$)..

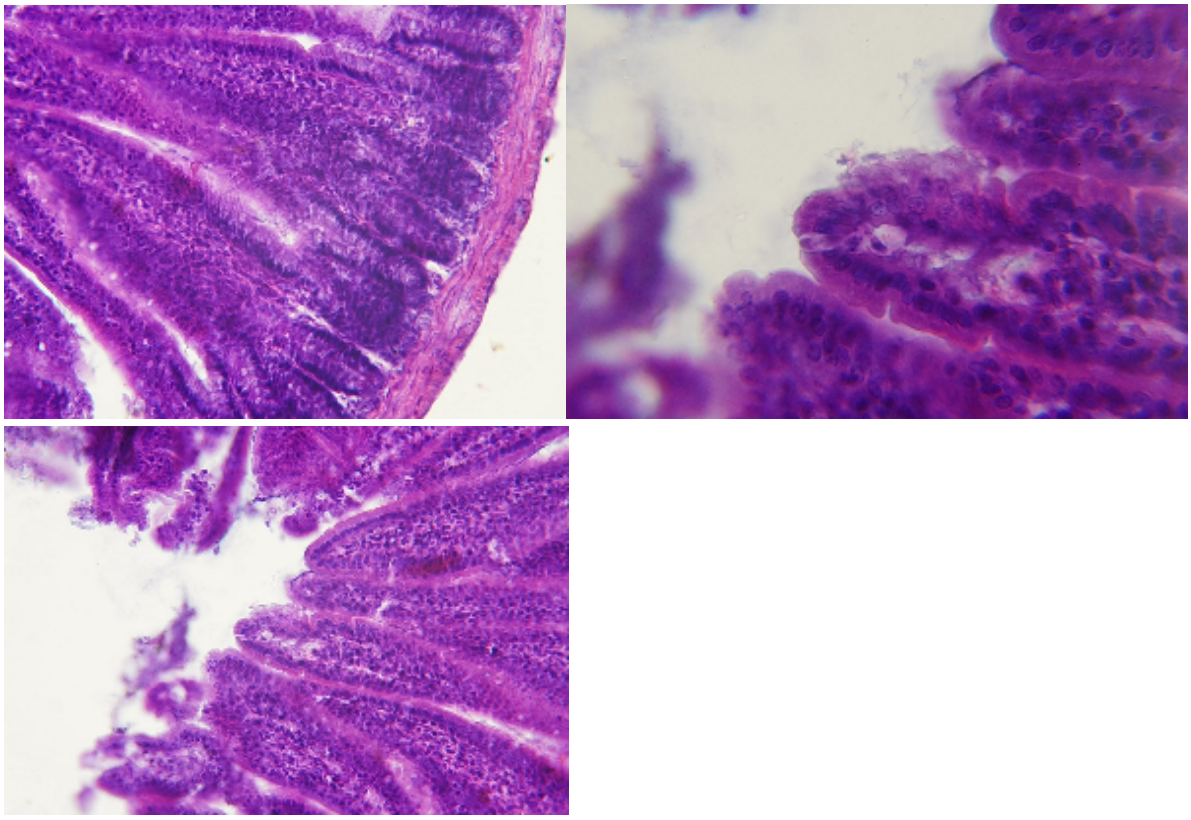

**Fig. 6.** Small intestine of female mice after being dosed with cholera toxin only.

### Lung

Histological examination of the lung in both experimental groups showed mild congestion of the alveoli with focal hemorrhage and Perivascular infiltration of inflammatory cells (Figures 7–8). Control lungs were normal.

### Detection of the *ctxA* Gene

Amplification of the ctxA gene by PCR was achieved in 8 of the 20 (40%) isolates where the amplicon size was 565 bp (Fig. 9). ctxA positive isolates had greater pathogenicity in the animal models and greater resistance to antibiotics than the ctxA negative strains.

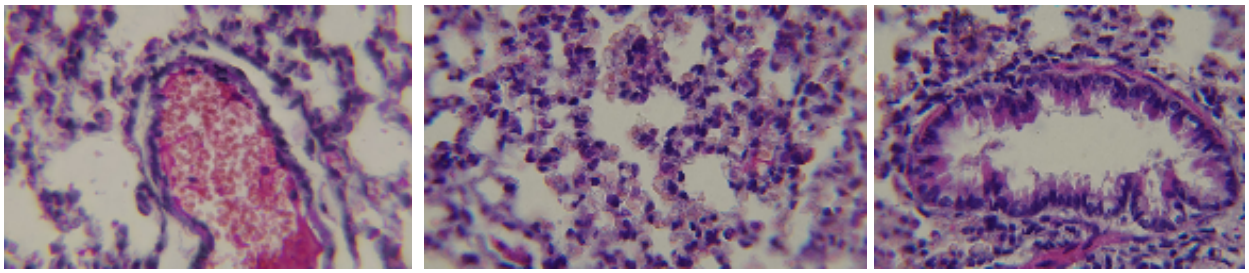

**Fig. 7.** Lungs of female mice injected with cholera bacteria

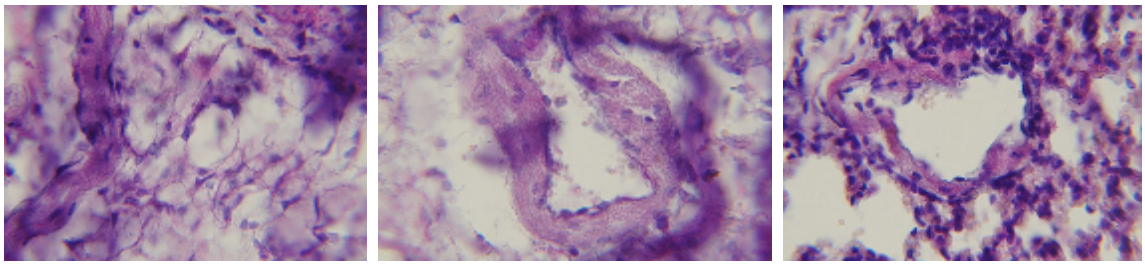

**Fig. 8.** Lungs of male mice injected with cholera bacteria

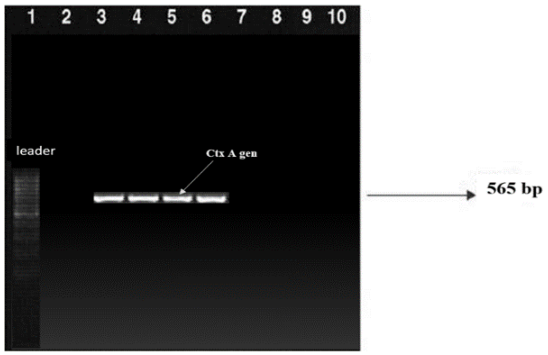


**Fig. 9.** PCR detection of *ctxA* gene in *V. cholerae* isolates showing 565 bp product on 1.5% agarose gel stained with ethidium bromide.

## Discussion

This study characterized clinical isolates of *Vibrio cholerae* from Baghdad with respect to antimicrobial profiles, molecular characteristics, and their histopathological effects in experimental mice. The 8% isolation rate from 250 enteric samples is consistent with reports from Iraq and other cholera-endemic countries. The cholera serotypes were defined by Inaba 55%, Ogawa 32.5%, and Non-O1 12.5%. is consistent with reports describing vibrios with yellow colonies on TCBS agar and characteristic biochemical reactions of gram-negative, motile, oxidase and indole-positive that confirmed the continuing significant clinical impact of *V. cholerae* on the Iraqi population.

The detected pattern of antimicrobial resistance entailed high resistance levels to the β-lactams and to tetracycline with isolates retaining susceptibility to ceftazidime, imipenem and streptomycin. This reflects the global resistance patterns of V. cholerae and the role of resistance plasmids and mobile genetic elements., In contrast to our findings, Iramiot et al (29) noted complete susceptibility to gentamicin in isolates from Uganda. This difference points to the unexplained impact of antibiotic prescribing practices and the use of antibiotics on the cholera disease in the region. In view of the observed patterns of resistance, there is an urgent need for the appropriate use of antibiotics and implementation of resistance surveillance to minimize the risk of therapeutic failure during forthcoming cholera outbreaks.

Using molecular analysis, the ctxA gene was found in 40% of the isolates, producing a 565-bp PCR amplicon similar to Aldoori *et al's* (14) toxigenic *V. cholerae*. The histopathological analysis of the ctxA-positive isolates showed more damage, relating to the greater concern of cholera toxin in pathogenesis. ctxA is cholera toxin's A subunit, and when released, it activates adenylate cyclase which stimulates cellular chloride secretion. This results in diarrhea, the hallmark of cholera (30, 31). There is variation in the distribution of ctxA in different regions. Hamad and Hamad (32) reported no ctxA amplification in isolates from Baghdad. From this, we can assume that Baghdad may experience cholera outbreaks from both toxigenic and non-toxigenic *V. cholerae*.

The histopathological changes give insight on the damage caused by *V. cholerae*. Both live bacteria and their purified toxin caused damage to the intestinal mucosa, though the effects differ. Toxin administration caused moderate damage to mucosa, while bacterial inoculation led to extensive destruction, hemorrhage, and ulceration. This is similar to the observations of Polotsky et al (33) and Mohammed and Hasan (34). The worsened lesions from bacterial suspension reflect the combined effects of bacterial adhesion, secretion of the toxin, and the inflammatory response of the host.

Early findings by Farthing (35) and Johnson et al (36) proposed that some serogroups, namely O1 and O139, may have other virulence factors, such as capsular polysaccharide layers, which may provide serum resistance and help them persist in the tissues of the host. Studies using electron microscopy showed that Bengal O139 strains have the ability to disrupt the apical epithelium and invade the lamina propria, causing mucosal ulceration and inflammation of the submucosa (37, 38). Current observations of

considerable intestinal necrosis and lamina propria infiltration also support these findings.

Microscopic examination of liver tissues of both bacteria- and toxin-treated showed hepatocellular degeneration and lymphocytic infiltration with congestion of the central vein. The same findings were reported in the studies of exposure to experimental cholera toxin, where changes to cholera toxin altered microcirculation to the liver (35). Changes to the lungs were also mild and showed congestion with minimal inflammatory infiltration, which were more likely indirect effects of the immune system rather than direct effects of bacterial infection, since *V. cholerae* is reported to be a non-invasive bacterium and does not infect the lung tissues. However, previous studies have also shown that high-dose cholera toxin can promote the proliferation of Type II pulmonary epithelial cells and can also induce the release of interleukin-6, a potent inflammatory cytokine, and macrophage inflammatory protein-2 (39, 40).

The demographics of this study show that the majority of the cases are among young adults (21-30), which is similar to the findings of Al-Sa'ady *et al* (41) in the 2017 cholera outbreak in Iraq. The persistence of the disease can be attributed to continued environmental and socioeconomic factors such as contaminated water supplies, inadequate sanitation, and poor hygienic practices resulting in a high population density.

When considering the findings in their totality, it can be concluded that Iraqi *V. cholerae* are highly virulent and multidrug resistant. CtxA-positive strains are more virulent in the studies we conducted. We found that in the presence of live pathogens, the toxin causes even more severe damage to the gut and liver. This confirms that the disease process is complex and includes the production of toxin, bacterial colonization, and various host inflammatory responses. Strategies to control cholera in endemic areas include improving water quality, developing rapid tests to detect the presence of virulent bacteria, and using antibiotics with great care.

## Conclusion

This study shows that *V. cholerae* obtained from patients in Iraq are resistant to multiple drugs and that their toxin production is variable. In our studies, we found that the presence of *V. cholerae* in live form caused more damage to the gut and liver than the cholera toxin alone, which indicates that colonization of the bacteria and the inflammatory response of the host are important factors in the process of disease along with the toxin. The detection of the ctxA gene in 40% of the isolates gives evidence of the presence of virulent bacteria in this region. Our findings call for the urgent need for improved water sanitation, appropriate use of antibiotics, and a monitoring system to detect *V. cholerae*.

## Acknowledgments

The authors thank the staff of the Microbiology Laboratory, Institute of Medical Technology–Al-Mansour, for technical support and animal care assistance.

## Authors' Contributors

K.A.H. and T.K.M. designed the study and supervised laboratory work. Z.S.J. performed molecular and histopathological analyses. All authors contributed to manuscript writing and approved the final version.

## Data Availability

The data supporting the results of this study are available upon request from the corresponding author.

## Funding

This research received no specific grant from any funding agency in the public, commercial, or not-for-profit sectors

## Ethics Approval

All animal procedures were approved by the Institutional Ethics Committee of the Institute of Medical Technology–Al-Mansour, Baghdad (Approval No. IMT-BIO-2022-17).

## Consent to Participate:

Follow-up data, including recurrence status, were obtained through direct contact with patients or their companions. The study utilized an open-access article distribution under the Creative Commons Attribution 4.0 International License (CC BY 4.0).

## Declaration of AI

During the preparation of this manuscript, the authors utilized advanced language models solely to enhance the grammatical structure, refine the English readability, and assist with programmatic text formatting. Following this linguistic optimization, the authors thoroughly reviewed, cross-referenced, and edited the text to ensure accuracy. The authors maintain full accountability for the integrity of the experimental design, the histopathological findings in the animal models, the molecular data, and the final scientific conclusions presented in this study.

## Conflict of Interest

The authors declared no conflict of interest.

## References


1. McLeod SM, Kimsey HH, Davis BM, Waldor MK. CTXphi and Vibrio cholerae: exploring a newly recognized type of phage-host cell relationship. Mol Microbiol. 2005;57(2):347-56. [DOI:10.1111/j.1365-2958.2005.04676.x] [PMID]
2. Kar P, Das TK, Ghosh S, Pradhan S, Chakrabarti S, Mondal KC, et al. Characterization of a Vibrio-infecting bacteriophage, VPMCC5, and proposal of its incorporation as a new genus in the Zobellviridae family. Virus Res. 2022;321:198904. [DOI:10.1016/j.virusres.2022.198904] [PMID]
3. King AA, Ionides EL, Pascual M, Bouma MJ. Inapparent infections and cholera dynamics. Nature. 2008;454(7206):877-80. [DOI:10.1038/nature07084] [PMID]
4. Ina-Salwany MY, Al-Saari N, Mohamad A, Mursidi FA, Aris AM, Amal MN, et al. Vibriosis in fish: a review on disease development and prevention. J Aquat Anim Health. 2019;31(1):3-22. [DOI:10.1002/aah.10045] [PMID]
5. Mishra A, Taneja N, Sharma M. Environmental and epidemiological surveillance of Vibrio cholerae in a cholera-endemic region in India with freshwater environs. J Appl Microbiol. 2012;112(1):225-37. [DOI:10.1111/j.1365-2672.2011.05191.x] [PMID]
6. Chowdhury F, Ross AG, Islam MT, McMillan NA, Qadri F. Diagnosis, management, and future control of cholera. Clin Microbiol Rev. 2022;35(3):e0021121. [DOI:10.1128/cmr.00211-21] [PMID] [PMCID]
7. Barua D. History of cholera. In: Barua D, Greenough WB 3rd, editors. Cholera. New York: Plenum Medical Book Company; 1992. p. 1-36. [DOI:10.1007/978-1-4757-9688-9_1]
8. Swerdlow DL, Isaäcson M. The epidemiology of cholera in Africa. In: Wachsmuth IK, Blake PA, Olsvik O, editors. Vibrio cholerae and cholera: molecular to global perspectives. Washington (DC): American Society for Microbiology; 1994. p. 297-307. [DOI:10.1128/9781555818364.ch19]
9. Ramamurthy T, Garg S, Sharma R, Bhattacharya SK, Nair GB, Shimada T, et al. Emergence of novel strain of Vibrio cholerae with epidemic potential in southern and eastern India. Lancet. 1993;341(8846):703-4. [DOI:10.1016/0140-6736(93)90480-5] [PMID]
10. Garg S, Saha PK, Ramamurthy T, Deb BC, Nair GB, Shimada T, et al. Nationwide prevalence of the new epidemic strain of Vibrio cholerae O139 Bengal in India. J Infect. 1993;27(1):108-9. [DOI:10.1016/0163-4453(93)94398-U] [PMID]
11. Taylor RK, Miller VL, Furlong DB, Mekalanos JJ. Use of phoA gene fusions to identify a pilus colonization factor coordinately regulated with cholera toxin. Proc Natl Acad Sci U S A. 1987;84(9):2833-7. [DOI:10.1073/pnas.84.9.2833] [PMID] [PMCID]
12. Zhou Q, Zhu X, Li Y, Yang P, Wang S, Ning K, et al. Intestinal microbiome-mediated resistance against vibriosis for Cynoglossus semilaevis. Microbiome. 2022;10(1):153. [DOI:10.1186/s40168-022-01346-4] [PMID] [PMCID]
13. Wachsmuth K, Olsvik Ø, Evins GM, Popovic T. Molecular epidemiology of cholera. In: Wachsmuth IK, Blake PA, Olsvik O, editors. Vibrio cholerae and cholera: molecular to global perspectives. Washington (DC): American Society for Microbiology; 1994. p. 357-70. [DOI:10.1128/9781555818364.ch23]
14. Aldoori AA, Samawi FT, Ahmed K. Vibrio Cholera 22: Isolation and molecular detection of cholera toxin (CTX) in some Iraqi governorates. Erbil: Cihan University-Erbil; 2024. p. 391-5. [DOI:10.24086/biohs2024/paper.1337]
15. Castañeda-Chávez MR, Aguilar-Muslera RE, Reyes-Velázquez C, Lango-Reynoso F, Zamudio-Alemán RE, Salcedo-Garduño MG. Vibrio sp. and identification of the ctx gene of cholera toxin in the Mandinga coastal lagoon, Veracruz, Mexico. Microorganisms. 2025;13(2):352. [PMCID] [DOI:10.3390/microorganisms13020352] [PMID]
16. Guerrero R. Bergey's manuals and the classification of prokaryotes. Int Microbiol. 2001;4(2):103-9. [DOI:10.1007/s101230100021] [PMID]
17. Aw B. Antimicrobial susceptibility testing by a standardized single disk method. Am J Clin Pathol. 1966;45(4):493-6. [DOI:10.1093/ajcp/45.4_ts.493] [PMID]
18. Clinical and Laboratory Standards Institute. M100: Performance standards for antimicrobial susceptibility testing. 32nd ed. Wayne (PA): CLSI; 2022.
19. Wang H, Guo J, Chen X, He H. The metabolomics changes in Luria-Bertani broth medium under different sterilization methods and their effects on Bacillus growth. Metabolites. 2023;13(8):958. [DOI:10.3390/metabo13080958] [PMID] [PMCID]
20. Mekalanos JJ, Collier RJ, Romig WR. Purification of cholera toxin and its subunits: new methods of preparation and the use of hypertoxinogenic mutants. Infect Immun. 20(2):552-8. [PMCID] [DOI:10.1128/iai.20.2.552-558.1978] [PMID]
21. Mekalanos JJ, Collier RJ, Romig WR. Simple method for purifying choleragenoid, the natural toxoid of Vibrio cholerae. Infect Immun. 1977;16(3):789-95. [DOI:10.1128/iai.16.3.789-795.1977] [PMID] [PMCID]
22. Chatterjee D, Chaudhuri K. Association of cholera toxin with Vibrio cholerae outer membrane vesicles which are internalized by human intestinal epithelial cells. FEBS Lett. 2011;585(9):1357-62. [DOI:10.1016/j.febslet.2011.04.017] [PMID]
23. Wernick NL, Chinnapen DJ, Cho JA, Lencer WI. Cholera toxin: an intracellular journey into the cytosol by way of the endoplasmic reticulum. Toxins (Basel). 2010;2(3):310-25. [DOI:10.3390/toxins2030310] [PMID] [PMCID]
24. Abu-Resha R. Extraction and purification of Vibrio cholerae enterotoxin and study its cytopathic effect on some mice organs. Iraqi J Sci. 2013;54(3):502-7.

25. Saleh TH, Sabbah MA, Jasem KA, Hammad ZN. Identification of virulence factors in Vibrio cholerae isolated from Iraq during the 2007-2009 outbreak. Can J Microbiol. 2011;57(12):1024-31. [DOI:10.1139/w11-094] [PMID]
26. Zereen F, Akter S, Sobur MA, Hossain MT, Rahman MT. Molecular detection of Vibrio cholerae from human stool collected from SK Hospital, Mymensingh, and their antibiogram. J Adv Vet Anim Res. 2019;6(4):451-5. [DOI:10.5455/javar.2019.f367] [PMID] [PMCID]
27. Ceccarelli D, Alam M, Huq A, Colwell RR. Reduced susceptibility to extended-spectrum β-lactams in Vibrio cholerae isolated in Bangladesh. Front Public Health. 2016;4:231. [DOI:10.3389/fpubh.2016.00231] [PMID] [PMCID]
28. Shah MM, Bundi M, Kathiiko C, Guyo S, Galata A, Miringu G, et al. Antibiotic-resistant Vibrio cholerae O1 and its SXT elements associated with two cholera epidemics in Kenya in 2007 to 2010 and 2015 to 2016. Microbiol Spectr. 2023;11(3):e0414022. [DOI:10.1128/spectrum.04140-22] [PMID] [PMCID]
29. Iramiot JS, Rwego IB, Kansiime C, Asiimwe BB. Epidemiology and antibiotic susceptibility of Vibrio cholerae associated with the 2017 outbreak in Kasese district, Uganda. BMC Public Health. 2019;19(1): 1405. [DOI:10.1186/s12889-019-7798-6] [PMID] [PMCID]
30. Field M. Intestinal secretion: effect of cyclic AMP and its role in cholera. N Engl J Med. 1971;284(20):1137-44. [DOI:10.1056/NEJM197105202842008] [PMID]
31. Crothers JW, Norton EB. Recent advances in enterotoxin vaccine adjuvants. Curr Opin Immunol. 2023;85:102398. [DOI:10.1016/j.coi.2023.102398] [PMID] [PMCID]
32. Hamad MN, Hamad ON, editors. Surveillance of Vibrio cholerae antimicrobial resistance: a comparative analysis of serotyping and molecular identification methods in Iraq. Proceedings of the 3rd International Conference on Biotechnology; 2025; Iraq. Bristol (UK): IOP Publishing; 2025. [DOI:10.1088/1755-1315/1449/1/012160]
33. Polotsky YE, Dragunskaya EM, Samostrelsky AY, Vasser NR, Efremov VE, Snigirevskaya ES, et al. Interaction of Vibrio cholerae El Tor and gut mucosa in ligated rabbit ileal loop experiment. Med Biol. 1977;55(3):130-40.
34. Mohammed TK, Hasan KA. A histological study on the effect of Vibrio cholerae and its enterotoxin on pregnant mice. Int J Appl Sci Technol. 2024;6(3):470-87.
35. Farthing MJ. Enterotoxins and the enteric nervous system--a fatal attraction. Int J Med Microbiol. 2000;290(4-5):491-6. [DOI:10.1016/S1438-4221(00)80073-9] [PMID]
36. Johnson JA, Salles CA, Panigrahi P, Albert MJ, Wright AC, Johnson RJ, et al. Vibrio cholerae O139 synonym Bengal is closely related to Vibrio cholerae El Tor but has important differences. Infect Immun. 1994;62(5):2108-10. [DOI:10.1128/iai.62.5.2108-2110.1994] [PMID] [PMCID]
37. Koley H, Ghosh AN, Paul M, Ghosh AR, Ganguly PK, Nair GB. Colonization ability & intestinal pathology of rabbits orally fed with Vibrio cholerae O139 Bengal. Indian J Med Res. 1995;101:57-61.
38. Saha DR, Koley H, Ghosh AN, Nair GB. Sequential changes in gut mucosa of rabbits infected with Vibrio cholerae O139 Bengal: an ultrastructural study. J Diarrhoeal Dis Res. 1997;15(2):59-64.
39. Fullner KJ, Boucher JC, Hanes MA, Haines GK 3rd, Meehan BM, Walchle C, et al. The contribution of accessory toxins of Vibrio cholerae O1 El Tor to the proinflammatory response in a murine pulmonary cholera model. J Exp Med. 2002;195(11):1455-62. [DOI:10.1084/jem.20020318] [PMID] [PMCID]
40. Nag D, Dastidar DG, Chakrabarti G. Natural flavonoid morin showed anti-bacterial activity against Vibrio cholera after binding with cell division protein FtsA near ATP binding site. Biochim Biophys Acta Gen Subj. 2021;1865(8):129931. [DOI:10.1016/j.bbagen.2021.129931] [PMID]
41. Al-Sa'ady AT, Baqer KA, Al-Salim ZK. Molecular detection and phylogenetic analysis of Vibrio cholerae genotypes in Hillah, Iraq. New Microbes New Infect. 2020;37:100739. [DOI:10.1016/j.nmni.2020.100739] [PMID] [PMCID]