Iranian Journal of Pathology | ISSN: 2345-3656

Malignant Transformation of a Brain Neurenteric Cyst: A Case Report

Sareh Etemad[1], Golnaz Ghayyem Hassankhani[2]*, Masoumeh Gharib[3]

1. *Department of Pathology, Faculty of Medicine, Mashhad University of Medical Sciences, Mashhad, Iran*
2. *Mashhad University of Medical Sciences, Mashhad, Iran*
3. *Department of Pathology, Faculty of Medicine, Mashhad University of Medical Sciences, Mashhad, Iran*

KEYWORDS

Neurenteric cyst, malignant transformation, squamous cell carcinoma, squamous metaplasia

Scan to discover online

Main Subjects:
Neuropathology

Received 01 Dec 2025;
Accepted 17 Feb 2026;
Published Online 10 May 2026;

10.22034/ijp.2026.2078764.3596

ABSTRACT

Background & Objective: Neurenteric cysts (NCs) are rare, benign congenital anomalies originating from the endoderm, and they rarely undergo malignant transformation. Only a small number of such cases have been reported in the literature.

Case Report: A 55-year-old man presented with a one-month history of headache and diplopia. Magnetic resonance imaging (MRI) showed a 49 × 41 × 54 mm solid mass in the left frontal lobe, extending into the frontal, sphenoid, and ethmoid sinuses as well as the left orbit. The patient underwent craniotomy for tumor resection. Histopathology showed small remnants of a neurenteric cyst wall with squamous metaplasia and malignant transformation into squamous cell carcinoma (SCC). Immunohistochemistry revealed carcinoembryonic antigen (CEA) positivity in the cyst wall, focal epithelial membrane antigen (EMA) positivity in the tumor component, and diffuse nuclear expression of mutant p53 and Ki-67 in more than 80% of tumor cells.

Conclusion: We report a rare case of an intracranial NC that underwent malignant transformation into SCC. Intracranial SCC arising from an NC is uncommon. Moreover, unlike typical NCs, the lesion appeared as a solid mass without any visible cystic component on imaging, and cystic remnants were detected only microscopically. The absence of typical imaging features makes diagnosis challenging and highlights the importance of histopathologic examination for definitive diagnosis.

Corresponding Information: **Golnaz Ghayyem Hassankhani,** Mashhad University of Medical Sciences, Mashhad, Iran. Email: Golnazhassankhani@gmail.com

Copyright © 2026. This is an open-access article distributed under the terms of the **Creative Commons Attribution 4.0 International License (CC BY 4.0)**, which permits unrestricted use, distribution, and reproduction in any medium, provided the original work is properly cited. The license also allows users to adapt, remix, transform, and build upon the material for any purpose, including commercial use.

Introduction

Neurenteric cysts (NCs) are benign congenital anomalies originating from the endoderm (1,2). These cysts are covered by columnar or cuboidal epithelium similar to that found in the gastrointestinal and respiratory tracts (2). They typically contain mucoid material and protein (3).

Although NCs can occur anywhere along the central nervous system (CNS), they are most commonly found in the spine (4). Spinal NCs are approximately three times more common than intracranial NCs (5). Most intracranial NCs are located in the posterior fossa (6–8). These cysts often compress adjacent structures or cranial nerves and present with neurological symptoms (8,9). Headaches have been reported in nearly half of cases (10).

The pathogenesis of NCs is still unclear. It is hypothesized that incomplete closure of the neurenteric canal, a temporary duct connecting the amniotic cavity to the yolk sac during the third week of gestation, results in the displacement of endodermal cells and subsequent cyst formation (9,11). NCs are often associated with other abnormalities that share a similar pathogenesis, such as spinal anomalies, dermal defects, and abdominal or thoracic cysts (9,11).

Malignant transformation of neurenteric cysts is very rare (10). In this report, we describe a case of an intracranial NC that underwent malignant transformation into squamous cell carcinoma (SCC).

Case Report

A 55-year-old man presented to Ghaem Hospital in Mashhad, Iran, with a one-month history of headache and diplopia. Physical examination showed proptosis and ptosis of the left eye. The remainder of the physical examination, including otolaryngologic and dermatologic examinations, was normal. The patient had no significant past medical history or family history of malignancy.

Brain magnetic resonance imaging (MRI) revealed a solid mass measuring 49 × 41 × 54 mm located in the left frontal lobe. The mass extended into the frontal, sphenoid, and ethmoid sinuses, as well as the left orbit. It was associated with significant brain edema and mass effect (Fig. 1).

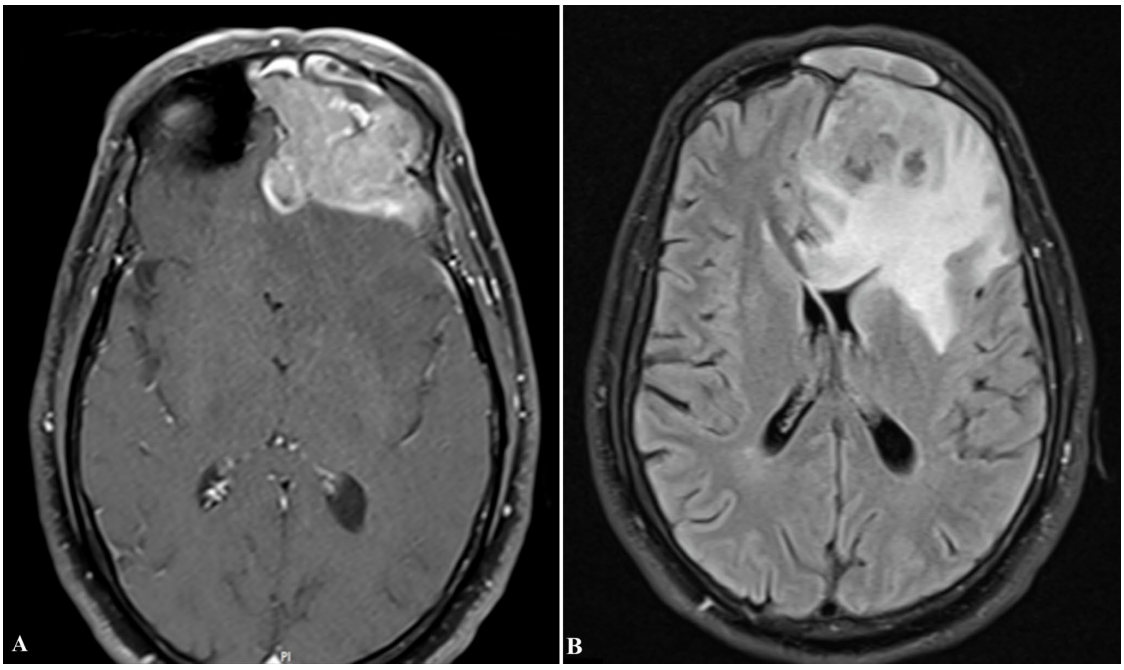

Fig. 1. (A-B) MRI of the brain shows a solid mass located in the left frontal lobe, measuring 49 × 41 × 54 mm, associated with surrounding brain edema and significant mass effect.

The patient underwent craniotomy for tumor resection. Histopathological examination of the resected specimen revealed small remnants of the neurenteric cyst wall, demonstrating ciliated pseudostratified columnar epithelium with squamous metaplasia and malignant transformation into SCC, involving over 80% of the cyst. This malignant transformation was characterized by highly pleomorphic squamous cell nests, mitotic figures, necrosis, and evidence of brain invasion (Figures 2 and 3).

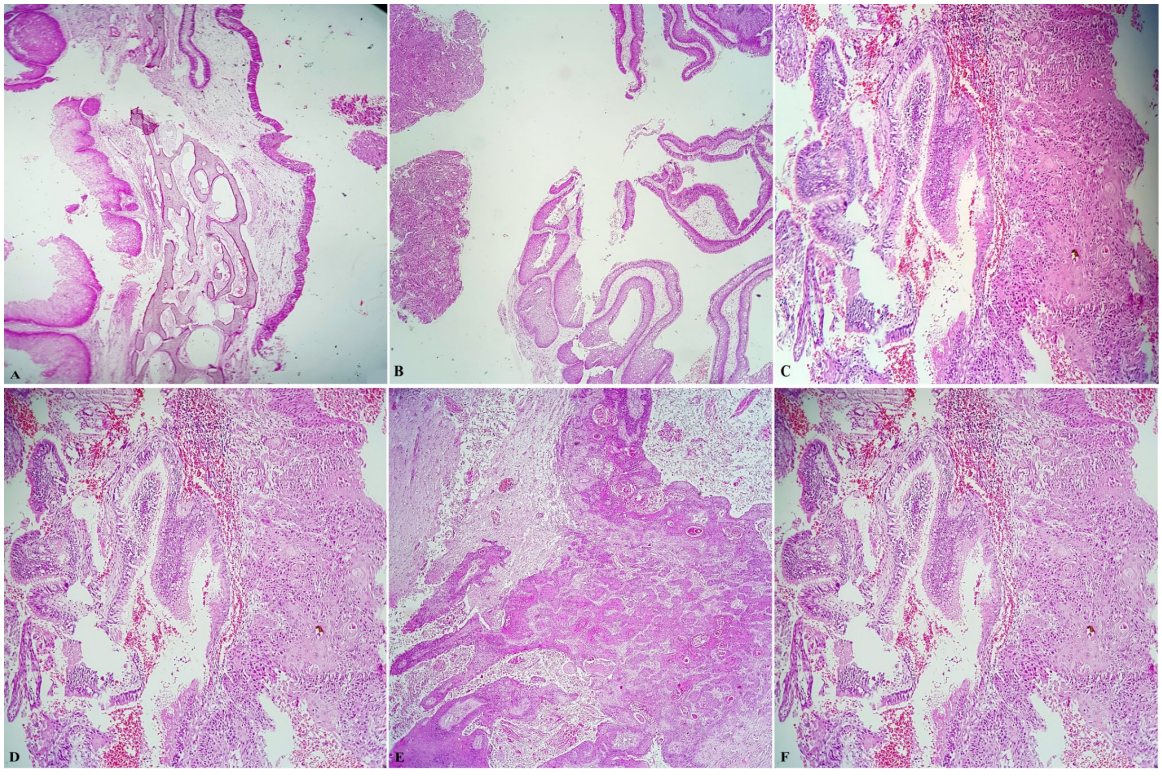

Fig. 2. (A-B) Neurenteric cyst wall resembling respiratory mucosa undergoing squamous metaplasia (40×). (C-D) Areas of the neurenteric cyst wall exhibiting squamous metaplasia (100×). (E-F) Dysplastic changes in the cyst wall with transformation into squamous cell carcinoma (100×).

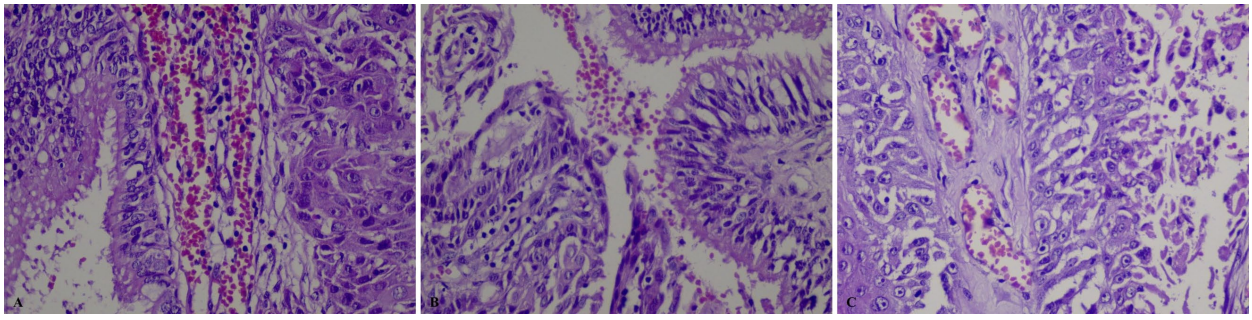

Fig. 3. (A-B) High-power view showing a neuroenteric cyst adjacent to SCC (400×). (C) High-power view demonstrating only the cystic component (400×).

Immunohistochemistry (IHC) showed positive staining of the neurenteric cyst wall with carcinoembryonic antigen (CEA), indicating an endodermal origin and a resemblance to intestinal tissue. Epithelial membrane antigen (EMA) was negative in the cyst epithelium but showed focal positivity in the tumor component. The carcinomatous areas showed aberrant (mutation-type) p53 expression, and Ki-67 staining revealed a high proliferative index in more than 80% of tumor cells (Fig. 4).

Postoperative MRI and spiral computed tomography (CT) scans showed changes at the surgical site, along with left frontal hyperintensity and edema. There was persistent mass effect on the lateral ventricle, causing a left midline shift and subfalcine herniation. No abnormal enhancement was observed after gadolinium administration. The patient refused further medical care and was discharged. Unfortunately, he passed away eight months later.

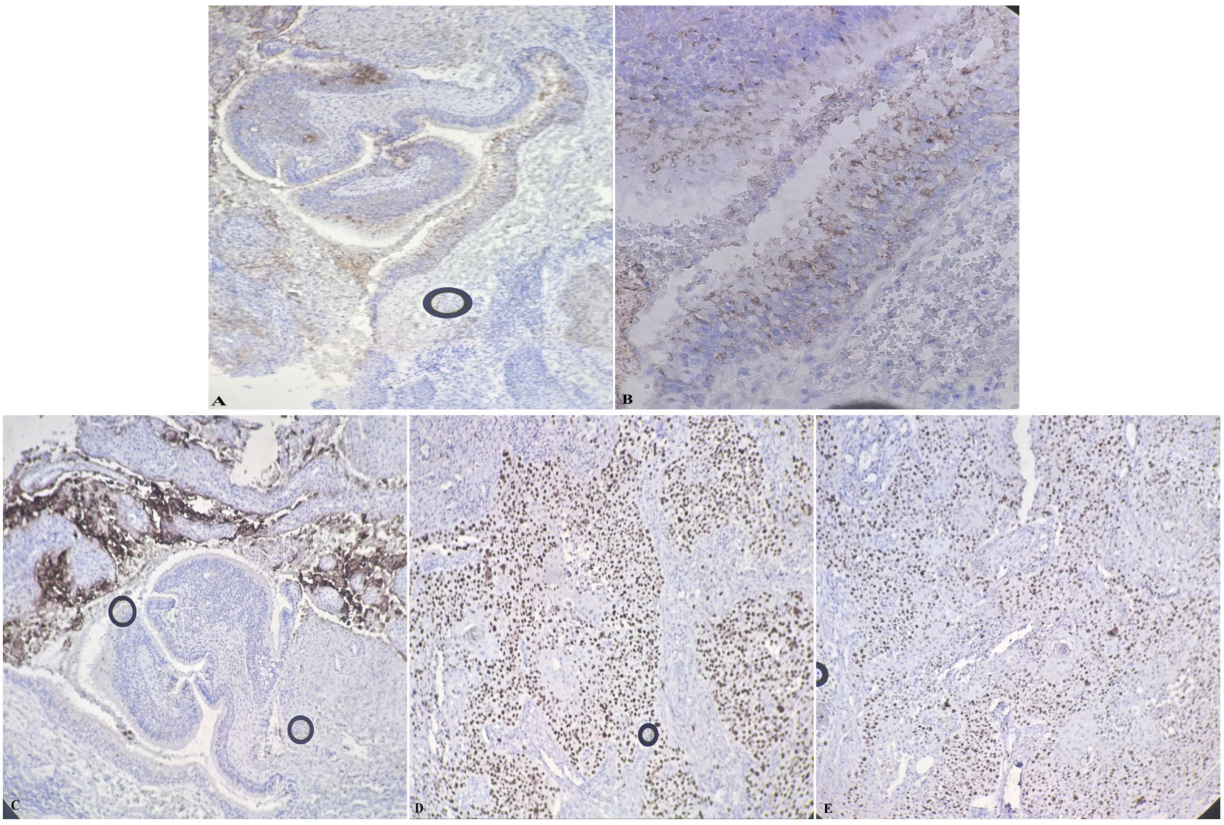

Fig. 4. Immunohistochemical staining findings. (A-B) CEA shows mild cytoplasmic positivity in the neurenteric cyst epithelium (A: 40×; B: 100×). (C) EMA staining is negative in the cyst epithelium but shows focal positivity in the carcinomatous component (40×). (D) Aberrant (mutational-type) p53 expression is observed in approximately 80% of tumor cells, with strong and diffuse nuclear staining (100×). (E) Ki-67 staining reveals a high proliferative index, with more than 80% of tumor cells positive (100×). The percentage of Ki-67–positive cells was calculated in hotspot regions and interpreted as nuclear staining, indicative of the proliferative index.

Table 1. Summary of the clinicopathological features of previously reported cases of neurenteric cysts with malignant transformation

Author(s)	Patient Age/Sex	Tumor Location	Malignant Transformation	Treatment	Outcome	Reference
Ho et al. (1998)	45/Female	Right parietal lobe	Well-differentiated papillary adenocarcinoma	Gross total resection	Stable	(18)
Sahara et al. (2001)	53/Male	left anterior cervicomedullary junction	Adenocarcinoma	Gross total resection, radiation, chemotherapy	Recurrence	(19)
Monaco et al. (2003)	36/Male	Cisterna magna, 4th ventricle	Carcinoma in situ	Gross total resection	Stable	(16)
Gessi et al. (2008)	25/Male	Right cerebellopontine angle	In situ papillary adenocarcinoma	Gross total resection	Recurrence, deceased	(14)
Wang et al. (2009)	26/Female	Left cerebellopontine angle	Columnar epithelium with atypical nuclei	Gross total resection, radiation	Metastasis	(6)
Dunham et al. (2009)	58/Female	Right parietal lobe	Invasive mucinous papillary cystadenocarcinoma	Gross total resection	Stable	(15)
Surash et al. (2009)	46/Male	Right cerebellopontine angle	Adenocarcinoma	Gross total resection, radiation	Stable	(20)
Okabe et al. (2014)	Late 50s/Female	Right cerebral hemisphere	Mucinous adenocarcinoma with broncho-pulmonary differentiation	Gross total resection	Stable	(17)
Fujisawa et al. (2015)	47/Female	Left cerebellopontine angle	Mucinous adenocarcinoma	Subtotal resection, radiation	Metastasis, deceased	(13)
Yang et al. (2016)	58/Female	Posterior to the medullar oblongata	Papillary adenocarcinoma	Subtotal resection	Deceased	(12)
Krivoshapkin et al. (2021)	33/Male	Suprasellar region	Mucinous adenocarcinoma	Minimally invasive surgery, radiation	Stable	(21)
Alanazi et.al (2025)	50/Female	Supratentorial	Adenocarcinoma	Gross total resection, radiation	Deceased	(22)

Discussion

ere, we report a rare case of an intracranial NC that underwent malignant transformation. The unique feature of this case is the presence of a solid brain mass with no visible cystic component on imaging. Cystic remnants were detected only on microscopic examination. The absence of a typical cystic component on imaging can make diagnosis challenging and increase the risk of misdiagnosis.

Neurenteric cysts are rare benign lesions and rarely undergo transformation into carcinomas (10). Malignant changes in NCs often occur in adults aged 25 to 60 years and may arise in primary NCs or in lesions that are initially benign but later become malignant upon recurrence (12). Reported cases of NCs with malignant transformation typically present as cystic or mixed cystic-solid lesions on imaging (13–17). In contrast, our case presented as a solid brain mass without any visible cystic component on imaging, and cyst remnants were detected only microscopically. This atypical presentation represents a unique diagnostic pitfall; therefore, we recommend thorough microscopic examination of all resected intracranial solid masses to avoid misdiagnosis.

Only a small number of NC cases with malignant transformation have been reported in the literature (Table 1). Most NCs with malignant changes have shown histopathologic features of adenocarcinoma (12–14,17–22). Some cases have exhibited a papillary adenocarcinoma pattern (12,14,18,19). Other malignant patterns included invasive papillary cystadenocarcinoma (15) and intraepithelial carcinoma (16). Okabe et al. reported a mucinous adenocarcinoma with bronchopulmonary differentiation developing from an NC, which resembled type I pulmonary cystic adenomatoid malformation (CCAM). However, this case did not have K-ras mutation and p16

overexpression, which are typical features of CCAM (17). In our case, the remnants of the NC wall showed squamous metaplasia and malignant transformation into SCC.

Intracranial SCCs usually originate from extracranial metastases or from the invasion of head and neck tumors (23), but they can rarely arise from epidermoid cysts (20). In this case, microscopic examination ruled out the possibility of metastatic SCC. The presence of neurenteric cyst wall remnants confirmed that the SCC originated from a preexisting NC rather than metastasis.

The exact mechanism for this malignant transformation is unclear. Several studies have suggested that repeated cyst rupture may trigger chronic inflammation, promoting cyst wall fibrosis and reactive gliosis in the adjacent brain tissue. These changes may result in squamous metaplasia and keratinization, and subsequent transformation into SCC (11,23). Others have proposed that KRAS mutation might be associated with malignant changes in NCs (25).

The limitation of this case report is the lack of comprehensive imaging studies, such as whole-body CT, PET-CT, or thoracic imaging, to rule out head and neck SCC due to financial limitations. Also, molecular profiling, such as KRAS mutation analysis, which could have provided evidence of malignant transformation and guided targeted therapies, was not available for the same reason.

Conclusion

In this study, we presented a rare case of intracranial SCC arising from an NC. Unlike typical NCs, which usually show a cystic component on imaging, our case uniquely appeared as a solid mass with no actual cyst on imaging. Such cases that lack typical imaging features are difficult to diagnose; therefore, histopathological examination is necessary for definitive diagnosis. Also, in cases of intracranial SCC, local extension or metastasis should be ruled out. Careful histopathological assessment is useful for distinguishing intracranial SCC arising in a benign cyst from metastatic carcinoma.

Acknowledgments

The authors would like to thank the Department of Pathology at Mashhad University of Medical Sciences and the team of clinicians involved in the patient's treatment.

Authors' Contributors

None.

Data Availability

The datasets generated and analyzed during the current study are not publicly available; however, the data can be shared for research and authentication purposes upon reasonable request.

Funding

This research received no specific grant from any funding agency in the public, commercial, or not-for-profit sectors.

Consent to Participate:

Written informed consent was obtained from the patient's legal next of kin for publication of this case report and accompanying images.

Ethics Approval

All identifying patient information was removed to protect privacy. Written informed consent for publication (text and images) was obtained from the patientThe procedures followed were in accordance with the ethical standards of the responsible committee on human experimentation (institutional and national) and with the Helsinki Declaration. Written informed consent was obtained from the patient for publication of this case report and accompanying images. A copy of the written consent is available for review by the Editor-in-Chief of this journal on request. No identifying information is included in the report.

Conflict of Interest

The authors declared no conflict of interest.

References

1. Chen CT, Lee CY, Lee ST, Chang CN, Wei KC, Wu CT. Neurenteric cysts: risk factors and management of recurrence. Acta Neurochir (Wien). 2016;158(7):1325-31. [DOI:10.1007/s00701-016-2828-y] [PMID]
2. Yagnik KJ, Vakharia K, Vaubel RA, Vizcaino MA, Benson JC, Daniels DJ, et al. Surgical Experience and Management of Intracranial Neurenteric Cysts: Single-Center Experience and Review of the Literature. J Neurol Surg B Skull Base. 2023;84(3):272-80. [DOI:10.1055/a-1775-0865] [PMID] [PMCID]
3. Ahuja S, Mankotia DS, Zaheer S. Enigmatic echoes: Exploring brainstem neurenteric cysts - A case series and literature review. Int J Surg Case Rep. 2024;117:109573. [DOI:10.1016/j.ijscr.2024.109573] [PMID] [PMCID]
4. Mittal S, Petrecca K, Sabbagh AJ, Rayes M, Melançon D, Guiot MC, et al. Supratentorial neurenteric cysts-A fascinating entity of uncertain embryopathogenesis. Clin Neurol Neurosurg. 2010;112(2):89-97. [DOI:10.1016/j.clineuro.2009.11.001] [PMID]
5. Wang L, Zhang J, Wu Z, Jia G, Zhang L, Hao S, et al. Diagnosis and management of adult intracranial

neurenteric cysts. Neurosurgery. 2011;68(1):44-52. [DOI:10.1227/NEU.0b013e3181fc5ee0] [PMID]

6. Wang W, Piao Y, Gui Q, Zhang X, Lu D. Cerebellopontine angle neurenteric cyst with focal malignant features. Neuropathology. 2009;29(1):91-5. [DOI:10.1111/j.1440-1789.2008.00930.x] [PMID]
7. Chu M, Wang L, Ye H, Li J, Lu D, Piao Y, et al. Meningeal carcinomatosis secondary to neurenteric cysts with malignant transformation: a case report. BMC Neurol. 2022;22(1):433. [DOI:10.1186/s12883-022-02978-7] [PMID] [PMCID]
8. Nosov IO, Kislyakov AN, Livshits MI, Lobankin PV, Chmutin GE, Musa G. Pineal region neuroenteric cyst in a 13-year-old girl: A rare localization with postoperative recurrence and local dissemination. Surg Neurol Int. 2022;13:287. [DOI:10.25259/SNI_312_2022] [PMID] [PMCID]
9. Anderson T, Kaufman T, Murtagh R. Intracranial neurenteric cyst: A case report and differential diagnosis of intracranial cystic lesions. Radiol Case Rep. 2020;15(12):2649-54. [DOI:10.1016/j.radcr.2020.10.017] [PMID] [PMCID]
10. Stopa BM, Cuoco JA, Stump MS, Rogers CM. Supratentorial Neurenteric Cysts: Systematic Literature Review and Case Report. World Neurosurg. 2022;164:8-24. [DOI:10.1016/j.wneu.2022.04.057] [PMID]
11. Watanabe N, Akasaki Y, Fujigasaki J, Mori R, Aizawa D, Ikeuchi S, et al. Imaging alterations due to squamous metaplasia in intracranial neurenteric cysts: A report of two cases. Neuroradiol J. 2016;29(3):187-92. [DOI:10.1177/1971400916638356] [PMID] [PMCID]
12. Yang Y, Fang J, Li D, Wang L, Ji N, Zhang J. Recurrent intracranial neurenteric cyst with malignant transformation: A case report and literature review. Oncol Lett. 2016;11(5):3395-402. [DOI:10.3892/ol.2016.4386] [PMID] [PMCID]
13. Fujisawa N, Oya S, Higashi M, Matsui T. Malignant Transformation of a Neurenteric Cyst in the Posterior Fossa Presenting with Intracranial Metastasis: A Case Report and Literature Review. NMC Case Rep J. 2015;2(4):123-7. [DOI:10.2176/nmccrj.cr.2014-0416] [PMID] [PMCID]
14. Gessi M, Legnani FG, Maderna E, Casali C, Solero CL, Pollo B, et al. Mucinous low-grade adenocarcinoma arising in an intracranial enterogenous cyst: case report. Neurosurgery. 2008; 62(4):E972-3. [DOI:10.1227/01.neu.0000318186.10536.f6] [PMID]
15. Dunham CP, Curry B, Hamilton M. Malignant transformation of an intraaxial-supratentorial neurenteric cyst - Case report and review of the literature. Neuropathology. 2009;29(4):460-6. [DOI:10.5414/NPP28460] [PMID]
16. Monaco R, Boscaino A, Di Blasi A, D'Antonio A, Profeta G, De Falco R, et al. Intraepithelial carcinoma arising in an endodermal cyst of the posterior fossa. Neuropathology. 2003;23(3):219-24. [DOI:10.1046/j.1440-1789.2003.00497.x] [PMID]
17. Okabe H, Katsura K, Yamano T, Tenjin H, Nakahara Y, Ishida M, et al. Mucinous adenocarcinoma arising from supratentorial intramedullary neuroenteric cyst with broncho-pulmonary differentiation. Neuropathology. 2014;34(4):420-4. [DOI:10.1111/neup.12118] [PMID]
18. Ho LC, Olivi A, Cho CH, Burger PC, Simeone F, Tihan T. Well-differentiated papillary adenocarcinoma arising in a supratentorial enterogenous cyst: case report. Neurosurgery. 1998;43(6):1474-7. [DOI:10.1227/00006123-199812000-00131] [PMID]
19. Sahara Y, Nagasaka T, Takayasu M, Takagi T, Hata N, Yoshida J. Recurrence of a neurenteric cyst with malignant transformation in the foramen magnum after total resection: Case report. J Neurosurg. 2001;95(2 Suppl):341-5. [DOI:10.3171/jns.2001.95.2.0341] [PMID]
20. Surash S, Ismail A, Loughrey C, Van Hille P. Malignant transformation of a neurenteric cyst in the posterior fossa following complete excision. Br J Neurosurg. 2009;23(4):458-61. [DOI:10.1080/02688690902785719] [PMID]
21. Krivoshapkin A, Sergeev G, Gaytan A, Salim N, Krotenkova I, Savitskiy I, et al. A case report: Malignant transformation of a neurenteric cyst with intracranial metastases mimicking neurocysticercosis. Interdiscip Neurosurg. 2021;25:101193. [DOI:10.1016/j.inat.2021.101193]
22. Alanazi N, Sayed AG, Hassounah M, Dababo M. Malignant Transformation of a Supratentorial Neurenteric Cyst: A Case Report and Literature Review. Cureus [Internet]. 2025 Jun 11 [cited 2025 May 13]. Available from: https://www.cureus.com/articles/352002-malignant-transformation-of-a-supratentorial-neurenteric-cyst-a-case-report-and-literature-review [DOI:10.7759/cureus.85781]
23. Cuoco JA, Rogers CM, Busch CM, Apfel LS, Entwistle JJ, Marvin EA. Intracranial Squamous Cell Carcinoma Arising From a Cerebellopontine Angle Epidermoid Cyst Remnant Four Decades After Partial Resection. Front Oncol. 2019;9:694. [DOI:10.3389/fonc.2019.00694] [PMID] [PMCID]
24. Hamlat A, Hua ZF, Saikali S, Laurent JF, Gedouin D, Ben-Hassel M, et al. Malignant transformation of intra-cranial epithelial cysts: systematic article review. J Neurooncol. 2005;74(2):187-94. [DOI:10.1007/s11060-004-5175-4] [PMID]
25. Rim HT, Song JH, Kim ES, Kwon MJ. Mucinous adenocarcinoma arising from a residual supratentorial neurenteric cyst and expressing mutated KRAS: a case report. Hum Pathol. 2016;58:146-51. [DOI:10.1016/j.humpath.2016.05.027] [PMID]
26. Bigio MR, Jay V, Drake JM. Prepontine cyst lined by respiratory epithelium with squamous metaplasia: immunohistochemical and ultrastructural study. Acta Neuropathol. 1992;83(5):564-8. [DOI:10.1007/BF00310038] [PMID]