Iranian Journal of Pathology | ISSN: 2345-3656

# Post-COVID-19 Rhinocerebral Mucormycosis, a Life-Threatening Event in the Background of an Immunosuppressive Condition: A Case Report

**Reihane Cheginі[1], Ali Zare-Mirzaei[2], Mohammad Eslami[3]***

1. *Department of Pathology, School of Medicine, Shahid Beheshti University of Medical Sciences, Tehran, Iran*
2. *Department of Pathology, School of Medicine, Iran University of Medical Sciences, Tehran, Iran*
3. *Department of Pathology, Emam Hossein Educational Hospital, Shahid Beheshti University of Medical Sciences, Tehran, Iran*

**KEYWORDS**

*COVID-19; SARS-CoV-2; mucormycosis; rhinocerebral; immunosuppression; case report*

Scan to discover online

**Main Subjects:**
Infectious Diseases

Received 09 Sep 2025;
Accepted 03 Feb 2026;
Published Online 10 May 2026;

10.22034/ijp.2026.2071232.3535

**ABSTRACT**

**Background & Objective:** In patients with COVID-19, immunocompromised conditions or immunosuppressive medications, such as corticosteroids, may predispose them to invasive fungal infections affecting the sinuses and brain. We describe a case of COVID-19 infection complicated by rhinocerebral mucormycosis, diagnosed through cerebrospinal fluid (CSF) analysis.

**Case Report:** A 32-year-old woman with a history of COVID-19 1 month prior, treated with high-dose corticosteroids, presented with rapidly progressive neurological symptoms, including lower extremity paralysis. Imaging revealed an intracranial hemorrhage and a mass-like lesion.

**Conclusion:** Cytological CSF analysis showed acute inflammation and fungal elements consistent with mucormycosis. Despite antifungal treatment, the patient's condition deteriorated; she developed a thromboembolism and ultimately died.

**Corresponding Information:** **Mohammad Eslami,** Department of Pathology, Emam Hossein Educational Hospital, Shahid Beheshti University of Medical Sciences, Tehran, Iran. Email: mohammadeslami@sbmu.ac.ir

**Copyright © 2026.** This is an open-access article distributed under the terms of the **Creative Commons Attribution 4.0 International License (CC BY 4.0)**, which permits unrestricted use, distribution, and reproduction in any medium, provided the original work is properly cited. The license also allows users to adapt, remix, transform, and build upon the material for any purpose, including commercial use.

## Introduction

The COVID-19 pandemic, caused by severe acute respiratory syndrome coronavirus 2 (SARS-CoV-2), has led to significant global morbidity and mortality (1, 2). The death toll continues to rise, particularly among older adults and those with comorbidities (3, 4). In addition to acute pulmonary complications, COVID-19 can have widespread extrapulmonary sequelae, including myocardial infarction, hemorrhagic and thrombotic events, and even strokes (5-7). Furthermore, there is emerging evidence of acute and delayed-onset complications occurring months after apparent recovery from COVID-19 (8). Among these, rare instances of viral or fungal meningitis and intracranial hemorrhage have been reported, which, though uncommon, carry high mortality (9, 10). Notably, several cases of mucormycosis, especially in patients on immunosuppressive regimens or with uncontrolled diabetes, have been reported following COVID-19; in some, this opportunistic fungal infection led to life-threatening cerebral involvement (11).

Herein, we describe a post-COVID-19 case that developed rhinocerebral mucormycosis, identified through cerebrospinal fluid (CSF) cytology, and eventually succumbed to intracranial complications. This report underscores the importance of vigilance for invasive fungal infections in patients with COVID-19 and immunosuppression.

## Case Report

A 32-year-old female with no significant past medical history was hospitalized for severe COVID-19 pneumonia 1 month prior to the current presentation. During that admission, she required supplemental oxygen and received high-dose corticosteroid therapy, methylprednisolone and dexamethasone, as part of her treatment. She was discharged after clinical improvement.

Approximately 4 weeks later, the patient returned to the hospital with new neurological symptoms. She presented with acute onset of lower extremity paralysis, plegia, and severe headache. On examination, she was tachycardic, with a heart rate of 110/min, and febrile, with a temperature of 38.2 °C. Her oxygen saturation on room air was 86.4%. Laboratory studies at this time showed a white blood cell count of 23.1 × $10^9$/L, leukocytosis, hemoglobin of 8.1 g/dL, anemia, MCV of 81.3 fL, and platelet count

of 214 × 10⁹/L. Given her neurological deficits, she was promptly referred to the neurology service.

During this post-COVID-19 hospitalization, the patient continued to receive immunosuppressive medications; corticosteroids were maintained. On the sixth day of admission, her neurological status acutely worsened, with loss of consciousness; the Glasgow Coma Scale score deteriorated from 15 to 8. An urgent brain CT scan (Fig. 1) showed a heterogeneous mass-like lesion, approximately 60 × 42 × 40 mm, in the right basal ganglia with surrounding edema, exerting a compressive effect on the right lateral ventricle and causing a mild midline shift to the left. There was also evidence of an acute intracranial hemorrhage within this lesion. A concurrent spiral chest CT scan without contrast still showed bilateral multilobar ground-glass opacities, consistent with COVID-19 pneumonia (Fig. 2). Given the neurological findings, a lumbar puncture was performed to evaluate for CNS infection or malignancy.

CSF analysis revealed elevated opening pressure and a cloudy appearance. Cytological examination of the CSF (Fig. 3) demonstrated numerous acute inflammatory cells, neutrophils and mononuclear cells, and the presence of broad, nonseptate hyphae, morphologically consistent with mucormycosis. No organisms were seen on Gram stain, but fungal culture of CSF, which later grew *Rhizopus* species, confirmed the diagnosis of invasive mucormycosis involving the central nervous system.

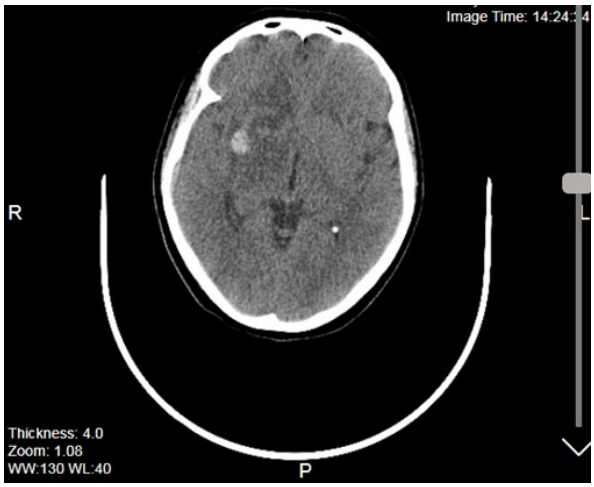


**Fig. 1. Brain CT (no contrast):** Axial image showing a heterogeneous mass-like area (~60 mm) in the right basal ganglia region with surrounding edema. There is compression of the right lateral ventricle and a mild midline shift to the left. An acute hemorrhagic component is visible within the lesion. These findings suggest an invasive process with hemorrhagic infarction.

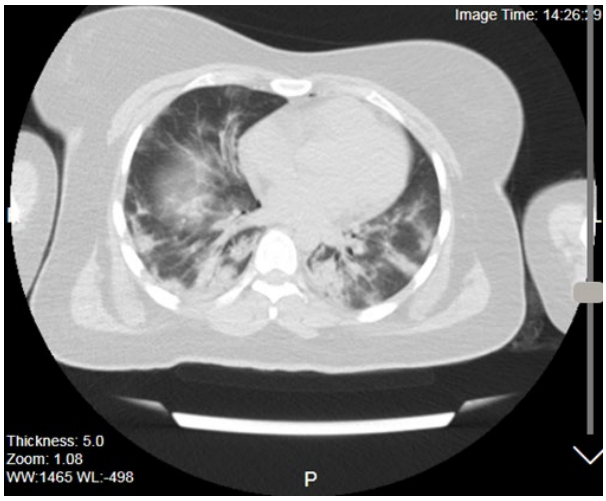


**Fig 2. Chest CT (no contrast):** (A, B) Axial and coronal views showing multiple ground-glass opacities with peripheral distribution in both lungs (asterisks), consistent with organizing pneumonia due to recent COVID-19 infection.

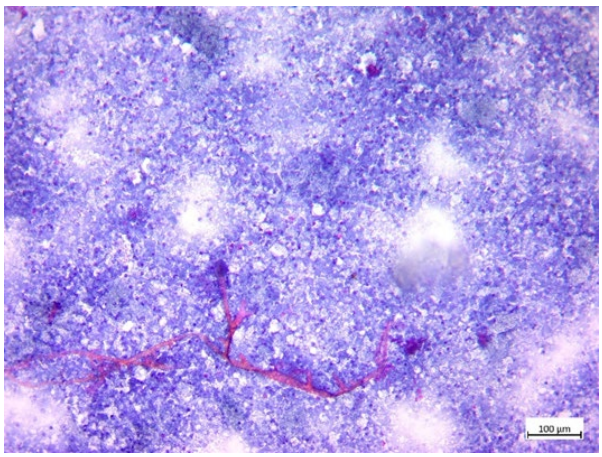


**Fig 3. CSF cytology (Papanicolaou stain):** Numerous inflammatory cells (neutrophils predominate) and scattered broad, ribbon-like hyphae (black arrow) lacking septations, consistent with *Mucorales* fungi. These fungal elements were observed entangled with necrotic debris, indicating acute invasive fungal infection in the CSF.

The patient underwent emergent neurosurgical intervention for intracranial pressure management; a decompressive craniectomy was performed. Additionally, given the confirmed diagnosis of mucormycosis, amphotericin B, liposomal formulation, was initiated promptly as the first-line antifungal treatment. Despite aggressive therapy, the patient's level of consciousness continued to decline over the next week, reaching a GCS score of 5. A biopsy of the right parietotemporal brain lesion was obtained during surgery; histopathology revealed extensive necrosis with invasive broad nonseptate fungal hyphae, confirming rhinocerebral mucormycosis (Fig. 4).

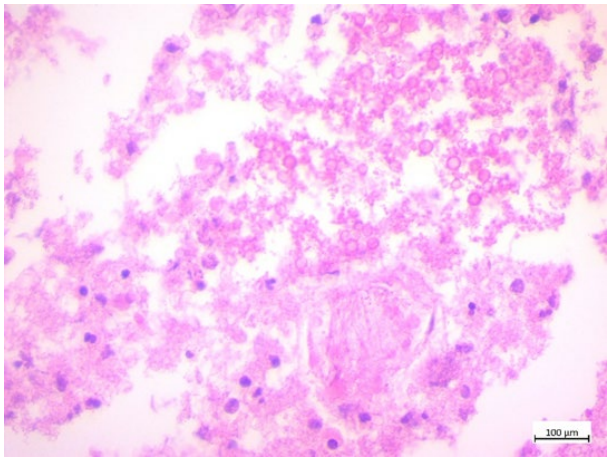


**Fig. 4. Brain biopsy (H&E stain):** Section from the decompressive surgery specimen showing broad, non-septate hyphae with right-angle branching (white arrow) invading cerebral tissue with an accompanying inflammatory infiltrate and necrosis. These histologic features are characteristic of mucormycosis.

Tragically, at the subsequent evaluation, the patient developed signs of systemic thromboembolism, presumably a pulmonary embolus, given acute oxygen desaturation and hemodynamic instability, and went into cardiopulmonary arrest. Resuscitation efforts were unsuccessful, and the patient died approximately 2 weeks after her neurological presentation.

## Discussion

Mucormycosis is an invasive infection caused by fungi of the order Mucorales. Its incidence has been increasing, especially among immunocompromised individuals (12). Common clinical manifestations include rhinosinusitis, pulmonary infection, gastrointestinal infection, and cutaneous infection, depending on the route of entry (13). Despite modern treatments, mucormycosis remains highly lethal, with reported mortality rates between 40% and 80%, depending on the site and patient factors (14). The distribution of fungal infections is largely influenced by the host's immune status. Immunocompromised conditions, such as impaired immune responses, prolonged use of immunosuppressive agents, severe trauma, or uncontrolled diabetes mellitus, are the main predisposing factors for the development of invasive fungal diseases, including mucormycosis and zygomycosis. In particular, rhino-orbital-cerebral mucormycosis can progress rapidly as the fungus invades blood vessels, leading to tissue necrosis and thrombosis, which are considered the hallmarks of this life-threatening infection (15-17).

Our patient was at elevated risk for mucormycosis due to an immunosuppressive state. She had received prolonged corticosteroid therapy for COVID-19, which likely contributed to immune dysfunction. The fungus typically enters via inhalation of spores into the sinuses; in susceptible hosts, it can then spread to the orbits and brain. Clinical manifestations vary from sinusitis symptoms to cranial nerve palsies, orbital cellulitis, cavernous sinus thrombosis, and cerebral infarction or hemorrhage (18). In our case, the patient's initial symptom of lower extremity paralysis was unusual; it likely resulted from the fungal infection causing an abscess or infarction in the basal ganglia region, as evidenced by the mass and hemorrhage on CT. This highlights that COVID-19-associated mucormycosis can present with atypical neurological deficits.

In rhinocerebral mucormycosis, the disease's hallmark is attributed to tissue necrosis from angioinvasion and subsequent thrombosis (19). In patients suspected of having rhinocerebral mucormycosis, a comprehensive assessment of the patient's medical history and physical and neurological examination, followed by imaging of the affected zones, can crucially lead to confirmation of the diagnosis. In a cranial CT scan, bone destruction may be the prominent finding (20). MRI is a sensitive modality for assessing cranial soft tissues, such as the brain, orbit, and sinuses (21).

For diagnosis, a high index of suspicion is required, especially in post-COVID-19 patients with risk factors who deteriorate neurologically. Confirmatory diagnosis relies on detecting the fungus via histopathology or culture. In our patient, visualization of the characteristic broad, nonseptate hyphae in the CSF was key to the early diagnosis, even before cultures grew *Rhizopus*. This case is somewhat unique in that CSF cytology provided the first diagnostic clue; usually, sinus biopsy or nasal endoscopy samples are used (10). In this regard, visualization of fungus under direct microscopy, its culture, or molecular assessment can lead to confirmation of the diagnosis (22). Our experience suggests that, in the appropriate context, CSF analysis can aid in diagnosing CNS mucormycosis when a brain biopsy is not immediately available.

Management of rhinocerebral mucormycosis involves two parallel approaches, including aggressive antifungal therapy and surgical debridement of infected tissue. The first-line antifungal medication is intravenous amphotericin B, preferably the liposomal formulation for better CNS penetration and reduced nephrotoxicity. In our case, amphotericin B was promptly started. Continuous monitoring of renal function is necessary due to the drug's nephrotoxic potential. Combination therapy can be considered in refractory cases; for instance, some protocols add an echinocandin, such as caspofungin, as second-line adjunctive therapy (23). Other medications, such as isavuconazole or posaconazole, have been used in cases with invasive mucormycosis (24). Our patient did not survive long enough to consider transitioning therapy. The second aspect of treatment is surgical: aggressive debridement of necrotic bone and tissue in the sinuses or orbit can reduce fungal load (25). In our case, neurosurgery was performed to alleviate intracranial pressure rather than to debride infected sinus tissue, since her primary presentation was cerebral. Ideally, an ENT surgical evaluation of the nasal/sinus area should

be done as well, but her critical condition limited extensive procedures.

There have been a few reported cases and series of COVID-19-associated mucormycosis. Such cases have usually appeared in the background of immunosuppressive regimens or uncontrolled diabetic conditions (11, 26). In a similar study by Sanjay Kumar Gupta et al. in 2021, a post-COVID-19 65-year-old woman with invasive fungal sinusitis and a "black turbinate" sign on MRI, indicating necrosis of nasal turbinates, was managed with antifungals and insulin for diabetes (27). Tamer Roushdy et al. in 2021 described 4 patients in Egypt who developed post-COVID-19 mucormycosis involving the orbits and cavernous sinus; despite treatment, 1 patient died when it progressed to rhinocerebral disease (28). Also, in another case by Kirill Alekseyev in 2021, a case of a 41-year-old man with type 1 diabetes who, after steroids and hydroxychloroquine for COVID-19, developed rhinocerebral mucormycosis from *Rhizopus* spp. was presented. These reports, alongside our case, underscore a recurring theme: COVID-19, especially when treated with steroids or in patients with diabetes, can create a permissive environment for Mucorales infection. The combination of virus-induced immune dysregulation, corticosteroid-induced hyperglycemia/immunosuppression, and underlying comorbidities likely all contribute (29).

Overall, patients recovering from COVID-19, whether in the immediate or subacute phase, are at higher risk of invasive fungal infections if they have risk factors such as immunosuppressive therapy or uncontrolled diabetes. Rhinocerebral mucormycosis remains a constant threat in these individuals. Clinicians should consider implementing screening strategies, such as ENT evaluations for persistent sinus symptoms, along with early intervention in high-risk patients. A high index of suspicion, timely imaging to detect sinus inflammation or the black turbinate sign on MRI, and prompt biopsy of suspicious lesions can facilitate early diagnosis. Early and aggressive therapy is essential to improving outcomes; however, as demonstrated in this case, the prognosis can be poor once the infection has extended to the brain.

## Conclusion

Rhinocerebral mucormycosis is a life-threatening fungal infection that can occur in the aftermath of COVID-19, particularly in patients who are immunosuppressed or have risk factors, such as steroid use and diabetes. This case highlights the need for healthcare providers to remain vigilant for symptoms of invasive fungal infections in post-COVID-19 patients. Early diagnosis, potentially through analysis of CSF or biopsy, and immediate antifungal and surgical treatment offer the best chance of survival. Preventive measures, such as tight glycemic control in patients with diabetes and judicious use of corticosteroids, as well as monitoring for sinus symptoms in patients recovering from COVID-19, should be considered to mitigate this deadly complication.

## Acknowledgments

This case report was previously posted as a preprint on Research Square (Chegini et al., "Post-COVID-19 rhinocerebral mucormycosis, a life-threatening event in the background of immunosuppressive condition: a case report"). The authors acknowledge the use of that platform and have since updated the content for journal submission.

## Authors' Contributors

A.Z. and R.C. contributed to study design and data collection. M.E. performed the cytological and histological examinations, interpreted the findings, and edited the final manuscript. All authors have read and approved the manuscript, and agree to be accountable for its content.

## Data Availability

The datasets generated and analyzed during the current study are not publicly available; however, the data can be shared for research and authentication purposes upon reasonable request.

## Funding

This research received no specific grant from any funding agency in the public, commercial, or not-for-profit sectors.

## Consent to Participate:

Written informed consent was obtained from the patient's legal next of kin for publication of this case report and accompanying images.

## Ethics Approval

All identifying patient information was removed to protect privacy. Written informed consent for publication (text and images) was obtained from the patientThe procedures followed were in accordance with the ethical standards of the responsible committee on human experimentation (institutional and national) and with the Helsinki Declaration. Written informed consent was obtained from the patient for publication of this case report and accompanying images. A copy of the written consent is available for review by the Editor-in-Chief of this journal on request. No identifying information is included in the report.

## Conflict of Interest

The authors declared no conflict of interest.

## References


1. Baloch S, Baloch MA, Zheng T, Pei X. The Coronavirus Disease 2019 (COVID-19) Pandemic. Tohoku J Exp Med. 2020;250(4):271-8. [DOI:10.1620/tjem.250.271] [PMID]
2. Aleem A, Samad ABA, Slenker AK. Emerging Variants of SARS-CoV-2 And Novel Therapeutics Against Coronavirus (COVID-19). In: StatPearls [Internet]. Treasure Island (FL): StatPearls Publishing; 2022.
3. Singhal T. A Review of Coronavirus Disease-2019 (COVID-19). Indian J Pediatr. 2020;87(4):281-6. [DOI:10.1007/s12098-020-03263-6] [PMID] [PMCID]
4. Kianifar F, Eslami M, Nikoohemmat M, Parsa S. Relationship between body mass index and disease severity in COVID-19 patients admitted from April to September 2020 at Imam Khomeini Hospital Complex, Tehran, Iran. Immunopathol Persa. 2024;10(1):e39626. [DOI:10.34172/ipp.2024.38456]
5. Louis TJ, Qasem A, Abdelli LS, Naser SA. Extra-Pulmonary Complications in SARS-CoV-2 Infection: A Comprehensive Multi Organ-System Review. Microorganisms. 2022;10(1):153. [PMID] [PMCID] [DOI:10.3390/microorganisms10010153]
6. Schoene D, Schnekenberg LG, Pallesen LP, Barlinn J, Puetz V, Barlinn K, et al. Pathophysiology of Cardiac Injury in COVID-19 Patients with Acute Ischaemic Stroke: What Do We Know So Far?-A Review of the Current Literature. Life (Basel). 2022;12(1):50. [DOI:10.3390/life12010075] [PMID] [PMCID]
7. Leung EH, Fan J, Flynn HW Jr, Albini TA. Ocular and systemic complications of COVID-19: impact on patients and healthcare. Clin Ophthalmol. 2022;16:1-13. [DOI:10.2147/OPTH.S336963] [PMID] [PMCID]
8. Sharma P, Chakraborty K. Delayed manifestation of extensive COVID-19-associated coagulopathy in high-risk patient. BMJ Case Rep. 2021;14(5):e241113. [DOI:10.1136/bcr-2021-242921] [PMID] [PMCID]
9. Lu DE, Hung SH, Su YS, Lee WS. Analysis of Fungal and Bacterial Co-Infections in Mortality Cases among Hospitalized Patients with COVID-19 in Taipei, Taiwan. J Fungi (Basel). 2022;8(1):44 . [DOI:10.3390/jof8010091] [PMID] [PMCID]
10. Elmokadem AH, Bayoumi D, Mansour M, Ghonim M, Saad EA, Khedr D. COVID-19-associated acute invasive fungal sinusitis: Clinical and imaging findings. J Neuroimaging. 2022;32(4):676-89. [DOI:10.1111/jon.12967] [PMID]
11. Alian S, Ahangarkani F, Boskabadi SJ, Kargar-Soleimanabad S, Delavarian L, Pakzad A. Mucormycosis, one month after recovery from COVID-19: A case report. Ann Med Surg (Lond). 2022;78: 103911. [DOI:10.1016/j.amsu.2022.103911] [PMID] [PMCID]
12. Skiada A, Pavleas I, Drogari-Apiranthitou M. Epidemiology and Diagnosis of Mucormycosis: An Update. J Fungi (Basel). 2020;6(4):265. [DOI:10.3390/jof6040265] [PMID] [PMCID]
13. Castrejón-Pérez AD, Welsh EC, Miranda I, Ocampo-Candiani J, Welsh O. Cutaneous mucormycosis. An Bras Dermatol. 2017;92(3):304-11. [DOI:10.1590/abd1806-4841.20176614] [PMID] [PMCID]
14. Sharma A, Goel A. Mucormycosis: risk factors, diagnosis, treatments, and challenges during COVID-19 pandemic. Folia Microbiol (Praha). 2022;67(3):363-87. [DOI:10.1007/s12223-021-00934-5] [PMID] [PMCID]
15. Riley TT, Muzny CA, Swiatlo E, Legendre DP. Breaking the Mold: A Review of Mucormycosis and Current Pharmacological Treatment Options. Ann Pharmacother. 2016;50(9):747-57. [DOI:10.1177/1060028016655425] [PMID]
16. Rammaert B, Lanternier F, Poirée S, Kania R, Lortholary O. Diabetes and mucormycosis: A complex interplay. Diabetes Metab. 2012;38(3):193-204. [DOI:10.1016/j.diabet.2012.01.002] [PMID]
17. Mirzaie AZ, Akram J, Sadeghipour A, Shayanfar N. Seven years of experience with zygomycosis in Iran: a seasonal disease. Braz J Infect Dis. 2011;15(5):504. [DOI:10.1016/S1413-8670(11)70240-9] [PMID]
18. Ali Asghar S, Majid Z, Tahir F, Qadar LT, Mir S. Rhino-oculo Cerebral Mucormycosis Resistant to Amphotericin B in a Young Patient with Diabetic Ketoacidosis. Cureus. 2019;11(3):e4295. [DOI:10.7759/cureus.4295]
19. Cornely OA, Alastruey-Izquierdo A, Arenz D, Chen SCA, Dannaoui E, Hochhegger B, et al. Global guideline for the diagnosis and management of mucormycosis: an initiative of the European Confederation of Medical Mycology in cooperation with the Mycoses Study Group Education and Research Consortium. Lancet Infect Dis. 2019;19(12):e405-e21.
20. Brunet K, Rammaert B. Mucormycosis treatment: Recommendations, latest advances, and perspectives. J Mycol Med. 2020;30(3):101007. [DOI:10.1016/j.mycmed.2020.101007] [PMID]
21. Sreshta K, Dave TV, Varma DR, Nair AG, Bothra N, Naik MN, et al. Magnetic resonance imaging in rhino-orbital-cerebral mucormycosis. Indian J Ophthalmol. 2021;69(7):1915-27. [DOI:10.4103/ijo.IJO_1439_21] [PMID] [PMCID]
22. Borg D, Farrugia J, Mallia Azzopardi C. SARS-CoV-2 related ARDS and Invasive Fungal Infections in Intensive Care Patients. Clin Infect Pract. 2021;11:100127. [DOI:10.1016/j.clinpr.2021.100127] [PMID] [PMCID]
23. Murthy R, Bagchi A, Gote Y, Desai S. Retrobulbar injection of amphotericin B using intravenous cannula for post-COVID-19 rhino-orbital mucormycosis. Indian J Ophthalmol. 2022;70(1):302-5. [DOI:10.4103/ijo.IJO_1511_21] [PMID] [PMCID]
24. Patel A, Patel K, Patel K, Shah K, Chakrabarti A. Therapeutic drug monitoring of posaconazole delayed release tablet while managing COVID-19-associated mucormycosis in a real-life setting. Mycoses. 2022;65(3):312-6. [DOI:10.1111/myc.13420] [PMID]
25. Deek AJ, Boukovalas S, Rathfoot CJ, Gotcher JE. Rhinocerebral Mucormycosis as a Sequelae of COVID-

19 Treatment: A Case Report & Literature Review. J Oral Maxillofac Surg. 2022;80(2):333-40. [DOI:10.1016/j.joms.2021.09.009] [PMID] [PMCID]

26. Hamed H, Madia R, Ladadweh H, Falana H, AbuKhalil AD. Fatal Mucormycosis Post COVID-19 Infection in Uncontrolled Diabetes with Misuse of Glucocorticoids and Antibiotics. Infect Drug Resist. 2022;15:1121-6. [DOI:10.2147/IDR.S356465] [PMID] [PMCID]
27. Kumar Gupta S, Jyotsana P, Singh A, Phuyal D, Allam P. Rhinocerebral Mucormycosis in a COVID-19 Patient from Nepal: A Case Report. JNMA J Nepal Med Assoc. 2021;59(239):703-5. [DOI:10.31729/jnma.6904] [PMID] [PMCID]
28. Roushdy T, Hamid E. A case series of post COVID-19 mucormycosis-a neurological prospective. Egypt J Neurol Psychiatr Neurosurg. 2021;57(1):100. [DOI:10.1186/s41983-021-00355-8] [PMID] [PMCID]
29. Alekseyev K, Didenko L, Chaudhry B. Rhinocerebral Mucormycosis and COVID-19 Pneumonia. J Med Cases. 2021;12(3):85-9. [DOI:10.14740/jmc3637] [PMID] [PMCID]