Iranian Journal of Pathology | ISSN: 2345-3656

ARID1A, β-Catenin and P53 Immunohistochemical Expression: Diagnostic Value in Endometrial Carcinoma and Premalignant Endometrial Lesions

Passant A. El-Sheikh*, Asmaa Bedeer, Dareen A. Mohamed, Fersan Sallam, Fatma MKh Ibrahim

Pathology Department, Faculty of Medicine, Tanta University, El-Gaish Street, Tanta 31527, El Gharbia governorate, Egypt

KEYWORDS

Endometrial carcinoma, Atypical endometrial hyperplasia, ARID1A, β-Catenin, P53

Scan to discover online

Main Subjects:
Gynecologic Pathology

Received 02 Dec 2025;
Accepted 25 Feb 2026;
Published Online 10 May 2026;

10.22034/ijp.2026.2079758.3599

ABSTRACT

Background & Objective: Although the role of atypical endometrial hyperplasia as a precursor lesion of endometrial carcinoma (EC) has been well documented, the molecular pathogenesis underlying malignant progression remains largely unclear. The current work aimed to evaluate the role of ARID1A, β-catenin, and p53 expression in differentiating between endometrial carcinoma and precancerous endometrial lesions.

Methods: Forty-eight cases of endometrial carcinoma (EC) and 14 cases of atypical endometrial hyperplasia (AEH) were evaluated for immunohistochemical expression of ARID1A, β-catenin, and p53.

Results: Combining ARID1A and β-catenin enhanced diagnostic performance. For distinguishing endometrioid carcinoma from AEH/EIN, the combination achieved a sensitivity of 70% and an accuracy of 70.5%, though with lower specificity (71.4%) than ARID1A alone. For differentiating endometrioid from non-endometrioid carcinoma, the combined markers showed higher sensitivity (86.7%) and accuracy (83.3%) but reduced specificity (77.8%) compared with ARID1A alone. The triple combination of ARID1A, β-catenin, and p53 increased specificity (92.9%) for distinguishing endometrioid carcinoma from AEH/EIN compared with individual markers or the ARID1A–β-catenin double panel, but markedly decreased sensitivity (53.3%). In contrast, for differentiating endometrioid from non-endometrioid carcinoma, the triple panel achieved superior sensitivity (87.7%), specificity (94.4%), and accuracy (91.5%) relative to each marker alone or the ARID1A–β-catenin combination.

Conclusion: The role of ARID1A, β-catenin, and p53 in the diagnosis of endometrial carcinoma (EC) is complex, as these markers are involved in distinct but interconnected molecular pathways that contribute to tumorigenesis. Their combined analysis can help classify endometrial carcinoma subtypes and may guide personalized treatment strategies.

Corresponding Information: **Passant A. El-Sheikh**, Pathology Department, Faculty of Medicine, Tanta University, El-Gaish street, Tanta 31527, El Gharbia governorate, Egypt. E-mail: passant.elsheikh@med.tanta.edu.eg

Copyright © 2026. This is an open-access article distributed under the terms of the **Creative Commons Attribution 4.0 International License (CC BY 4.0)**, which permits unrestricted use, distribution, and reproduction in any medium, provided the original work is properly cited. The license also allows users to adapt, remix, transform, and build upon the material for any purpose, including commercial use.

Introduction

Worldwide, endometrial carcinoma (EC) is the sixth most common malignancy in women and the second most prevalent gynecological cancer after cervical cancer (1). Endometrial carcinoma represents a heterogeneous spectrum, with marked differences in aggressiveness, treatment response, and outcome (2). Endometrioid carcinoma (EEC), the most common histological type, tends to be well-differentiated tumors with a 5-year survival rate of 85.6%. On the other hand, non-endometrioid EC usually exhibits poor differentiation, with a high risk of recurrence, less favorable prognosis, and a 5-year survival rate of 58.8% (3). Atypical endometrial hyperplasia (AEH) is considered a premalignant lesion or intraepithelial neoplasia, and approximately 40%–50% of patients with AEH who do not receive effective therapy may develop EC. This progression makes AEH a crucial condition for early diagnosis and intervention (4).

During the last decades, research studies have focused on molecular targets to improve diagnostic methods, develop new prognostic biomarkers, and propose therapeutic interventions (5). The Cancer Genome Atlas (TCGA) project identified four distinct prognostic groups of ECs based on molecular alterations: POLE-ultramutated, hypermutated MSI, p53-abnormal (copy number high/serous), and no specific molecular profile (copy number low/endometrioid), with significantly different clinical outcomes (6). In addition to the original publication in 2013, frequent tumor driver genes have been identified

in the molecular profile of EC, including PTEN, β-catenin (CTNNB1), AT-rich interaction domain 1A (ARID1A), PIK3CA, and KRAS (7).

AT-rich interaction domain 1A (ARID1A) is a key component of the SWI/SNF (SWItch/Sucrose Non-Fermentable) chromatin remodeling complex. This complex is involved in critical cellular functions, including transcription modulation, DNA damage repair, DNA synthesis, and DNA methylation (8). Most ARID1A mutations are nonsense or frameshift mutations causing protein truncation and functional loss, which leads to defects in cell cycle checkpoint activation in response to DNA damage and dysregulation of signaling pathways involved in cell self-renewal (9).

Among the most frequently detected mutations in EC are alterations in the β-catenin (CTNNB1) gene, occurring in approximately 20%–25% of tumors (10). β-Catenin is the effector of the Wnt (Wingless/int1) signaling pathway, which is involved in tumor proliferation, metastasis, epithelial-mesenchymal transition (EMT), recurrence, chemoresistance, and antitumor immune regulation (11). CTNNB1 mutation is reported in 52% of the no specific molecular profile group of EC and has been associated with increased recurrence and worse overall survival in low-grade, early EC (12).

p53 is a well-studied tumor suppressor gene that plays a key role in regulating the cell cycle. It is a principal mediator of growth arrest, senescence, and apoptosis in response to a broad array of cellular damage (11). In endometrial carcinoma, p53 alterations are associated with the worst prognosis among molecular subtypes (13). p53 alteration is most frequently detected in serous and mixed types of EC and is associated with higher grade and stage tumors (12).

Recent studies have highlighted the role of ARID1A, β-catenin, and p53 alterations in endometrial carcinogenesis. Nevertheless, the diagnostic validity of integrating these markers into a single panel for evaluation of different histological subtypes of EC and for discrimination between malignant and premalignant endometrial lesions has not yet been fully explored. Therefore, this study aimed to investigate the role of immunohistochemical expression of ARID1A, β-catenin, and p53 individually and in combination to differentiate between endometrioid carcinoma and atypical endometrial hyperplasia as a precursor premalignant lesion, and to differentiate endometrioid carcinoma from non-endometrioid endometrial carcinoma.

Materials and Methods

Study Design

This retrospective study included 48 cases of endometrial carcinoma (EC; received as total hysterectomy with bilateral salpingo-oophorectomy) and 14 cases of atypical endometrial hyperplasia (AEH; received mainly as D&C specimens) retrieved from the archives of the Pathology Department, Faculty of Medicine, Tanta University, during the period from February 2023 to December 2024. Approval from the research ethics committee was obtained prior to conducting the study, with approval code (36190/12/22).

Inclusion and Exclusion Criteria

Cases with available full clinicopathological data in pathology reports and sufficient tissue in paraffin blocks were considered eligible for inclusion in the study, whereas EC cases that received neoadjuvant therapy were excluded.

Methods

Clinicopathological Data Collection and Histopathological Evaluation

Data regarding age and tumor size were obtained from pathology reports. Tumor size was categorized into <2 cm and ≥2 cm, as recommended by Roma et al. (14). Paraffin blocks were serially sectioned (3–5 μm thick) and stained with hematoxylin and eosin (H&E) to assess histopathologic features. The studied EC cases were classified according to the 2020 World Health Organization (WHO) classification of endometrial tumors (15).

Endometrioid carcinoma cases were graded according to the binary FIGO grading system into low-grade and high-grade categories. Non-endometrioid carcinomas were considered high-grade by definition (16). Pathological staging was determined according to the 2023 FIGO staging system (17). Cases were categorized according to the depth of myometrial invasion into none, <50%, or ≥50% of myometrial thickness (18). Lymphovascular space invasion was evaluated as no LVSI, focal LVSI (<5 vessels), or extensive LVSI (≥5 vessels) (17).

Immunohistochemical Staining

Methodology for Immunohistochemical Staining

The studied cases underwent immunohistochemical staining using the DAKO EnVision FLEX protocol. Briefly, 5 μm-thick tissue sections on positively charged slides were dried for 30 minutes at 37 °C. Deparaffinization and antigen retrieval were carried out in the DAKO PT Link unit using high-pH EnVision™ FLEX Target Retrieval Solution at 97 °C for 20 minutes. Immunostaining was performed in the DAKO Autostainer Link 48 (DAKO/Agilent Corp).

The Dako EnVision™ FLEX detection system was then applied according to standard protocol times as follows: peroxidase blocking reagent for 10 minutes, primary antibodies for 20–30 minutes, horseradish peroxidase polymer reagent for 20 minutes, and chromogen (diaminobenzidine) for 10 minutes. Finally, counterstaining with Mayer's hematoxylin was performed.

Primary antibodies used in the study included anti-ARID1A antibody (rabbit monoclonal, dilution 1:150,

ABclonal, Massachusetts, United States), anti-β-catenin antibody (mouse monoclonal, ready-to-use, Dako, Glostrup, Denmark), and anti-p53 antibody (mouse monoclonal, ready-to-use, Dako, Glostrup, Denmark).

Assessment of Immunohistochemical Staining

Immunostaining evaluation was performed in a minimum of 10 randomly selected high-power fields (×400) containing representative tumor sections using a Leica DM500 microscope with a built-in Leica ICC50 digital camera (Leica Microsystems, Wetzlar, Germany).

Assessment of ARID1A Immunostaining:

ARID1A immunostaining was assessed as nuclear staining in endometrial or tumor cells. Cytoplasmic staining was ignored. Stromal cells served as an internal positive control. ARID1A expression was assessed quantitatively according to the percentage of positive tumor cells, regardless of staining intensity, and was categorized into three classes: retained expression/positive (>90% nuclear staining), complete loss (>90% negative nuclear staining), and clonal loss (regional negativity with 10%–90% negative tumor cells). Both complete and clonal loss were regarded as ARID1A loss/negative expression (19).

Assessment of β-Catenin Immunostaining:

β-Catenin immunostaining was detected as cytoplasmic and/or membranous brownish staining in endometrial or tumor cells. Both staining intensity and percentage of positive tumor cells were evaluated. Intensity was scored as 0 (negative), 1 (weak), 2 (moderate), or 3 (strong). The percentage of positive cells was scored as 1 (1%–25%), 2 (26%–50%), 3 (51%–75%), or 4 (76%–100%). The two scores were multiplied to yield a final score (0–12). Scores <6 were considered negative expression, whereas scores ≥6 indicated positive expression (20).

Assessment of p53 Immunostaining:

p53 staining was assessed as nuclear staining in endometrial or tumor cells and categorized as wild-type expression (1%–80% nuclear staining with variable intensity) or abnormal/mutant-like expression (p53abn), defined as either overexpression (>80% strong nuclear staining) or null pattern (complete absence of staining with preserved internal control staining in non-neoplastic cells such as lymphocytes, fibroblasts, or endothelial cells) (21).

Statistical Analysis

Results were statistically analyzed using the Statistical Package for Social Sciences (SPSS), version 22.0. Diagnostic performance of the studied markers was evaluated using sensitivity, specificity, positive predictive value (PPV), negative predictive value (NPV), and diagnostic accuracy, with histopathological diagnosis of surgical specimens considered the gold standard.

Receiver operating characteristic (ROC) curve analysis was performed by plotting sensitivity against the false-positive rate (1 − specificity) at various cutoff values, and the area under the ROC curve (AUC) was calculated as a measure of diagnostic accuracy (range, 0.5–1.0). Categorical variables were expressed as frequencies and compared using the chi-square, Fisher exact, or Monte Carlo tests, whereas continuous variables were presented as mean ± standard deviation. A p value < 0.05 was considered statistically significant.

Results

Clinicopathological Results

The current study included 48 endometrial carcinoma (EC) cases (mean age 68.1 ± 9.6 years) and 14 atypical endometrial hyperplasia (AEH) cases (mean age 46.6 ± 6.9 years). The clinicopathological features of the studied EC cases are demonstrated in Table 1.

Table 1. Clinicopathological features of the studied EC cases (48 cases)

	N (%)
Age (years) Mean±SD	68.1 ± 9.58
Tumor size (cm)	
< 2cm	14 (29.2)
≥ 2 cm	34 (70.8)
Histological type	
Endometrioid carcinoma	30 (62.5)
Serous carcinoma	11(22.9)
Clear cell carcinoma	5 (10.4)
Carcinosarcoma	2 (4.2)
Histopathological grading	
Low-grade	23 (47.9)
High-grade	25 (52.1)
Myometrial invasion (MI)	

	N (%)
Absent	3 (6.3)
<50%	16 (33.3)
≥50%	29 (60.4)
Lymphovascular space invasion (LVSI)	
No LVSI	21 (43.8)
Focal LVSI	11 (22.9)
Extensive LVSI	16 (33.3)
Cervical stromal invasion	
Absent	26 (54.2)
Present	22 (45.8)
FIGO staging	
I	22 (45.8)
II	12 (25)
III	14 (29.2)

SD: standard deviation; FIGO: international federation of gynecology and obstetrics

Immunohistochemical Results (Table 2)

Table 2. Immunohistochemical expression of ARID1A, β-Catenin and P53 in AEH and EC cases

	AEH (n=14)		Endometrioid Carcinoma (n = 30)		Non-endometrioid Carcinoma (n = 18)	
ARID1A expression	**No.**	**%**	**No.**	**%**	**No.**	**%**
Loss/negative	3	21.4%	20	66.7%	2	11.1%
Retained/positive	11	78.6%	10	33.3%	16	88.9%
β-Catenin expression						
Negative	7	50%	12	40.0%	14	77.8%
Positive	7	50%	18	60.0%	4	22.2%
P53 status						
Wild type	14	100%	27	90%	4	22.2%
Mutant type	0	0	3	10%	14	77.8%

AEH: Atypical endometrial hyperplasia; EC: endometrial carcinoma

ARID1A Expression

ARID1A loss of expression was detected in 3 cases (21.4%) of AEH, 20 cases (66.7%) of endometrioid EC, and only 2 cases (11.1%) of non-endometrioid EC, as illustrated in Fig. 1.

β-Catenin Expression

Positive β-catenin expression was detected in 7 cases (50%) of AEH, 18 cases (60%) of endometrioid EC, and 4 cases (22.2%) of non-endometrioid EC. The expression of β-catenin in AEH and EC cases is illustrated in Fig. 2.

p53 Expression

Wild-type p53 expression was seen in all AEH cases and 27 cases (90%) of endometrioid EC. In contrast, in non-endometrioid EC cases, mutant-type p53 expression predominated in 14 cases (77.8%), as illustrated in Fig. 3.

Diagnostic Performance of Immunohistochemical Markers

The diagnostic validity of ARID1A, β-catenin, and p53 was assessed individually and in combination to differentiate between endometrioid endometrial carcinoma (EEC) and atypical endometrial hyperplasia (AEH), as well as between endometrioid and non-endometrioid endometrial carcinoma.

Differentiation of EEC From AEH

Individually, ARID1A loss was significantly more frequent in EEC than AEH ($p = 0.005$), demonstrating moderate diagnostic performance with a sensitivity of 66.7%, specificity of 78.6%, and overall accuracy of 70.5%. Positive β-catenin expression alone exhibited lower sensitivity (60%) and specificity (50%) with a nonsignificant p value ($p = 0.745$), whereas mutant-type p53 showed very low sensitivity (10%) but perfect specificity (100%), as demonstrated in Table 3.

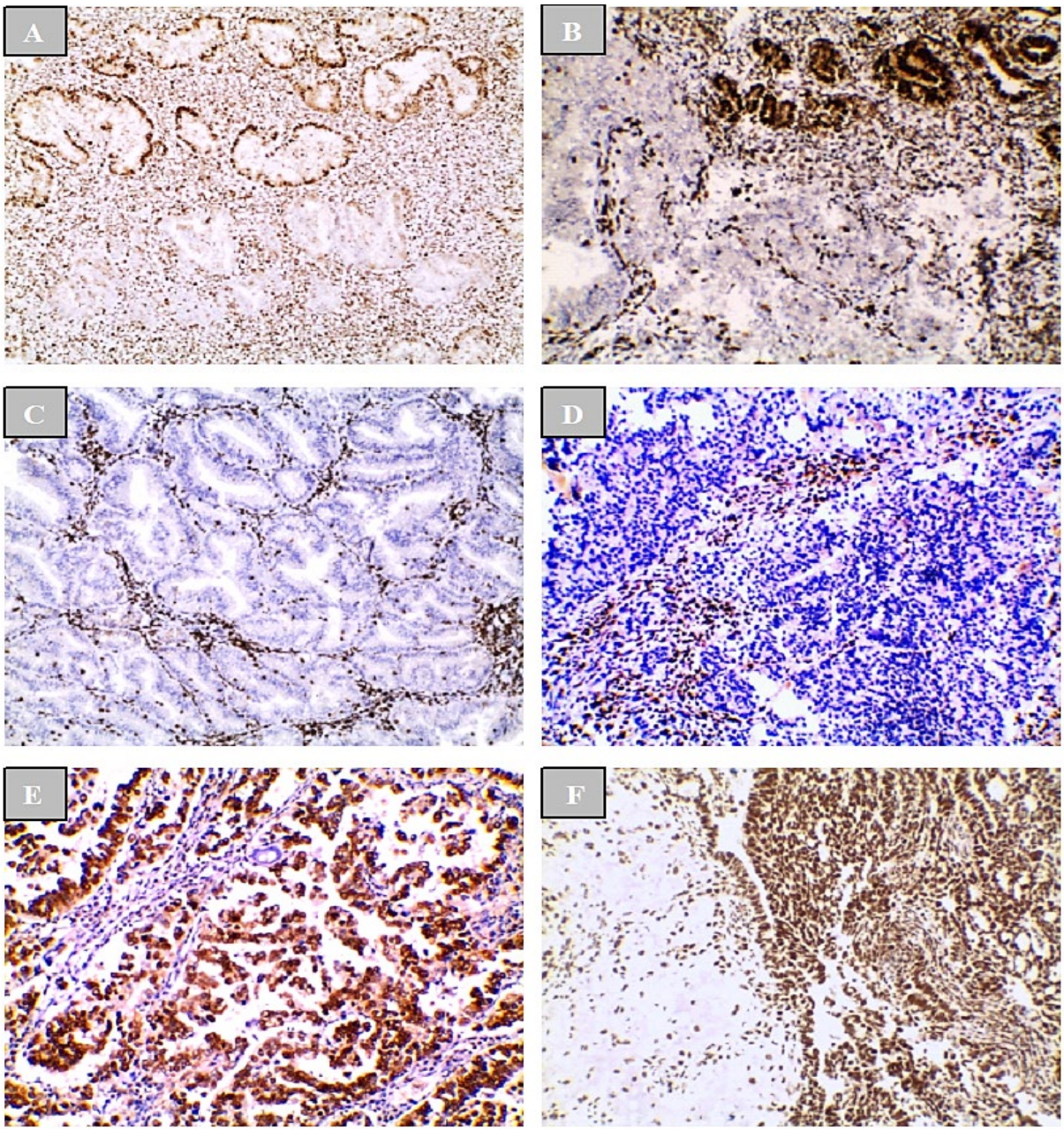

Fig. 1. Immunohistochemical expression of ARID1A in the studied AEH and EC cases: (A) clonal loss of ARID1A in AEH with regional nuclear negativity in endometrial glands (x100), (B) low-grade endometrioid carcinoma with complete loss of ARID1A A expression in malignant glands and retained expression in the nearby focus of AEH (x200),(C) complete loss of ARID1A in low-grade endometrioid carcinoma with positive internal control in stromal cells (x100), (D) complete loss of ARID1A in high-grade endometrioid carcinoma with positive internal control in stromal cells (x200). (E) retained ARID1A nuclear expression in serous carcinoma (x200), (F) retained ARID1A nuclear expression in carcinosarcoma (x200).

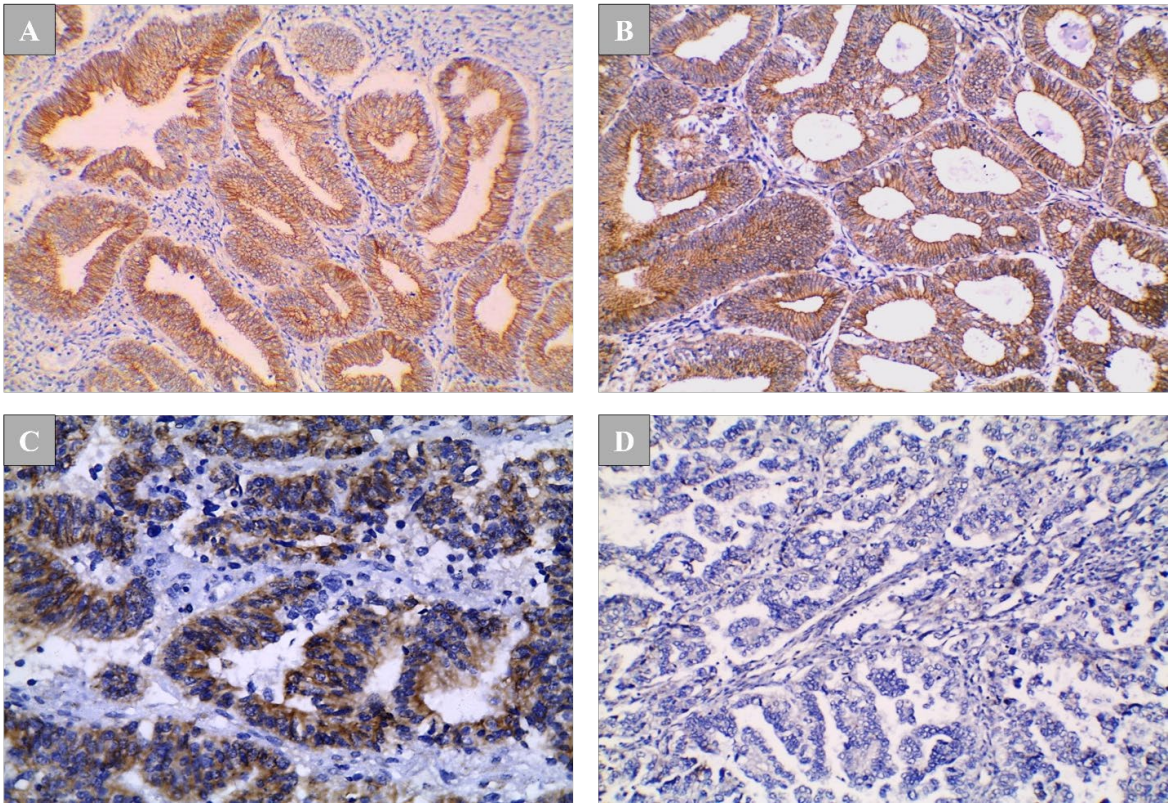

Fig. 2. Immunohistochemical expression of ß-catenin in AEH and EC cases: (A) positive cytoplasmic and membranous ß-catenin expression in AEH (x200), (B) moderate diffuse cytoplasmic and membranous ß-catenin expression in low-grade endometrioid carcinoma (x200), (C) strong diffuse cytoplasmic and membranous ß-catenin expression in low-grade endometrioid carcinoma (x400), (D) negative ß-catenin expression in serous endometrial carcinoma (x200).

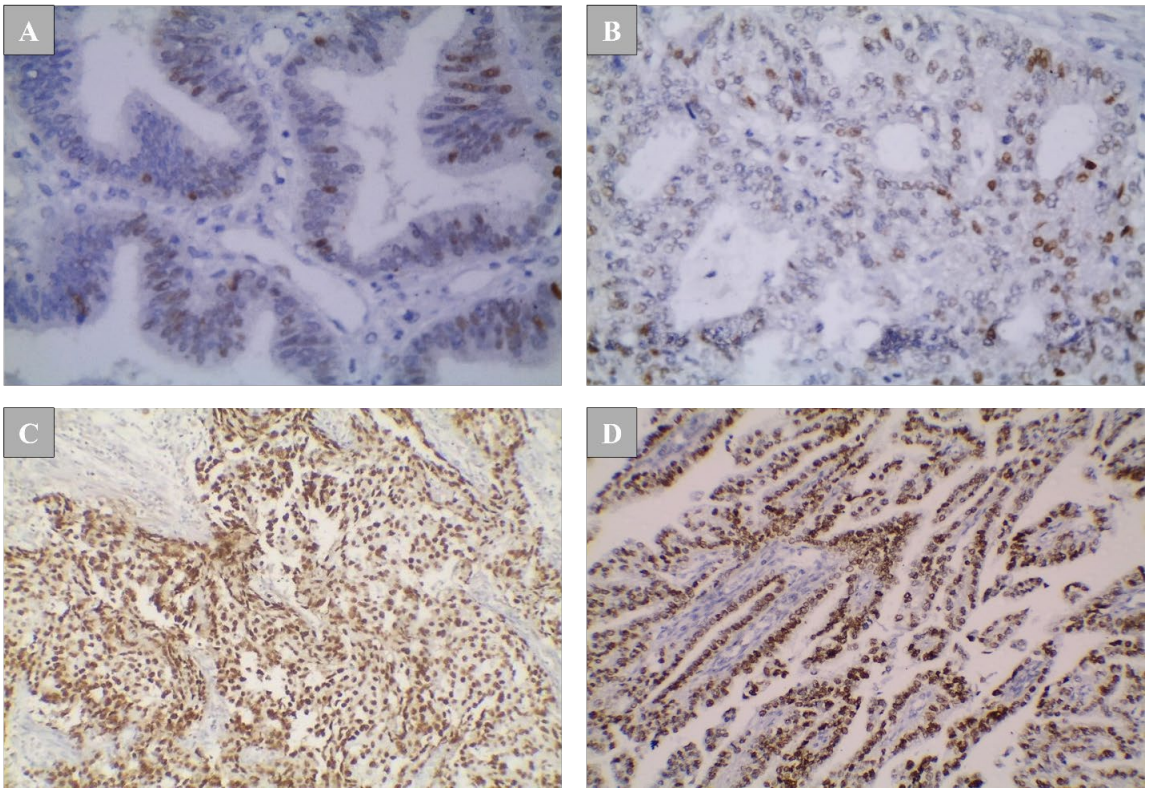

Fig. 3. P53 expression in AEH and EC cases: (A) wild type p53 nuclear expression in AEH (x400), (B) wild type nuclear p53 expression in low-grade endometrioid carcinoma (x400), (C) mutant type p53 nuclear overexpression in high-grade endometrioid carcinoma (x200), (D) mutant type p53 nuclear overexpression in serous endometrial carcinoma (x200).

Table 3. Diagnostic validity of single and combined markers expression in differentiating EEC from AEH

Marker	Sensitivity	Specificity	Positive predictive value	Negative predictive value	Diagnostic accuracy	p. value
ARID1A	66.7%	78.6%	87%	52.4%	70.5%	0.005*
β-Catenin	60%	50%	72%	36.8%	56.8%	0.745
P53	10%	100%	100%	34.2%	38.6%	0.540
ARID1A loss and β-Catenin expression	70%	71.4%	84%	52.6%	70.5%	0.003*
ARID1A loss, β-Catenin and P53 expression	53.3%	92.9%	94.1 %	48.1%	65.2%	<0.004*

*Significant value

The double-marker panel combining ARID1A loss and positive β-catenin expression improved sensitivity to 70% and specificity to 71.4%, with an accuracy of 70.5% and a significant p value (p = 0.003), surpassing either marker alone, although specificity was slightly lower than that of ARID1A loss alone (78.6%). Incorporation of p53 into a triple-marker panel further increased specificity to 92.9% but reduced sensitivity to 53.3%, as illustrated in Fig. 4. Compared with p53 alone, the triple panel markedly improved sensitivity while maintaining high specificity.

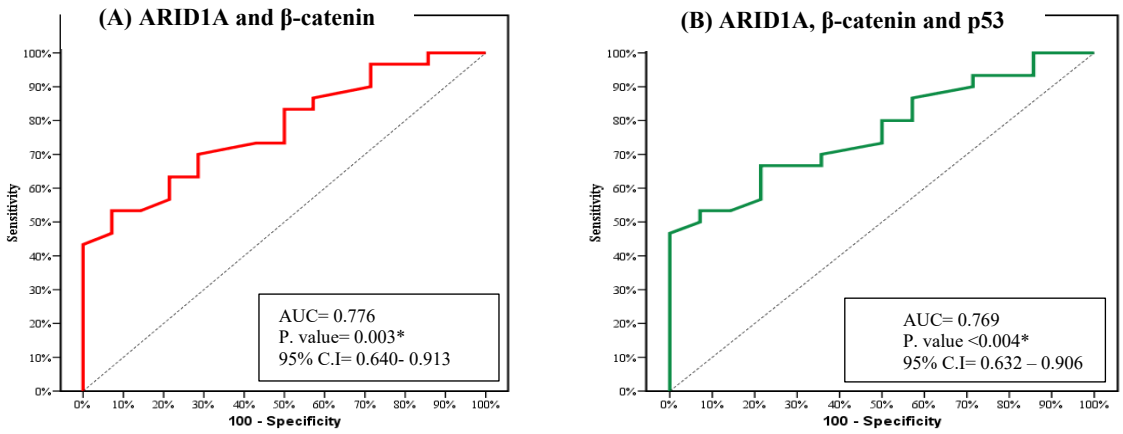

Fig. 4. ROC curve testing diagnostic performance for (A) ARID1A loss and ß-catenin expression (double marker combination), and (B) ARID1A loss, ß-catenin and p53 expression (triple marker combination) to differentiate between EEC and AEH. AUC: Area under curve, CI: Confidence interval, ROC: Receiver operating characteristics.

Differentiation of Endometrioid and Non-Endometrioid EC

For distinguishing endometrioid from non-endometrioid carcinoma, ARID1A loss alone was significantly more frequent in endometrioid carcinoma compared with non-endometrioid carcinoma ($p < 0.001$), showing moderate sensitivity (66.7%) and high specificity (88.9%), with an accuracy of 75%. Positive β-catenin alone was significantly higher in EEC ($p = 0.011$) but demonstrated lower sensitivity (60%) and specificity (77.8%), with a diagnostic accuracy of 66.7%. In contrast, mutant-type p53 was significantly more frequent in non-endometrioid carcinoma than in endometrioid carcinoma ($p < 0.001$), achieving both high sensitivity (77.8%) and specificity (90%), with an accuracy of 85.4%, as illustrated in Table 4.

The double-marker combination of ARID1A and β-catenin improved sensitivity to 86.7% but showed slightly reduced specificity (77.8%) compared with ARID1A alone (88.9%), achieving an accuracy of 83.3% ($p < 0.001$; AUC = 0.890). The triple-marker panel combining ARID1A, β-catenin, and p53 yielded the highest diagnostic performance, with sensitivity of 87.7%, specificity of 94.4%, and accuracy of 91.5% ($p < 0.001$; AUC = 0.931), outperforming single markers and the double-marker panel, as illustrated in Fig. 5.

Overall, these findings indicate that combined analysis of ARID1A, β-catenin, and p53 enhances diagnostic accuracy, particularly in distinguishing endometrioid from non-endometrioid carcinoma, while single markers provide moderate performance individually.

Table 4. Diagnostic validity of single and combined markers expression in differentiating endometrioid from non-endometrioid EC

Marker	Sensitivity	Specificity	Positive predictive value	Negative predictive value	Diagnostic accuracy	p. value
ARID1A	66.7%	88.9%	90.9%	61.5%	75%	<0.001*
β-Catenin	60%	77.8%	81.8%	53.9%	66.7%	0.011*
P53	77.8%	90%	82.4%	87.1%	85.4%	<0.001*
ARID1A loss and β-Catenin expression	86.7%	77.8%	86.7%	77.8%	83.3%	<0.001*
ARID1A loss, β-Catenin and p53 expression	87.7%	94.4%	96.3%	81%	91.5%	<0.001*

*Significant value

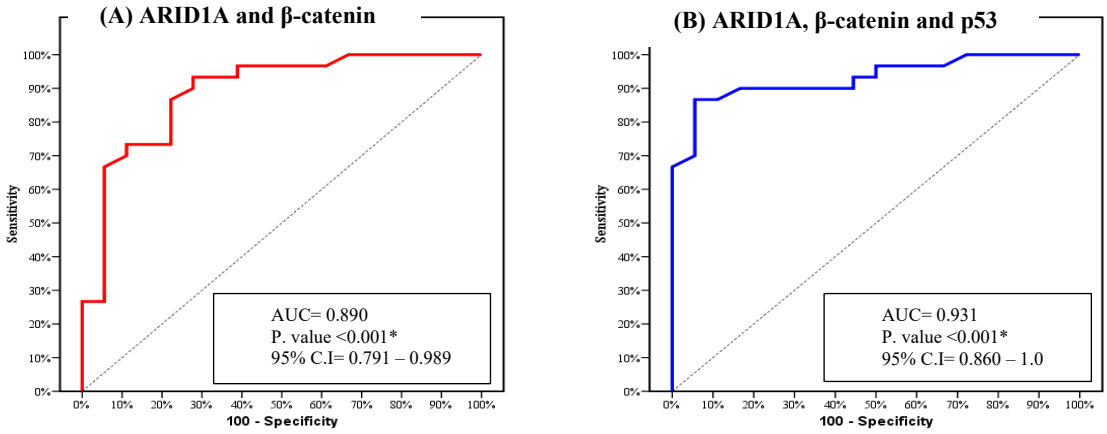

Fig. 5. ROC curve testing diagnostic performance for (A) ARID1A loss and ß-catenin expression (double combination), and (B) ARID1A loss, ß-catenin and p53 (triple combination) to differentiate between Endometrioid endometrial carcinoma (EEC) and non-endometrioid endometrial carcinoma. AUC: area under curve, CI: Confidence interval.

Discussion

Endometrial carcinoma (EC) is the sixth most commonly diagnosed cancer in females worldwide. The prevalence of EC has increased over the past decade, and it now poses serious public health concern (1). There is continuous interest in developing immunohistochemical and molecular marker combinations for the evaluation of endometrial carcinoma and premalignant endometrial lesions, which can aid in risk stratification and guide treatment decisions. In this study, we evaluated the diagnostic performance of ARID1A, β-catenin, and p53 immunohistochemical expression, either individually or in combination, to differentiate endometrioid carcinoma from AEH and to distinguish endometrioid from non-endometrioid endometrial carcinoma.

In the current study, ARID1A nuclear expression was retained in 78.6% of AEH cases, while the remaining 21.4% exhibited clonal loss. These findings are consistent with those of Hijazi et al. (22) and Yen et al. (23). However, Vierkoetter et al. (24) reported retained ARID1A expression in all AEH cases. Such discrepancies may be attributed to differences in ARID1A assessment methods and antibody clones.

Analysis of the diagnostic performance of ARID1A loss in distinguishing endometrioid carcinoma from AEH showed a sensitivity of 66.7%, specificity of 78.6%, and diagnostic accuracy of 70.5%. El Sawi et al. (25) reported similar findings but with lower sensitivity (46.7%), possibly due to differences in the number of AEH cases included.

The significant increase in ARID1A loss from AEH to endometrioid carcinoma, along with the premalignant nature of AEH, suggests that ARID1A loss may represent an early event in endometrial carcinogenesis. This highlights its potential role in disease pathogenesis and prognostic stratification. ARID1A loss contributes to impaired DNA repair and genomic instability, which are early steps in carcinogenesis (5). Progression to advanced disease likely requires additional genetic alterations beyond ARID1A loss (26).

Few studies have evaluated the role of β-catenin in differentiating endometrioid carcinoma from AEH. The current study demonstrated that positive β-catenin expression lacks diagnostic significance in this context, consistent with findings by Senol et al. (27). This limited utility may reflect the complexity of endometrial carcinogenesis, which involves multiple molecular pathways, making reliance on a single marker insufficient (28).

Regarding p53 expression, mutant-type p53 was significantly more frequent in endometrioid carcinoma compared with AEH, showing 100% specificity but very low sensitivity (10%) and diagnostic accuracy (38.6%). Similar findings were reported by Samani et al. (29), where mutant p53 expression was confined to carcinoma cases, while hyperplastic and normal tissues showed wild-type expression.

The current study also evaluated combinations of markers to enhance diagnostic performance. The dual combination of ARID1A loss and positive β-catenin expression demonstrated improved sensitivity (70%) and diagnostic accuracy (70.5%) for differentiating endometrioid carcinoma from AEH compared with either marker alone, although specificity (71.4%) was slightly lower than that of ARID1A loss alone.

In contrast, the triple combination of ARID1A loss, positive β-catenin expression, and mutant p53 improved specificity (92.9%) compared with individual markers and the dual combination, but reduced sensitivity (53.3%), limiting its overall diagnostic value in distinguishing endometrioid carcinoma from AEH. These findings suggest that the dual combination of ARID1A loss and positive β-catenin expression may represent the most practical approach for this distinction.

In distinguishing histopathological subtypes of EC, ARID1A loss was significantly more frequent in endometrioid (66.7%) than non-endometrioid carcinoma (11.1%). Lower rates of ARID1A loss have been reported by Zhang et al. (30) and Hijazi et al. (22), likely reflecting differences in sample size, antibody clones, and scoring protocols.

ARID1A demonstrated moderate sensitivity (66.7%), high specificity (88.9%), and diagnostic accuracy of 75% in differentiating endometrioid from non-endometrioid carcinoma, consistent with findings by De Leo et al. (31) and Szewczuk et al. (32). However, Asaka et al. (33) reported no significant association between ARID1A loss and histological subtype.

Positive β-catenin expression was observed in 60% of endometrioid carcinoma cases and 22.2% of non-endometrioid carcinoma cases, consistent with Yoon et al. (34). β-Catenin demonstrated moderate sensitivity (60%), specificity (77.8%), and diagnostic accuracy (66.7%). Keyhanian et al. (35) reported higher specificity but lower sensitivity, likely due to differences in classification systems used.

Mutant p53 expression was present in 77.8% of non-endometrioid carcinoma cases, including all serous carcinomas, 40% of clear cell carcinomas, and 50% of carcinosarcomas, while only 10% of endometrioid carcinoma cases showed mutant-type expression. p53 demonstrated high sensitivity (77.8%), specificity (90%), and diagnostic accuracy (85.4%), consistent with studies by Kang et al. (36) and Streel et al. (37).

Overall, the combined use of ARID1A, β-catenin, and p53 provided superior diagnostic performance. The dual combination of ARID1A loss and β-catenin improved sensitivity (86.7%) and diagnostic accuracy (83.3%) for distinguishing endometrioid from non-endometrioid carcinoma, although specificity was slightly reduced (77.8%). The triple combination demonstrated the highest diagnostic performance, with sensitivity (87.7%), specificity (94.4%), and accuracy (91.5%), supported by ROC analysis showing higher AUC values.

These findings suggest that the triple marker combination is the most effective for differentiating endometrioid from non-endometrioid carcinoma. Additionally, ARID1A, β-catenin, and p53 alterations provide insight into EC molecular subtypes. ARID1A mutations are common in MSI-high tumors, β-catenin alterations are associated with copy-number low tumors, and abnormal p53 expression characterizes copy-number high tumors with poor prognosis (19,38).

This study has limitations, including a relatively small sample size, which may limit statistical power, and a single-center design, which may affect generalizability. Larger multicenter studies are needed to validate these findings and to explore the integration of these markers into clinical practice.

Conclusion

This study suggests that the dual combination of ARID1A loss and β-catenin expression offers the best balance of sensitivity and specificity for differentiating endometrioid carcinoma from AEH. In contrast, the triple combination of ARID1A loss, β-catenin, and p53 expression provides the highest diagnostic performance for distinguishing endometrioid from non-endometrioid endometrial carcinoma.

Acknowledgments

None.

Authors' Contributors

PE and FMKh contributed to the selection and diagnosis of cases. In addition, they contributed to writing the manuscript, performing histopathological examination, and assessment of the immunohistochemical results. AB, DA, and FS revised the diagnosis of the cases, interpretations of the markers and manuscript writing. All authors read and approved the final manuscript.

Data Availability

The data supporting the results of this study are available upon request from the corresponding author.

Funding

This research received no specific grant from any funding agency in the public, commercial, or not-for-profit sectors.

Ethics Approval

Approval from the research ethics committee (REC), Faculty of Medicine, Tanta University, was obtained antecedent to conducting the study with approval code number (36190/12/22).

Consent to Participate:

This retrospective study was conducted on archived formalin-fixed paraffin-embedded tissue samples. Approval was obtained from the Research Ethics Committee, Faculty of Medicine, Tanta University. The requirement for informed consent was waived due to the retrospective nature of the study.

Conflict of Interest

The authors declared no conflict of interest.

References

1. Bray F, Laversanne M, Sung H, Ferlay J, Siegel RL, Soerjomataram I, et al. Global cancer statistics 2022: GLOBOCAN estimates of incidence and mortality worldwide for 36 cancers in 185 countries. CA Cancer J Clin. 2024;74(3):229-63. [DOI:10.3322/caac.21834] [PMID]
2. Gravbrot N, Weil CR, DeCesaris CM, Gaffney DK, Suneja G, Burt LM. Differentiation of survival outcomes by anatomic involvement and histology with the revised 2023 International Federation of Gynecology and Obstetrics staging system for endometrial cancer. Eur J Cancer. 2024;201:113913. [DOI:10.1016/j.ejca.2024.113913] [PMID]
3. Shen Y, Tian Y, Ding J, Chen Z, Zhao R, Lu Y, et al. Unravelling the molecular landscape of endometrial cancer subtypes: Insights from multiomics analysis. Int J Surg. 2024;110(9):5385-95. [PMCID] [DOI:10.1097/JS9.0000000000001685] [PMID]
4. Chou AJ, Bing RS, Ding DC. Endometrial Atypical Hyperplasia and Risk of Endometrial Cancer. Diagnostics (Basel). 2024;14(22):2471. [PMCID] [DOI:10.3390/diagnostics14222471] [PMID]
5. Kontomanolis E, Symeonidis P, Nikolettos K, Perros P, Rody A, Tsikouras P, et al. ARID1 and BRG1 Expression in Endometrial Cancer. In Vivo. 2024;38(3):1260-5. [DOI:10.21873/invivo.13563] [PMID] [PMCID]
6. Arciuolo D, Travaglino A, Raffone A, Raimondo D, Santoro A, Russo D, et al. TCGA Molecular Prognostic Groups of Endometrial Carcinoma: Current Knowledge and Future Perspectives. Int J Mol Sci. 2022;23(19):11684. [DOI:10.3390/ijms231911684] [PMID] [PMCID]
7. Chen H, Strickland A, Castrillon D. Histopathologic diagnosis of endometrial precancers: Updates and future directions. Semin Diagn Pathol. 2022;39(3):137-47. [PMID] [PMCID] [DOI:10.1053/j.semdp.2021.12.001]
8. De Leo A, de Biase D, Lenzi J, Barbero G, Turchetti D, Grillini M, et al. ARID1A and CTNNB1/β-Catenin Molecular Status Affects the Clinicopathologic Features and Prognosis of Endometrial Carcinoma: Implications for an Improved Surrogate Molecular Classification. Cancers (Basel). 2021;13(5):950. [DOI:10.3390/cancers13050950] [PMID] [PMCID]
9. Mullen J, Kato S, Sicklick J, Kurzrock R. Targeting ARID1A mutations in cancer. Cancer Treat Rev. 2021;100:102287. [DOI:10.1016/j.ctrv.2021.102287] [PMID]
10. Ledinek Z, Sobočan M, Knez J. The Role of CTNNB1 in Endometrial Cancer. Dis Markers. 2022;2022: 1442441. [DOI:10.1155/2022/1442441] [PMID] [PMCID]
11. Heckl M, Schmoeckel E, Hertlein L, Rottmann M, Jeschke U, Mayr D. The ARID1A, p53 and ß-Catenin statuses are strong prognosticators in clear cell and endometrioid carcinoma of the ovary and the endometrium. PLoS One. 2018;13(2):e0192881. [DOI:10.1371/journal.pone.0192881] [PMID] [PMCID]
12. Alexa M, Hasenburg A, Battista M. The TCGA Molecular Classification of Endometrial Cancer and Its Possible Impact on Adjuvant Treatment Decisions. Cancers (Basel). 2021;13(6):1478. [DOI:10.3390/cancers13061478] [PMID] [PMCID]
13. Edmondson R, Crosbie E, Nickkho-Amiry M, Kaufmann A, Stelloo E, Nijman H, et al. Markers of the P53 Pathway Further Refine Molecular Profiling in High-Risk Endometrial Cancer: A TransPORTEC Initiative. Gynecol Oncol. 2017;146(2):327-33. [DOI:10.1016/j.ygyno.2017.05.014] [PMID]
14. Roma A, Rybicki L, Barbuto D, Euscher E, Djordjevic B, Frauenhoffer E, et al. Risk factor analysis of

recurrence in low-grade endometrial adenocarcinoma. Hum Pathol. 2015;46(10):1529-39. [DOI:10.1016/j.humpath.2015.06.015] [PMID]

15. Kim K, Lax S, Lazar A, Longacre T, Malpica A, Matias-Guiu X, et al. Tumors of the uterine corpus. In: WHO Classification of Female Genital Tumors. 5th ed. Lyon: International Agency for Research on Cancer; 2020. p. 245-308.
16. Soslow RA, Tornos C, Park KJ, Malpica A, Matias-Guiu X, Oliva E, et al. Endometrial carcinoma diagnosis: use of FIGO grading and genomic subcategories in clinical practice: recommendations of the International Society of Gynecological Pathologists. Int J Gynecol Pathol. 2019;38(1 Suppl 1):S64-74. [DOI:10.1097/PGP.0000000000000518] [PMID]
17. Berek J, Matias-Guiu X, Creutzberg C, Fotopoulou C, Gaffney D, Kehoe S, et al. FIGO staging of endometrial cancer: 2023. Int J Gynaecol Obstet. 2023;162(2):383-94. [DOI:10.1002/ijgo.14923] [PMID] [PMCID]
18. Wang J, Xu P, Yang X, Yu Q, Xu X, Zou G, et al. Association of myometrial invasion with lymphovascular space invasion, lymph node metastasis, recurrence, and overall survival in endometrial cancer: a meta-analysis of 79 studies with 68,870 patients. Front Oncol. 2021;11:762329. [DOI:10.3389/fonc.2021.762329] [PMID] [PMCID]
19. Kato M, Yoshida H, Tanase Y, Uno M, Ishikawa M, Kato T. Loss of ARID1A Expression as a Favorable Prognostic Factor in Early-Stage Grade 3 Endometrioid Endometrial Carcinoma Patients. Pathol Oncol Res. 2021;27:598550. [DOI:10.3389/pore.2021.598550] [PMID] [PMCID]
20. Deng L, Liang H, Han Y. Cyclooxygenase-2 and β-Catenin as Potential Diagnostic and Prognostic Markers in Endometrial Cancer. Front Oncol. 2020;10:582704. [DOI:10.3389/fonc.2020.582704] [PMID] [PMCID]
21. Vermij L, Léon-Castillo A, Singh N, Powell M, Edmondson R, Genestie C, et al. p53 immunohistochemistry in endometrial cancer: clinical and molecular correlates in the PORTEC-3 trial. Mod Pathol. 2022;35(10):1475-83. [DOI:10.1038/s41379-022-01102-x] [PMID]
22. Hijazi N, Almadani N, Gilks C, Huntsman D. ARID1A Loss of Expression in Complex Atypical Hyperplasia and Grade 1 Endometrioid Carcinoma of the Endometrium. Can J Pathol. 2015;7(3):23-30.
23. Yen T, Miyamoto T, Asaka S, Chui M, Wang Y, Lin S, et al. Loss of ARID1A expression in endometrial samplings is associated with the risk of endometrial carcinoma. Gynecol Oncol. 2018;150(3):426-31. [DOI:10.1016/j.ygyno.2018.06.025] [PMID]
24. Vierkoetter K, Wong J, Ahn H, Shimizu D, Kagami L, Terada K. Using gene expression in patients with endometrial intraepithelial neoplasia to assess the risk of cancer. Gynecol Oncol Rep. 2018;24:24-6. [DOI:10.1016/j.gore.2018.02.006] [PMID] [PMCID]
25. El Sawi R, Hassan A, Youssef S, Agina H, Ahmed H, Ibrahim E. The Diagnostic and Prognostic Significance of ARID1A and CD8+ Expression in Endometrial Hyperplasia and Endometrial Endometrioid Adenocarcinoma (Immunohistochemical study). Benha Med J. 2022;39(1):294-318. [DOI:10.21608/bmfj.2022.156719.1642]
26. Raab J, Resnick S, Magnuson T. Genome-Wide Transcriptional Regulation Mediated by Biochemically Distinct SWI/SNF Complexes. PLoS Genet. 2015;11(12):e1005748. [PMID] [PMCID] [DOI:10.1371/journal.pgen.1005748]
27. Senol S, Sayar I, Ceyran A, Ibiloglu I, Akalin I, Firat U, et al. Stromal clues in endometrial carcinoma: loss of expression of β-catenin, epithelial-mesenchymal transition regulators, and estrogen-progesterone receptor. Int J Gynecol Pathol. 2016;35(3):238-48. [DOI:10.1097/PGP.0000000000000233] [PMID] [PMCID]
28. Raffone A, Travaglino A, Saccone G, Mascolo M, Insabato L, Mollo A, et al. PAX2 in endometrial carcinogenesis and in differential diagnosis of endometrial hyperplasia. A systematic review and meta-analysis of diagnostic accuracy. Acta Obstet Gynecol Scand. 2019;98(3):287-99. [DOI:10.1111/aogs.13512] [PMID]
29. Samani S, Ezazi Bojnordi T, Zarghampour M, Merat S, Fouladi D. Expression of p53, Bcl-2 and Bax in endometrial carcinoma, endometrial hyperplasia and normal endometrium: a histopathological study. J Obstet Gynaecol. 2018;38(7):999-1004. [DOI:10.1080/01443615.2018.1437717] [PMID]
30. Zhang Z, Xiao S, Sun G, Liu Y, Zhang F, Yang H, et al. The clinico pathologic significance of the loss of BAF250a (ARID1A) expression in endometrial carcinoma. Int J Gynecol Cancer. 2014;24(3):534-40. [DOI:10.1097/IGC.0000000000000092] [PMID]
31. De Leo A, Ravegnini G, Musiani F, Maloberti T, Visani M, Sanza V, et al. Relevance of ARID1A Mutations in Endometrial Carcinomas. Diagnostics (Basel). 2022;12(3):592. [PMCID] [DOI:10.3390/diagnostics12030592] [PMID]
32. Szewczuk W, Szewczuk O, Czajkowski K, Górnicka B, Ilczuk T, Semczuk A. ARID1A and GPR30 expression patterns characterize the different histological subtypes of endometrial carcinoma. Eur J Gynaecol Oncol. 2021;42(6):1138-45. [DOI:10.31083/j.ejgo4206166]
33. Asaka S, Liu Y, Yu Z, Rahmanto Y, Ono M, Asaka R, et al. ARID1A Regulates Progesterone Receptor Expression in Early Endometrial Endometrioid Carcinoma Pathogenesis. Mod Pathol. 2023;36(2): 100045. [DOI:10.1016/j.modpat.2022.100045] [PMID]
34. Yoon H, Suh D, Kim K, No JH, Kim Y, Kim H. Evaluation of prognostic potential of β-catenin and L1CAM expression according to endometrial cancer risk group. Gynecol Oncol. 2024;184:132-8. [DOI:10.1016/j.ygyno.2024.01.044] [PMID]
35. Keyhanian K, Yang E, Howitt B. Nuclear β-Catenin Expression in the Context of Abnormal p53 Expression Indicates a Nonserous Histotype in Endometrial Carcinoma. Int J Gynecol Pathol. 2023;42(5):435-42. [DOI:10.1097/PGP.0000000000000923] [PMID]
36. Kang E, Wiebe N, Aubrey C, Lee C, Anglesio M, Tilley D, et al. Selection of endometrial carcinomas for p53 immunohistochemistry based on nuclear features. J Pathol Clin Res. 2022;8(1):19-32. [DOI:10.1002/cjp2.243] [PMID] [PMCID]

37. Streel S, Salmon A, Dheur A, Bours V, Leroi N, Habran L, et al. Diagnostic Performance of Immunohistochemistry Compared to Molecular Techniques for Microsatellite Instability and p53 Mutation Detection in Endometrial Cancer. Int J Mol Sci. 2023;24(5):4866. [DOI:10.3390/ijms24054866] [PMID] [PMCID]

38. Yang Y, Wu S, Bao W. Molecular subtypes of endometrial cancer: Implications for adjuvant treatment strategies. Int J Gynaecol Obstet. 2023;164(2):436-59. [DOI:10.1002/ijgo.14969] [PMID]