Iranian Journal of Pathology | ISSN: 2345-3656

LAPTM4B and MMP9 Immunohistochemical Expression in Hepatocellular Carcinoma: Relation to Clinicopathological Features and Prognostic Implications in Egyptian Patients

Doha Maher Taie*, Mona Saeed Tantawy, Walaa Gaber El gendy, Taysseer Abd El-hamid Talab

Department of Pathology, National Liver Institute, Menoufia University, Shebin El Kom, Egypt

KEYWORDS

Hepatocellular carcinoma, lysosomal-associated transmembrane protein 4B, matrix metalloproteinase-9

Scan to discover online

Main Subjects:
GI, Liver & Pancreas Pathology

Received 29 Nov 2025;
Accepted 11 Feb 2026;
Published Online 10 May 2026;

10.22034/ijp.2026.2076149.3569

ABSTRACT

Background & Objective: Hepatocellular carcinoma (HCC) is a leading cause of cancer-related death worldwide. Lysosomal-associated transmembrane protein 4B (LAPTM4B) and matrix metalloproteinase-9 (MMP9) are overexpressed in various cancers; however, their relevance in HCC is not well defined, particularly among Egyptian patients. This study aimed to investigate the immunohistochemical expression of LAPTM4B and MMP9 in HCC and to assess their associations with clinicopathological features.

Methods: Seventy-five HCC cases with matched adjacent non-tumorous areas were retrospectively examined. The mean patient age was 53.33 ± 9.07 years, with a 4.36:1 male-to-female ratio. The mean follow-up duration was 25.6 months. Overall survival was 58.7% (44/75), while 41.3% (31/75) died during follow-up. Immunohistochemistry was used to evaluate LAPTM4B and MMP9 expression, and correlations with clinicopathological features were analyzed.

Results: LAPTM4B and MMP9 were overexpressed in tumor tissues compared with adjacent non-tumorous areas ($p < 0.001$). Higher LAPTM4B expression was associated with female gender ($p = 0.043$), older age ($p = 0.041$), lower alpha-fetoprotein levels ($p = 0.042$), and poorer overall survival ($p = 0.022$). Higher MMP9 expression correlated with tumor grade and lymphovascular invasion ($p = 0.026$). A positive correlation was observed between LAPTM4B and MMP9 H-scores ($p < 0.038$).

Conclusion: LAPTM4B and MMP9 are overexpressed in HCC and show significant associations with tumor behavior. LAPTM4B correlates with features linked to prognosis, while MMP9 reflects aggressive tumor behavior. Their concurrent upregulation suggests involvement in overlapping biological processes. These findings support further evaluation of LAPTM4B and MMP9 as potential prognostic biomarkers in Egyptian patients; however, evaluation of mechanistic and therapeutic implications requires additional study.

Corresponding Information: **Doha Maher Taie**, Department of Pathology, National Liver Institute, Menoufia University, Shebin El Kom, Egypt. E-mail: dr_dohamaher@yahoo.com

Copyright © 2026. This is an open-access article distributed under the terms of the **Creative Commons Attribution 4.0 International License (CC BY 4.0)**, which permits unrestricted use, distribution, and reproduction in any medium, provided the original work is properly cited. The license also allows users to adapt, remix, transform, and build upon the material for any purpose, including commercial use.

Introduction

Hepatocellular carcinoma (HCC) is one of the most lethal malignancies worldwide, with a rising incidence, particularly in Africa and Asia (1,2). In Egypt, it represents a major health burden, accounting for over 30% of cancer-related mortality (3,4). Despite advancements in diagnosis and therapy, patient outcomes remain poor, and the five-year survival rate remains low (5). This underscores the need to identify novel molecular biomarkers that better characterize tumor behavior and improve prognostication and therapeutic strategies (6,7).

Lysosomal-associated transmembrane protein 4B (LAPTM4B), a member of the LAPTM protein family, is an oncogenic protein initially identified by fluorescence differential display in HCC and subsequently found to be overexpressed in several solid cancers (8). It enhances tumor proliferation, invasion, and metastasis partly through activation of the PI3K/AKT/NF-κB pathway and upregulation of matrix metalloproteinase-9 (MMP9) (9). MMP9 (gelatinase B, 92 kDa) is a major metalloproteinase produced by human macrophages and is responsible for extracellular matrix degradation (10). It facilitates tumor invasion, migration, and angiogenesis through pathways frequently dysregulated in HCC (11,12).

Despite the established oncogenic roles of LAPTM4B and MMP9, their relative contributions to HCC pathogenesis remain unclear. Among Egyptian patients, available studies have mainly addressed serum levels or genetic polymorphisms, whereas immunohistochemical evaluation of their tissue expression in HCC remains scarce. This gap highlights the need to evaluate their expression patterns and explore their potential pathogenic and prognostic significance in HCC.

Materials and Methods

This retrospective cohort study included 75 HCC tissues with matched adjacent non-tumorous areas from Egyptian patients who underwent surgical resection at the National Liver Institute (NLI), Menoufia University, Egypt (2018–2022). The study protocol was IRB approved (IRB 00771/2025), and informed consent was obtained. Clinical data were extracted from medical records, including age, gender, hepatitis B/C status, serum levels of alpha-fetoprotein (AFP), prior treatments, recurrence, and overall survival (OS). Follow-up averaged 25.6 months (range: 1–39.2). Paraffin-embedded tissue blocks were retrieved from the Pathology Department archives.

Inclusion criteria: Eligible cases required adequate formalin-fixed, paraffin-embedded tissue blocks containing viable primary HCC tissue and matched adjacent non-tumorous liver at least 1 cm from the tumor margin. Patients must not have received any preoperative neoadjuvant treatment (e.g., transarterial chemoembolization, local ablation, systemic therapy, targeted therapy, or immunotherapy) to avoid treatment-related biomarker alterations. Complete clinical and follow-up data, including demographics, laboratory results, and virology status, were required.

Exclusion criteria: Cases were excluded if tumor or adjacent tissue was insufficient or nonviable, if matched non-tumorous liver was unavailable, in instances of recurrent HCC or other primary hepatic malignancies (e.g., combined hepatocellular–cholangiocarcinoma), or when clinical or pathological data were incomplete. Samples with inadequate tissue quality for immunohistochemistry (poor fixation, overfixation, fragmentation, or antigen degradation) were also excluded.

Histopathological evaluation was performed to assess tumor type, size, focality, lymphovascular invasion (LVI), tumor grade (WHO 2019) (13), and tumor stage (AJCC 8th edition) (14). Masson trichrome stain was used to assess adjacent non-tumor tissue as cirrhotic or noncirrhotic.

Immunohistochemical technique and interpretation

Tissue microarrays (TMAs) were manually constructed using a 2 mm punch needle (Beecher Instruments, USA). For each case, two cores from the tumor and adjacent non-tumorous tissue were selected (15). Immunohistochemistry (IHC) was performed using a streptavidin-biotin amplification method (16). Sections were incubated with polyclonal rabbit antibodies targeting LAPTM4B (Abcam, Cambridge, UK; Ref: ab70328; dilution 1:100) and MMP9 (Quartett Biocyc Biotechnology, Potsdam, Germany; Ref: MA 100-02_RUO; dilution 1:100).

After tissue deparaffinization and rehydration, antigen retrieval was carried out using high-pH EDTA solution (Dako, Ref K8000, Glostrup, Denmark), followed by cooling at room temperature for 20 minutes. Slides were incubated with primary antibodies overnight at 4 °C. Secondary antibody using the Ultravision detection system (anti-polyvalent HRP/DAB, ready-to-use, Neomarker) was applied for 30 minutes. Staining was visualized using DAB chromogen substrate and Mayer's hematoxylin as a counterstain.

Positive controls (kidney tissue for LAPTM4B; thyroid tissue for MMP9) and negative controls (omitting the primary antibody) were included. All control and patient tissues were processed and stained in parallel using identical protocols (fixation time, paraffin embedding, section thickness, antigen retrieval, antibody batches, and detection reagents).

Staining intensity was independently scored by two pathologists into four levels: negative (0), weak (1), moderate (2), and strong (3). The staining percent H-score was calculated (0–300), and median values of tumor samples were used for analysis. High expression was defined as greater than or equal to the median value, and low expression as less than the median value (17). In cases of disagreement between the two independent histopathologists, a consensus was reached through joint review.

Statistical Analysis

Statistical analysis was conducted using SPSS version 20.0 (IBM, Armonk, NY). Categorical variables were presented as frequencies and percentages. To compare categorical variables between two groups, the chi-square test was applied; however, if more than 20% of expected cell counts were below 5, Fisher's exact test was used instead.

The distribution of continuous variables was evaluated using the Kolmogorov-Smirnov test to determine normality. Continuous variables were described using the range, mean, standard deviation, and median as appropriate. For comparing two sets of normally distributed continuous variables, the independent samples t-test was used. The Wilcoxon signed-rank test was used to compare paired nonparametric variables. In cases involving more than two groups with non-normally distributed data, the Kruskal-Wallis test was conducted.

Kaplan–Meier survival curves were used to evaluate overall survival. Prognostic 95% confidence intervals (CI) and hazard ratios were estimated using multivariate Cox regression analysis. Statistical significance was considered at a p value less than or equal to 0.05.

Results

Patient Characteristics:

Demographic, clinical, laboratory, histopathological, recurrence, and overall survival data for the 75 HCC cases are shown in Table 1.

Immunohistochemical Expression of LAPTM4B and MMP9:

Immunohistochemical results for both markers in HCC and matched adjacent non-tumorous tissues are presented in Table 2 and Figures 1–4. The [high LAPTM4B, high MMP9] profile was more frequent in tumor tissue, while adjacent non-tumor tissues most commonly exhibited [low LAPTM4B and/or low MMP9] expression.

Table 1. Distribution of the studied cases according to different parameters (N = 75)

Parameter	N (%)
Sex	
Male	61 (81.3%)
Female	14 (18.7%)
Age (years)	
< 55 years old **≥55 years old**	37 (49.3%) 38 (50.7%)
Min. – Max.	14.0 – 70.0
Mean ± SD.	53.33 ± 9.07
Median (IQR)	55 (48.0 – 59.0)
Etiology	
Non-viral	7 (9.3%)
Viral	68 (90.7%)
HCV	65 (86.7%)
HBV	3 (4.0%)
Focality	
Single	46 (61.3%)
Multiple	29 (38.7%)
Stage	
Early stage	72 (96.0%)
T1	25 (33.3%)
T2	47 (62.7%)
Late stage	3 (4.0%)
T3	2 (2.7%)
T4	1 (1.3%)
Grade	
Low grade	57 (76.0%)
I	4 (5.3%)
II	53 (70.7%)
High grade	18 (24.0 %)
III	17 (22.7%)
IV	1 (1.3%)
Size	
< 4 cm	30 (40.0%)
≥ 4 cm	45 (60.0%)
Min. – Max.	0.5 – 17.0
Mean ± SD.	4.41 ± 2.90

Parameter	N (%)
Median (IQR)	4.0 (3.0 – 5.0)
Recurrence	
No	59 (78.7%)
Yes	16 (21.3%)
Min. – Max.	1.0 – 24.0
Mean ± SD.	10.13 ± 5.25
Median (IQR)	11.0 (6.0 – 12.0)
Overall survival	
Live	44 (58.7%)
Dead	31 (41.3%)
Survival [months]	
Min. – Max.	0.4 – 96.0
Mean ± SD.	24.92 ± 19.96
Median (IQR)	21.0 (12.0 – 34.0)
AFP	
Min. – Max.	3 – 20010
Mean ± SD.	1118.34 ± 3600.59
Median (IQR)	47.50 (8.15 – 256.50)
Treatment	
Received treatment	37 (49.3%)
DAA	24 (32.0%)
Interferon	13 (17.3%)
NO treatment	36 (48.0%)
Adjacent	
Cirrhotic	65 (86.7%)
Non cirrhotic	10 (13.3%)
Lympho vascular invasion (LVI)	
Present	29 (38.7%)
Absent	46 (61.3%)

IQR: Inter quartile range, SD: Standard deviation, N: number, %: percentage, Min. – Max: Minimal-Maximum, AFP: alpha fetoprotein, DDA: Direct-Acting Antiviral, LVI: lymphovascular invasion.

Table 2. Immunohistochemical expression of LAPTM4B and MMP9 in HCC and adjacent non-tumor tissues

LAPTM4B expression in adjacent non-tumor tissue			
LAPTM4B percent	Min. – Max. Mean ± SD. Median (IQR)	0.0 –100.0 54.07 ±35.58 50.0(20.0 –90.0)	
LAPTM4B H-SCORE	Min. – Max. Mean ± SD. Median (IQR)	0.0 – 300.0 80.87 ± 77.09 50.0(20.0 – 100.0)	
LAPTM4B expression	Low High	36 39	52.0 % 48.0 %
LAPTM4B expression in HCC			
LAPTM4B percent	Min. – Max. Mean ± SD. Median (IQR)	10.0 –100.0 95.60 ±16.09 100.0(100.0 –100.0)	
LAPTM4B H-SCORE	Min. – Max. Mean ± SD. Median (IQR)	10.0 – 300.0 265.13 ± 68.77 300.0(270.0 – 300.0)	
LAPTM4B expression	Low High	23 52	30.7 % 69.3 %

LAPTM4B expression in adjacent non-tumor tissue			
MMP9 expression in adjacent non-tumor tissue			
MMP9 percent	Min. – Max. Mean ± SD. Median (IQR)	0.0 –100.0 41.47 ±36.34 40.0(10.0 –80.0)	
MMP9 H-SCORE	Min. – Max. Mean ± SD. Median (IQR)	0.0 – 120.0 42.40 ± 37.41 40.0 (10.0 – 80.0)	
MMP9 expression	Low High	43 32	57.3 42.7
MMP9 expression in HCC			
MMP9 percent	Min. – Max. Mean ± SD. Median (IQR)	0.0 –100.0 90.60 ±21.75 100.0(100.0 –100.0)	
MMP9 H-SCORE	Min. – Max. Mean ± SD. Median (IQR)	0.0 – 300.0 128.93 ± 58.48 100.0(100.0 – 160.0)	
MMP9 expression	Low High	8 67	10.7 89.3
Immunophenotype profile of adjacent non-tumor tissue	Both LAPTM4B and MMP9 show high expression	19	25.3%
	At least one of LAPTM4B or MMP9 shows low expression.	56	74.7%
Immunophenotype of HCC tumor tissue	Both LAPTM4B and MMP9 show high expression	48	64.0%
	At least one of LAPTM4B or MMP9 show low expression.	27	36.0%

IQR: Inter quartile range, SD: Standard deviation, Min. – Max: Minimal-Maximum, %: percentage, LAPTM4B: Lysosomal-associated transmembrane protein 4B, MMP9: matrix metalloproteinase-9, HCC: Hepatocellular carcinoma.

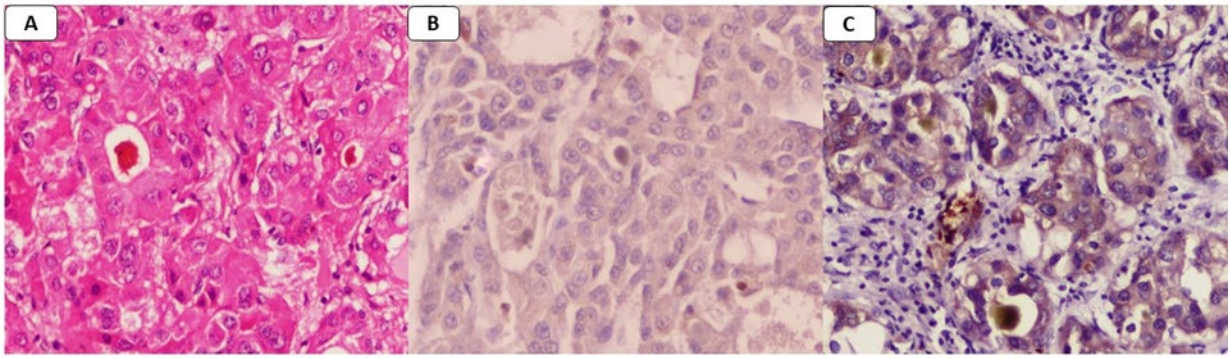

Fig. 1. (A) HCC moderate grade (H&E x200); **(B)** with low LAPTM4B cytoplasmic expression (IHC x200); **(C)** with low MMP9 cytoplasmic expression (IHC x200).

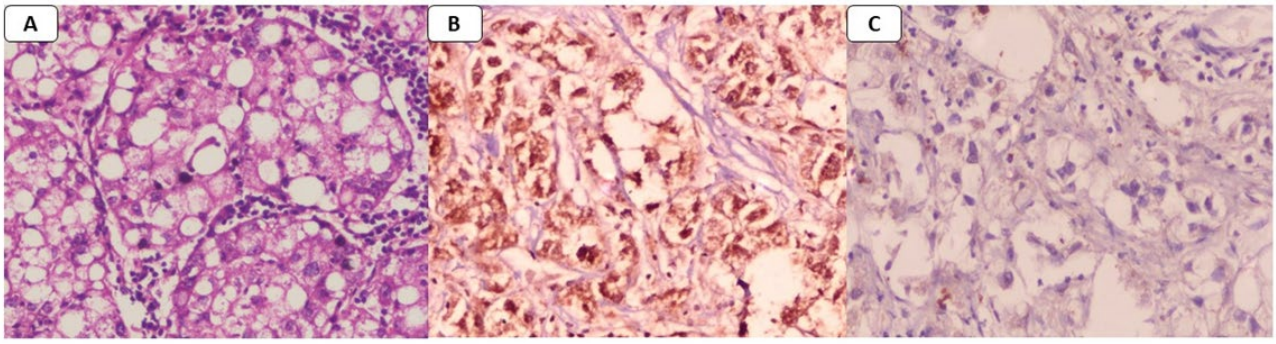

Fig. 2. (A) HCC, steatohepatitic variant (H&E x200); **(B)** with high LAPTM4B cytoplasmic expression (IHC x200); **(c)** with low MMP9 cytoplasmic expression (IHC x200).

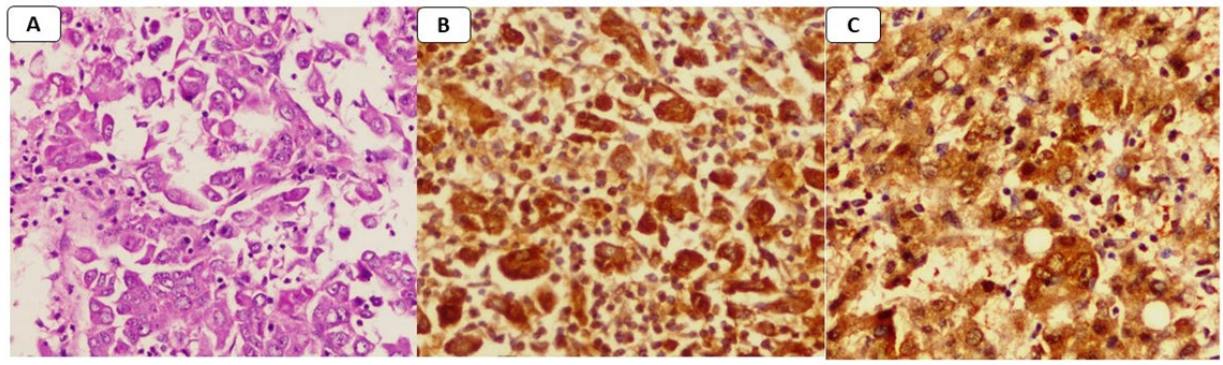

Fig. 3. (A) HCC High grade (H&E x200); **(B)** with high LAPTM4B cytoplasmic expression (IHC x200); **(c)** with high MMP9 cytoplasmic expression (IHC x200).

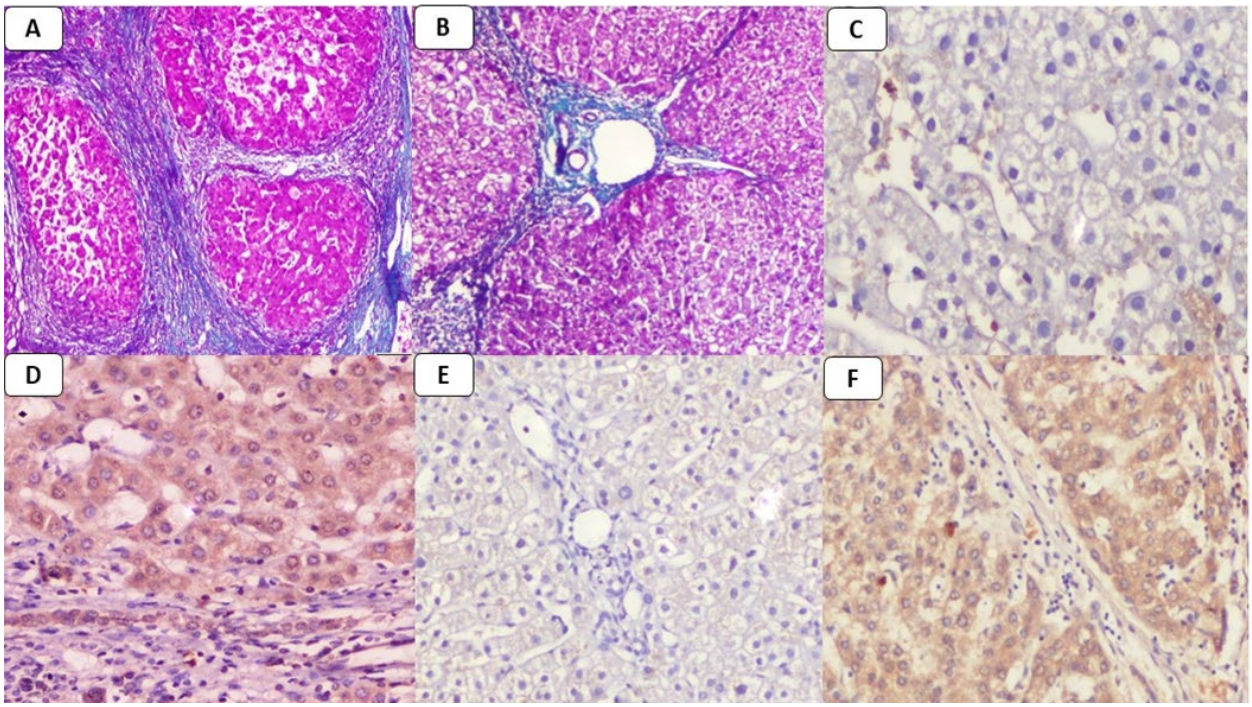

Fig. 4. Examples of adjacent non tumor liver tissues. **(A)** with cirrhosis (Masson trichrome (MT) stain x200); **(B)** non cirrhotic with features of chronic hepatitis (MT x200); **(C)** with negative LAPTM4B cytoplasmic expression (IHC x200); **(D)** with mild LAPTM4B cytoplasmic expression (IHC x200); **(E)** with negative MMP9 expression (IHC x200); **(F)** with mild MMP9 cytoplasmic expression (IHC x200).

Tumor versus Adjacent Non-Tumor Comparison:

Both LAPTM4B and MMP9 were significantly upregulated in tumor tissues compared with adjacent non-tumor tissues ($p < 0.001$ for each) (Table 3, Fig. 5).

Correlation Between LAPTM4B and MMP9:

LAPTM4B and MMP9 H-scores showed a significant positive correlation in HCC tissues ($p = 0.038$) (Fig. 6).

LAPTM4B Expression and Clinicopathological Parameters in HCC:

High LAPTM4B expression was significantly associated with female gender ($p = 0.043$), older age ($p = 0.041$), and lower AFP levels ($p = 0.042$). High LAPTM4B expression was also linked to poorer overall survival, with 26 of 31 deceased patients showing elevated levels ($p = 0.022$). Although not statistically significant, higher LAPTM4B tended to occur in tumors with viral etiology, multifocality, larger size (≥4 cm), advanced T stages, higher grade, cirrhosis, and lymphovascular invasion. Patients treated with DAAs before surgery showed lower LAPTM4B expression than those treated with interferon or no antiviral therapy (Tables 4–5).

Table 3. Comparison between tumor and adjacent non-tumor tissue according to LAPTM4B H score and MMP9 H score

	Tumor (N = 75)	Adjacent (N= 75)	Test of Sig.	p
LAPTM4B H score				
Min. – Max.	10.0 – 300.0	0.0 –300.0	Z= 7.297*	<0.001*
Mean ± SD.	265.13 ± 68.77	80.87 ± 77.09		
Median (IQR)	300.0(270.0 – 300.0)	50.0(20.0 –100.0)		
MMP9 H score				
Min. – Max.	0.0 – 300.0	0.0 – 120.0	Z= 7.308*	<0.001*
Mean ± SD.	128.93 ± 58.48	42.40 ± 37.41		
Median (IQR)	100.0(100.0 – 160.0)	40.0 (10.0 –80.0)		

IQR: **Inter quartile range,** SD: **Standard deviation,** Z: **Wilcoxon signed ranks test,** p: p value for comparing between tumor and adjacent, *: Statistically significant at $p \leq 0.05$, N**: number, LAPTM4B: Lysosomal-associated transmembrane protein 4B, MMP9: matrix metalloproteinase-9**

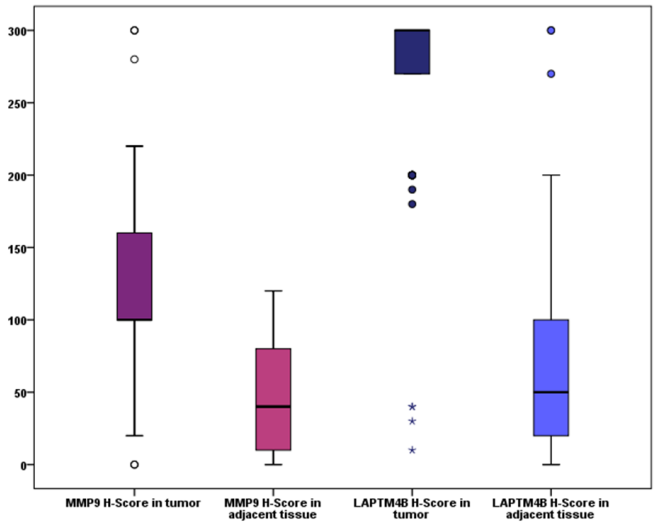

Fig. 5. Comparison between tumor and adjacent non-tumor tissue according to MMP9 and LAPTM4B H-Score.

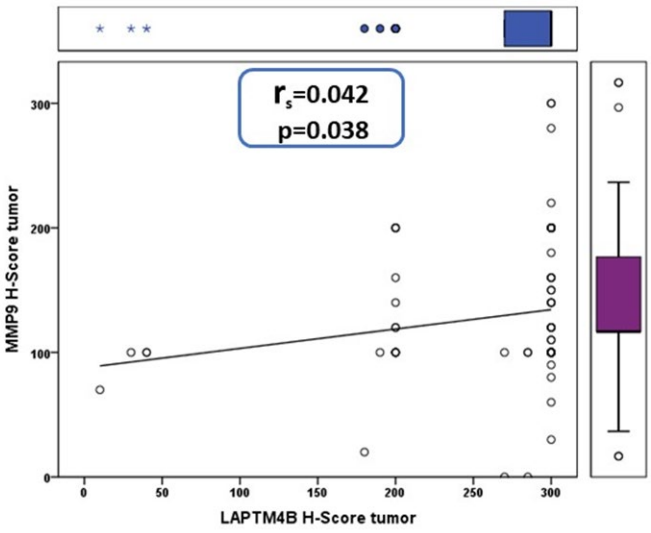

Fig 6. Correlation between MMP9 and LAPTM4B H-Score in tumor [r_s: Spearman coefficient]

Table 4. Relation between LAPTM4B H- score with clinicopathological parameters of the studied HCC cases (N= 75)

	LAPTM4B expression				χ2 P	LABTM4B H score tumor		Test of Sig. P
	Low (N=23)		High (N=52)			Mean ± SD.	Median (Min. -Max.)	
	N	%	N	%				
Age (years)					1.766 0.184			U=801.0 0.202
< 55 years old	14	37.8	23	62.2		255.95±79.83	300(10 – 300)	
≥55 years old	9	23.7	29	76.7		274.08±55.60	300(40 – 300)	
Sex					3.026 0.082			U=306.0 0.043
Male	16	26.2	45	73.8		261.30 ± 72.58	300.0 (10.0 – 300.0)	
Female	7	50.0	7	50.0		271.21 ± 63.01	300.0 (30.0 –300.0)	
Etiology					0.540 0.463			U=208.0 0.502
Viral	20	29.4	48	70.6		267.06 ± 65.74	300.0 (10.0 – 300.0)	
Non-viral	3	42.9	4	57.1		246.43±98.09	300.0 (40.0 –300.0)	
Focality					0.211 0.646			U=709.50 0.570
Single	15	32.6	31	67.4		261.30 ±72.58	300.0 (30.0 – 300.0)	
Multiple	8	27.6	21	72.4		271.21±63.01	300.0 (10.0 –300.0)	
Size					0.167 0.683			U=726.50 0.494
< 4 cm	10	33.3	20	66.7		252.17±85.70	300.0 (10.0 – 300.0)	
≥ 4 cm	13	28.9	32	71.1		273.78±54.06	300.0 (30.0 –300.0)	
Stage					0.010 0.919			U=105.50 0.949
Early	22	30.6	50	69.4		265.07±69.54	300.0 (10.0 – 300.0)	
Advanced	1	33.3	2	66.7		266.67±57.74	300.0(200.0 –300.0)	
Grade					FE=3.658 0.310			H=2.423 0.489
I	2	50.0	2	50.0		210.0 ±122.75	300.0 (40.0 – 300.0)	
II	14	26.4	39	73.6		266.13±70.91	300.0 (10.0 –300.0)	
III	6	35.3	11	64.7		274.71±42.99	300.0(200.0–300.0)	
IV	1	100	0	0		270.0		
Recurrence					1.358 0.244			U=541.50 0.270
No	20	33.9	39	66.1		262.46 ± 68.76	300.0 (10.0 – 300.0)	
Yes	3	18.8	13	81.3		275.00 ± 70.14	300.0 (30.0 –300.0)	
Status					5.252 0.022			U=822.50 0.063
Censored	18	40.9	26	59.1		263.75 ± 56.81	300.0 (40.0 – 300.0)	
Dead	5	16.1	26	83.9		267.10 ± 83.87	300.0 (10.0 –300.0)	
Treatment					FE=0.705 0.728			H=0.835 0.659
DAA	9	37.5	15	62.5		255.42 ± 66.59	300.0 (40.0 – 300.0)	
Interferon	4	30.8	9	69.2		268.08 ±76.80	300.0 (30.0 –300.0)	
No	10	27.8	26	72.2		268.61±70.09	300.0 (10.0 –300.0)	
Adjacent					0.473 0.492			U=299.5 0.625
Cirrhotic	19	29.2	46	70.8		266.00±67.00	300.0 (10.0 – 300.0)	
Non cirrhotic	4	40.0	6	60.0		259.50±83.22	300.0 (30.0 –300.0)	
LVI					0.211 0.646			U=623.5 0.561
Present	8	27.6	21	72.4		271.90±60.09	300.0 (30.0 – 300.0)	
Absent	15	32.6	31	67.4		260.87±74.04	300.0 (10.0 –300.0)	

U: Mann Whitney test, H: H for **Kruskal Wallis test,** p: p value for comparison between the studied categories

*: Statistically significant at p ≤ 0.05, IQR: Inter quartile range, SD: Standard deviation, N: number, %: percentage, Min. – Max: Minimal-Maximum, DDA: Direct-Acting Antiviral, LVI: lymphovascular invasion, LAPTM4B: Lysosomal-associated transmembrane protein 4B, HCC: Hepatocellular carcinoma.

Table 5. Correlation between expression of MMP9, LAPTM4B percent and H-score in tumor tissue, with different clinicopathological parameters of the studied HCC cases.

	LAPTM4B percent		LAPTM4B H score		MMP9 percent		MMP9 H score	
	r_s	p	r_s	p	r_s	p	r_s	p
Age	0.237	0.041 *	-0.170	0.146	0.212	0.068	0.213	0.067
AFP	-0.262	0.042*	-0.147	0.271	-0.388	0.003*	-0.154	0.248
Size	0.078	0.505	0.073	0.535	0.215	0.064	0.002	0.983

r_s: Spearman coefficient, p: p value for comparison between the studied categories, *: Statistically significant at $p \leq 0.05$, **LAPTM4B: Lysosomal-associated transmembrane protein 4B, MMP9: matrix metalloproteinase-9, HCC: Hepatocellular carcinoma, AFP: alpha fetoprotein.**

MMP9 Expression and Clinicopathological Parameters in HCC:

High MMP9 expression was significantly associated with higher tumor grade (p = 0.026), lymphovascular invasion (p = 0.026), and lower AFP levels (p = 0.042). Although other correlations were not statistically significant, elevated MMP9 tended to be more frequent in cases with viral etiology, advanced stage, multifocal tumors, cirrhosis, and prior DAA treatment (Tables 5–6).

Table 6. Relation between MMP9 H score with clinicopathological parameters of the studied HCC cases (N= 75)

	MMP9 expression				χ2 P	MMP9H score tumor		Test of Sig. P
	Low (N=8)		High (N= 67)			Mean ± SD.	Median (Min. – Max.)	
	N	%	N	%				
Age (years)					2.360 0.124			U=848 0.109
< 55 years old	6	16.2	31	83.8		120.54±60.50	100.0(0 – 280)	
≥55 years old	2	5.3	36	94.7		137.11±56.04	120.0 (30 – 300)	
Sex					0.237 0.627			U=369.0 0.410
Male	6	9.8	55	90.2		131.48 ±57.76	100.0 (0.0 – 300.0)	
Female	2	14.3	12	85.7		117.86 ± 62.53	100.0 (20.0 – 300.0)	
Etiology					2.597 0.107			U=207.50 0.562
Viral	6	8.8	62	91.2		131.47±57.52	100.0 (0.0 – 300.0)	
Non-Viral	2	28.6	5	71.4		104.29 ± 66.79	110.0 (0.0 – 220.0)	
Focality					0.005 0.943			U=708.50 0.637
Single	5	10.9	41	89.1		124.57±55.85	100.0 (0.0 – 300.0)	
Multiple	3	10.3	26	89.7		135.86 ± 62.82	100.0 (30.0 – 300.0)	
Size					0.840 0.360			U=676.00 0.991
< 4 cm	2	6.7	28	93.3		133.67±58.22	100.0 (70 – 300.0)	
≥ 4 cm	6	13.3	39	86.7		125.78±59.10	100.0 (0.0 – 280.0)	
Stage					0.373 0.541			U=148.00 0.301
Early	8	11.1	64	88.9		126.81±56.69	100.0 (0.0 – 300.0)	
Advanced	0	0.0	3	100		180.00 ± 91.65	160.0 (100 – 280.0)	

	MMP9 expression				χ2 P	MMP9H score tumor		Test of Sig. P
	Low (N=8)		High (N= 67)			Mean ± SD.	Median (Min. – Max.)	
	N	%	N	%				
Grade								
I	0	0	4	100	FE=9.285 0.026	125.0 ± 50.0	100.0 (100.0 –200.0)	H=3.909 0.271
II	6	11.3	47	88.7		133.58±55.96	110.0 (20.0 – 300.0)	
III	1	5.9	16	94.1		122.94±63.42	100.0 (0.0 –300)	
IV	1	100	0	0		0.0		
Recurrence								
No	5	8.5	54	91.5	1.395 0.238	133.24±60.78	100.0 (0.0 – 300.0)	U=437.50 0.641
Yes	3	18.8	13	81.3		120.00±54.30	100.0 (0.0 –300.0)	
Status								
Censored	1	11.4	39	88.6	0.054 0.816	126.82±61.64	100.0 (0.0 – 280.0)	U=758.0 0.393
Dead	3	9.7	28	90.3		131.94±54.55	120.0 (30.0 – 300.0)	
Treatment								
DAA	1	4.2	23	95.8	FE=1.836 0.425	146.67 ± 60.55	115.0 (80.0 – 300.0)	H=3.166 0.205
Interferon	2	15.4	11	84.6		108.46 ± 55.05	100.0 (0.0 – 200.0)	
No	5	13.9	31	86.1		120.00 ± 54.30	100.0 (0.0 –300.0)	
Adjacent								
Cirrhotic	7	10.8	58	89.2	0.005 942	131.08±59.14	100.0 (0.0 – 300.0)	U=292.50 0.597
Non cirrhotic	1	10	9	9		115.00±54.82	100.0 (0.0 – 200.0)	
LVI								
Present	6	20.7	23	79.3	4.985 0.026	121.03±58.15	100.0 (0.0 – 200.0)	U=715.50 0.582
Absent	2	4.3	44	95.7		133.91±58.78	100.0 (20.0 – 300.0)	

U: Mann Whitney test, H: H for **Kruskal Wallis test,** p: p value for comparison between the studied categories, *: Statistically significant at $p \leq 0.05$. IQR: **Inter quartile range**, SD: **Standard deviation, N: number, %: percentage, Min. – Max: Minimal-Maximum, DDA: Direct-Acting Antiviral, LVI: lymphovascular invasion, MMP9: matrix metalloproteinase-9, HCC: Hepatocellular carcinoma.**

Profile of Cases with [High LAPTM4B and High MMP9] Phenotype:

Cases with dual high-expression phenotype were predominantly aged ≥55 years (56.3%), male (87.5%), cirrhotic (87.5%), without preoperative antiviral treatment (52.2%), positive for viral hepatitis (93.3%), had larger tumors (≥4 cm; 60.4%), higher grades (II and III; 72.9% and 22.9%), and T2 stage (58.3%) (Table 7).

Survival Analysis

Survival data were available for all 75 patients. Overall survival ranged from 0.4 to 96 months (mean 24.92 ± 19.96; median 21 months). Thirty-one patients (41.3%) died during follow-up (Table 1).

Univariate Analysis of Overall Survival Predictors

High LAPTM4B expression was associated with worse survival (p = 0.021). The [high LAPTM4B, high MMP9] phenotype was also linked to poor outcomes, being present in 77.4% of deaths (24 of 31) (p = 0.05). MMP9 alone was not significantly associated with survival (Figures 7–8).

Table 7. Relation between HCC Immunophenotypes with Clinicopathological parameters of the studied HCC cases (n= 75)

	High LAPTM4B and high MMP9 phenotype (N=48)		Low LAPTM4B or/and low MMP9 phenotype (N= 27)		χ2	P
	N	%	No	%		
Age (years)					1.663	0.197
< 55 years old	21	43.8	16	59.3		
≥55 years old	27	56.3	11	40.7		
Sex					3.340	0.068
Male	42	87.5	19	70.4		
Female	6	12.5	8	29.6		
Etiology					1.498	0.221
Viral	45	93.8	23	85.2		
Non-viral	3	6.3	4	14.8		
Focality					0.047	0.828
Single	29	60.4	17	63.0		
Multiple	19	39.6	10	37.0		
Size					0.010	0.922
< 4 cm	19	39.6	11	40.7		
≥ 4 cm	29	60.4	16	59.3		
Stage					0.010	0.922
Early	46	95.8	26	96.3		
Advanced	2	4.2	1	3.7		
Grade					2.217	0.529
I	2	4.2	2	7.4		
II	35	72.9	18	66.7		
III	11	22.9	6	22.2		
IV	0	0.0%	1	3.7%		
Recurrence					0.199	0.213
No	37	77.1	22	81.5		
Yes	11	22.9	5	18.5		
Status					4.130	0.042
Censored	24	50.0	20	74.1		
Dead	24	50.0	7	25.9		
Treatment					0.444	0.801
DAA	14	30.4	10	37.0		
Interferon	8	17.4	5	18.5		
No	24	52.2	12	44.4		
Adjacent					0.080	0.777
Cirrhotic	42	87.5	23	85.2		
Non cirrhotic	6	12.5	4	14.8		
LVI					0.594	0.441
Present	17	35.4	12	44.4		
Absent	31	64.6	15	55.6		

p: p value for comparison between the studied categories χ2: ***Chi square test,****: Statistically significant at p ≤ 0.05, **N: number, %: percentage, DDA: Direct-Acting Antiviral, LVI: lymphovascular invasion, LAPTM4B: Lysosomal-associated transmembrane protein 4B, MMP9: matrix metalloproteinase-9, HCC: Hepatocellular carcinoma.**

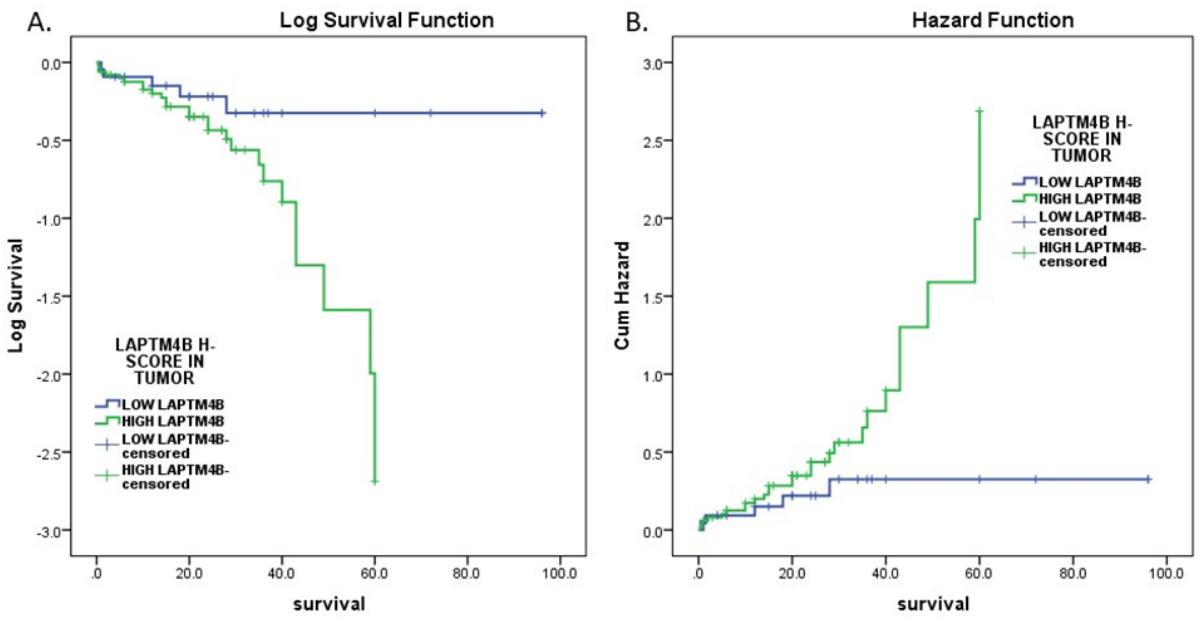

Fig 7. Kaplan-Meier survival curve demonstrating the impact of LAPTM4B on overall survival (Log rank= 5.316, P=0.021). B) Hazard function of overall survival for HCC patients revealed that high LAPTM4B was more hazardous.

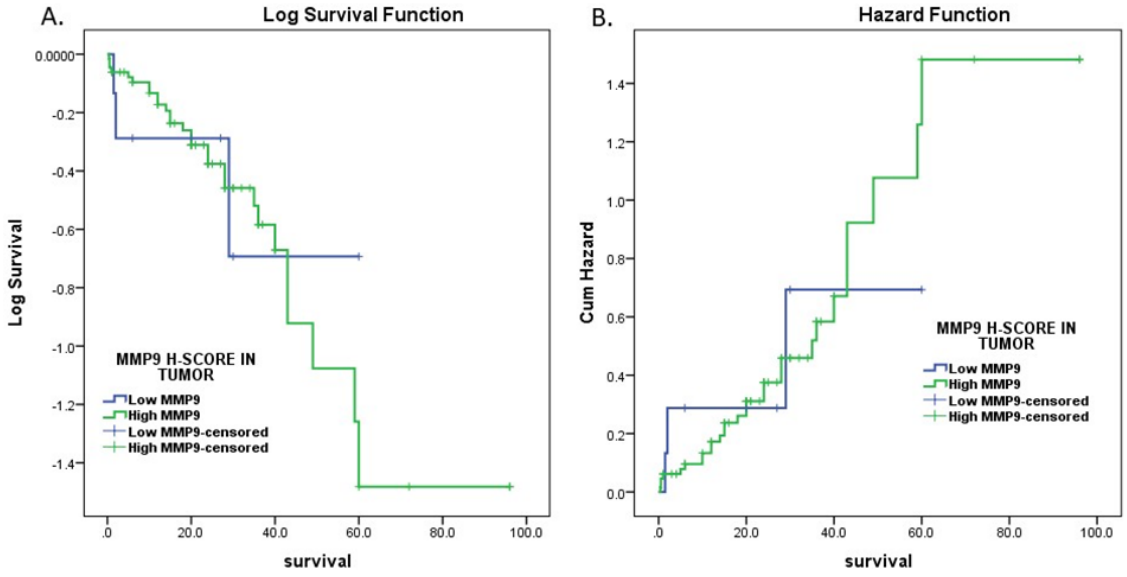

Fig 8. Kaplan-Meier survival curve demonstrating the impact of MMP9 on overall survival (Log rank=0.011, P=0.915). B) Hazard function of overall survival for HCC patients in view of MMP9 expression.

Multivariate Cox Regression:

Multivariate analysis identified preoperative antiviral therapy and lymphovascular invasion as independent predictors of poor overall survival in patients with HCC (Table 8).

Recurrence-Free Survival:

The recurrence-free survival period ranged from 1.0 to 24 months (mean 12.16 ± 5.25; median 11 months) (Table 1). Recurrence occurred in 16 of 75 cases (21.3%). No clinicopathological factors independently predicted recurrence-free survival on univariate or multivariate analysis (Table 8, Fig. 9).

Table 8. Multivariate COX –regression analysis for detection of the most independent prognostic factor affecting Overall survival

Clinicopathological data	Hazard ratio	(95%CI)		P-value
		Lower	Upper	
Age	1.283	0.525	3.138	0.584
Sex	0.460	0.131	1.623	0.228
Antiviral treatment	2.122	0.123	7.788	0.048**
Size	2.425	0.822	7.156	0.109
Focality	1.288	0.488	3.404	0.609
Grade	11988.4	0.000	5.081E+88	0.450
Stage group	1354.36	0.000	2.455E+61	0.916
LVI	3.443	1.197	9.903	0.022**
Adjacent	2.158	0.466	9.995	0.325
LAPTM4B	1.165	0.072	18.926	0.915
MMP9	1.744	0.144	21.055	0.662
Immunophenotype profile	1.733	0.090	33.430	0.716

CI= confidence interval, **significant, LVI: lymphovascular invasion, LAPTM4B: Lysosomal-associated transmembrane protein 4B, MMP9: matrix metalloproteinase-9.

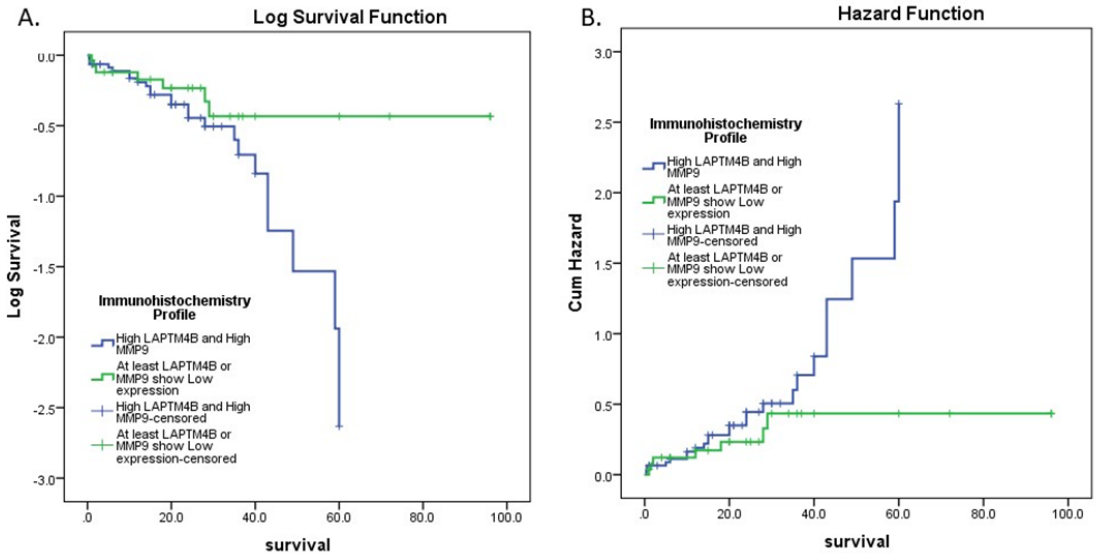

Fig. 9. Kaplan-Meier survival curve demonstrating the impact of immunohistochemical profile on overall survival (Log rank= 3.563, P=0.05). B) Hazard function of overall survival for HCC patients revealed that High LAPTM4B and High MMP9 immunohistochemical profile was more hazardous.

Discussion

HCC represents a formidable malignancy, largely due to its intricate molecular pathways and resistance to treatment. Although therapeutic strategies have witnessed significant progress, overall patient survival remains unsatisfactory (18). Thus, uncovering the molecular mechanisms driving HCC initiation and progression, alongside identifying reliable biomarkers for diagnosis and therapy, is a critical step toward improving patient outcomes. The current study aimed to elucidate the immunohistochemical expression patterns of LAPTM4B and MMP-9 in HCC in Egyptian patients and to assess their associations with standard clinicopathological parameters and patient prognosis.

Our findings reveal a marked upregulation of LAPTM4B in malignant hepatic tissues compared with adjacent noncancerous counterparts. This aligns with previous studies (19,20) that demonstrated elevated LAPTM4B expression in HCC compared with surrounding non-tumorous tissues. Furthermore, its overexpression has also been documented in several other solid tumors, including those of the ovary, bladder, and breast, compared with normal and premalignant tissues, reinforcing the gene's proposed oncogenic role in various cancer types (21). LAPTM4B has been implicated in endosomal-lysosomal trafficking, autophagy modulation, and regulation of signaling pathways that promote proliferation, survival, and metastasis in various cancers. Its overexpression in HCC could reflect enhanced endocytic trafficking that fosters oncogenic signaling and resistance to stress (22).

In line with LAPTM4B, our study also demonstrated a significant increase in MMP-9 expression in HCC tissues compared with adjacent non-tumorous liver tissues. This upregulation aligns with previous findings reporting frequent MMP-9 overexpression in HCC and other solid tumors, including cancers of the colon, prostate, breast, lung, and pancreas (23-26). These results suggest a central role for MMP-9 in malignant transformation and invasive tumor behavior. It is typically found at higher levels in malignant tumors and their surrounding peritumoral tissues compared with normal or benign tissues, with maximal expression observed in actively invasive regions at the tumor–stromal interface (10). In HCC, MMP-9 is thought to have two principal functions: degradation of the extracellular matrix and modulation of angiogenesis (27,28). These processes disrupt the balance within this highly vascular tumor, facilitating growth and spread.

The shift toward a tumor phenotype characterized by [High LAPTM4B / High MMP9] may indicate cooperative interactions or shared regulatory pathways that drive invasion, angiogenesis, and survival in HCC cells. Potential cross-talk may involve shared signaling pathways regulating lysosomal function, autophagy, and matrix remodeling. The concordant high expression suggests a coordinated tumor-specific program facilitating malignant behavior. These findings support that both markers are actively induced during hepatocarcinogenesis and tumor progression rather than reflecting background expression.

The observed positive correlation between LAPTM4B and MMP9 suggests shared regulatory mechanisms (e.g., PI3K/AKT, NF-κB, or MAPK pathways) or a possible causal relationship. LAPTM4B may influence endosomal/lysosomal trafficking and thereby affect processing or secretion of proteases such as MMP9. Alternatively, both proteins may be induced by common oncogenic stressors within the tumor microenvironment (29). Additionally, LAPTM4B has been shown to promote invasion, adhesion, and angiogenesis by stimulating hypoxia-inducible factor-1α (HIF-1α) along with MMP-2 and MMP-9 expression. Conversely, LAPTM4B knockdown reduces expression of proliferating cell nuclear antigen (PCNA), VEGF, MMP-2, MMP-9, and CDK12 (30).

Our analysis revealed a significant relationship between elevated LAPTM4B expression and female gender, older age, and reduced overall survival. The higher expression in females may reflect sex-specific regulation or hormonal influences (31). The LAPTM4B gene has two alleles (*1 and *2), and studies suggest that the *2 allele is associated with higher expression and stronger oncogenic effects, particularly in female patients (32). The association with age may reflect cumulative exposure to etiologic factors or age-related molecular changes (33). Several studies have reported increased LAPTM4B expression with advancing age in cancer patients (34).

The inverse relationship between LAPTM4B expression and AFP levels suggests that LAPTM4B-high tumors may represent AFP-low subtypes with distinct biological behavior. Clinically, reliance on AFP alone may fail to detect these cases (35). Although not statistically significant, trends toward higher LAPTM4B expression in tumors with viral etiology, multifocality, larger size, advanced stage, higher grade, cirrhosis, and lymphovascular invasion support its association with aggressive tumor phenotype (36). The observation of lower LAPTM4B expression in patients treated with DAAs may reflect reduced inflammatory signaling, although this requires further investigation (37).

High MMP-9 expression was significantly associated with higher tumor grade and lymphovascular invasion, consistent with previous studies linking MMP-9 to tumor invasion, metastasis, and poor differentiation (38,39). By degrading type IV collagen, MMP-9 facilitates invasion and vascular penetration, contributing to tumor progression (40).

An inverse association between MMP-9 expression and AFP levels was observed, although this is not commonly reported in the literature. It may reflect complex interactions between extracellular matrix remodeling and tumor biomarker production (41). Viral etiology and advanced-stage trends suggest that MMP-9 upregulation may be linked to chronic inflammation and activation of transcription factors such as NF-κB and AP-1 (42).

Higher MMP-9 expression in patients treated with DAAs may reflect complex interactions between viral clearance, immune modulation, and tumor biology (43,44). In our cohort, cases with [High LAPTM4B, High MMP9] phenotype were predominantly older, male, cirrhotic, and associated with viral hepatitis, aligning with known epidemiological patterns (45). This phenotype was also associated with larger tumors, higher grade, and T2 stage, supporting its link to aggressive tumor behavior (46,47).

Regarding survival, high LAPTM4B expression was significantly associated with poorer overall survival, indicating its potential as a prognostic biomarker. Although MMP-9 alone was not significantly associated with survival, the combined [High LAPTM4B, High MMP9] phenotype was linked to higher mortality (77.4% of deaths), suggesting a synergistic effect (22,48). Independent predictors of poor survival included preoperative antiviral treatment status and lymphovascular invasion, consistent with established literature (44,49).

Limitations and Future Perspectives: This study has several limitations. It is retrospective and conducted at a single center, which may limit generalizability. The sample size, although adequate for exploratory analysis, does not support broad conclusions, and no external validation cohort was included. Two cases had missing data regarding preoperative antiviral treatment status, introducing

minor uncertainty. The observational design precludes causal inference.

Future research should include prospective multicenter studies with larger cohorts, as well as genomic and functional analyses to clarify mechanistic links. Experimental models may help determine whether targeting LAPTM4B alone or in combination with MMP9 inhibitors has therapeutic potential. Integration of these markers into multifactorial prognostic models may improve risk stratification and guide individualized treatment strategies.

Conclusion

Our results suggest that LAPTM4B and MMP9 are biologically and clinically meaningful markers of tumor aggressiveness in Egyptian patients with HCC. LAPTM4B overexpression was strongly associated with poorer overall survival, highlighting its potential as a prognostic biomarker and therapeutic target. Although MMP9 alone was not independently associated with survival, its combined expression with LAPTM4B identified patients at highest risk. These findings support the incorporation of LAPTM4B, alone or with MMP9, into prognostic models. Further studies are needed to validate these findings and explore therapeutic implications.

Acknowledgments

The authors would like to express their sincere gratitude to the medical and technical staff of the Pathology Department for their invaluable assistance in sample collection, preparation, and analysis. Special thanks are extended to the laboratory team for their support and dedication throughout the immunohistochemical procedures. The authors are also grateful to the patients and their families for their cooperation, without which this research would not have been possible.

Authors' Contributors

None.

Data Availability

The data supporting the results of this study are available upon request from the corresponding author.

Funding

This research received no specific grant from any funding agency in the public, commercial, or not-for-profit sectors.

Ethics Approval

The study protocol was conducted in accordance with the Declaration of Helsinki of the World Medical association.

Consent to Participate:

Written informed consent was obtained from all participants before enrollment in the study and before blood sample collection. Participants who were unable or unwilling to provide consent were excluded from the study. This is consistent with the Methods section, which states that eligible participants provided written informed consent and that inability or unwillingness to consent was an exclusion criterion.

Conflict of Interest

The authors declared no conflict of interest.

References

1. Bray F, Laversanne M, Sung H, Ferlay J, Siegel RL, Soerjomataram I, et al. Global cancer statistics 2022: GLOBOCAN estimates of incidence and mortality worldwide for 36 cancers in 185 countries. CA Cancer J Clin. 2024;74(3):229-63. [DOI:10.3322/caac.21834] [PMID]
2. Petrick JL, Florio AA, Znaor A, Ruggieri D, Laversanne M, Alvarez CS, et al. International trends in hepatocellular carcinoma incidence, 1978-2012. Int J Cancer. 2020;147(2):317-30. [DOI:10.1002/ijc.32723] [PMID] [PMCID]
3. Bray F, Ferlay J, Soerjomataram I, Siegel RL, Torre LA, Jemal A. Global cancer statistics 2018: GLOBOCAN estimates of incidence and mortality worldwide for 36 cancers in 185 countries. CA Cancer J Clin. 2018;68(6):394-424. [DOI:10.3322/caac.21492] [PMID]
4. Yameny AA. Hepatocellular carcinoma (HCC) in Egypt: Prevalence, risk factors, diagnosis and prevention: A Review. J Biosci Appl Res. 2024;10(4): 879-90. [DOI:10.21608/jbaar.2024.393371]
5. European Association for the Study of the Liver. EASL Clinical Practice Guidelines: Management of hepatocellular carcinoma. J Hepatol. 2018;69(1):182-236.
6. Xu Y, Tian H, Luan CG, Sun K, Bao PJ, Zhang HY, et al. Telocytes promote hepatocellular carcinoma by activating the ERK signaling pathway and miR-942-3p/MMP9 axis. Cell Death Discov. 2021;7(1):209. [DOI:10.1038/s41420-021-00592-z] [PMID] [PMCID]
7. Ko KL, Mak LY, Cheung KS, Yuen MF. Hepatocellular carcinoma: recent advances and emerging medical therapies. F1000Res. 2020;9:546. [DOI:10.12688/f1000research.24543.1] [PMID] [PMCID]
8. Yang H, Xiong F, Wei X, Yang Y, McNutt MA, Zhou R. Overexpression of LAPTM4B-35 promotes growth and metastasis of hepatocellular carcinoma in vitro and in vivo. Cancer Lett. 2010;294(2):236-44. [DOI:10.1016/j.canlet.2010.02.006] [PMID]
9. Wang F, Wu H, Zhang S, Lu J, Lu Y, Zhan P, et al. LAPTM4B facilitates tumor growth and induces autophagy in hepatocellular carcinoma. Cancer Manag Res. 2019;11:2485-97. [DOI:10.2147/CMAR.S201092] [PMID] [PMCID]
10. Vandooren J, Van den Steen PE, Opdenakker G. Biochemistry and molecular biology of gelatinase B or matrix metalloproteinase-9 (MMP-9): the next decade. Crit Rev Biochem Mol Biol. 2013;48(3):222-72. [DOI:10.3109/10409238.2013.770819] [PMID]
11. Barillari G. The Impact of Matrix Metalloproteinase-9 on the Sequential Steps of the Metastatic Process. Int J Mol Sci. 2020;21(12):4520. [DOI:10.3390/ijms21124526] [PMID] [PMCID]
12. Sapa-Wojciechowska A, Rak-Pasikowska A, Pormańczuk K, Czapla B, Bil-Lula I. Extracellular Matrix Remodeling Factors as Markers of Carotid Artery Atherosclerosis. Cardiol Res Pract. 2020;2020:9036157. [DOI:10.1155/2020/9036157] [PMID] [PMCID]
13. Nagtegaal ID, Odze RD, Klimstra D, Paradis V, Rugge M, Schirmacher P, et al. The 2019 WHO classification of tumours of the digestive system. Histopathology. 2020;76(2):182-8. [DOI:10.1111/his.13975] [PMID] [PMCID]
14. Amin MB, Greene FL, Edge SB, Compton CC, Gershenwald JE, Brookland RK, et al. The Eighth Edition AJCC Cancer Staging Manual: Continuing to build a bridge from a population-based to a more "personalized" approach to cancer staging. CA Cancer J Clin. 2017;67(2):93-9. [DOI:10.3322/caac.21388] [PMID]
15. Kim KH, Choi SJ, Choi YI, Kim L, Park IS, Han JY, et al. In-house Manual Construction of High-Density and High-Quality Tissue Microarrays by Using Homemade Recipient Agarose-Paraffin Blocks. Korean J Pathol. 2013;47(3):238-44. [DOI:10.4132/KoreanJPathol.2013.47.3.238] [PMID] [PMCID]
16. Magaki S, Hojat SA, Wei B, So A, Yong WH. An Introduction to the Performance of Immunohistochemistry. Methods Mol Biol. 2019;1897:289-98. [DOI:10.1007/978-1-4939-8935-5_25] [PMID] [PMCID]
17. Price P, Ganugapati U, Gatalica Z, Kakadekar A, Macpherson J, Quenneville L, et al. Reinventing Nuclear Histo-score Utilizing Inherent Morphologic Cutoffs: Blue-brown Color H-score (BBC-HS). Appl Immunohistochem Mol Morphol. 2023;31(7):500-6. [DOI:10.1097/PAI.0000000000001095] [PMID] [PMCID]
18. Amin N, Anwar J, Sulaiman A, Naumova NN, Anwar N. Hepatocellular Carcinoma: A Comprehensive Review. Diseases. 2025;13(7):207. [DOI:10.3390/diseases13070207] [PMID] [PMCID]
19. Roy G, Roy P, Bhattacharjee A, Shahid M, Misbah M, Gupta S, et al. Expression signature of lysosomal-associated transmembrane protein 4B in hepatitis C virus-induced hepatocellular carcinoma. Int J Biol Markers. 2018;33(3):283-92. [DOI:10.1177/1724600818773631] [PMID]
20. Wang M, Liao J, Wang J, Xu M, Cheng Y, Wei L, et al. HDAC2 promotes autophagy-associated HCC malignant progression by transcriptionally activating LAPTM4B. Cell Death Dis. 2024;15(8):593. [DOI:10.1038/s41419-024-06981-3] [PMID] [PMCID]
21. Xu XC, Feng JG, Tang LL. Lysosomal-associated protein transmembrane-4 beta: a novel potential biomarker for cancer therapy with multiple functions. Chin Med J (Engl). 2020;134(1):38-40. [DOI:10.1097/CM9.0000000000001021] [PMID] [PMCID]
22. Meng Y, Wang L, Chen D, Chang Y, Zhang M, Xu JJ, et al. LAPTM4B: an oncogene in various solid tumors and its functions. Oncogene. 2016;35(50):6359-65. [DOI:10.1038/onc.2016.189] [PMID] [PMCID]

23. Pinheiro LCL, Pereira ÉR, Francelino AL, Guembarovski AFML, Fuganti PE, de Oliveira KB, et al. Metalloproteinase 9 immunostaining profile is positively correlated with tumor grade, extraprostatic extension and biochemical recurrence in prostate cancer. Pathol Res Pract. 2024;253:155024. [DOI:10.1016/j.prp.2023.155024] [PMID]

24. Mohammadizadeh F, Bagherian-Dehkordia M. Relationship between matrix metalloproteinase-9 and some clinicopathological prognostic factors of breast carcinoma. Am J Clin Exp Immunol. 2021;10(1):17-22. [DOI:10.21203/rs.3.rs-16942/v1]

25. Veljkovic A, Stanojevic G, Brankovic B, Roumeliotis S, Leivaditis K, Djordjevic B, et al. MMP-9 Activation via ROS/NF-κB Signaling in Colorectal Cancer Progression: Molecular Insights and Prognostic-Therapeutic Perspectives. Curr Issues Mol Biol. 2025;47(7):557. [DOI:10.3390/cimb47070557] [PMID] [PMCID]

26. Yu X, Huang J, Wu S, Huang Y, Shan Y, Lu C. Copy number variations of MMP-9 are prognostic biomarkers for hepatocellular carcinoma. Transl Cancer Res. 2020;9(2):698-706. [DOI:10.21037/tcr.2019.11.52] [PMID] [PMCID]

27. Reunanen N, Kähäri V. Matrix metalloproteinases in cancer cell invasion. In: Madame Curie Bioscience Database. Austin (TX): Landes Bioscience; 2013. [Available from: https://www.ncbi.nlm.nih.gov/books/NBK6142/].

28. Kahari V, Reunanen N. Matrix metalloproteinases in cancer cell invasion. In: Cell invasion. Austin (TX): Eurekah; 2002. p. 1-11. [DOI:10.1201/9781498713160-6]

29. Yang Y, Li Y, Wang Y, Chen X, Yao Y, Li D, et al. The role and regulatory mechanism of lysosome associated protein transmembrane 4β in tumors. Front Oncol. 2025;15:1482012. [DOI:10.3389/fonc.2025.1552007] [PMID] [PMCID]

30. Rehman Z, Fahim A, Bhatti A, Sadia H, John P. Co-expression of HIF-1α, MDR1 and LAPTM4B in peripheral blood of solid tumors. PeerJ. 2019;7:e6309. [DOI:10.7717/peerj.6309] [PMID] [PMCID]

31. Natri HM, Wilson MA, Buetow KH. Distinct molecular etiologies of male and female hepatocellular carcinoma. BMC Cancer. 2019;19(1):951. [DOI:10.1186/s12885-019-6167-2] [PMID] [PMCID]

32. Li X, Kong X, Chen X, Zhang N, Jiang L, Ma T, et al. LAPTM4B allele* 2 is associated with breast cancer susceptibility and prognosis. 2012. [DOI:10.1371/journal.pone.0044916] [PMID] [PMCID]

33. Kim IH, Kisseleva T, Brenner DA. Aging and liver disease. Curr Opin Gastroenterol. 2015;31(3):184-91. [DOI:10.1097/MOG.0000000000000176] [PMID] [PMCID]

34. Liao J, Wang J, Xu Y, Wu Y, Wang M, Zhao Q, et al. LAPTM4B-YAP loop feedback amplification enhances the stemness of hepatocellular carcinoma. iScience. 2023;26(6):106754. [DOI:10.1016/j.isci.2023.106754] [PMID] [PMCID]

35. Carr B, Guerra V, Ince V, Isik B, Yilmaz S. Alpha-fetoprotein and albumin inversely relate to each other and to tumor parameters in patients with hepatocellular carcinoma. Hepatol Forum. 2024;5(1):11-7. [DOI:10.14744/hf.2023.2023.0023] [PMID] [PMCID]

36. Meng Y, Wang L, Xu J, Zhang Q. AP4 positively regulates LAPTM4B to promote hepatocellular carcinoma growth and metastasis, while reducing chemotherapy sensitivity. Mol Oncol. 2018;12(3):373-90. [DOI:10.1002/1878-0261.12171] [PMID] [PMCID]

37. Imai K, Takai K, Hanai T, Suetsugu A, Shiraki M, Shimizu M. Sustained virological response by direct-acting antivirals reduces the recurrence risk of hepatitis C-related hepatocellular carcinoma after curative treatment. Mol Clin Oncol. 2020;12(2):111-6. [DOI:10.3892/mco.2019.1956]

38. Chen SZ, Yao HQ, Zhu SZ, Li QY, Guo GH, Yu J. Expression levels of matrix metalloproteinase-9 in human gastric carcinoma. Oncol Lett. 2015;9(2):915-9. [DOI:10.3892/ol.2014.2768] [PMID] [PMCID]

39. Elewa MAF, Al-Gayyar MM, Schaalan MF, Abd El Galil KH, Ebrahim MA, El-Shishtawy MM. Hepatoprotective and anti-tumor effects of targeting MMP-9 in hepatocellular carcinoma and its relation to vascular invasion markers. Clin Exp Metastasis. 2015;32(5):479-93. [DOI:10.1007/s10585-015-9721-6] [PMID]

40. Chen JS, Wang Q, Fu XH, Huang XH, Chen XL, Cao LQ, et al. Involvement of PI3K/PTEN/AKT/mTOR pathway in invasion and metastasis in hepatocellular carcinoma: Association with MMP-9. Hepatol Res. 2009;39(2):177-86. [DOI:10.1111/j.1872-034X.2008.00449.x] [PMID]

41. Cabral-Pacheco GA, Garza-Veloz I, Castruita-De la Rosa C, Ramirez-Acuña JM, Perez-Romero BA, Guerrero-Rodriguez JF, et al. The Roles of Matrix Metalloproteinases and Their Inhibitors in Human Diseases. Int J Mol Sci. 2020;21(24):9583. [DOI:10.3390/ijms21249739] [PMID] [PMCID]

42. Yuan H, Xu R, Li S, Zheng M, Tong Q, Xiang M, et al. The Malignant Transformation of Viral Hepatitis to Hepatocellular carcinoma: Mechanisms and Interventions. MedComm (2020). 2025;6(3):e70121. [DOI:10.1002/mco2.70121] [PMID] [PMCID]

43. Augoff K, Hryniewicz-Jankowska A, Tabola R, Stach K. MMP9: A Tough Target for Targeted Therapy for Cancer. Cancers (Basel). 2022;14(7):1847. [DOI:10.3390/cancers14071847] [PMID] [PMCID]

44. Radu P, Becchetti C, Schropp J, Schmid P, Künzler-Heule P, Mertens J, et al. Effect of Direct Acting Antiviral Drugs on the Occurrence and Recurrence of Intra- and Extra-Hepatic Malignancies in Patients with Chronic Hepatitis C Virus Infection. Cancers (Basel). 2024;16(14):2546. [DOI:10.3390/cancers16142573] [PMID] [PMCID]

45. Iqbal S, Qureshi Z, Mudasir HM, Khan A, Sohail A, Ahmad J, et al. Prevalence and Risk Factors of Hepatocellular Carcinoma in Patients Co-infected With Hepatitis B Virus (HBV) and Hepatitis C Virus (HCV): A Cross-Sectional Retrospective Study.

Cureus. 2025;17(6):e83412. [DOI:10.7759/cureus.85985]

46. Chen J, Gao G, He Y, Zhang Y, Wu H, Dai P, Zheng Q, Huang H, Weng J, Zheng Y, Huang Y. Construction and validation of a novel lysosomal signature for hepatocellular carcinoma prognosis, diagnosis, and therapeutic decision-making. Sci Rep. 2023;13(1): 22624. [DOI:10.1038/s41598-023-49985-3] [PMID] [PMCID]

47. Chen R, Cui J, Xu C, Xue T, Guo K, Gao D, et al. The significance of MMP-9 over MMP-2 in HCC invasiveness and recurrence of hepatocellular carcinoma after curative resection. Ann Surg Oncol. 2012;19 Suppl 3:375-84. [DOI:10.1245/s10434-011-1836-7] [PMID]

48. Jensen S, Aaberg Poulsen C, Christensen K, Kristensen B. Expression of the lysosomal-associated membrane protein-1 (LAMP-1) in astrocytomas. Int J Clin Exp Pathol. 2013;6(7):1294-305.

49. Sakamoto K, Ogawa K, Tamura K, Honjo M, Funamizu N, Takada Y. Prognostic Role of the Intrahepatic Lymphatic System in Liver Cancer. Cancers (Basel). 2023;15(7):2028. [DOI:10.3390/cancers15072142] [PMID] [PMCID]