Iranian Journal of Pathology | ISSN: 2345-3656

Cytopathological Findings of Axillary Lymph Nodes in Patients with Breast Cancer in Correlation with Ultrasound Findings

Zainab Kh. Almukhtar[1], Noora M. Kareem[2*], Sura Tami Abduljabbar[1], Osama A. Mohsein

1. *Pathology Department, College of Medicine, University of Baghdad, Baghdad, Iraq*
2. *Pathology and Forensic Medicine Department, Al-Nahrain College of Medicine, Al-Nahrain University, Baghdad, Iraq*
3. *Thi-Qar Health Directorate, Al-Habbobi Teaching Hospital, Thi-Qar, Iraq*

KEYWORDS

Axillary US, axillary FNAC, sensitivity of axillary US, accuracy of axillary US

Scan to discover online

Main Subjects:
Breast Pathology

Received 22 Jun 2025;
Accepted 03 Feb 2026;
Published Online 10 May 2026;

10.22034/ijp.2026.2071233.3534

ABSTRACT

Background & Objective: Another important factor in the staging and management of breast cancer is axillary lymph node metastasis. This research paper was intended to evaluate the diagnostic effectiveness of axillary ultrasound (US) and its relationship with fine-needle aspiration cytology (FNAC) as a preoperative staging method in patients with breast cancer.

Methods: We recruited 130 patients with newly diagnosed breast cancer. All patients underwent axillary US, and FNAC was performed on any suspicious lymph nodes.

Results: A correlation between axillary lymph node ultrasound characteristics and cytology was also significant in the study of 130 patients with breast cancer. Positive biopsy results were related to irregular shape, increased size, thickened cortex, hypoechoic echogenicity, and absence of an intact hilum. It was found that ultrasound had a sensitivity of 98.9%, a PPV of 72%, an NPV of 80%, and an accuracy of 72.3%, which proved its usefulness in predicting nodal malignancy.

Conclusion: Axillary US is highly sensitive in the identification of axillary lymph node involvement, and it has a close correlation with FNAC. These two techniques together can be used successfully to direct preoperative tumor staging, which may result in fewer patients undergoing unnecessary surgical procedures, such as sentinel lymph node biopsy or axillary lymph node dissection, thereby reducing morbidity.

Corresponding Information: **Noora M. Kareem**, Pathology and Forensic Medicine Department, Al-Nahrain College of Medicine, Al-Nahrain University, Baghdad, Iraq. E-mail: dr.nooramk@nahrainuniv.edu.iq

Copyright © 2026. This is an open-access article distributed under the terms of the **Creative Commons Attribution 4.0 International License (CC BY 4.0)**, which permits unrestricted use, distribution, and reproduction in any medium, provided the original work is properly cited. The license also allows users to adapt, remix, transform, and build upon the material for any purpose, including commercial use.

Introduction

Breast cancer is the most prevalent type of malignancy in women worldwide, and it remains a significant public health issue, especially in developing countries. The World Health Organization reports that breast cancer represents about 25 percent of all cancers diagnosed in women, with a large discrepancy in incidence, stage at diagnosis, and survival between high- and low-resource settings (1,2). Diagnosis of breast cancer in Iraq and in most countries in the Middle East often occurs at comparatively advanced stages compared with Western countries. Late presentation can be explained by lack of access to screening programs, cultural factors, and lack of awareness of early signs and symptoms. Consequently, accurate and cost-effective diagnostic tools for staging are essential for treatment planning and patient outcomes (3,4).

One of the most important prognostic factors in breast cancer is axillary lymph node status. Involvement of regional lymph nodes is not only important for disease staging but also for determining treatment options and prognosis (5). Axillary involvement typically signifies extracorporeal spread of tumor cells compared with the primary tumor, and its presence has a significant role in determining systemic treatment, radiation therapy, and surgical management. Therefore, accurate preoperative evaluation of axillary lymph nodes is vital for treatment decision-making and to avoid under- and overtreatment (6).

Axillary lymph node dissection (ALND) is conventionally considered the reference standard for assessing nodal involvement. However, despite providing accurate histopathological data, ALND is associated with high morbidity, including lymphedema, shoulder dysfunction, nerve damage, and long-term impairment of quality of life (7,8). To avoid these complications, sentinel lymph node biopsy (SLNB) has emerged as a less invasive alternative. Nevertheless, SLNB remains an invasive procedure that requires surgical expertise and the use of radioisotopes or dyes; therefore, in resource-limited settings such as Iraq, this technique may not always be feasible. There is thus an unmet need for noninvasive or minimally invasive diagnostic techniques that allow reliable preoperative prediction of axillary nodal involvement (9).

Axillary ultrasound (AUS) is a well-recognized imaging modality for the assessment of axillary lymph nodes. It is noninvasive, easily accessible, inexpensive, and does not involve radiation exposure. Ultrasonography can evaluate lymph node morphology in detail, including cortical thickness, hilum integrity, and nodal shape, and can help differentiate benign from suspicious nodes (10). However, ultrasound alone cannot confirm cytological or histological evidence of malignancy. Therefore, it is usually combined with FNAC of suspicious nodes. FNAC is rapid, simple, and minimally invasive, and it can establish the metastatic status of lymph nodes with high specificity (11,12).

There are several advantages to combining AUS with FNAC. Suspicious nodes identified by ultrasound and confirmed by FNAC may directly lead to axillary dissection, thereby avoiding unnecessary SLNB. This approach not only reduces the number of surgical procedures but also facilitates earlier decisions regarding adjuvant therapy. In addition, AUS combined with FNAC can reduce healthcare costs and improve diagnostic accuracy and turnaround time, which is particularly important in resource-limited settings (13).

Previous studies in European, Korean, and American populations have evaluated the use of AUS and FNAC in the diagnostic workup of axillary lymph nodes. Although reported sensitivities and specificities vary, most studies have demonstrated that the combination of these methods significantly improves preoperative diagnostic accuracy compared with ultrasound alone (14). However, studies investigating this association in Middle Eastern populations, particularly in Iraq, are limited. The scarcity of data on the use of these modalities in Iraqi patients with breast cancer necessitates further research to provide local evidence regarding their diagnostic performance (15,16).

This study was designed to assess the diagnostic value of axillary ultrasound and FNAC in the preoperative staging of patients with breast cancer in Iraq. By evaluating their accuracy, sensitivity, specificity, and predictive values, this research aims to provide insights into how these techniques can be integrated into routine clinical practice in resource-limited settings. Ultimately, it is hoped that a reliable, noninvasive, and cost-effective diagnostic approach can be developed to guide surgical management and improve outcomes in Iraqi women with breast cancer.

Materials and Methods

The study was a cross-sectional study conducted between July 2024 and July 2025 at Baghdad Teaching Hospital after approval by the institutional ethics committee at Baghdad College of Medicine. The study was performed among patients of the Breast Imaging and Oncology Units at Baghdad Teaching Hospital who were seen during the study period in order of selection. Inclusion criteria were biopsy-proven breast cancer and full ultrasound evaluation of the breast and axilla. Non-diagnostic FNAC samples, prior axillary surgery, or active infection were excluded to limit selection bias. One hundred and thirty patients with biopsy-proven breast cancer were recruited after providing written informed consent.

Age and sex of the patients, as well as tumor factors such as size, location, histological type, and grade, were collected to consider variables that could influence axillary lymph node status. Biopsy-proven breast cancer and comprehensive assessment of the breast and axilla were inclusion criteria, whereas non-diagnostic FNAC samples, previous axillary surgery, active systemic infections, and other conditions that impair lymph node evaluation were exclusion criteria to provide a homogeneous study population.

A full ultrasound of the breast and axilla was performed for all patients. All suspicious axillary lymph nodes were carefully assessed using five sonographic features: size, shape, cortical thickness, echogenicity, and hilum status (lost or displaced). Two experienced radiologists independently conducted the ultrasound examinations, and discrepancies in node evaluation were resolved through consensus review, ensuring high interobserver reliability. Axillary lymph nodes were considered suspicious when they met two or more of the following sonographic criteria: size greater than 8 mm, round shape, cortical thickness greater than 3 mm, hypoechogenicity, or hilum loss or displacement. These criteria were used to select nodes for ultrasound-guided FNAC and were based on established breast imaging guidelines.

Ultrasound equipment was regularly calibrated according to the manufacturer's recommendations, and all radiologists were trained and experienced in breast and axillary imaging to ensure quality and consistency of assessment. Suspicious nodes then underwent ultrasound-guided fine-needle aspiration cytology (FNAC) using a 22-gauge needle under local anesthesia. Negative pressure was applied with back-and-forth movements to achieve aspiration. In cases of unsatisfactory or non-diagnostic FNAC samples, the procedure was repeated using a standardized protocol: the same 22-gauge needle with ultrasound guidance, consistent back-and-forth movements during aspiration, and preparation of multiple smears for microscopic examination to ensure reproducibility.

FNAC samples were examined by two independent pathologists, and any disagreements were resolved by consensus review. Inter-rater agreement was not formally assessed (e.g., by a kappa statistic), which should be considered in future studies to quantify diagnostic consistency. Several smears were prepared and examined under the microscope by two separate pathologists using air-dried Giemsa stains and hematoxylin and eosin (H and E) stains. Unsatisfactory or non-diagnostic samples were excluded, and the FNAC procedure was repeated. Radiologists performing ultrasound assessments were blinded to FNAC results, and pathologists analyzing FNAC samples were blinded to ultrasound findings and clinical data.

Statistical analysis

SPSS (2022) was used to perform statistical analysis. Continuous variables were presented as means and standard deviations, whereas categorical variables were expressed as frequencies and percentages. Associations between categorical variables were evaluated using the chi-square test. Univariate and multivariate analyses were performed to determine odds ratios and 95% confidence intervals. A p value of 0.05 or less was considered statistically significant.

The sensitivity, specificity, positive predictive value, negative predictive value, and accuracy of axillary ultrasound were calculated to determine its diagnostic performance. To ensure accuracy, all collected data were reviewed for completeness, and cases with missing key variables were excluded from statistical analysis. No imputation was performed due to the small amount of missing data. Multicollinearity in multivariate models was assessed using the variance inflation factor (VIF), and variables with VIF values above 5 were examined or excluded to maintain the stability and reliability of the models.

Results

Sociodemographic, Clinical, and Cytological Profile of Breast Cancer Patients. The research findings indicated that the average age of patients was 57.67 ± 12.27 years, with the greatest proportion in the 51–60 age group (30.8%) and the 61–70 age group (25.4%). Most patients were women (99.2%), whereas males constituted only 0.8%. In terms of the affected breast side, 51.5% were left-sided, 42.3% were right-sided, and 6.2% were bilateral (Table 1).

In 66.9% of patients, samples were collected by means of Tru-cut biopsy, and in 33.1% by excisional biopsy. The ductal type of tumor was the most prevalent (78.5%), followed by lobular (12.3%) and in situ (9.2%). With reference to axillary lymph nodes, most (61.5%) were on the left side as opposed to the right side (38.5%).

In 89.2% of cases, the nodules were enlarged; irregular shape was observed in 70%, cortical thickening in 78.5%, and hypoechogenicity in 89.2%. In 96.2% of patients, the hilum was abnormal. These ultrasound findings included lymph nodes with indistinct margins, loss of fatty hilum, mainly peripheral vascularity, and cortical thickening (Fig. 1). Cytological examination showed positive results in 70% of cases; clusters and sheets were observed in 53.8%, and single cells in 16.2%. Positive FNAC smears demonstrated large clusters of pleomorphic cells with a high nuclear-to-cytoplasmic ratio and irregular nuclear membranes, as well as singly dispersed malignant cells with a high nuclear-to-cytoplasmic ratio (Figs. 2 and 3). The presence of normal lymphocytes was noted in 16.9%, acute inflammatory cells in 6.9%, and necrosis or granulomatous cells in 3.1%.

Table 1. Distribution of Age, Sex, Tumor Characteristics, and Axillary Lymph Node Features

Characteristic	Sub-characteristic	No.	%	95% CI (Range)
Age	Mean ± SD (years)	57.67 ± 12.27	-	
Age Groups	≤ 30 years	5	3.8	0.5–7.1
	31-40 years	5	3.8	0.5–7.1
	41-50 years	29	22.3	15.1–29.5
	51-60 years	40	30.8	22.9–38.7
	61-70 years	33	25.4	17.9–32.9
	71-80 years	18	13.8	7.9–19.7
Sex	Male	1	0.8	0.0–2.3
	Female	129	99.2	97.7–100.0
Breast Side	Right	55	42.3	33.8–50.8
	Left	67	51.5	42.9–60.1
	Bilateral	8	6.2	2.1–10.3
Procedure	Tru-cut biopsy	87	66.9	58.8–75.0
	Excisional biopsy	43	33.1	25.0–41.2
Tumor Type	Ductal	102	78.5	71.4–85.6
	Lobular	16	12.3	6.7–17.9
	In situ	12	9.2	4.2–14.2
LN Side	Right	50	38.5	30.1–46.9
	Left	80	61.5	53.1–69.9
LN Size	Normal	14	10.8	5.5–16.1
	Enlarged	116	89.2	83.9–94.5

Characteristic	Sub-characteristic	No.	%	95% CI (Range)
LN Shape	Rounded	39	30.0	22.1–37.9
	Irregular	91	70.0	62.1–77.9
Cortex	Normal	28	21.5	14.4–28.6
	Thickened	102	78.5	71.4–85.6
Echogenicity	Echogenic	14	10.8	5.5–16.1
	Hypoechoic	116	89.2	83.9–94.5
Hilum	Intact	5	3.8	0.5–7.1
	Not intact	125	96.2	92.9–99.5
Cytology	Negative	39	30.0	22.1–37.9
	Positive	91	70.0	62.1–77.9
Cytology Findings	Normal LN cells	22	16.9	10.5–23.3
	Acute inflammatory cells	9	6.9	2.5–11.3
	Necrosis	4	3.1	0.1–6.1
	Granulomatous	4	3.1	0.1–6.1
	Clusters and sheets	70	53.8	45.2–62.4
	Single dispersed cells	21	16.2	9.9–22.5

Predictive Value of Axillary Lymph Node Ultrasound Features in Breast Cancer

The results of the study revealed that ultrasound assessment of axillary lymph nodes was very important in predicting tumor development. Irregular shape of the node was most closely related to the highest positive predictive value (PPV) of 95.6%, followed by cortical thickness (84.3%) and enlarged node size (75%). Hypoechogenicity had a PPV of 74.1%, and the lowest PPV was associated with hilum non-intactness (72%). These findings indicate that irregular shape and cortical thickness are more useful predictors of tumor progression, whereas hilum status alone is less precise (Table 2).

Table 2. Sensitivity and Positive Predictive Values of Sonographic Parameters

Ultrasound features	N	TP	FP	PPV%	95% CI (Range)
Enlarged size	116	87	29	75	67.1–82.9
Irregular shape	91	87	4	95.6	91.4–99.8
Thickened cortex	102	86	16	84.3	77.2–91.4
Hypoechogenicity	116	86	30	74.1	66.1–82.1
Not intact hilum	125	90	35	72	64.1–79.9

Correlation Between Axillary Lymph Node Ultrasound and Cytology Findings

Correlation Between Axillary Lymph Node Ultrasound and Cytology Findings

The NPV of ultrasonography was 80% with a 95% CI (44.9–100) (4 true negatives and 1 false positive). The PPV was 72%, with a 95% CI (63.8–80.2), based on 90 true positives and 35 false positives. These findings show that ultrasound is a valuable modality for predicting metastatic lymph nodes and may assist preoperatively in decision-making for further biopsy and surgical intervention (Table 3).

Table 3. Diagnostic Performance of Ultrasound Compared to FNAC

	Cytology Findings			
Ultrasound Findings	Negative	Positive	Diagnostic Value	95% CI (Range)
Negative	4	1	NPV: 80%	(100-44.9)
Positive	35	90	PPV: 72%	(80.2- 63.8)

Cytological Assessment of Axillary Lymph Nodes in Breast Cancer Patients

The table results showed a statistically significant relationship between some characteristics of axillary lymph nodes on ultrasound and cytological biopsy results in patients with breast cancer. It was noted that increased node size was significantly associated with positive biopsy results (87 of 116 enlarged cases, $p = 0.001$, odds ratio 2.015). Irregular nodule shape was associated with positive results in 87 cases compared with 4 cases of round nodules ($p < 0.001$, odds ratio 5.249).

Regarding the cortex, its thickness was a strong predictor of cytological positivity (86 cases with thickening vs 5 normal cases, $p < 0.001$, odds ratio 3.208). For nodular echogenicity, hypoechoic nodes were more associated with positive results than normal echogenic nodes ($p = 0.005$, odds ratio 1.641). Finally, non-intact hilum status showed a greater association with positive biopsy results compared with intact hila ($p = 0.007$, odds ratio 2.331).

These results confirm that assessment of ultrasound characteristics can be an important indicator for identifying the presence of cancer cells in axillary lymph nodes (Table 4).

Table 4. Correlation Between Ultrasound Characteristics and Cytology Results

		Cytology		P value	Odds ratio (95% CI)
		Negative	Positive		
LN size	Normal	10 (7.7%)	4 (3.1%)	0.001	12.015 (0.782-3.248)
	Enlarged	29 (22.3%)	87 (66.9%)		
Shape	Rounded	35 (26.9%)	4 (3.1%)	0.000	15.249 (3.808-6.689)
	Irregular	4 (3.1%)	87 (66.9%)		
Cortex	Normal	23 (17.7%)	5 (3.8%)	0.000	13.208 (2.103-4.312)
	Thickened	16 (12.3%)	86 (66.2%)		
Echogenicity	Echogenic	9 (6.9%)	5 (3.8%)	0.005	11.641 (0.471-2.81)
	Hypo echoic	30 (23.1%)	86 (66.2%)		
Hilum	Intact	4 (3.1%)	1 (0.8%)	0.007	12.331 (0.105-4.557)
	Not intact	35 (26.9%)	90 (69.2%)		

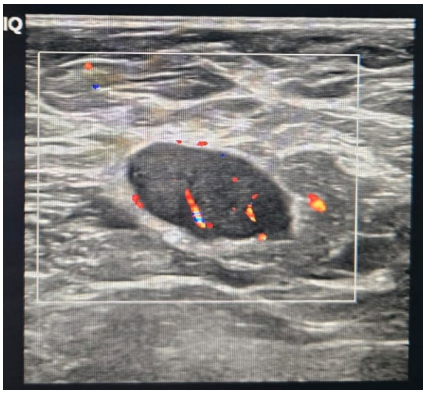

Fig. 1. lymph node with indistinct, loss fatty Hilum with mainly peripheral vascularity and cortical thickening

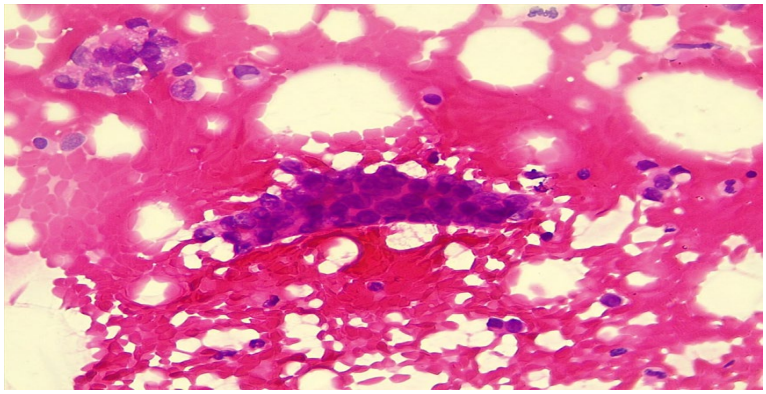

Fig. 2. FNAC of a positive axillary lymph node showing large cluster of pleomorphic cells with high N/C ratio, irregular nuclear membranes power 40x, H&E stain

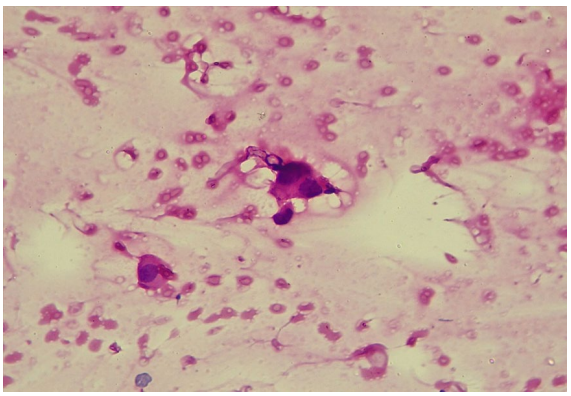

Fig. 3. FNAC of a positive axillary lymph node showing singly dispersed malignant cells with high N/C ratio, power 40x, H&E stain

Discussion

Axillary ultrasound (US) evaluation is widely recognized as the primary investigative technique in patients diagnosed with breast cancer due to its accessibility, noninvasiveness, real-time imaging capabilities, and potential to accurately guide biopsy procedures. Assessment of axillary lymph node metastasis is critical for staging, treatment planning, and prognosis in patients with breast cancer. Various sonographic features, including lymph node size, cortical thickness, hilum status, and shape, have been utilized to predict metastatic involvement (17,18). Despite its widespread use, US alone is not entirely accurate in predicting malignant lymph nodes, largely due to operator dependency, variability in equipment resolution, and interobserver differences (19). Fine-needle aspiration cytology (FNAC) is a complementary method to US and offers cytological confirmation of suspected metastasis. However, FNAC is also operator dependent, requiring both an experienced cytologist and radiologist, and its accuracy may be affected by the sampling method and quality of the aspirated specimen (20).

This research involved 130 patients with newly diagnosed breast cancer confirmed through core or excisional biopsy, and the median age of the patients was 57 years. This cohort is in line with that reported in (21), whereas another study indicated a somewhat younger majority population of 41–50 years. These differences in age distribution may reflect population-specific epidemiological trends in breast cancer incidence (22). The five sonographic parameters assessed in the current study were lymph node size, cortical thickness, echogenicity, hilum status (intact or displaced), and nodal shape. Among these, irregular lymph node shape exhibited the highest predictive value (PPV 95.6%), followed by thickened cortex (PPV 84.3%), enlarged size (PPV 75%), hypoechogenicity (PPV 74.1%), and displaced hilum (PPV 72%) (23). These results indicate that morphological irregularity and cortical changes are more sensitive indicators of metastatic involvement than hilum displacement. Differences from (24), which reported lower PPVs for shape and cortical thickness, may be explained by variations in methodology, sample size, imaging modalities, or population characteristics. Similarly, a Mexican study reported substantially lower PPVs for shape, cortical thickness, and hilum status (44%, 33.3%, and 40.5%, respectively), possibly due to differences in patient selection, radiologist experience, and imaging criteria (25,26).

Our findings are consistent with (27), which demonstrated a significant correlation between increased cortical thickness, absence of fatty hilum, and metastatic infiltration confirmed by FNAC, supporting the predictive value of these sonographic variables. Another recent study (28) also supported our findings, indicating that hypoechogenicity and abnormal lymph node shape are important predictors of axillary metastasis. Increased cortical thickness and absence of hilum are independent predictors of high-burden axillary disease, highlighting the utility of morphological evaluation in risk stratification. The biological basis for these associations is that metastatic infiltration disrupts the normal lymph node architecture, leading to cortical thickening, increased cellular density reflected as hypoechogenicity, and deformation or loss of the fatty hilum (29,30).

Regarding diagnostic performance, axillary US in our study demonstrated a sensitivity of 98.9%, specificity of 10.3%, NPV of 80%, PPV of 72%, and accuracy of 72.3%. Fidan et al. reported a sensitivity of 91%, specificity of 77%, NPV of 83%, and PPV of 87%, whereas Laiq et al. reported a sensitivity of 84.2%, specificity of 48.1%, NPV of 72.2%, and PPV of 65.5% (31). A Mexican study reported a sensitivity of 32.8%, specificity of 82.5%, NPV of 79.6%, PPV of 37.1%, and accuracy of 70.6% (32). These differences may be attributed to variations in patient demographics, inclusion criteria, sample size, and the operator-dependent nature of US. Selection criteria for lymph nodes, operator experience, and ultrasound resolution all play critical roles in determining sensitivity and specificity, emphasizing the need for standardized imaging protocols (33).

Malignant cytological aspirates were identified in 91 of 125 cases (70%) in our cohort, consistent with a 2023 study conducted in Saudi Arabia, which reported 52.8% malignant aspirates (34). The difference in proportions may be explained by variations in sample size and inclusion criteria; the Saudi study analyzed 354 axillary lymph nodes and included all suspicious breast masses, allowing for a broader estimation of diagnostic indicators. Our study focused exclusively on histologically confirmed malignant cases, a methodological approach that limited the ability to determine sensitivity and specificity of FNAC but strengthened the observed association between sonographic features and cytological malignancy (35).

Moreover, a significant correlation between sonographic parameters and FNAC outcomes was observed, consistent with (36), which performed US-guided FNAC in 25 patients and confirmed findings with histopathological analysis. In that study, absence of fatty hilum was reported in 73% and hypoechoic cortex in 74% of positive nodes, with diagnostic performance values of 50% sensitivity, 100% specificity, 100% PPV, 27.6% NPV, and 58% accuracy (37).

To our knowledge, no prior studies have comprehensively evaluated the correlation between axillary cytology and detailed ultrasound parameters, which underscores the novelty and clinical relevance of our work (38). These findings highlight the importance of morphological ultrasound assessment in identifying metastatic involvement, guiding FNAC, and improving diagnostic accuracy, which may ultimately influence treatment decisions and survival outcomes in patients

with breast cancer (39, 40). The study used FNAC as the sole cytological assessment method without comparison with alternative diagnostic techniques (e.g., core needle biopsy or sentinel lymph node biopsy), which represents a limitation. Future comparative studies are recommended to further evaluate diagnostic accuracy.

Limitations

There are a number of limitations in this study. It is a cross-sectional study and does not allow for establishing causal relationships between ultrasound characteristics of axillary lymph nodes and cytology outcomes. The sample size and duration of the study (130 patients over one year), limited to a single center, may compromise generalizability and may not reflect seasonal or operational variations. The sample was further restricted by strict inclusion criteria (biopsy-proven breast cancer and satisfactory cytology).

The study did not account for potential confounding factors, such as tumor size, grade, and prior treatments. Despite these limitations, significant correlations were observed. Future multicenter studies with larger sample sizes and longer follow-up periods are recommended to validate these findings.

Conclusion

Preoperative axillary ultrasound (US) is a highly sensitive and noninvasive method for identifying metastatic axillary lymph node involvement and plays an important role in accurate staging of patients with breast cancer. This technique shows a strong correlation with axillary lymph node cytology. The combination of these methods may help prevent unnecessary surgical procedures and reduce morbidity.

Acknowledgments

We are thankful to Dr. Imad Mahmood for his valuable efforts in statistical analysis of this study.

Authors' Contributors

None.

Data Availability

The data supporting the results of this study are available upon request from the corresponding author.

Funding

This research received no specific grant from any funding agency in the public, commercial, or not-for-profit sectors.

Ethics Approval

This study has only received an ethical approval by the Institutional Ethics Committee at Baghdad College of Medicine and all processes were carried out in accordance with the institutional regulations and Declaration of Helsinki. Mentions of ALNahrain University have been eliminated to make it factual.

Consent to Participate:

Written informed consent was obtained from all participants before enrollment in the study and before blood sample collection. Participants who were unable or unwilling to provide consent were excluded from the study. This is consistent with the Methods section, which states that eligible participants provided written informed consent and that inability or unwillingness to consent was an exclusion criterion.

Conflict of Interest

The authors declared no conflict of interest.

References

1. Cuthrell KM, Tzenios N. Breast cancer: updated and deep insights. Int Res J Oncol. 2023;6(1):104-18.
2. Smolarz B, Zadrożna Nowak A, Romanowicz H. Breast cancer-epidemiology, classification, pathogenesis and treatment (review of literature). Cancers (Basel). 2022;14(10):2569. [DOI:10.3390/cancers14102569] [PMID] [PMCID]
3. Al-Shamsi HO, Abu-Gheida IH, Iqbal F, Al-Awadhi A. Breast cancer in the Arabian Gulf countries. Cancers (Basel). 2023;15(22):5398. [DOI:10.3390/cancers15225398] [PMID] [PMCID]
4. Al Ajmi A, Aljarrah A, et al. Challenges with the management of young women's breast cancer in Gulf countries and the Middle East. J Young Womens Breast Cancer Health. 2024;1(1-2):36-41. [DOI:10.4103/YWBC.YWBC_14_24]
5. Pesapane F, Nicosia L, Rossi Mischiati C, Abbate F, Latronico A, Pellini F, et al. Future directions in the assessment of axillary lymph nodes in patients with breast cancer. Medicina (Kaunas). 2023;59(9):1544. [DOI:10.3390/medicina59091544] [PMID] [PMCID]
6. Andring LM, Sioshansi S, Al-Hilli Z, Weaver DL, Javid SH, Connolly JL, et al. Locoregional

management and prognostic factors in breast cancer with ipsilateral internal mammary and axillary lymph node involvement. Int J Radiat Oncol Biol Phys. 2022;113(3):552-60. [DOI:10.1016/j.ijrobp.2022.02.037] [PMID]

7. Cocco D, Elswick SM, Shridhar R, Arlow RL, Slingerland JM, Jabbour SK, et al. Axillary lymph node dissection can be omitted in patients with limited clinically node-positive breast cancer: a National Cancer Database analysis. Br J Surg. 2022;109(12):1293-9. [DOI:10.1093/bjs/znac305] [PMID]

8. Fan YJ, Cao L, Cui JX, Ding XY, Zhao S, Zhang GJ. Efficacy and safety comparison between axillary lymph node dissection with no axillary surgery in patients with sentinel node-positive breast cancer: a systematic review and meta-analysis. BMC Surg. 2023;23(1):209. [DOI:10.1186/s12893-023-02101-8] [PMID] [PMCID]

9. Mathelin C, Lodi M. Narrative review of sentinel lymph node biopsy in breast cancer: a technique in constant evolution with still numerous unresolved questions. Chin Clin Oncol. 2021;10(2):14. [DOI:10.21037/cco-20-207] [PMID]

10. Raymond WA, Kleinig P. The value of fine needle aspiration biopsy in the pre-operative assessment of the axilla in breast cancer patients. J Mol Pathol. 2022;3(4):228-42. [DOI:10.3390/jmp3040020]

11. Hallur N, Heera R, Kumar S, Gupta A, Khurana S, Goyal S. Evaluation of metastatic lymph nodes in oral squamous cell carcinoma: a comparative study of clinical, FNAC, ultra sonography and computed tomography with post operative histopathology. Indian J Otolaryngol Head Neck Surg. 2022;74(Suppl 3):5921-6. [DOI:10.1007/s12070-021-02495-y] [PMID] [PMCID]

12. Ren Y, Wang Z, Sun S, Zhao Q, Li Y. Ultrasonographic and cytological characterization of ultrasound-guided fine-needle aspiration cytology of cervical lymph nodes for false-negative and false-positive diagnosis. Eur Arch Otorhinolaryngol. 2023;280(5):2463-70. [DOI:10.1007/s00405-022-07802-z] [PMID]

13. Gouveia MC, et al. Accuracy of ultrasound-guided fine needle aspiration cytology (US-FNAC) to detect axillary involvement in breast cancer. Braz J Oncol. 2021;17:e-20210014. [DOI:10.5935/2526-8732.20200044]

14. Trimboli P, Castellana M, Piccardo A, Romanelli F, Giovanella L, Bongiovanni M. Thyroid nodules with indeterminate FNAC according to the Italian classification system: prevalence, rate of operation, and impact on risk of malignancy. An updated systematic review and meta-analysis. Endocr Pathol. 2022;33(4):457-71. [DOI:10.1007/s12022-022-09729-x] [PMID] [PMCID]

15. Alrawi N. A review on breast cancer in Iraq and future therapies insights. Baghdad J Biochem Appl Biol Sci. 2022;3(1):4-16. [DOI:10.47419/bjbabs.v3i01.64]

16. Hassan FM. Risk Factors Associated with Breast Cancer among Women in Iraq: A Case-Control Study. Asian Pac J Cancer Prev. 2025;26(5):1701-8. [DOI:10.31557/APJCP.2025.26.5.1701] [PMID] [PMCID]

17. Adhitama H., Dwianingsih E. Kus, Suwardjo S., Aryandono T. Association between FOXP3 Expression and Disease-Free Survival in Triple Negative Breast Cancer. Iran J Pathol, 2025; 20(4): 386-393. [DOI:10.30699/ijp.2025.2052684.3418] [PMID] [PMCID]

18. Lee YW, Chen HH, Chou MC, Yeh DC, Lee MH, Huang CW, et al. Axillary lymph node metastasis status prediction of early-stage breast cancer using convolutional neural networks. Comput Biol Med. 2021;130:104206. [DOI:10.1016/j.compbiomed.2020.104206] [PMID]

19. Faiella E, Vertulli D, Santucci D, Russillo M, Zobel BB, Quattrocchi CC. Can machine learning models detect and predict lymph node involvement in prostate cancer? A comprehensive systematic review. J Clin Med. 2023;12(22):7032. [DOI:10.3390/jcm12227032] [PMID] [PMCID]

20. Sheppard SC, Al-Nahas S, Frelinghuysen M, Van Koevering KK. Diagnostic use of fine-needle aspiration cytology and core-needle biopsy in head and neck sarcomas. Head Neck. 2021;43(6):1939-48. [DOI:10.1002/hed.26670] [PMID]

21. Carleton N. Understanding Hormone Disposition and Innate Immune Biology to Right-Size Treatment in Older Women with ER+ Breast Cancer (Doctoral dissertation, University of Pittsburgh).

22. Dalal H. Precision medicine in breast cancer: A molecular genomics and diagnostics approach. Lund University; 2024.

23. Naif NH, Ahmed EM, Thamer NA, Muhsein OA. The Impact of Inflammatory and Adipokine Biomarkers on Breast Cancer Progression and Patient Outcomes. Bull Pharm Sci Assiut Univ. 2025;48(1):511-22. [DOI:10.21608/bfsa.2025.339732.2360]

24. Fischerova D, Burgetova A, Dundr P, Nemejcova K, Cibula D, Zikan M, et al. Terms, definitions and measurements to describe sonographic features of lymph nodes: consensus opinion from the Vulvar International Tumor Analysis (VITA) group. Ultrasound Obstet Gynecol. 2021;57(6):861-79. [DOI:10.1002/uog.23617] [PMID]

25. Pham W, et al. A critical guide to the automated quantification of perivascular spaces in magnetic resonance imaging. Front Neurosci. 2022;16:1021311. [DOI:10.3389/fnins.2022.1021311] [PMID] [PMCID]

26. Ni H, et al. Accurate identification of individuals with subjective cognitive decline using 3D regional fractal dimensions on structural magnetic resonance imaging. Comput Methods Programs Biomed. 2024;254: 108281. [DOI:10.1016/j.cmpb.2024.108281] [PMID]

27. Reddy h, ullas l, kethineni m. Role of spectral doppler in evaluation of palpable breast masses in co-relation with ultrasound guided fnac. Panacea Journal of Medical Sciences учредители: ip innovative publication. 2025;11(3):527-32. [DOI:10.18231/j.pjms.2021.103]

28. Huang JX, et al. Combining conventional ultrasound and sonoelastography to predict axillary status after

neoadjuvant chemotherapy for breast cancer. Eur Radiol. 2022;32(9):5986-96. [DOI:10.1007/s00330-022-08751-1] [PMID]

29. Ahmed AW, Abdul-QaderKhuder H, Jasim SA, Mohsein OA. Hormonal profiles and metabolic changes in women diagnosed with concomitant Hashimoto's thyroiditis and polycystic ovary syndrome via sonography. European Journal of Clinical and Experimental Medicine. 2025(3):596-604. [DOI:10.15584/ejcem.2025.3.12]
30. Gillot L, et al. The pre-metastatic niche in lymph nodes: formation and characteristics. Cell Mol Life Sci. 2021;78(16):5987-6002. [DOI:10.1007/s00018-021-03873-z] [PMID] [PMCID]
31. Samiei S, et al. Diagnostic performance of noninvasive imaging for assessment of axillary response after neoadjuvant systemic therapy in clinically node-positive breast cancer: a systematic review and meta-analysis. Ann Surg. 2021;273(4):694-700. [DOI:10.1097/SLA.0000000000004356] [PMID]
32. Zheng H, et al. The accuracy of ultrasound-guided fine-needle aspiration and core needle biopsy in diagnosing axillary lymph nodes in women with breast cancer: a systematic review and meta-analysis. Front Oncol. 2023;13:1166035. [DOI:10.3389/fonc.2023.1166035] [PMID] [PMCID]
33. Shin SU, et al. The Usefulness of Ultrasound Surveillance for Axillary Recurrence in Women With Personal History of Breast Cancer. J Breast Cancer. 2021;25(1):25-36. [DOI:10.4048/jbc.2022.25.e3] [PMID] [PMCID]
34. MONDAL K., Mandal R. Oral Mucosal Melanoma and Sinonasal Amelanotic Melanoma: A Summary of Two Unusual Cases. Iran J Pathol, 2024; 19(4): 474-476. [DOI:10.30699/ijp.2024.2014328.3199] [PMID] [PMCID]
35. Chen L, et al. Ultrasound radiomics models improve preoperative diagnosis and reduce unnecessary biopsies in indeterminate thyroid nodules. Front Endocrinol (Lausanne). 2025;16:1615304. [DOI:10.3389/fendo.2025.1615304] [PMID] [PMCID]
36. Akhtar MK, Sah D, Acharya R, Jha AK, Mahato RK, Rimal B, Shah SS, Alam F, Singh AK, Hussain A. Correlation between ultrasonography and fine needle aspiration cytology (FNAC) findings in patients with thyroid lesions. Age. 2021;38(11.742):38-14.
37. Hussein MA, et al. Correlation of ultrasound features in the TIRADS scoring system with cytological findings in the FNAC of thyroid nodules and their association with the metabolic status. Egypt J Intern Med. 2024;36(1):29. [DOI:10.1186/s43162-024-00290-z]
38. Giansanti D. AI in Cytopathology: A Narrative Umbrella Review on Innovations, Challenges, and Future Directions. J Clin Med. 2024;13(22):6745. [DOI:10.3390/jcm13226745] [PMID] [PMCID]
39. Buzatto IPC, et al. Axillary ultrasound and fine-needle aspiration cytology to predict clinically relevant nodal burden in breast cancer patients. World J Surg Oncol. 2021;19(1):292. [DOI:10.1186/s12957-021-02391-3] [PMID] [PMCID]
40. Ozair A, et al. Leptomeningeal metastatic disease: new frontiers and future directions. Nat Rev Clin Oncol. 2025;22(2):134-54. [DOI:10.1038/s41571-024-00970-3] [PMID]