Iranian Journal of Pathology | ISSN: 2345-3656

Bridging Cytology and Histology: Concordance Analysis of Lymph Node Lesions within the Sydney Framework

Pinky Pandey[1], Alka Yadav[1*], Alok Dixit [2], Roopak Aggarwal[1], Asttha Kapoor[1], Neelshi Pandey[1], Parul Verma[1]

1. *Department of Pathology, Uttar Pradesh University of Medical Sciences, Saifai, India*
2. *Department of Clinical Pharmacology, Uttar Pradesh University of Medical Sciences, Saifai, India*

KEYWORDS

Lymph node; fine needle aspiration cytology; Sydney System; risk of malignancy (ROM)

Scan to discover online

Main Subjects:
Cytology

Received 27 Sep 2025;
Accepted 11 Nov 2025;
Published Online 10 May 2026;

10.22034/ijp.2026.2072878.3548

ABSTRACT

Background & Objective: Benign and malignant lymphadenopathy is a common presenting feature in a wide spectrum of diseases. Previously, there was no standard reporting system or common terminology available for lymph node cytology. A diagnostic "gray zone" exists in lymph node cytology, where accuracy declines, making it difficult to categorize certain lesions and leading to diagnostic discrepancies. The aim of the study was to assess the accuracy of fine needle aspiration of the lymph nodes and critically evaluate the cytohistological discordant cases. In the 20th International Congress of Cytology held in Sydney in 2019, a standardized category-based lymph node cytology reporting system was proposed.

Methods: This is a retrospective study conducted at the Department of Cytopathology from January 2021 to December 2025. A total of 1500 cases were re-evaluated and reviewed and were classified according to the Sydney System and compared with clinical and histopathological diagnoses. The present study aimed to analyze and classify lymph node samples as per the newly proposed Sydney System and to calculate risk of malignancy, sensitivity, specificity, positive predictive value, and negative predictive value (NPV) for all categories, considering histopathology as the reference standard. The statistical analysis was performed using SPSS version 20.

Results: Of the 1500 cases, distribution was as follows: L1, 150; L2, 1000; L3, 180; L4, 115; and L5, 55. Risk of malignancy (ROM) was 1.3% for L1, 0.7% for L2, 99.4% for L3, 99.1% for L4, and 96.36% for L5.

Conclusion: The Sydney System study helped in achieving uniformity and reproducibility of cytological diagnosis. It enhanced understanding and communication between clinicians and pathologists, thereby improving patient care.

Corresponding Information: **Alka Yadav**, Department of Pathology Uttar Pradesh University of Medical Sciences, Saifai, India. E-mail: dr.alkayadav080989@gmail.com

Copyright © 2026. This is an open-access article distributed under the terms of the **Creative Commons Attribution 4.0 International License (CC BY 4.0)**, which permits unrestricted use, distribution, and reproduction in any medium, provided the original work is properly cited. The license also allows users to adapt, remix, transform, and build upon the material for any purpose, including commercial use.

Introduction

Fine-needle aspiration cytology (FNAC) is widely used as an initial approach for investigating lymphadenopathy of uncertain cause. It is a rapid, minimally invasive, and cost-effective technique that also provides material suitable for ancillary investigations, which enhances diagnostic accuracy (1).

A reliable diagnosis of both reactive and malignant lymphadenopathies can often be achieved when FNAC findings are supplemented with ancillary tests, including flow cytometry (FC), immunocytochemistry (ICC), microbiological studies, and molecular assays (2-20). These combined methods reduce the need for unnecessary surgical biopsies. FNAC is particularly valuable in patients for whom surgery is risky or not feasible, such as elderly individuals with multiple comorbidities or those with widespread metastatic disease. Nevertheless, excisional biopsy and histopathology continue to be regarded as the reference standards for confirming malignant lymphadenopathy (21,22).

The cytological interpretation of lymph nodes can be challenging because many lesions exhibit overlapping morphological features, which may introduce subjectivity in diagnosis. Currently, lymphoma diagnosis by FNAC almost always requires histopathological confirmation. Furthermore, in the absence of a structured reporting framework, cytology of lymph nodes has not been widely adopted in routine clinical decision-making (23). To address these limitations, a category-based reporting system—known as the Sydney System—was introduced at the 20th International Congress of Cytology in 2020 (24).

Despite its promise, the Sydney System has been slow to gain widespread acceptance, and literature on its practical application remains sparse (11). The present study was undertaken in a tertiary care center in northern India, where the Sydney System was incorporated into routine diagnostic practice as a pilot project. The framework was developed to provide consensus-based terminology, enhance communication among pathologists and clinicians, and link cytological findings with suggested management strategies (25).

The classification suggested two levels of diagnostic categories, in which the first category is mandatory to categorize the lesion according to a broad diagnosis from L1 to L5, such as inadequate, benign, and malignant. The second diagnostic level aimed at identification of specific diagnostic entities by using ancillary techniques like ICC, fluorescent in situ hybridization, and cell block to obtain a more accurate diagnosis on a cytopathological basis.

The classification also recommended the format of lymph node reporting in cytopathological examination, in which basic clinical data, radiological findings, site, and basic diagnostic categories (L1-L5) are recommended. Additional data such as microscopic description, ancillary techniques, and secondary diagnosis, if any, were also suggested (26). However, the Sydney System remains underutilized, and there are limited data in the literature to date (27). Therefore, the present study was aimed at validating the diagnostic utility of the Sydney reporting system in fine needle aspiration cytology for lymph node lesions. The main objective was to calculate the risk of malignancy for all categories from L1 to L5. Unfortunately, the lack of universally accepted terminology for reporting results has hindered its widespread support. The Sydney System proposal for lymph node cytopathology categorization and reporting introduced five diagnostic categories to address the lack of universally accepted terminology for reporting results in lymphadenopathy.

Materials and Methods

This retrospective observational study was carried out based on archived cytology and histopathology records, and wherever possible, additional clinical and radiological information of benign and malignant nodes (Fig. 1) was retrieved from hospital records to supplement the requisition form data, with efforts made to standardize case review and data extraction to minimize confounding factors. It was conducted in the Department of Pathology, Uttar Pradesh University of Medical Sciences, Saifai, from January 2022 to May 2025. The study utilized de-identified archival slides and records without any direct patient contact or intervention. Institutional Ethics Committee approval was obtained with a waiver of informed consent, in accordance with the ICMR National Ethical Guidelines for Biomedical Research Involving Human Participants (2017). This complies with standard practice for retrospective cytology audits.

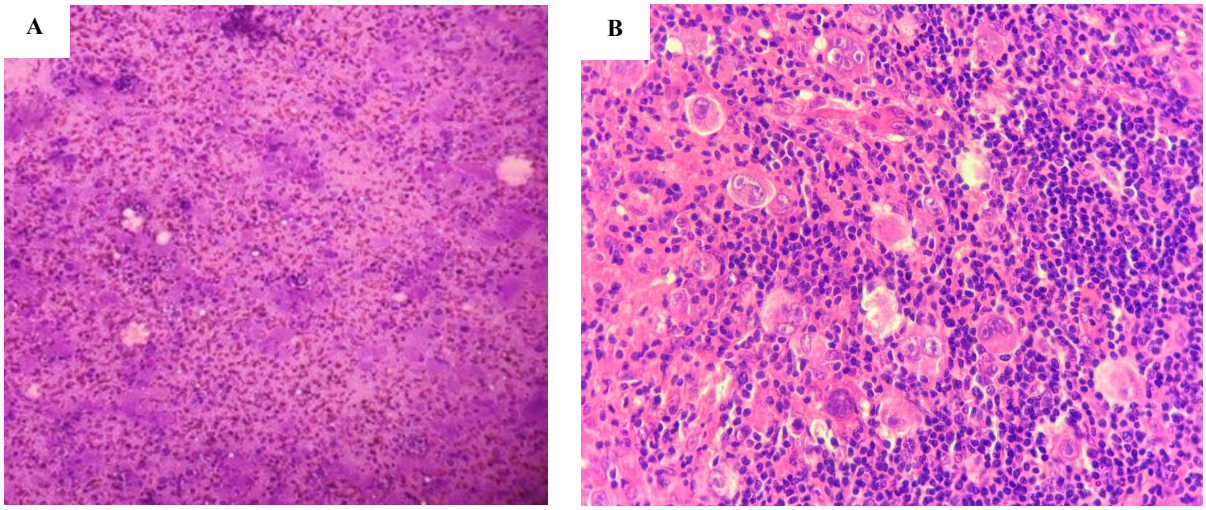

Fig. 1. A) Category L1 (Non-diagnostic/Insufficient) a, Smear showing necrotic background with a few macrophages and scant lymphocyte (MGG, 10X). **B)** Biopsy section from similar case shows metastatic breast with comedo necrosis (H&E).

Inclusion criteria and Exclusion criteria:

All consecutive lymph node aspirates from patients were included. Both sexes and all age groups were included in the study. Non–lymph node aspirates were excluded from the study.

A total of 1500 lymph node FNAC cases performed over the past three years were reviewed. To minimize observer bias during smear re-examination and Sydney System categorization, all cases were independently reviewed by two experienced cytopathologists who were blinded to the original diagnosis and histopathological outcome at the time of review. In

instances of disagreement, a consensus diagnosis was reached through joint discussion. While interobserver variability was not statistically quantified, this dual-review approach helped reduce subjective bias. In the present study, cases with incomplete cytological details, inadequate smears, or missing essential clinical information were excluded from the final analysis. Specifically, cases for which histopathological follow-up data were not available were analyzed separately for cytological distribution but were excluded from the risk of malignancy (ROM) and diagnostic accuracy calculations. This approach ensured that only histologically verified cases contributed to the statistical validation of the Sydney System categories.

Superficial and palpable lymph node FNAs were performed blindly, while image-guided FNAs (mostly ultrasonography-guided) were carried out for deep-seated, nonpalpable, or suspicious malignant nodes. Procedures were performed using a 23-gauge needle under aseptic conditions. The cytological smears in our study were prepared and stained following institutional standard operating procedures. Air-dried smears were stained with May–Grünwald–Giemsa (MGG), and alcohol-fixed smears were stained with the Papanicolaou stain, as per routine protocol. Periodic internal quality control checks were performed by the cytology laboratory as part of accreditation requirements.

For each case, at least two air-dried and three alcohol-fixed smears were prepared. Air-dried smears were stained with May–Grünwald–Giemsa (MGG), while alcohol-fixed smears were stained with Papanicolaou and hematoxylin-eosin (H&E). In suspected cases of tuberculosis, additional smears were stained using the Ziehl–Neelsen method. Cell blocks and immunohistochemistry (IHC) were performed in selected cases, particularly for subtyping lymphomas on histopathological specimens.

The smears were reported and classified into 5 different diagnostic categories based on the proposed Sydney System of Reporting. The first diagnostic level included cases from L1 to L5 (Table 1):

- L1: Inadequate/Nondiagnostic
- L2: Benign
- L3: Atypical cells of undetermined significance/atypical lymphoid cells of uncertain significance (AUS/ALUS)
- L4: Suspicious
- L5: Malignant

Table 1. Correlation of Sydney System Categories with Final Diagnosis Based on Histopathology and Clinical Follow-up

Category (Sydney System)	Cytological Diagnosis	Histopathology (n)	Discordant Cases (n)	Risk of Malignancy (%)
L1 – Inadequate/Non-diagnostic (n=150)	Blood only (n=112); Necrosis (n=38)	40	2	1.3
L2 – Benign (n=1000)	Tubercular lymphadenitis (n=500); Granulomatous lymphadenitis (n=400); Non-specific lymphadenitis (n=70); Reactive lymphadenitis (n=30)	844	10	0.7
L3 – AUS/ALUS (n=180)	Atypical lymphoid population (n=78); Atypical non-lymphoid population (n=102)	98	35	99.4
L4 – Suspicious (n=115)	Non-Hodgkin lymphoma (n=60); Hodgkin lymphoma (n=8); Metastatic lesions (n=47)	44	7	99.1
L5 – Malignant (n=55)	Non-Hodgkin lymphoma (n=15); Lymphoproliferative disorders (n=22); Metastatic – Breast (n=10), Seminoma (n=1), Ovary (n=2), Lung (n=5)	34	12	96.36
Total	**1500**	**1060**	**66**	—

Histopathology and Follow-Up

Diagnostic accuracy was assessed by correlating FNAC findings with histopathology wherever tissue was available. For cases without biopsy, clinical follow-up records were reviewed. Of the total 1500 FNAC cases, histopathological confirmation was available for 1060.

Ancillary Techniques

Cell block preparation and immunohistochemistry (IHC) were performed in cases in which cytomorphology was inconclusive or required further characterization, such as atypical lymphoid lesions, metastatic malignancies of unknown primary, or poorly differentiated neoplasms. The decision was based on cytological findings and the availability of residual material in the needle rinse. Appropriate IHC markers were applied on cell blocks to aid in lineage determination and diagnostic categorization as per the Sydney System.

Risk of malignancy (ROM) for each Sydney System category was calculated by dividing the number of confirmed malignant cases by the total number of cases with histological or clinical follow-up in that category (Table 1).

Sample Size Calculation

The sample size was calculated to estimate the sensitivity of the Sydney System to detect malignancy. Assuming an expected sensitivity of 0.85, a desired precision of ±5% for the 95% confidence interval, and an expected disease prevalence of 40% among cases with histopathological follow-up, 196 histopathology-positive cases were required.

$$n = Z^2 \times Se\,(1 - Se) / d^2$$

This gives the number of true-disease cases (histopathology positive) needed to estimate sensitivity with precision.

$$n = 1.96^2 \times 0.85 \times 0.15 / 0.05^2 \approx 196$$

Convert to total sample size using disease prevalence P:

$$N = n / P$$

$$N = 196 / 0.40 \approx 490$$

This corresponds to a total of approximately 490 cases (196/0.40). We therefore included all eligible cases available during the study period (N = 1500), which meets the calculated requirement.

Statistical Analysis

Statistical analysis was performed using SPSS version 25.0 (IBM Corp., Armonk, NY, USA). The chi-square test was applied to evaluate the association between Sydney System categories and corresponding histopathological outcomes. Risk of malignancy (ROM) for each category was calculated along with 95% confidence intervals (CIs) using the binomial proportion method. A p value < 0.05 was considered statistically significant.

Results

T A total of 1500 fine-needle aspiration (FNA) smears of lymph nodes were reviewed during the study period. Of these, 80% (n = 1200) were percutaneous aspirations, while 20% (n = 300) were image-guided procedures. The patients' ages ranged from 5 months to 70 years, with a mean age of 30 years. There was a female predominance, with 930 cases (62%) compared to 570 males (38%), yielding a female-to-male ratio of 2:1. The distribution of histopathological outcomes across Sydney system categories showed a statistically significant association ($\chi^2 = 1550.3$, df = 4, $p < 0.001$). The risk of malignancy (ROM) increased progressively from L1 to L5, ranging from 0.7% in L2 (95% CI: 0.2–1.2%) to 99.4% in L3 (95% CI: 97.1–100%).

Cervical lymph nodes were the most frequently aspirated site, accounting for 70% (n = 1050) of cases, followed by inguinal lymph nodes in 25% (n = 375). Axillary (n = 10; 0.7%) and submandibular lymph nodes (n = 10; 0.7%) were less commonly involved.

Non-diagnostic/inconclusive cases (L1) represented 10% (n = 150) of all aspirates. Among these, 112 cases (75%) showed only blood with no cellular elements, while 38 cases (25%) contained only necrotic material (Fig. 2).

Benign diagnoses (L2) (Figures 3, 4) constituted the largest group, seen in 66.6% (n = 1000) of cases. Within this category, tuberculous lymphadenitis was the most frequent finding (n = 500; 50%), followed by nonspecific lymphadenitis (n = 70; 7%), reactive lymphadenitis (n = 30; 3%), necrotizing lymphadenitis (n = 40; 4%), and acute suppurative lymphadenitis (n = 30; 3%). Tuberculosis was the predominant granulomatous lesion, characterized by epithelioid cell granulomas, Langhans giant cells, and necrosis, with Acid-Fast Bacilli positivity confirming the diagnosis in several cases.

Atypia of undetermined significance (AUS) (L3) included 12% (n=180) cases with atypical lymphocytic population and atypical non lymphocytic population (Fig. 5).

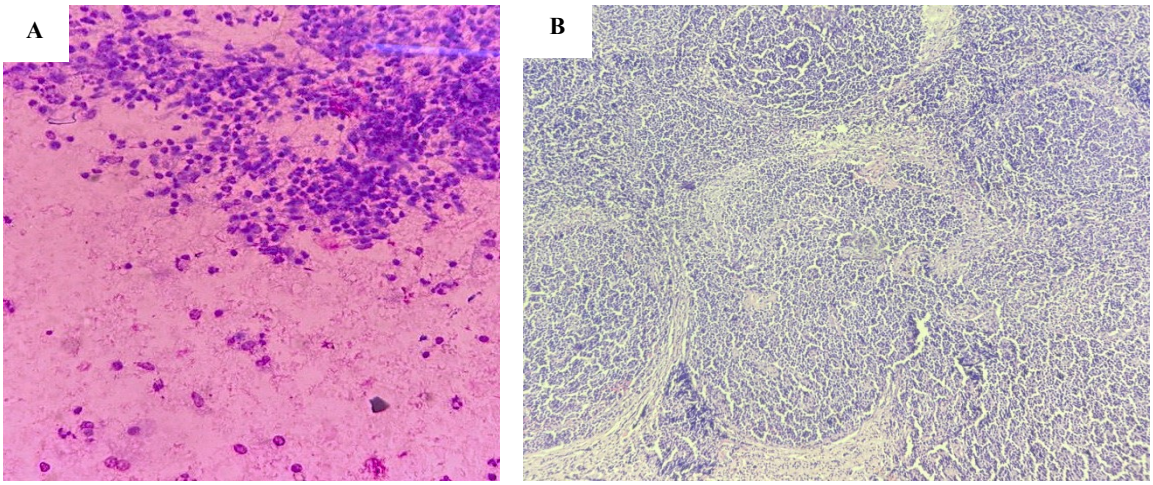

Fig. 2. A) Reactive lymphnode (Supraclavicular region) Smear showing heterogenous population of lymphoid cells in logical proportions with predominantly small lymphocytes. Categorized under Category L2: Benign. (MGG, 40X). **B)** Section from the lymph node shows features of follicular hyperplasia (H&E, 10X).

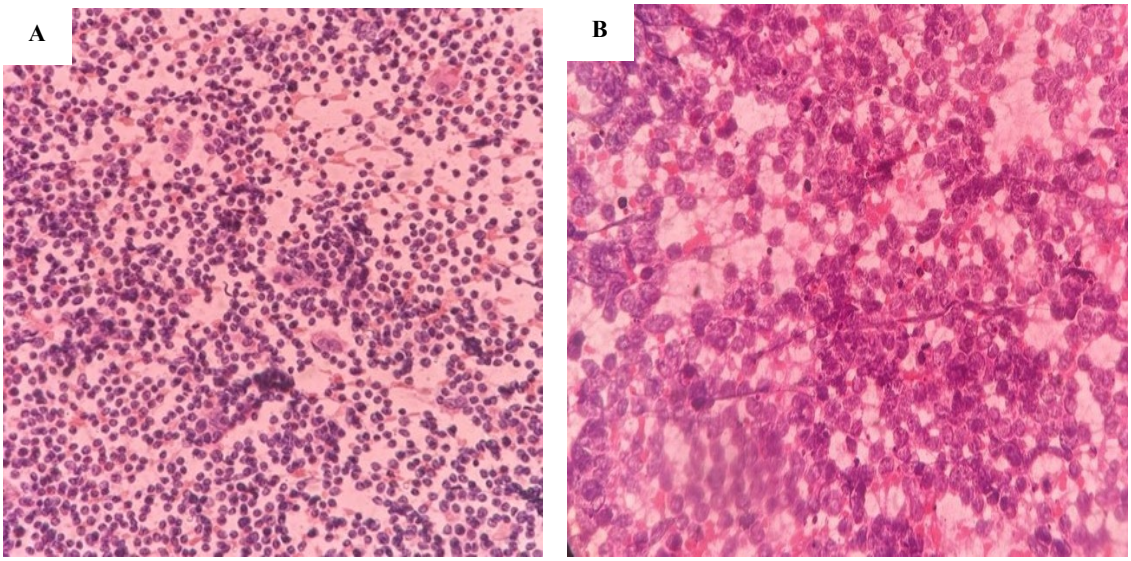

Fig. 3. A) Smear showing heterogenous population of lymphoid cells in logical proportions with predominantly small lymphocytes. Categorized under Category L2: Benign. (MGG, 10X). **B)** Section from the lymph node shows features of NHL (H&E, 10X).

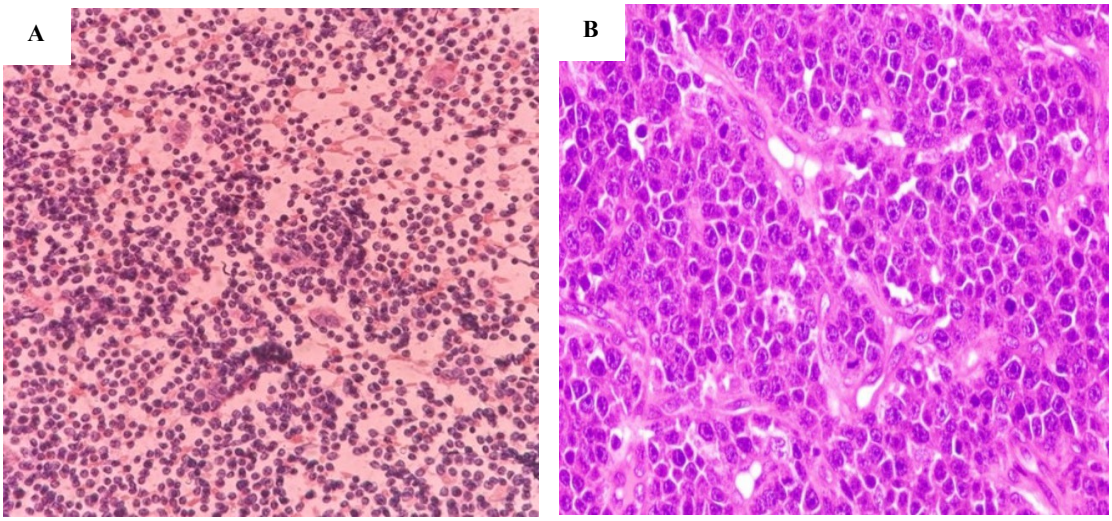

Fig. 4. Category L3. **A)** Smear showing very few Atypical cells (R-S cells) with a few macrophages and lymphocytes again Atypical cells of undetermined significance/atypical lymphoid cells of uncertain significance (AUS/ALUS)-: (MGG, 10X). **B)** Biopsy section from similar case shows Non Hodgkin Lymphoma. (H&E)

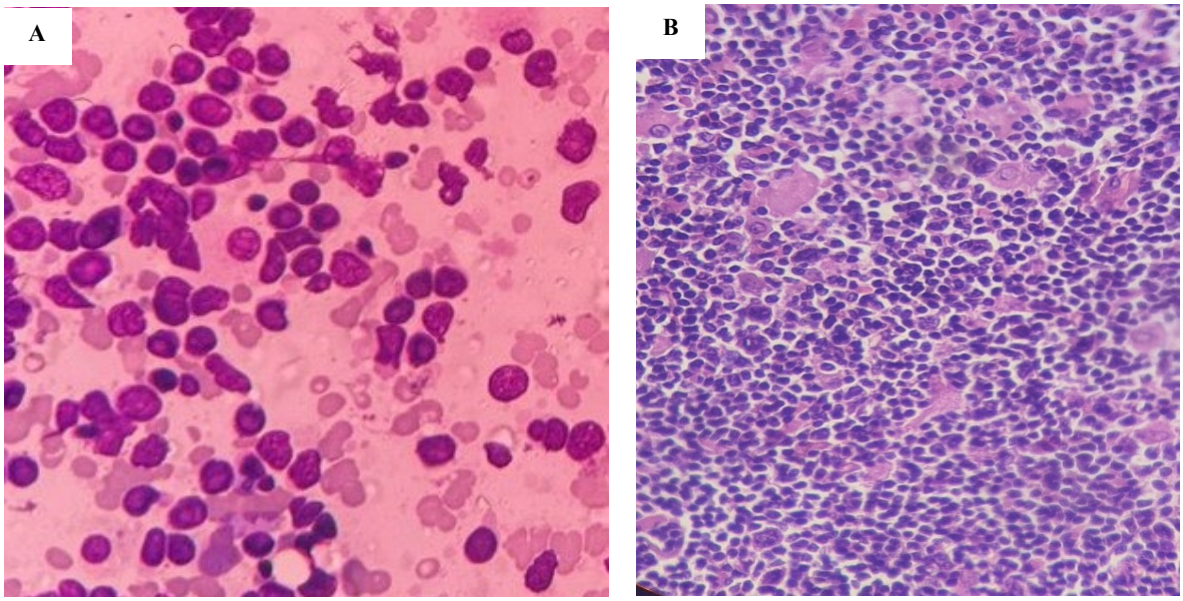

Fig. 5. Category L4 (Suspicious of malignancy)

A) Smear showing many Atypical lymphocytes against hemorrhagic Categorized under (MGG, 40X). **B)** Biopsy section from similar case show hodgkins lymphoma. (H&E)

Suspicious of malignancy-category L4 cytological diagnosis were rendered in 8% (n=115) cases including lymphomas in 68 (59.13%) cases and metastatic lesions in 47 (40.8%) cases.

Malignant lesions (L5) were seen in 55 cases (Figures 6, 7). Amongst these 15(27.2%) cases were reported as non-Hodgkin's lymphoma,25 (45.4%) case as lymphoproliferative disorder.27% (n=15) cases as metastatic lesions. Among metastatic lesions, 66.6% (n=10) cases were of metastatic squamous cell carcinoma from the oral cavity, and 33.3% (n=05) cases were of metastatic carcinoma from breast, ovary and lung, colon (Figures 8, 9).

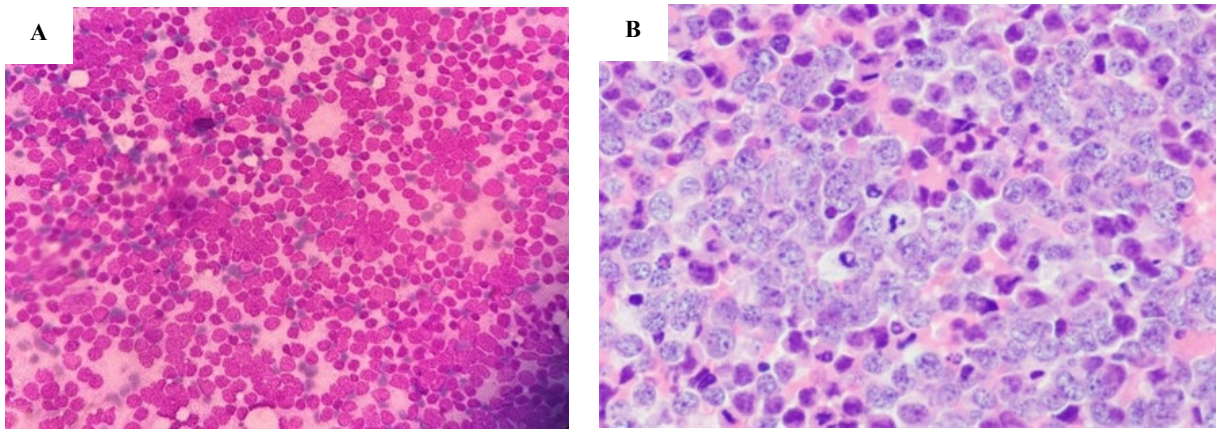

Fig. 6. A) Smear showing monotonus population of atypical lymphocytes and brisk mitoses against Categorized under Category L5 malignancy (MGG, 40X). **B)** Biopsy section from similar case shows DLBCL (Diffuse large B cell Lymphoma) (H&E,40X)

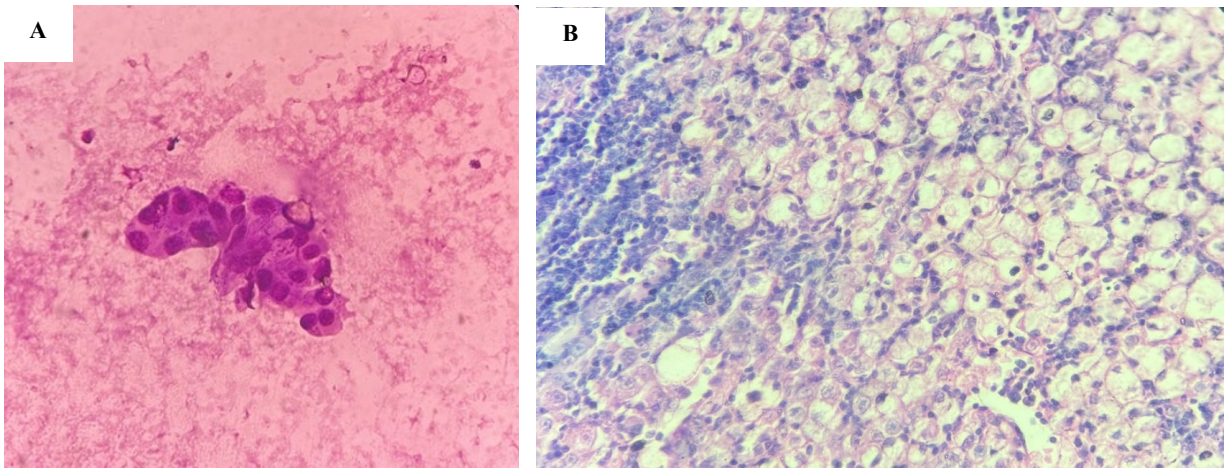

Fig. 7. Metastasis **A)** Smear showing hyperchromatic cells in lymph nodes and against scant lymphocytes background Categorized under Category L5 malignancy (MGG, 40X). **B)** Biopsy section from similar case showing signet ring cells in lymphnodes suggesting metastasis (H&E)

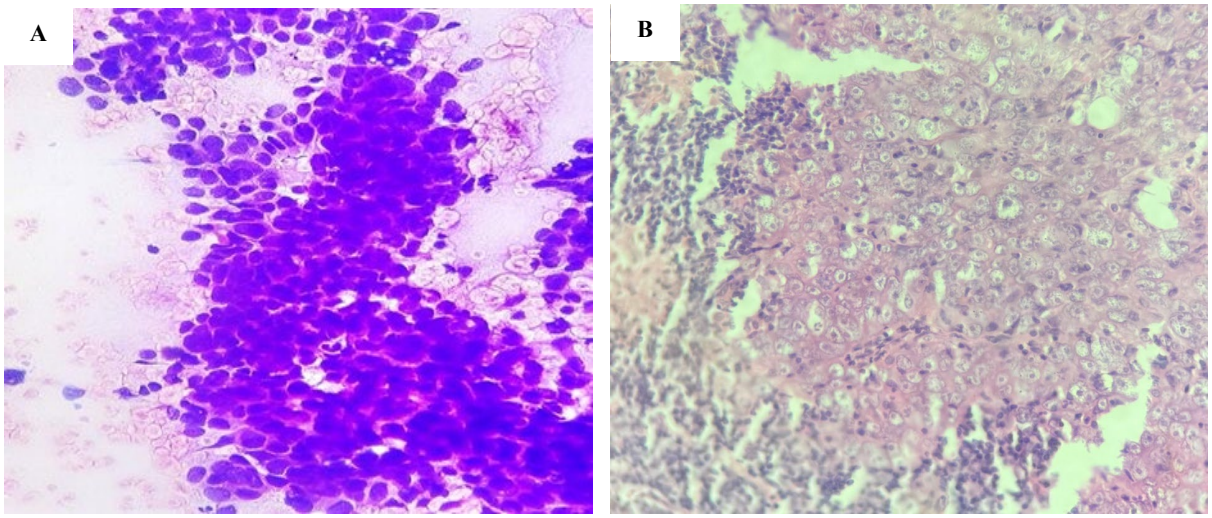

Fig. 8. Metastatic Adenocarcinoma **A)** Smear showing hyperchromatic cells in lymph nodes and brisk mitoses against Categorized under Category L5 malignancy (MGG, 40X). **B)** Biopsy section from similar case showing Metastatic adenocarcinoma in lymph nodes (H&E)

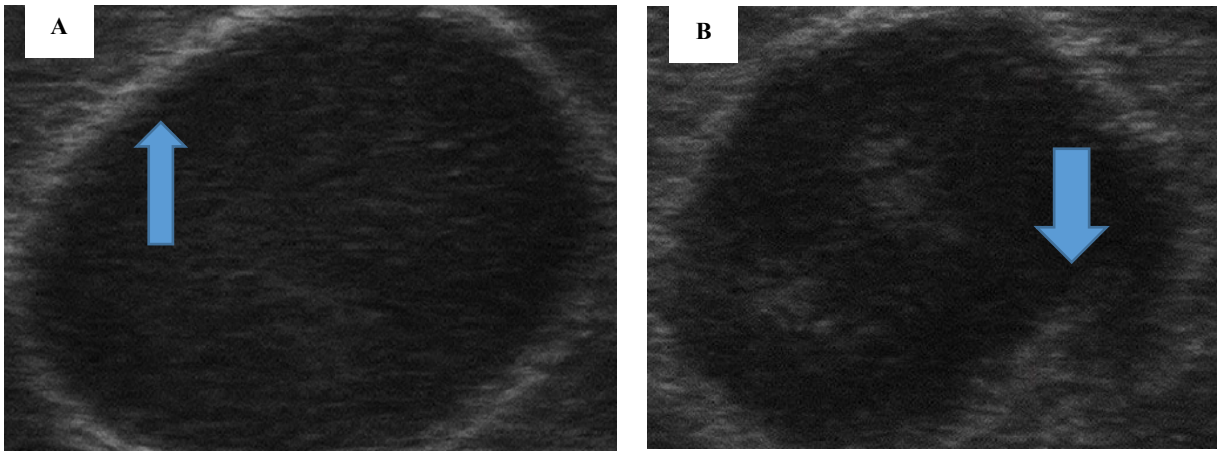

Fig. 9 A) Ultrasound image of a benign lymph node showing an oval shape, well-defined margins (Blue arrow), homogenous hypoechoic cortex, and preserved echogenic hilum. **B)** Ultrasound image of a malignant lymph node showing a round shape, loss of echogenic hilum (Blue arrow) and markedly hypoechoic appearance.

Histopathological follow-up (Table 1, Fig. 1) was available for 70% (n = 1060) of the cases, which included both benign and malignant lesions for concordance and discordance (Table 2, Fig. 10). Among these, 844 cases belonged to category L2, 98 cases to L3, 42 cases to L4, and 34 cases to L5. In the non-diagnostic group (L1), histopathological correlation was available in 40 cases. Of these, only two showed discrepancies with the initial cytological impression.

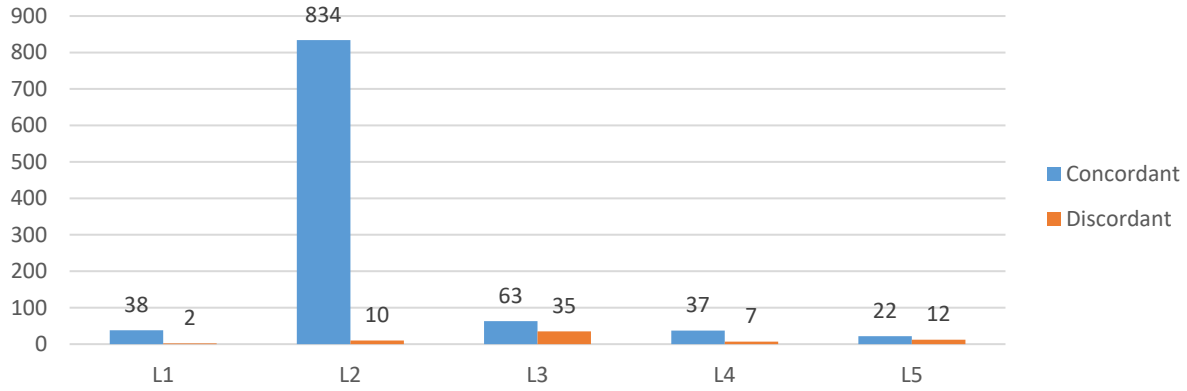

Fig. 10. Cyto-Histological Concordance and Discordance across Sydney System Categories

Table 2. Discordant Lymph Node FNAC Cases with Corresponding Histopathology and Reasons for Discrepancy"

Category	Discordant Cases (n)	Cytology Diagnosis	Histopathology Diagnosis	Reasons for Discrepancy
L1 (n=150)	2	a. Proteinaceous background (1 case) b. Reactive lymphadenitis (1 case)	a. Metastatic thyroid carcinoma with cystic change b. Tuberculous lymphadenitis	- scant cellularity - proteinaceous/colloid-like fluid - Occasional ill-formed granulomas Sampling error (aspirating from a non-caseating area) were missed
L2 (n=1000)	10	a. Reactive lymphadenitis (6 cases) b. Tubercular lymphadenitis (2 cases) c. Infectious mononucleosis (2 cases)	a. Infectious mononucleosis (1 case) b. Hodgkin's lymphoma (3 cases) c. Non-Hodgkin's lymphoma – Angioimmunoblastic T-cell lymphoma (1 case) d. Follicular lymphoma (1 case) a. SCC metastasis (2case) a. Hodgkin's lymphoma (1 case) b. Reactive lymphadenitis (1 case)	- Large immunoblasts were missed on smears - Lymphocyte predominant Hodgkin's cases appeared as small lymphocytes - Interfollicular expansion caused large cells with irregular nuclei to mimic atypia - Necrosis obscured malignant deposits - R-S cells or mononuclear R-S cells were missed
L3 (n=180)	35	a.Atypical lymphocytes (26 cases) b. Atypical non-lymphocytic cells (9 cases)	a. Lymphoproliferative disorders (25 cases) b. Rosai-Dorfman disease (1 case) c. Squamous cell carcinoma (7 cases) d. Neuroendocrine carcinoma (2 cases)	- Very few cells present and overlooked - Large histiocytes and emperipolesis ignored - Predominant necrosis obscured diagnostic cells
L4 (n=115)	7	a. Non-Hodgkin lymphomas (6 cases) b. Metastasis (1 case)	a. CLL (4 cases) b. Follicular lymphoma (1 case) c. Follicular hyperplasia (1 case) d. Squamous cell carcinoma (1 case)	- Sampling from germinal centers led to atypical cytology - Limited representation of malignant cells in smear
L5 (n=55)	12	a. Poorly differentiated carcinoma (8 cases)	a. Metastatic carcinoma – breast, ovary, lung, colon (1 case each) b. Non-Hodgkin's lymphoma (1 case) c. Reactive (2 cases)	- Morphology on cytology smears difficult to interpret - Sampling from germinal centers resulted in predominance of medium-large cells and paucity of small lymphocytes

In category L2, comparison with histopathology revealed 10 discordant cases. Five cases that were cytologically diagnosed as tuberculous lymphadenitis were subsequently identified as lymphoma on histopathology, two as Hodgkin's lymphoma and three as non-Hodgkin's lymphoma.

For L3 cases, 35 showed discrepancies when compared with histopathology. Of these, 15 were definitively diagnosed as Hodgkin's lymphoma and 20 were confirmed as reactive hyperplasia with infectious mononucleosis.

In the suspicious category (L4), 7 cases were discordant with histopathology, while in the malignant category (L5), 12 cases did not correlate with the final histopathological diagnosis (Fig. 11).

The ROC curve (Fig. 12) demonstrated excellent diagnostic performance of cytology reported under the Sydney System when compared with histopathology. The curve showed a steep ascent towards the upper left corner, indicating high sensitivity and specificity. The area under the ROC curve (AUC) approached 1.0, signifying near-perfect discrimination between benign and malignant categories.

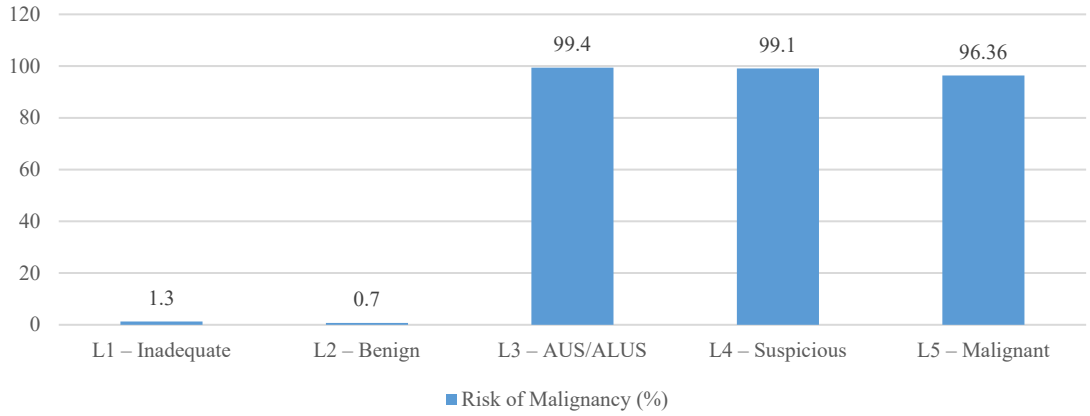

Fig. 11. Risk of Malignancy (ROM) across Sydney System Categories

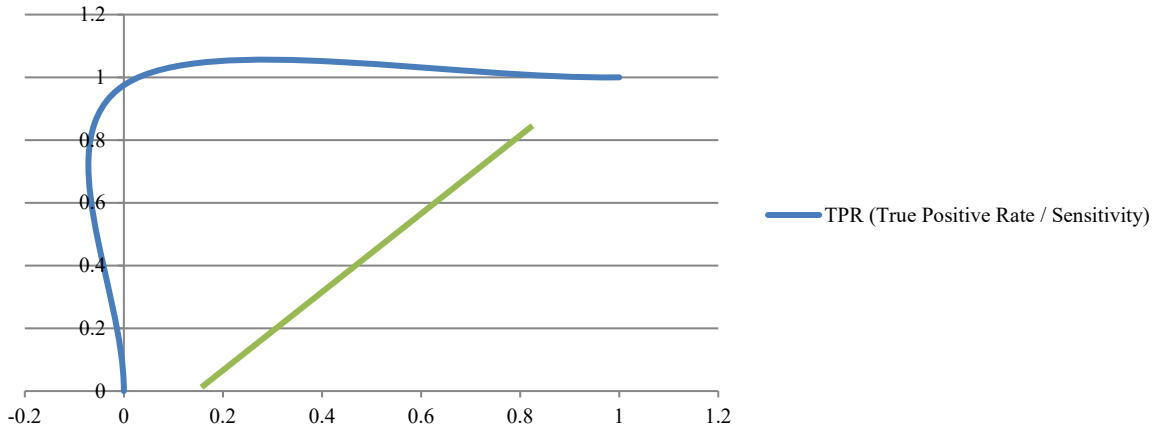

Fig. 12. Receiver operating curve for Sydney system

Discussion

It has been observed that the application of standardized reporting systems in cytopathology reduces intraobserver variability in reporting and helps in the communication of clinically relevant information in a reproducible manner (27-29). Moreover, it enhances the interpretation of cytopathological reports by clinicians with regard to risk assessment.

The proposed system for reporting LN-FNAC cytopathology had the following seven aims:

1. Develop consensus guidelines and a framework of reference to facilitate communication among cytopathologists, hematopathologists, clinicians, surgeons, and other health care providers.
2. Define and identify LN-FNAC indications, preferred operators, recommended performance, analytical and preanalytical issues, technical and diagnostic limitations, as well as the basic diagnostic reporting categories and additional diagnostic information that can produce specific disease subtyping when possible.

3. Obtain the key diagnostic cytopathological features of lesions that occur commonly in the various categories.
4. Make recommendations on the components of standardized diagnostic reports with the aim to improve reporting and communication between cytopathologists and clinicians.
5. Provide management recommendations linked to the reporting categories with possible options that include the use of clinical and imaging follow-up, ancillary testing, and the possible need for LN excision.
6. Encourage cytohistopathological correlations, cell storage, and research on neoplastic and non-neoplastic LN specimens.
7. Increase LN-FNAC reliability and clinician awareness of its diagnostic potential.

In the present study, the risk of malignancy was calculated for every diagnostic category in the Sydney System of classification and reporting of lymph node cytopathology. It was found that the risk of malignancy was 1.3% for the nondiagnostic category. This is lower when compared to 27.5% found by Gupta et al (26), much less than the 50% found by Vigliar et al (1), and 66.7% found by Caputo et al (25). Repeat FNAs using ultrasound guidance and utilization of ROSE explain the lower rate of false-negative results in this category in our study. However, the high risk of malignancy found in this category by Vigliar et al (1) was explained by them to be owing to the lower number of cases having histopathological follow-up data under this category.

Within expectations, the benign category (L2) had the lowest ROM of 0.7%. This is lower when compared to that found by Vigliar et al (13) (1.92%), Gupta et al (11) (11.5%), and Caputo et al (30) (9.38%). Out of the 8 malignant cases classified in this category, 1 was metastatic carcinoma in lymph nodes. This was a similar problem to that encountered by Vigliar et al (13) and Garg et al (31) in their study, where lymph nodes with partial involvement by metastatic carcinoma did not yield representative malignant cells on cytology (13,22). There were 5 cases diagnosed as lymphocyte-predominant type of Hodgkin lymphoma. It has been found to be extremely difficult by FNAC, and similar sampling errors in cases of FNAC of Hodgkin lymphoma have been seen in other studies (28,31-32).

The L3, or atypia of undetermined significance category, was introduced in most reporting systems with the aim of maintaining high negative and positive predictive values in the benign and malignant categories, respectively. The risk of malignancy calculated for the L3 category in this study was intermediate (99.4%). This was quite lower when compared with 58.3% and 66.7% in the studies conducted by Vigliar et al (1) and Gupta et al (26), respectively, but higher than that calculated by Caputo et al (30) (28.6%). Other studies also encountered similar pitfalls in cytology smears of reactive lymph nodes due to viral etiology and interfollicular expansion (20,21).

Each of the L4 (suspicious for malignancy) and L5 (malignant) categories in this study had a very high ROM of 99.1% and 96.36%, respectively. The ROM calculated for these categories by Gupta et al (26) was 88% and 99.6%, respectively. Vigliar et al (1) calculated it to be 100% for both categories, which was owing to the extensive use of ancillary procedures and flow cytometry in their studies. The number of false-negative results may be further diminished by use of the second diagnostic level based on ancillary techniques, as suggested in the proposal for the classification system (4). The benign case categorized under the L4 category in this study was a case of parafollicular hyperplasia containing large immunoblast-like cells and histiocytes along with numerous tingible body macrophages, which revealed Reed-Sternberg–like binucleate cells in the cytopathology smear. Immunoblasts mimicking Reed-Sternberg cells on cytology are a commonly encountered phenomenon (34).

The benign case categorized under the L5 category in this study revealed reactive hyperplasia with a predominance of centroblast-like cells in the smear. It was seen in this study that the maximum number of cases were categorized under the malignant category (64.09%), and only two cases were categorized under the malignant category. This was similar to the studies conducted by Vigliar et al (1) and Gupta et al (26), which had a greater number of cases categorized under the malignant category. However, this is owing to the pattern of cases commonly encountered in the health care setup, being located in a region where there is a high predominance of tuberculosis, and benign lymphadenopathies are routinely sent for FNA.

The kappa coefficient of 0.98 demonstrates an almost perfect agreement between cytological and histopathological diagnoses according to the Sydney System. This high level of concordance highlights the reliability and reproducibility of lymph node FNAC when reported using this standardized framework. It also indicates that the system minimizes interobserver variability and strengthens diagnostic confidence for both benign and malignant categories. The sensitivity, specificity, NPV, PPV, and accuracy were also found to be comparable with other studies (Table 3).

Table 3. Sensitivity, Specificity, PPV, NPV, Accuracy calculated for the Sydney system of lymph node cytology classification and reporting in this study.

Statistic	Value
Sensitivity	97.7%
Specificity	99.7%
Positive Predictive Value	98.3%
Negative Predictive Value	99.5%

Limitations of the Study

Interobserver variability: In our study, cytological review and categorization according to the Sydney System were independently performed by two experienced cytopathologists. Discordant cases were jointly reviewed to reach a consensus. Although interobserver variability was not statistically quantified, we acknowledge this as a limitation and plan to include formal kappa analysis in future prospective studies.

Being retrospective in design, it was not possible to control for all potential confounding variables, such as variability in clinical history documentation, sample adequacy, and differences in follow-up data availability. Nevertheless, uniform diagnostic criteria based on the Sydney System were applied, and re-evaluation of all available slides was performed to ensure consistency and reduce observer bias.

As this was a retrospective study based on archived cytology cases, there is a possibility of selection bias, as only cases with complete records and available slides were included. Nevertheless, uniform inclusion criteria were followed, and a broad range of diagnostic categories were represented, providing a realistic overview of the application of the Sydney System in routine cytology practice.

Histopathological correlation could be established in 1060 out of 1500 cases, as tissue diagnosis was available only for cases that proceeded to biopsy or excision. This partial correlation limits complete validation of the Sydney System categories. Nonetheless, the cases with available follow-up were representative of the diagnostic spectrum, allowing reliable evaluation of system performance.

Conclusion

The implementation of the Sydney System for lymph node cytology provides a standardized and structured framework that improves diagnostic accuracy and reproducibility. In our study of 1500 cases, categorization using the Sydney System allowed for clearer communication between pathologists and clinicians and facilitated accurate assessment of the risk of malignancy across all categories. The system proved especially useful in reducing interpretative variability in challenging cases, including atypical and suspicious lesions. Adoption of this standardized reporting approach enhances patient management by enabling informed clinical decisions and demonstrates its practical utility in routine cytopathology practice.

Acknowledgments

None

Authors' Contributors

Alka Yadav, Concept, design, literature search; Pinki Pandey, Manuscript editing and review, Concept, design, literature search; Alok Dixt, Data acquisition, data analysis; Asttha Kapoor, Literature search.

Data Availability

The data supporting the results of this study are available upon request from the corresponding author.

Funding

This work was supported by Research Project No. 4011927 as a residency thesis, financed by Mashhad University of Medical Sciences.

Ethics Approval

This study protocol was reviewed and approved by Institutional Ethics Committee, IEC(H) Ref No.159/cert/IEC/UPUMS/2023-24

Consent to participate:

The study, being a retrospective study collected all patient related data from the hospital medical records only. The study involves no more than minimal risk to the study subjects.Therefore, the institutional ethics committee, upums, has granted an exemption from requiring written informed consent for the study.

Conflict of Interest

The authors declared no conflict of interest.

References

1. Vigliar E, Acanfora G, Iaccarino A, Mascolo M, Russo D, Scalia G, et al. A novel approach to classification and reporting of lymph node fine-needle cytology: application of the proposed Sydney system. Diagnostics (Basel). 2021;11(8):1314. [DOI:10.3390/diagnostics11081314] [PMID] [PMCID]
2. Mathiot C, Decaudin D, Klijanienko J, Couturier J, Salomon A, Dumont J, et al. Fine-needle aspiration cytology combined with flow cytometry immunophenotyping is a rapid and accurate approach for the evaluation of suspicious superficial lymphoid lesions. Diagn Cytopathol. 2006;34(7):472-8. [DOI:10.1002/dc.20487] [PMID]
3. Dey P. Role of ancillary techniques in diagnosing and subclassifying non-Hodgkin's lymphomas on fine needle aspiration cytology. Cytopathology. 2006;17(5): 275-87. [DOI:10.1111/j.1365-2303.2006.00331.x] [PMID]
4. Jin M, Wakely PE. Lymph node cytopathology: essential ancillary studies as applied to lymphoproliferative neoplasms. Cancer Cytopathol. 2018;126(8):615-26. [DOI:10.1002/cncy.22013] [PMID]
5. Scott GD, Lau HD, Kurzer JH, Kong CS, Gratzinger DA. Flow immunophenotyping of benign lymph nodes sampled by FNA: representative with diagnostic pitfalls. Cancer Cytopathol. 2018;126(10):797-808. [DOI:10.1002/cncy.22038] [PMID] [PMCID]
6. Cozzolino I, Giudice V, Mignogna C, Selleri C, Caputo A, Zeppa P. Lymph node fine-needle cytology in the era of personalised medicine. Is there a role? Cytopathology. 2019;30(4):348-62. [DOI:10.1111/cyt.12708] [PMID]
7. Vigliar E, Pepe F, Migliatico I, Nacchio M, Cesaro S, Della Pepa R, et al. Microfluidic chip technology applied to fine-needle aspiration cytology samples for IGH clonality assessment. Diagn Cytopathol. 2019;47(8):749-57. [DOI:10.1002/dc.24184] [PMID]
8. Labarca G, Sierra-Ruiz M, Kheir F, Folch E, Majid A, Mehta HJ, et al. Diagnostic accuracy of endobronchial ultrasound transbronchial needle aspiration in lymphoma: a systematic review and meta-analysis. Ann Am Thorac Soc. 2019;16(11):1432-9. [DOI:10.1513/AnnalsATS.201902-175OC] [PMID]
9. Ronchi A, Caputo A, Pagliuca F, Montella M, Marino FZ, Zeppa P, et al. Lymph node fine needle aspiration cytology (FNAC) in paediatric patients: why not? Diagnostic accuracy of FNAC in a series of heterogeneous paediatric lymphadenopathies. Pathol Res Pract. 2021;217:153289. [DOI:10.1016/j.prp.2020.153294] [PMID]
10. Shyu S, Rajgariah A, Saoud C, Rogers N, Ali SZ. Image-guided lymph node fine-needle aspiration: The Johns Hopkins Hospital experience. J Am Soc Cytopathol. 2021;10(6):566-73. [DOI:10.1016/j.jasc.2021.04.004] [PMID]
11. Huang CG, Li MZ, Wang SH, Tang XQ, Haybaeck J, Yang ZH. The application of fine needle aspiration biopsy in the diagnosis of axillary masses. Acta Cytol. 2021;65(5):415-22. [DOI:10.1159/000513149] [PMID]
12. Hedenström P, Chatzikyriakos V, Shams R, Lewerin C, Sadik R. High sensitivity of EUS-FNA and EUS-FNB in lymphadenopathy caused by metastatic disease: a prospective comparative study. Clin Endosc. 2022;55(2):236-44.
13. Zeppa P, Vigliar E, Cozzolino I, Troncone G, Picardi M, De Renzo A, et al. Fine needle aspiration cytology and flow cytometry immunophenotyping of non-Hodgkin lymphoma: can we do better? Cytopathology. 2010;21(5):300-10. [DOI:10.1111/j.1365-2303.2009.00725.x] [PMID]
14. Zhang S, Yu X, Zheng Y, Yang Y, Xie J, Zhou X. Value of fine needle aspiration cell blocks in the diagnosis and classification of lymphoma. Int J Clin Exp Pathol. 2014;7(11):7717-25.
15. Boyd JD, Smith GD, Hong H, Mageau R, Juskevicius R. Fine-needle aspiration is superior to needle core biopsy as a sample acquisition method for flow cytometric analysis in suspected hematologic neoplasms. Cytometry B Clin Cytom. 2015;88(1):64-8. [DOI:10.1002/cytob.21183]
16. Roepman P, Boots CM, Scheidel KC, Sprong T, De Bruin P, De Weerdt O, et al. Molecular clonality assessment shows high performance to predict malignant B-cell non-Hodgkin's lymphoma using cytological smears. J Clin Pathol. 2016;69(12):1109-15. [DOI:10.1136/jclinpath-2016-203757] [PMID]
17. Peluso AL, Cozzolino I, Bottiglieri A, Lucchese L, Di Crescenzo RM, Langella M, et al. Immunoglobulin heavy and light chains and T-cell receptor beta and gamma chains PCR assessment on cytological samples. A study comparing FTA cards and cryopreserved lymph node fine-needle cytology. Cytopathology. 2017;28(1):15-27. [DOI:10.1111/cyt.12402] [PMID]
18. Peluso AL, Ieni A, Mignogna C, Zeppa P. Lymph node fine-needle cytology: beyond flow cytometry. Acta Cytol. 2016;60(4):372-84. [DOI:10.1159/000447734] [PMID]
19. Cozzolino I, Rocco M, Villani G, Picardi M. Lymph node fine-needle cytology of non-Hodgkin lymphoma: diagnosis and classification by flow cytometry. Acta Cytol. 2016;60(4):302-14. [DOI:10.1159/000448389] [PMID]
20. McCroskey Z, Khoury JD, Stewart JM, Caraway NP. Sensitivity of fine-needle aspiration biopsy for diagnosing and grading follicular lymphomas using a multiparameter approach in a cancer center. J Am Soc Cytopathol. 2017;6(2):80-8. [DOI:10.1016/j.jasc.2016.12.001] [PMID]
21. Frederiksen JK, Sharma M, Casulo C, Burack WR. Systematic review of the effectiveness of fine-needle aspiration and/or core needle biopsy for subclassifying lymphoma. Arch Pathol Lab Med. 2015;139(2):245-51. [DOI:10.5858/arpa.2013-0674-RA] [PMID]
22. Kroft SH, Sever CE, Bagg A, Billman B, Diefenbach C, Dorfman DM, et al. Guideline from the American Society for Clinical Pathology and the College of

American Pathologists. Am J Clin Pathol. 2021; 155(1):12-37. [DOI:10.1093/ajcp/aqaa191] [PMID]

23. Katz RL. Modern approach to lymphoma diagnosis by fine-needle aspiration: restoring respect to a valuable procedure. Cancer. 2005;105(6):429-31. [DOI:10.1002/cncr.21499] [PMID]

24. Al-Abbadi MA, Barroca H, Bode-Lesniewska B, Calaminici M, Caraway NP, Chhieng DF, et al. A proposal for the performance, classification, and reporting of lymph node fine-needle aspiration cytopathology: the Sydney system. Acta Cytol. 2020;64(4):306-22. [DOI:10.1159/000506497] [PMID]

25. Zeppa P. Haematocytopathology: why? Cytopathology. 2012;23(2):73-5. [DOI:10.1111/j.1365-2303.2012.00972.x] [PMID]

26. Gupta P, Gupta N, Kumar P, Bhardwaj S, Srinivasan R, Dey P, et al. Assessment of risk of malignancy by application of the proposed Sydney system for classification and reporting lymph node cytopathology. Cancer Cytopathol. 2021;129(9):701-18. [DOI:10.1002/cncy.22432] [PMID]

27. Hehn S, Grogan T, Miller T. Utility of fine-needle aspiration as a diagnostic technique in lymphoma. J Clin Oncol. 2004;22(15):3046-52. [DOI:10.1200/JCO.2004.02.104] [PMID]

28. Hehn S, Grogan T, Miller T. Utility of fine-needle aspiration as a diagnostic technique in lymphoma. J Clin Oncol. 2004;22(15):3046-52. [DOI:10.1200/JCO.2004.02.104] [PMID]

29. Sundling K, Kurtycz D. Standardized terminology systems in cytopathology. Diagn Cytopathol. 2019;47(1):53-63. [DOI:10.1002/dc.24103] [PMID]

30. Caputo A, Zanelli M, Martino G, Zizzo M, Bisagni A, Sanguedolce F, et al. Real-world experience with the Sydney system on 1458 cases of lymph node fine-needle aspiration cytology. Cancer Cytopathol. 2022; 130(2): 111-22. [DOI:10.1111/cyt.13079] [PMID]

31. Garg S, Rohilla M, Srinivasan R, Bal A, Das A, Dey P, et al. Fine-needle aspiration diagnosis of lymphoma based on cytomorphology alone: how accurate is it? - A cyto-histopathology correlative study. J Cytol. 2021;38(4):164-70. [DOI:10.4103/JOC.JOC_217_20] [PMID] [PMCID]

32. Sandhaus L. Fine-needle aspiration cytology in the diagnosis of lymphoma. Am J Clin Pathol. 2000;113(5):623-7. [DOI:10.1309/BEBH-BLA2-J5AY-YE2L] [PMID]

33. Rajalakshmi T, Rashmi Kumari T. Fine needle aspiration cytology in the diagnosis of Hodgkin lymphoma: hits and misses. J Cytol. 2008;25(1):10-2. [DOI:10.4103/0970-9371.40651]

34. Malakar D, Swarup K. A clinical evaluation of fine needle aspiration of cytology in the diagnosis of lymphadenopathy. Ind J Tuberc. 1991;38(1):8-17.