Iranian Journal of Pathology | ISSN: 2345-3656

Hepatic perivascular epithelioid cell tumor (PEComa): Clinicopathological Findings and Prognosis-A Systematic Review and Meta-Analysis

Alireza Abdollahi[1], **Masoomeh Safaei**[2]

1. *Department of Pathology, Tehran University of Medical Sciences, Tehran, Iran*
2. *Department of Pathology, Cancer Institute, Imam Khomeini Hospital Complex, Tehran University of Medical Sciences, Tehran, Iran*

KEYWORDS

Hepatic PEComa, perivascular epithelioid cell tumor, angiomyolipoma, immunohistochemistry, malignancy

Scan to discover online

Main Subjects:
GI, Liver & Pancreas Pathology

Received 02 Jun 2025;
Accepted 25 Feb 2026;
Published Online 10 May 2026;

10.22034/ijp.2026.2062240.3468

ABSTRACT

Background & Objective: Hepatic Perivascular epithelioid cell tumors (PEComas) are rare and can complicate diagnosis due to their low incidence, possible malignant potential and misdiagnosis as melanoma and hepatocellular carcinoma (HCC). The purpose of this systematic review and meta-analysis was to investigate the clinicopathological traits, diagnostic indicators, and prognostic implications associated with hepatic PEComas.

Methods: We conducted a systematic literature search in PubMed, Web of Science, and Scopus using relevant keywords. Studies were included if they assessed clinicopathological findings or prognostic outcomes of hepatic PEComas. Data extraction was performed using a standardized sheet and data were pooled using RStudio.

Results: The initial search retrieved 1,172 articles, from which 286 duplicates were removed. Ultimately, 15 studies met our eligibility criteria for inclusion in the meta-analysis. The mean patient age was 45.42 years. Misdiagnosis as HCC occurred in 18% of cases. The pooled malignancy rate was 8.6% with 6% of cases demonstrating tumor progression. Immunohistochemistry analysis revealed HMB-45 positivity in 98.8% (95% CI: 97% - 100%) and Smooth Muscle Actin positivity in 95.2% (95% CI: 81% - 98%) of cases. The mean tumor size was 67.1 mm (95% CI: 52.86 - 81.34), with 4.7% (95% CI: 3% - 8%) showing invasive features.

Conclusion: Hepatic PEComas are predominantly benign but can pose diagnostic challenges due to their resemblance to HCC and melanoma. Despite generally favorable outcomes, long-term follow-up is crucial due to the risk of recurrence. Further prospective studies utilizing standardized diagnostic criteria are warranted to refine management strategies and identify prognostic indicators.

Corresponding Information: **Masoomeh Safaei**, Department of pathology, Cancer institute, Imam Khomeini Hospital Complex, Tehran University of Medical Sciences, Tehran, IR Iran Email: Safaeima3@gmail.com

Copyright © 2026. This is an open-access article distributed under the terms of the **Creative Commons Attribution 4.0 International License (CC BY 4.0)**, which permits unrestricted use, distribution, and reproduction in any medium, provided the original work is properly cited. The license also allows users to adapt, remix, transform, and build upon the material for any purpose, including commercial use.

Introduction

Perivascular epithelioid cell tumors (PEComas) are rare mesenchymal neoplasms characterized by distinct perivascular epithelioid cells (1). These tumors can occur in various anatomical sites. When they arise in the liver, they are referred to as hepatic PEComas. Due to their rarity, the clinicopathological characteristics and prognosis of hepatic PEComas are poorly understood (2).

PEComas encompass a diverse group of tumors, most prominently including angiomyolipoma (AML) and lymphangioleiomyomatosis (LAM). AMLs are benign tumors composed of a heterogeneous collection of aberrant blood vessels, smooth muscle, and fat cells (3). While AMLs arise predominantly in the kidneys, they can also occur in other organs. LAM is a progressive pulmonary disease characterized by the proliferation of smooth muscle-like cells, leading to cystic lung destruction (4). Both AML and LAM share a common origin with PEComas, arising from perivascular epithelioid cells and often exhibiting mutations in either the *TSC1* or *TSC2* genes, which are associated with the mTOR signaling pathway (5).

Hepatic PEComas are usually asymptomatic and may be incidentally detected during imaging studies conducted for unrelated reasons (6). When symptoms do manifest, they are usually nonspecific, such as abdominal pain or discomfort (7). Histologically, these tumors consist of epithelioid cells with clear to granular cytoplasm arranged in a perivascular distribution (8). Immunohistochemically, hepatic PEComas frequently express melanocytic markers such as HMB-45 (Human Melanoma Black), Melan-A (Melanocyte Antigen), and smooth muscle markers such as actin (SMA) (9).

The relationship between hepatic PEComas, AML, and LAM is understood by their shared origin from perivascular epithelioid cells and common genetic mutations. This connection suggests that insights gained from studying AML and LAM may enhance the understanding of hepatic PEComas. However, while most hepatic PEComas are benign, certain cases have exhibited malignant characteristics, including aggressive local recurrence and distant metastasis. Therefore, accurate diagnosis and appropriate management are crucial (8, 10, 11). The criteria for the diagnosis of malignant PEComas are based on the presence of at least two of the following histologic features; 1) tumor size > 5 cm, 2) high nuclear grade, 3) hypercellularity, 4) mitotic rate > 1/50 HPF, 5) necrosis, 6) infiltration into surrounding normal parenchyma, or 7) vascular invasion (10).

In this systematic review and meta-analysis, we aimed to critically analyze the clinicopathological features and prognostic significane of hepatic PEComas. By reviewing existing literature, we seek to identify key determinants of patient outcomes and provide evidence-based recommendations for the diagnosis and management of this rare tumor.

Materials and Methods

This systematic review and meta-analysis study was conducted based on the Preferred Reporting Items for Systematic reviews and Meta-Analyses (PRISMA) guideline 2020 (12).

Search strategy

Two authors performed a systematic search of literature in the following electronic databases: PubMed, Web of Science, and Scopus. No time limitation was applied and all English studies from inception until December 2024 were included. The relevant medical subject heading (MeSH) terms and related keywords were used in combination to build the search strategy:

"Perivascular Epithelioid Cell Neoplasms" OR "PEComa" OR "Perivascular Epithelioid Cell Tumors" OR "Perivascular Epithelioid Cell Neoplasm" OR " Perivascular Epithelioid Cell Tumor" OR "PEComas" OR "Clear-Cell Sugar Tumors" OR "Clear Cell Sugar Tumor" OR "Clear-Cell Myomelanocytic Tumors" OR "Clear Cell Myomelanocytic Tumors" OR "CCMMT" OR "Clear-Cell Myomelanocytic Tumor" OR "Clear Cell Myomelanocytic Tumor") AND ("hepatic" OR "hepatics" OR "liver" OR "livers").

Eligibility criteria

Our eligibility criteria were defined based on the PICO framework (population, Intervention, Comparison, Outcome):

(P) Population: patients with perivascular epithelioid cell tumor.

(I) Intervention: Not Applicable.

(C) Comparison: Clinical outcomes based on diagnostic evaluations (e.g., histopathological and immunohistochemical studies) and treatment strategies (e.g., surgical vs. non-surgical management).

(O) Outcome: Treatment response, recurrence rates, malignancy rates and prognostic factors.

Studies that did not include control groups, studies with unavailable full text or required data; and studies not published in English were also excluded.

Data extraction and outcome measures

A standardized Excel sheet was prepared to extract relevant data including study characteristics such as the first author's name, year of publication, study design, country, total number of cases, gender distribution, mean age, and reference of comparison. Two independent authors conducted the data extraction. Disagreements regarding inclusion, exclusion, or data extraction were resolved by a third author.

Data synthesis and Statistical Analysis

Statistical analyses and figure generation were performed using RStudio (RStudio, Inc., Boston, MA, USA) with R software, and pooled proportions and means were estimated using the meta package (13). Proportions were pooled using the logit transformation method, while means were pooled using a random-effects model to account for variability among studies. The 95% confidence interval for proportions was also calculated using the logit transformation. The overall significance of the random-effects model was tested using a z-test. To assess heterogeneity among the included studies, I^2 and Tau^2 tests were used. Forest plots were created to display individual study estimates and pooled results graphically. Publication bias was assessed graphically using funnel plots and statistically using both Begg's and Egger's tests.

Risk of bias was assessed using the Joanna Briggs Institute (JBI) critical appraisal tools. The JBI checklist for case reports was used for single-patient studies, the JBI checklist for case series for studies reporting multiple patients, and the JBI checklist for analytical cross-sectional studies for retrospective and single-center observational studies. Given the rarity of the disease, risk of bias was summarized as overall methodological quality in Table 1.

Overall, the included studies demonstrated a moderate risk of bias. This was mainly attributable to the predominance of case reports, case series, and retrospective study designs. Common limitations included incomplete follow-up data, unclear patient selection methods, and limited control of confounding factors.

Due to the limited number of included studies and incomplete reporting of effect estimates, calculation of pooled p-values was not feasible. Therefore, the meta-analysis results should be interpreted as exploratory rather than confirmatory.

Table 1. Quality assessment of the included studies based on study type using the related JBI checklists

Case reports

Author(Date)	Were patint's demographic characteristics clearly described?	Was the patients' history clearly described and presented as a time line?	Was rge current clinical condition of the patient on presentation clearly described?	Were diagnostic tests or assessment methods and the results clearly described?	Was the intervention(s) or treatment procedure(s) clearly described?	Was the post-intervention clinical condition clearly described?	Were adverse events (harms) or unanticipated events identified and described?	Does the case report provide takeaway lessons?	Overall score	Overall quality
Dalle et al. (2000)	Yes	Yes	Yes	Yes	Yes	Yes	Yes	Yes	8	High
Parfitt et al. (2006)	Yes	Yes	Yes	Yes	Yes	Yes	Yes	Yes	8	High
Nguyen et al. (2008)	Yes	Yes	Yes	Yes	Yes	Yes	No	Yes	7	High
Deng et al. (2008)	Yes	Yes	Yes	Yes	Yes	Yes	Yes	Yes	8	High
Selvaggi et al. (2011)	Yes	Yes	Yes	Yes	Yes	Yes	No	Yes	7	High
Bing et al. (2012)	Yes	Yes	Yes	Yes	Yes	Yes	No	Yes	7	High
Wang et al. (2015)	Yes	Yes	Yes	Yes	Yes	Yes	No	Yes	7	High
Abhirup et al. (2015)	Yes	Yes	Yes	Yes	Yes	Yes	No	Yes	7	High
Fukuda et al. (2016)	Yes	Yes	Yes	Yes	Yes	Yes	No	Yes	7	High
Li et al. (2022)	Yes	Yes	Yes	Yes	No	No	No	Yes	5	Moderate
Tababi et al. (2024)	Yes	Yes	Yes	Yes	Yes	Yes	No	Yes	7	High
Althunibat et al. (2024)	Yes	Yes	Yes	Yes	Yes	Yes	No	Yes	7	High
Li et al. (2024)	Yes	Yes	Yes	Yes	No	No	No	Yes	5	Moderate
Tan et al. (2024)	Yes	Yes	Yes	Yes	Yes	Yes	Yes	Yes	8	High

Case series

Author/Date	Hao et al. (2016)	Yan et al. (2018)	Flemming et al. (2000)	Vijayanirmala et al. (2024)	Yan et al. (2024)	Yang et al. (2007)
Were there clear criteria for inclusion in the case series?	yes	yes	yes	yes	yes	yes
Was the condition measured in a standard, reliable way for all participants included in the case series?	yes	yes	yes	yes	yes	yes
Were valid methods used for identification of the condition for all participants included in the case series?	yes	yes	yes	yes	yes	yes
Did the case series have consecutive inclusion of participants?	no	yes	no	no	no	no
Did the case series have consecutive inclusion of participants?	no	yes	no	no	no	no
Was there clear reporting of the demographics of the participants?	yes	yes	yes	yes	yes	yes
Was there clear reporting of clinical information of the participants?	yes	yes	yes	yes	yes	yes
Were the outcomes of follow up results of cases clearly reported?	yes	yes	yes	yes	yes	yes
Was there clear reporting site(s) demographic information?	yes	yes	yes	yes	yes	yes
Was statistical analysis appropriate?	Not applicable	Not applicable	Not applicable	Not applicable	Not applicable	Not applicable
Overall score	7	9	7	7	7	7
Overall quality	Moderate	High	Moderate	Moderate	Moderate	Moderate

Author/Date	Shi et al. (2013)	Hu et al. (2012)	Ding et al. (2011)
Were there clear criteria for inclusion in the case series?	yes	yes	yes
Was the condition measured in a standard, reliable way for all participants included in the case series?	yes	yes	yes
Were valid methods used for identification of the condition for all participants included in the case series?	yes	yes	yes
Did the case series have consecutive inclusion of participants?	no	no	no
Did the case series have consecutive inclusion of participants?	no	no	no
Was there clear reporting of the demographics of the participants?	yes	yes	yes
Was there clear reporting of clinical information of the participants?	yes	yes	yes
Were the outcomes of follow up results of cases clearly reported?	yes	yes	yes
Was there clear reporting site(s) demographic information?	yes	yes	yes
Was statistical analysis appropriate?	Not applicable	yes	Not applicable
Overall score	7	8	7
Overall quality	Moderate	High	Moderate

Cross-sectional studies

Author/Date	Sal et al. (2024)	Jiang et al. (2024)	Yoo et al. (2024)	Xu et al. (2009)	Jia et al. (2022)	Ji et al. (2024)
Were the criteria for inclusion in the sample clearly defined?	yes	yes	yes	yes	yes	yes
Were the study subjects and the setting described in detail?	yes	yes	yes	yes	yes	yes
Was the exposure measured in a valid and reliable way?	yes	yes	yes	yes	yes	yes
Were objective, standard criteria used for measurement of the condition?	yes	yes	yes	yes	yes	yes
Were confounding factors identified?	no	no	no	no	no	no
Were strategies to deal with confounding factors stated?	no	no	no	no	no	no
Were the outcomes measured in a valid and reliable way?	yes	yes	yes	yes	yes	yes
Was appropriate statistical analysis used?	no	no	no	yes	yes	yes
Overall score	5	5	5	6	6	6
Overall quality	Moderate	Moderate	Moderate	Moderate	Moderate	Moderate

Results

Our initial search retrieved 1,172 articles from PubMed, Scopus, and Web of Science, from which 289 duplicates were removed. After screening the title and abstract of 883 records were excluded leaving 37 full texts for review. Finally, 34 studies were included based on the eligibility criteria (14-47), among which 15 were included in our meta-analysis (Fig. 1). More detail regarding the study characteristics of the reviewed studies is summarized in Table 2.

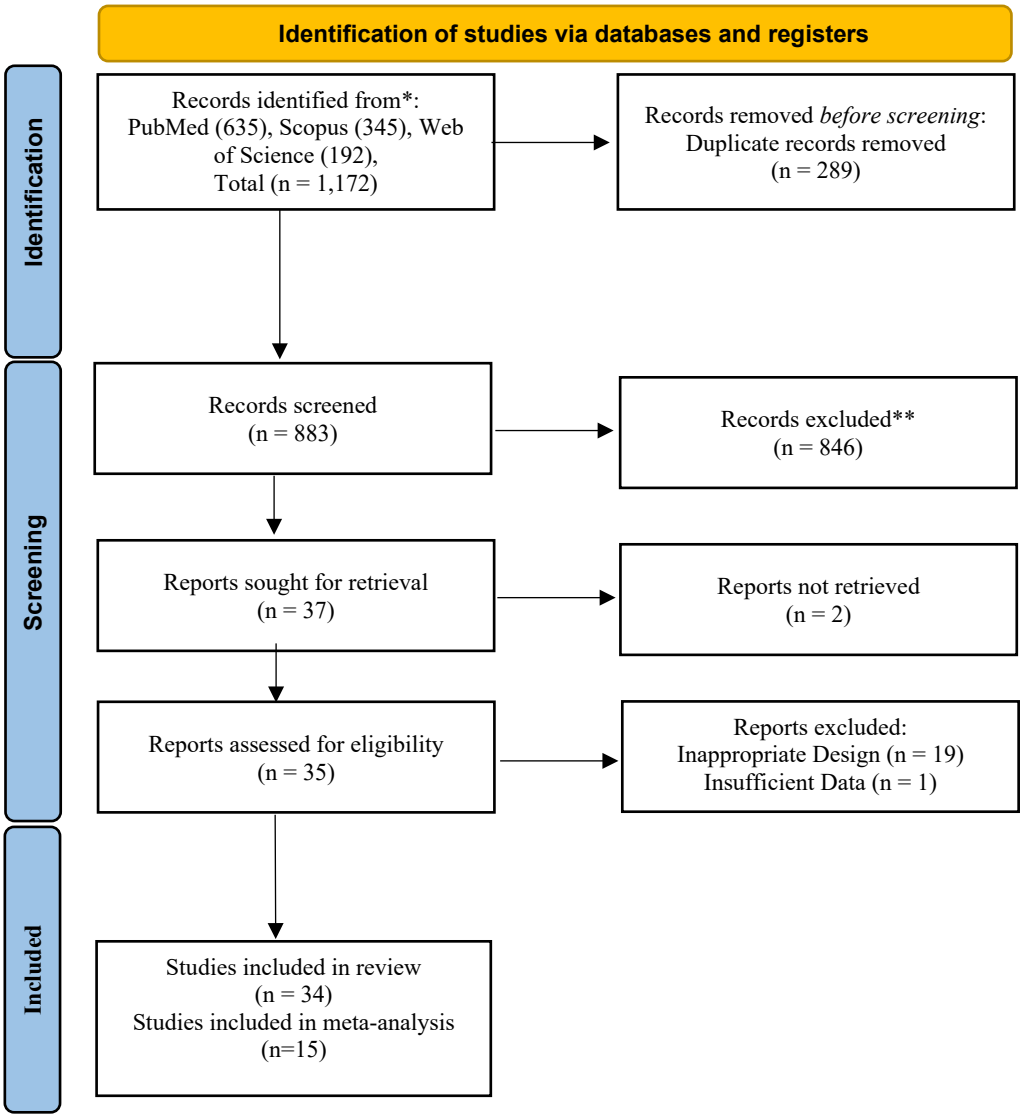

Fig. 1. PRISMA 2020 flow diagram showing the study selection process.

A total of 34 studies, including 450 patients diagnosed with hepatic PEComas and AMLs, were systematically reviewed. Among these patients, 342 (76%) were female and 108 (24%) were male. The mean age of patients was 45.42 years, ranging from 10 to 73 years. Eighty patients (18%) were initially misdiagnosed with hepatocellular carcinoma (HCC). Among the 53 patients with hepatitis, 34 were infected with hepatitis B and 19 patients with hepatitis C. The mean follow-up duration across studies was 37.4 months (ranging from one to 116 months). Progression of the tumor occurred in 27 (6%) patients during follow-up.

Based on the random effects model, the pooled proportion of malignancy in hepatic PEComa and AML was 8.6% (95% CI: 0.0183 - 0.3209). We found a statistically significant heterogeneity among the studies, with an I^2 value of 64.6% (95% CI: 34.3% - 80.9%). Begg's and Egger's tests indicated no significant publication bias for pooled malignancy proportion (p-value>0.05). Figures 2 and 3 present the forest and funnel plots for the pooled proportion of malignancy, respectively. For all pooled analyses, statistical significance of the overall effect could not be formally tested, and p-values were therefore not reported.

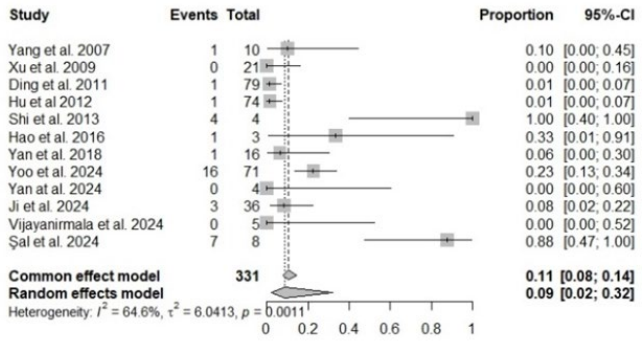

Fig. 2. Forest plot of pooled malignancy proportion among included studies

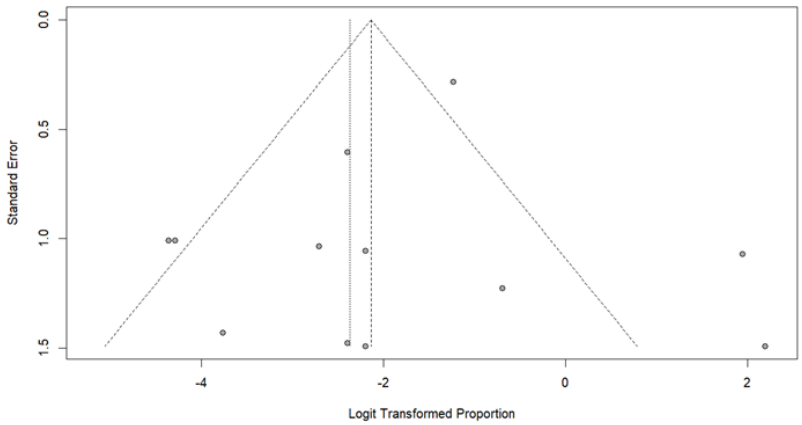

Fig. 3. Funnel plot of pooled malignancy proportion among included studies

The pooled proportion of positive HMB45 was 0.9881 (95% CI: 0.9717 - 0.9950) in both the common effect and random effects models. There was no heterogeneity, with an I² value of 0.0% (95% CI: 0.0% - 55.0%), indicating a high level of consistency across studies. Begg's test revealed no significant publication bias for pooled proportion of positive HMB45 (*p-value>0.05*), but Egger's test suggested a potential bias (*p-value=0.0052*). Figures 4 and 5 show the forest and funnel plots for the pooled proportion of positive HMB45, respectively.

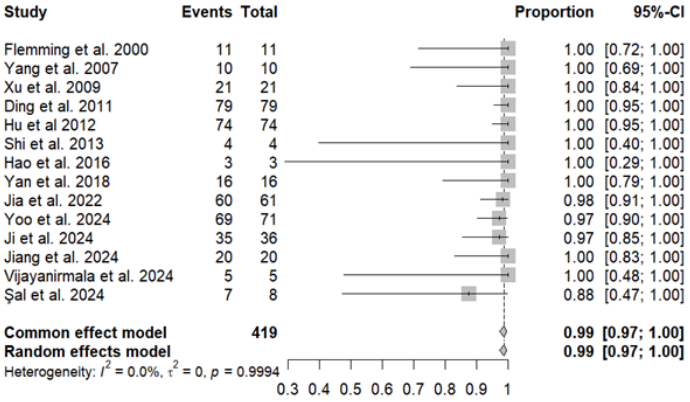

Fig. 4. Forest plot of pooled HMB45 positivity proportion among included studies

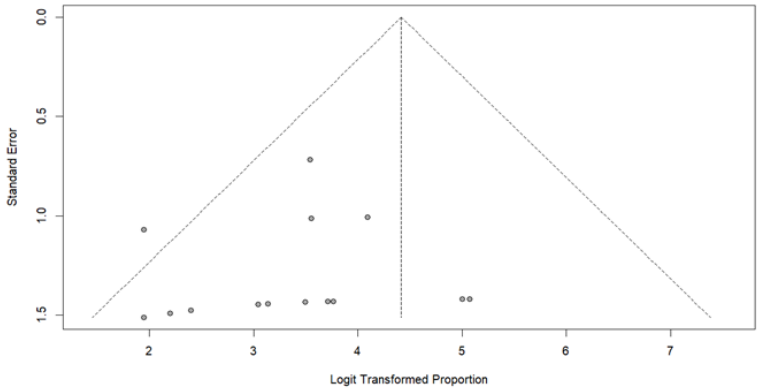

Fig. 5. Funnel plot of pooled HMB45 positivity proportion among included studies

According to random effects model the pooled proportion of SMA (smooth muscle actin) positivity was 0.9523 (95% CI: 0.8073 - 0.9896). There was low heterogeneity, with an I^2 value of 14.2% (95% CI: 0.0% - 54.1%). Heterogeneity test was not statistically significant (*p=0.3049*). No significant publication bias was detected using Begg's and Egger's tests (*p>0.05*). Figures 6 and 7 display the forest and funnel plots for the pooled proportion of SMA positivity.

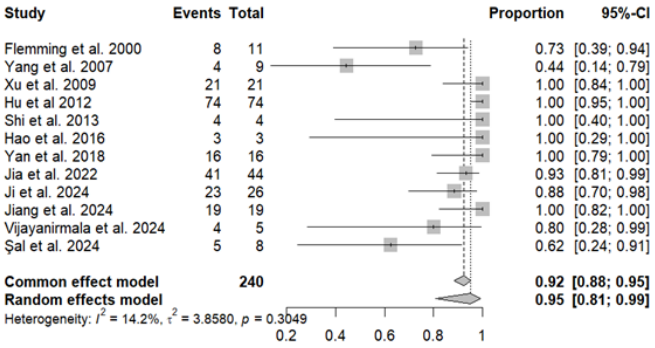

Fig. 6. Forest plot of pooled SMA positivity proportion among included studies

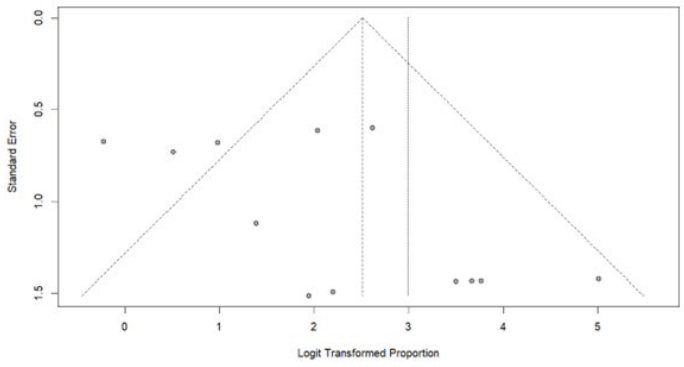

Fig. 7. Funnel plot of pooled SMA positivity proportion among included studies

For tumor invasion, the pooled proportion under the random effects model was 0.0469 (95% CI: 0.0268 - 0.0807), suggesting that only 4.7% of the cases exhibited invasive features. Heterogeneity was observed, with an I^2 value of 29.8% (95% CI: 0.0% - 66.4%). The test for heterogeneity was not statistically significant (*p=0.17*). Begg's and Egger's tests indicated no significant publication bias (*p>0.05*). Figures 8 and 9 present the forest and funnel plots for this outcome.

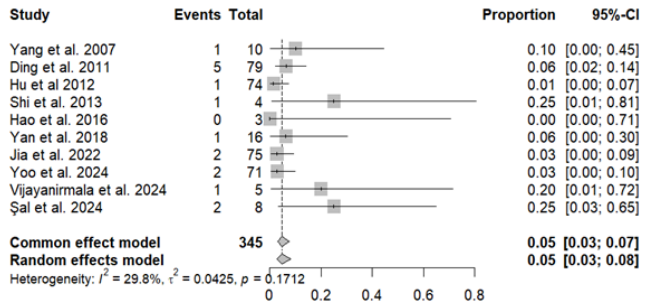

Fig. 8. Forest plot of pooled invasion proportion among included studies

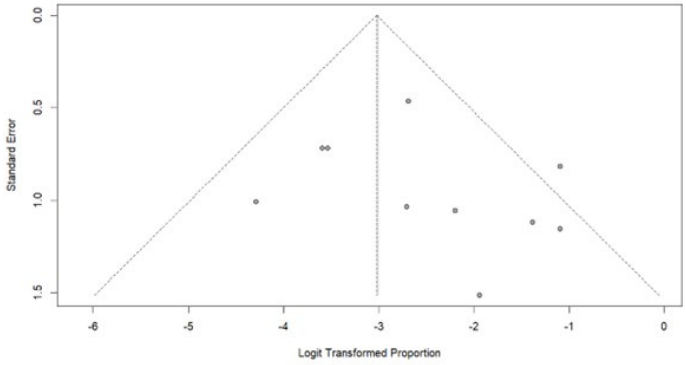

Fig. 9. Funnel plot of pooled invasion proportion among included studies

The pooled proportion of S-100 protein positivity under the random effects model was 0.2024 (95% CI: 0.0535 - 0.5329) with moderate heterogeneity (I^2 = 49.6%; 95% CI: 0.0% - 74.8%). The heterogeneity test was significant (*p=0.03*). No publication bias was seen on Begg's and Egger's tests (*p>0.05*). Forest and funnel plots are shown in Figures 10 and 11.

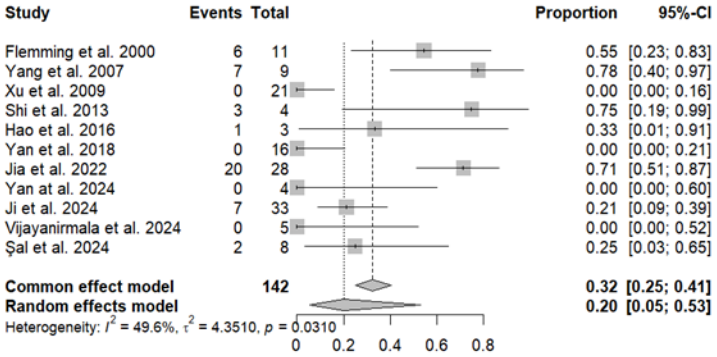

Fig. 10. Forest plot of pooled S-100 positivity proportion among included studies

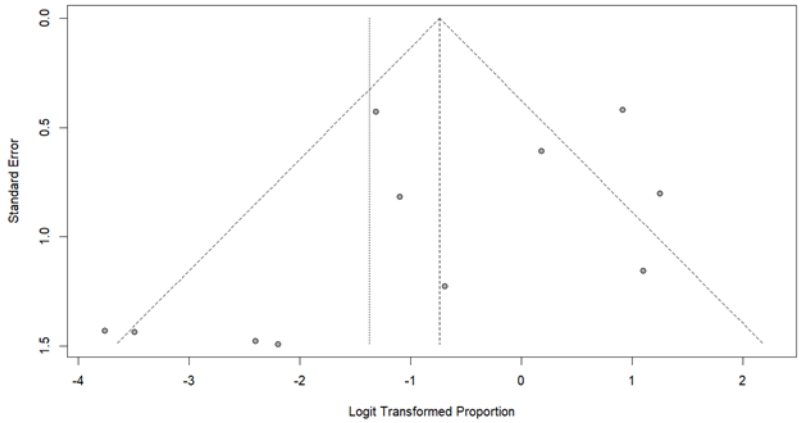

Fig 11. Funnel plot of pooled S-100 positivity proportion among included studies

For tumor size, the pooled mean under the random effects model was 67.10 mm (95% CI: 52.86 - 81.34). High heterogeneity was observed, with an I^2 value of 88.6% (95% CI: 83.0% - 92.4%), and the heterogeneity test was statistically significant ($p<0.0001$). While Egger's test indicated no significant publication bias ($p>0.05$), Begg's test suggested potential bias ($p=0.04$). Figures 12 and 13 show the forest and funnel plots for this outcome.

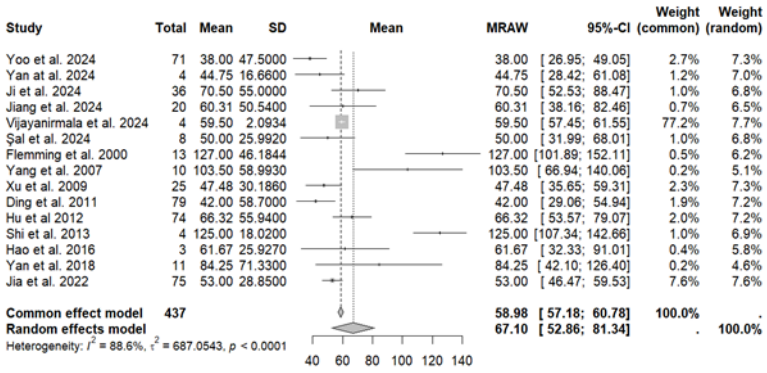

Fig. 12. Forest plot of pooled mean tumor size among included studies

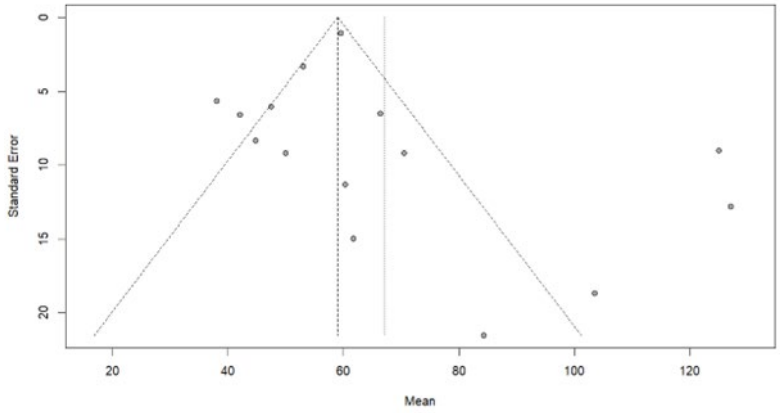

Fig. 13. Funnel plot of pooled mean tumor size among included studies

Table 2. Characteristics of the included studies

Author(s)	Year	Country	Study Design	Population Size	Age (Mean ± SD)	Gender		Number of Lesions		Follow Up	Progression
						Female	Male	Single	Multiple		
Dalle et al. (14)	2000	Belgium	Case report	1	70	1	0	1	0	66	1
Flemming et al. (15)	2000	Germany	Case series analysis	12	52.5 ± 8.85	11	1	11	1	48	2
Parfitt et al. (16)	2006	England	Case report	1	60	1	0	1	0	108	1
Yang et al. (17)	2007	Taiwan	Case series analysis	10	49 ± 8.66	9	1	10	0	38	1
Nguyen et al. (18)	2008	USA	Case report	1	43	1	0	1	0	9	1
Deng et al. (19)	2008	China	Case report	1	30	0	1	1	0	36	1
Xu et al. (20)	2009	China	Retrospective analysis	21	42.86 ± 11.17	18	3	18	3	42	1
Selvaggi et al. (21)	2011	Italy	Case report	1	42	0	1	1	0	1	1
Ding et al. (22)	2011	China	Case series	79	43 ± 15.02	58	21	79	0	96	1
Bing et al. (23)	2012	USA	Case report	1	43	0	1	1	0	33	1
Hu et al. (24)	2012	China	Case series	74	43.1 ± 10.4	54	20	74	0	64	1
Shi et al. (25)	2013	China	Case series	4	48 ± 4.42	3	1	4	0	32.5	4
Wang et al. (26)	2015	China	Case report	1	37	1	0	0	1	NA	1
Abhirup et al. (27)	2015	India	Case report	1	72	1	0	1	0	14	1
Fukuda et al. (28)	2016	Japan	Case report	1	58	0	1	1	0	84	1
Hao et al. (29)	2016	China	Case series	3	35.33 ± 11.26	2	1	3	0	8	1
Yan et al. (30)	2018	USA	Case series	10	43 ± 20.2	10	0	9	1	17.5	1
Baba et al. (31)	2021	Japan	Case report	1	10	0	1	1	0	34	1
Jia et al. (32)	2022	China	Single-center retrospective study	75	44 ± 11.55	52	23	69	6	NA	2
Li et al. (33)	2022	China	Case report	1	49	1	0	1	0	NA	0
Yoo et al. (34)	2024	Republic of Korea	Single-center retrospective study	71	51 ± 14	53	18	67	4	23	2
Yan at al. (35)	2024	China	Case series analysis	4	49.5 ± 7.75	3	1	4	0	6.65	0
Ji et al. (36)	2024	China	Retrospective analysis	36	47.8 ± 12.9	29	7	31	5	41.5	1
Jiang et al. (37)	2024	China	Retrospective analysis	19	43.2 ± 15.28	15	4	18	1	39.07	NA
Vijayanirmala et al. (38)	2024	India	Case series	5	35.5 ± 7.22	5	0	4	0	18.3	0
Şal et al. (39)	2024	Turkey	Single-center retrospective study	8	49.5 ± 9.38	7	1	8	0	116	0
Tababi et al. (40)	2024	Tunisia	Case report	1	50	1	0	1	0	3	0
Althunibat et al. (41)	2024	USA	Case report	1	73	1	0	1	0	NA	NA
Liu et al. (42)	2024	China	Case report	1	58	1	0	1	0	36	0
Li et al. (43)	2024	China	Case report	1	36	1	0	1	0	12	0
Takada et al. (44)	2024	Japan	Case report	1	32	1	0	1	0	16	0
Kvietkauskas et al. (45)	2024	Lithuania	Case report	1	42	1	0	1	0	4	0
Dymkowski et al. (46)	2024	Poland	Case report	1	27	0	1	0	1	36	0
Tan et al. (47)	2024	China	Case report	1	39	1	0	1	0	6	0

Discussion

PEComas are rare mesenchymal tumors first described by Bonetti et al. in 1992 (1, 2). In 2013, the World Health Organization characterized PEComas as "a mesenchymal tumor which shows a local association with vessel walls and usually expresses melanocyte and smooth muscle markers" (48, 49). This definition allows us to consider angiomyolipoma, lymphangioleiomyomatosis and clear cell sugar tumor of the lung as the PEComa family (9, 10, 50).

Based on our study the majority of patients were female (76%). This finding is consistent with previous reports suggesting a female predominance in PEComas (2, 51-53). The mean age of the patients was 45.42 years with a broad age range (10 to 73 years), which was in line with previous studies demonstrating that these tumors can affect individuals across a wide age range (8).

Approximately 8.6% of patients showed malignancy, suggesting that while most cases are benign, a subset exhibits malignant potential. This finding aligns with previous studies indicating that hepatic PEComas, though rare, can exhibit aggressive behavior, including local recurrence and distant metastasis (10, 54). The risk of malignant PEComas increases with larger tumor size, high mitotic activity, and necrosis-features that should lead to closer monitoring and aggressive management (55). Our study showed that tumor progression occurred in 6% of cases during follow-up, underscoring the importance of long-term surveillance, even in patients with initially benign-appearing tumors. The mean tumor size of 67.10 mm in our meta-analysis reflects the often-asymptomatic nature of hepatic PEComas, which are frequently detected incidentally during imaging studies for unrelated conditions. Larger tumors may be more likely to cause symptoms or exhibit malignant features, emphasizing the importance of early detection and intervention (56).

The strong expression of melanocytic markers, including HMB-45 and Melan-A, and smooth muscle markers like SMA highlights their value as reliable diagnostic markers in hepatic PEComas. As noted by Hornick et al., these tumors typically express immunoreactivity for both melanocytic and smooth muscle markers, which are critical in making a correct diagnosis (57). This dual immunophenotyping, distinguishes hepatic PEComas from the other liver tumors, including HCC and metastatic melanoma, which may share some morphological features but lack the characteristic immunoprofile of PEComas.

A notable finding from our review was the high rate of initial misdiagnosis, with 18% of patients incorrectly diagnosed with HCC. This highlights the diagnostic challenges associated with hepatic PEComas, particularly due to their radiological resemblance to HCC, as noted in previous studies (58). These challenges emphasize the need for thorough immunohistochemical evaluation to ensure accurate diagnosis and appropriate management. Another misdiagnosed malignancy was melanoma due to morphological features and positivity for HMB-45 and Melan-A. Studies have indicated that diffuse Mum-1 positivity can help distinguish between melanoma and PEComas. Additionally, S100 is typically negative in PEComas and diffuse positive in melanoma [57].

Several limitations of our study should be noted. The included studies were largely observational and retrospective, which are prone to selection and reporting biases. The considerable heterogeneity observed for certain outcomes, including tumor size and malignancy, limits the generalizability of our findings. Additionally, the lack of standardized diagnostic and reporting criteria across the studies may have contributed to variability in the results. Given the rarity of PEComa and the consequent scarcity of well-reported studies, formal hypothesis testing was not possible. The absence of pooled p-values limits the strength of statistical inference, and the results should therefore be interpreted as hypothesis-generating rather than confirmatory. Future research should focus on prospective studies with standardized criteria to better characterize the clinicopathological features and prognosis of hepatic PEComas.

Conclusion

This systematic review and meta-analysis highlight the rarity, diagnostic challenge, and generally favorable prognosis of hepatic PEComas. The high expression of HMB-45 and SMA underscores the importance of immunohistochemistry as a key diagnostic tool. Although these tumors are predominantly benign, the small proportion of malignant cases require complete histological analysis and long-term follow-up. Therefore, the risk factors for malignancy should be focused in the management of these tumors. Future research should prioritize standardized criteria and prospective studies to improve diagnosis and patient outcomes.

Overall our study findings indicated that hepatic PEComa is a rare disease that can affect all ages with female predominance. Although mainly benign, the risk of malignancy should be assessed and immunohistochemical assessment is required to reduce misdiagnosis rate. However, due to the heterogeneity of data, these findings might not be generalizable to all PEComa cases.

Acknowledgments

During the preparation of this paper, ChatGPT (GPT-40, open AI) was used in order to improve writing style, flow and readability. The authors reviewed and edited the ChatGPT suggestions as needed and take full responsibility for the content of publication.

Authors' Contributors

Alireza Abdollahi & Masoomeh Safaei, Investigation, Resources, Validation, Writing - review & editing;

Data Availability

The data supporting the results of this study are available upon request from the corresponding author.

Funding

This research received no specific grant from any funding agency in the public, commercial, or not-for-profit sectors.

Ethics Approval

This study was conducted in accordance with the ethical principles outlined in the Declaration of Helsinki. Ethical approval was obtained from the ethics committee of Tehran University of Medical Sciences.

Conflict of Interest

The authors declared no conflict of interest.

References

1. Bonetti F, Pea M, Martignoni G, Zamboni G. PEC and sugar. Am J Surg Pathol. 1992;16(3):307-8. [DOI:10.1097/00000478-199203000-00013] [PMID]
2. Ma Y, Huang P, Gao H, Zhai W. Hepatic perivascular epithelioid cell tumor (PEComa): analyses of 13 cases and review of the literature. Int J Clin Exp Pathol. 2018;11(5):2759-67.
3. Ahmad M, Varshney K, Qadri S, Ali WM, Ali I. A case of asymptomatic giant renal angiomyolipoma with extrusion of fat content with literature review. J Surg Case Rep. 2024;2024(11):rjae732. [DOI:10.1093/jscr/rjae732] [PMID] [PMCID]
4. Harari S, Torre O, Moss J. Lymphangioleiomyomatosis: what do we know and what are we looking for? Eur Respir Rev. 2011;20(119):34-44. [PMID] [PMCID] [DOI:10.1183/09059180.00011010]
5. Ameurtesse H, Chbani L, Bennani A, Toughrai I, Beggui N, Kamaoui I, et al. Primary perivascular epithelioid cell tumor of the liver: new case report and literature review. Diagn Pathol. 2014;9(1):149. [DOI:10.1186/1746-1596-9-149] [PMID] [PMCID]
6. Matrood S, Gorg C, Safai Zadeh E, Alhyari A. Hepatic perivascular epithelioid cell tumor (PEComa): contrast-enhanced ultrasound (CEUS) characteristics-a case report and literature review. Clin J Gastroenterol. 2023;16(3):444-9. [DOI:10.1007/s12328-023-01779-w] [PMID] [PMCID]
7. Rackauskas R, Luksaite-Lukste R, Stulpinas R, Bausys A, Paskonis M, Kvietkauskas M, et al. The Impact of Chemotherapy and Transforming Growth Factor-beta1 in Liver Regeneration after Hepatectomy among Colorectal Cancer Patients. J Pers Med. 2024;14(2):212. [DOI:10.3390/jpm14020144] [PMID] [PMCID]
8. Nie P, Wu J, Wang H, Zhou R, Sun L, Chen J, et al. Primary hepatic perivascular epithelioid cell tumors: imaging findings with histopathological correlation. Cancer Imaging. 2019;19(1):32. [PMCID] [DOI:10.1186/s40644-019-0212-x] [PMID]
9. Zhang S, Yang PP, Huang YC, Chen HC, Chen DL, Yan WT, et al. Hepatic perivascular epithelioid cell tumor: Clinicopathological analysis of 26 cases with emphasis on disease management and prognosis. World J Gastroenterol. 2021;27(35):5967-77. [DOI:10.3748/wjg.v27.i35.5967] [PMID] [PMCID]
10. Amante MF. Hepatic perivascular epithelioid cell tumors: Benign, malignant, and uncertain malignant potential. World J Gastroenterol. 2024;30(18):2374-8. [DOI:10.3748/wjg.v30.i18.2374] [PMID] [PMCID]
11. Czarnecka AM, Skoczylas J, Bartnik E, Switaj T, Rutkowski P. Management Strategies for Adults with Locally Advanced, Unresectable or Metastatic Malignant Perivascular Epithelioid Cell Tumor (PEComa): Challenges and Solutions. Cancer Manag Res. 2023;15:615-23. [DOI:10.2147/CMAR.S351284] [PMID] [PMCID]
12. Page MJ, McKenzie JE, Bossuyt PM, Boutron I, Hoffmann TC, Mulrow CD, et al. The PRISMA 2020 statement: an updated guideline for reporting systematic reviews. BMJ. 2021;372:n71. [DOI:10.1136/bmj.n71] [PMID] [PMCID]
13. Team RC. R: A language and environment for statistical computing. R Foundation for Statistical Computing, Vienna, Austria 2016 [Available from: http://www.R-project.org/. Missing closing bracket and final access date].
14. Dalle I, Sciot R, de Vos R, Aerts R, van Damme B, Desmet V, et al. Malignant angiomyolipoma of the liver: a hitherto unreported variant. Histopathology. 2000;36(5):443-50. [DOI:10.1046/j.1365-2559.2000.00891.x] [PMID]
15. Flemming P, Lehmann U, Becker T, Klempnauer J, Kreipe H. Common and epithelioid variants of hepatic angiomyolipoma exhibit clonal growth and share a

distinctive immunophenotype. Hepatology. 2000;32(2):213-7. [DOI:10.1053/jhep.2000.9142] [PMID]

16. Parfitt JR, Bella AJ, Izawa JI, Wehrli BM. Malignant neoplasm of perivascular epithelioid cells of the liver. Arch Pathol Lab Med. 2006;130(8):1219-22. [DOI:10.5858/2006-130-1219-MNOPEC] [PMID]
17. Yang CY, Ho MC, Jeng YM, Hu RH, Wu YM, Lee PH. Management of hepatic angiomyolipoma. J Gastrointest Surg. 2007;11(4):452-7. [PMCID] [DOI:10.1007/s11605-006-0037-3] [PMID]
18. Nguyen TT, Gorman B, Shields D, Goodman Z. Malignant hepatic angiomyolipoma: report of a case and review of literature. Am J Surg Pathol. 2008;32(5):793-8. [DOI:10.1097/PAS.0b013e3181607349] [PMID]
19. Deng YF, Lin Q, Zhang SH, Ling YM, He JK, Chen XF. Malignant angiomyolipoma in the liver: a case report with pathological and molecular analysis. Pathol Res Pract. 2008;204(12):911-8. [DOI:10.1016/j.prp.2008.06.007] [PMID]
20. Xu PJ, Shan Y, Yan FH, Ji Y, Ding Y, Zhou ML. Epithelioid angiomyolipoma of the liver: cross-sectional imaging findings of 10 immunohisto chemically-verified cases. World J Gastroenterol. 2009;15(36):4576-81. [DOI:10.3748/wjg.15.4576] [PMID] [PMCID]
21. Selvaggi F, Risio D, Claudi R, Cianci R, Angelucci D, Pulcini D, et al. Malignant PEComa: a case report with emphasis on clinical and morphological criteria. BMC Surg. 2011;11(1):3. [DOI:10.1186/1471-2482-11-3] [PMID] [PMCID]
22. Ding GH, Liu Y, Wu MC, Yang GS, Yang JM, Cong WM. Diagnosis and treatment of hepatic angiomyolipoma. J Surg Oncol. 2011;103(8):807-12. [DOI:10.1002/jso.21814] [PMID]
23. Bing Z, Yao Y, Pasha T, Tomaszewski JE, Zhang PJ. p53 in pure epithelioid PEComa: an immunohistochemistry study and gene mutation analysis. Int J Surg Pathol. 2012;20(2):115-22. [DOI:10.1177/1066896912441829] [PMID]
24. Hu WG, Lai EC, Liu H, Li AJ, Zhou WP, Fu SY, et al. Diagnostic difficulties and treatment strategy of hepatic angiomyolipoma. Asian J Surg. 2011; 34(4):158-62. [DOI:10.1016/j.asjsur.2011.11.005] [PMID]
25. Shi H, Bai Y, Guo A. Four cases of primary malignant perivascular epithelioid cell tumour of the liver. Pathology. 2013;45(6):614-6. [DOI:10.1097/PAT.0b013e32836537fe] [PMID]
26. Wang WT, Li ZQ, Zhang GH, Guo Y, Teng MJ. Liver transplantation for recurrent posthepatectomy malignant hepatic angiomyolipoma: a case report. World J Gastroenterol. 2015;21(12):3755-8. [DOI:10.3748/wjg.v21.i12.3755] [PMID] [PMCID]
27. Abhirup B, Kaushal K, Sanket M, Ganesh N. Malignant hepatic perivascular epithelioid cell tumor (PEComa) - Case report and a brief review. J Egypt Natl Canc Inst. 2015;27(4):239-42. [DOI:10.1016/j.jnci.2015.05.004] [PMID]
28. Fukuda Y, Omiya H, Takami K, Mori K, Kodama Y, Mano M, et al. Malignant hepatic epithelioid angiomyolipoma with recurrence in the lung 7 years after hepatectomy: a case report and literature review. Surg Case Rep. 2016;2(1):31. [DOI:10.1186/s40792-016-0158-1] [PMID] [PMCID]
29. Hao BB, Rao JH, Fan Y, Zhang CY, Dai XZ, Li X, et al. Hepatic perivascular epithelioid cell tumor in three patients. Hepatobiliary Pancreat Dis Int. 2016;15(6): 660-4. [DOI:10.1016/S1499-3872(16)60077-2] [PMID]
30. Yan Z, Grenert JP, Joseph NM, Ren C, Chen X, Shafizadeh N, et al. Hepatic angiomyolipoma: mutation analysis and immunohistochemical pitfalls in diagnosis. Histopathology. 2018;73(1):101-8. [DOI:10.1111/his.13509] [PMID] [PMCID]
31. Baba T, Kawano T, Saito Y, Onishi S, Yamada K, Yamada W, et al. Malignant perivascular epithelioid cell neoplasm in the liver: report of a pediatric case. Surg Case Rep. 2021;7(1):212. [PMCID] [DOI:10.1186/s40792-021-01300-w] [PMID]
32. Jia J, Luo J, Pan CG, Ge G, Feng M, Zou B, et al. Single-center Experience in the Diagnosis and Treatment of Hepatic Perivascular Epithelioid Cell Neoplasm. J Clin Transl Hepatol. 2022;10(1):72-9. [DOI:10.14218/JCTH.2020.00170] [PMID] [PMCID]
33. Li Z, Zhou Y, Wang C, Yu H, Yang G, Ma Y. Insights into clinical diagnosis and treatment of malignant hepatic perivascular epithelioid cell tumor. Intractable Rare Dis Res. 2022;11(4):202-5. [DOI:10.5582/irdr.2022.01111] [PMID] [PMCID]
34. Yoo Y, Kim J, Song IH. Risk prediction criteria for the primary hepatic perivascular epithelioid cell tumour family, including angiomyolipoma: analysis of 132 cases with a literature review. Histopathology. 2025; 86(6):979-92. [DOI:10.1111/his.15405] [PMID]
35. Yan J, Zhou D, Wang Y, Yang B, Wang Y, Zhang K, et al. A retrospective clinical analysis of 11 cases of PEComa from different sites. World J Surg Oncol. 2024;22(1):116. [DOI:10.1186/s12957-024-03349-x] [PMID] [PMCID]
36. Ji M, Zhang Y, Liu S, Zhang M, Qiao B. Hepatic perivascular epithelioid cell tumor: a retrospective analysis of 36 cases. Front Oncol. 2024;14:1416254. [DOI:10.3389/fonc.2024.1416254] [PMID] [PMCID]
37. Jiang T, Hu Y, Wang J, Li W. Fat-Poor Hepatic Angiomyolipoma in Noncirrhotic Livers: Imaging Features, Pathology, and Differential Diagnosis. J Comput Assist Tomogr. 2024;48(5):727-33. [DOI:10.1097/RCT.0000000000001605] [PMID]
38. Vijayanirmala P, Yadav R, Goyal S, Barwad A, Bhowmik S, Malik R, et al. Hepatic and perihepatic PEComas: A study describing a series of five rare cases. Indian J Pathol Microbiol. 2024;67(2):355-61. [DOI:10.4103/ijpm.ijpm_587_23] [PMID]
39. Sal O, Goksoy B, Al Hajeh A, Ercan LD, Buyuk M, Serin KR. Surgical management of liver angiomyolipoma: eighteen years of experience from a single-reference center. HPB (Oxford). 2024;26(1):156-9. [DOI:10.1016/j.hpb.2023.10.006] [PMID]
40. Tababi R, Medhioub M, Soussi I, Noomen I, Kallel Y, Yakoubi M, et al. Hepatic Angiomyolipoma: A Case Report and Literature Review. J Investig Med High Impact Case Rep. 2024;12: 23247096241306542. [PMID] [PMCID] [DOI:10.1177/23247096241306542]

41. Althunibat I, Qirem M, Alomari A, Kogilathota Jagirdhar GS, Hussain M, Bains Y, et al. S4355 A Rare Case of Hepatic Perivascular Epithelioid Cell Tumor (PEComa) in a 73-Year-Old Female Patient. Am J Gastroenterol. 2024;119(10S):S2792-3. [DOI:10.14309/01.ajg.0001046788.67238.70]

42. Liu XL, Cui J, Tian H. Hepatic perivascular epithelioid cell neoplasm in a 58-year-old woman. Pol Arch Intern Med. 2024;134(1):16631. [DOI:10.20452/pamw.16615]

43. Li G, Wang X, He X. Hepatic perivascular epithelioid cell tumor with the constipation symptom: A rare case report. Asian J Surg. 2024;47(3):1628-30. [DOI:10.1016/j.asjsur.2023.12.079] [PMID]

44. Takada R, Takahashi M, Hayashi T, Higashihara T, Morita Y, Inoue D, et al. Laparoscopic resection of liver PEComa associated with Li Fraumeni syndrome: A case report. Biomed Rep. 2024;21(5):154. [DOI:10.3892/br.2024.1842] [PMID] [PMCID]

45. Kvietkauskas M, Samuolyte A, Rackauskas R, Luksaite-Lukste R, Karaliute G, Maskoliunaite V, et al. Primary Liver Perivascular Epithelioid Cell Tumor (PEComa): Case Report and Literature Review. Medicina (Kaunas). 2024;60(3):477. [PMCID] [DOI:10.3390/medicina60030409] [PMID]

46. Dymkowski M, Kalman P, Niecikowski P, Koperski L, Kosieradzki M. Case report: Liver PEComa after kidney transplantation in recipient with tuberous sclerosis complex. Front Oncol. 2024;14:1386569. [DOI:10.3389/fonc.2024.1386569] [PMID] [PMCID]

47. Tan LLY, Lee VTW, Lim TKH. A case of liver angiomyolipoma accompanied with multiple focal nodular hyperplasia. Pathology. 2024;56(5):755-8. [DOI:10.1016/j.pathol.2024.02.007] [PMID]

48. Maebayashi T, Abe K, Aizawa T, Sakaguchi M, Ishibashi N, Abe O, et al. Improving recognition of hepatic perivascular epithelioid cell tumor: Case report and literature review. World J Gastroenterol. 2015;21(17):5432-41. [DOI:10.3748/wjg.v21.i17.5432] [PMID] [PMCID]

49. Fletcher CD, Unni K, Mertens F. World Health Organization classification of tumours. Pathology and genetics of tumours of soft tissue and bone. Lyon: IARC press; 2002.

50. Folpe AL, Kwiatkowski DJ. Perivascular epithelioid cell neoplasms: pathology and pathogenesis. Hum Pathol. 2010;41(1):1-15. [DOI:10.1016/j.humpath.2009.05.011] [PMID]

51. Chang Z, Zhang JM, Ying JQ, Ge YP. Characteristics and treatment strategy of hepatic angiomyolipoma: a series of 94 patients collected from four institutions. J Gastrointestin Liver Dis. 2011;20(1):65-9.

52. Nonomura A, Enomoto Y, Takeda M, Takano M, Morita K, Kasai T. Angiomyolipoma of the liver: a reappraisal of morphological features and delineation of new characteristic histological features from the clinicopathological findings of 55 tumours in 47 patients. Histopathology. 2012;61(5):863-80. [DOI:10.1111/j.1365-2559.2012.04306.x] [PMID]

53. Lo RC. Epithelioid angiomyolipoma of the liver: a clinicopathologic study of 5 cases. Ann Diagn Pathol. 2013;17(5):412-5. [DOI:10.1016/j.anndiagpath.2013.04.009] [PMID]

54. Bleeker JS, Quevedo JF, Folpe AL. "Malignant" perivascular epithelioid cell neoplasm: risk stratification and treatment strategies. Sarcoma. 2012;2012:541626. [DOI:10.1155/2012/541626] [PMID] [PMCID]

55. Sobiborowicz A, Czarnecka A, Szumera-Ciećkiewicz A, Rutkowski P, Świtaj T. Diagnosis and treatment of malignant PEComa tumours. Oncol Clin Pract. 2020;16(1):22-33. [DOI:10.5603/OCP.2020.0003]

56. Krawczyk M, Ziarkiewicz-Wroblewska B, Wroblewski T, Podgorska J, Grzybowski J, Gierej B, et al. PEComa-A Rare Liver Tumor. J Clin Med. 2021;10(8):1665. [DOI:10.3390/jcm10081756] [PMID] [PMCID]

57. Hornick JL, Fletcher CD. PEComa: what do we know so far? Histopathology. 2006;48(1):75-82. [DOI:10.1111/j.1365-2559.2005.02316.x] [PMID]

58. Stockman DL. PEComa of Liver. In: Stockman DL, editor. Diagnostic Pathology: Vascular. Philadelphia: Elsevier; 2016. 9-26-31. [DOI:10.1016/B978-0-323-37674-7.50080-5]