Iranian Journal of Pathology | ISSN: 2345-3656

Thyroid Collision Carcinoma: A Case Report

Zahra Miri [1], Sareh Etemad [2], Golnaz Ghayyem Hassankhani [3], Mahsa Akbari Oryani[2]

1. *Department of Pathology, School of Medicine, Mashhad University of Medical Sciences, Mashhad, Iran*
2. *Department of Pathology, Faculty of Medicine, Mashhad University of Medical Sciences, Mashhad, Iran*
3. *Mashhad University of Medical Sciences, Mashhad, Iran*

KEYWORDS

Collision tumor, Thyroid, Papillary carcinoma, Medullary carcinoma

Scan to discover online

Main Subjects:
Endocrine Pathology

Received 19 Dec 2025;
Accepted 18 Feb 2026;
Published Online 25 Feb 2026;

10.22034/ijp.2026.2077955.3588

ABSTRACT

Background & Objective: Thyroid cancer is one of the most prevalent endocrine neoplasms. Papillary thyroid carcinoma (PTC) and Medullary thyroid carcinoma (MTC) are two different types of thyroid cancers. The synchronous occurrence of PTC and MTC is a rare phenomenon, but it can present as a thyroid collision tumor. The purpose of this case report is to highlight a rare presentation of a collision tumor and its associated diagnostic challenges.

Case Report: In this case report, a 61-year-old female patient presented with a painless anterior neck mass and voice hoarseness. She had a previous history of benign multinodular goiter and left lobectomy. Preoperative fine needle aspiration (FNA) biopsy of neck lymph nodes showed malignant epithelioid cells with anisonucleosis, plasmacytoid and spindle-like morphology, consistent with metastatic carcinoma, likely MTC. She underwent completion total thyroidectomy and histopathology investigations post-operation showed PTC in right lobe and the remnant of left lobe, and concurrent MTC was detected in two out of two central lymph nodes. On follow up patient had no signs of recurrence.

Conclusion: This case highlights the importance of careful histological assessment of thyroid masses and lymph nodes for accurate diagnosis and the importance of long-term follow up after subtotal thyroidectomy or thyroid lobectomy.

Corresponding Information: **Sareh Etemad,** Department of Pathology, Faculty of Medicine, Mashhad University of Medical Sciences, Mashhad, Iran. Email: etemadsr2@mums.ac.ir

Copyright © 2026. This is an open-access article distributed under the terms of the **Creative Commons Attribution 4.0 International License (CC BY 4.0)**, which permits unrestricted use, distribution, and reproduction in any medium, provided the original work is properly cited. The license also allows users to adapt, remix, transform, and build upon the material for any purpose, including commercial use.

Introduction

Thyroid cancer is one of the most common endocrine neoplasms and occur more frequently in women (1,2). In the last decades, the incidence of thyroid cancer has increased, probably due to use of more accurate diagnostic tools such as ultrasound and fine-needle aspiration (FNA) (2).

Papillary thyroid carcinoma (PTC) is the most common type of malignant thyroid tumors that arises from thyroid follicular cells (3,4). Medullary thyroid carcinoma (MTC) is a rare form of thyroid cancer that originates from parafollicular C cells, which produce calcitonin (5,6). Most MTC cases are sporadic, but about 20-30% are hereditary (6). The hereditary form is associated with multiple endocrine neoplasia type 2 (MEN 2) syndrome (6).

The concurrent occurrence of PTC and MTC is uncommon, but it can present as either a mixed tumor or a collision tumor (7,8). Thyroid collision tumors are rare and account for only about 1% of all thyroid cancers (9). The most common combination is synchronous PTC/MTC, followed by PTC/follicular thyroid cancer (FTC) (10).

In this report, we present a rare case of a PTC/MTC thyroid collision tumor with an uncommon presentation. This case report highlights a thyroid collision tumor in which PTC coexists with metastatic MTC without an identifiable primary MTC, a rare presentation associated with diagnostic challenges.

Case Report

A 61-year-old female presented to Omid hospital in Mashhad, Iran, in 2024 with a painless anterior neck mass and voice hoarseness. She had been diagnosed with benign multinodular goiter in 2016 and underwent a left lobectomy. She had no family history of thyroid disease or malignancy. At the time of presentation, the patient was not taking any medications, and details of medication use in 2016 were unavailable. Physical examination revealed a firm, painless left thyroid nodule. Vital signs were within normal range and the reminder of physical examination was unremarkable. Laboratory tests showed suppressed TSH (<0.05 mIU/L) (normal range: 0.4 to 4.5 mIU/L), with normal T3 and T4 levels (Table 1).

Ultrasound revealed a hypoechoic left thyroid nodule measuring 9.5 × 11 mm with internal microcalcifications and undefined margins (TIRADS 5). Also, three cystic lymph nodes were found, the largest measuring 22 × 10 mm at level VI anterior to the left thyroid lobe, and another lymph node measuring 14.5 × 13.5 mm with irregular vascularity at level VI. All findings were suspicious for metastatic disease. The thyroid scan demonstrated a diffuse goiter with increased uptake in the right thyroid lobe and a cold nodule in the left lobe.

Preoperative fine needle aspiration (FNA) biopsy was performed on the left level VI cervical lymph node. Because the thyroid nodule was located deep within the left lobe and posterior to the cystic lymph nodes, the thyroid lesion was not accessible for FNA. FNA biopsy of neck lymph nodes showed malignant epithelioid cells with anisonucleosis, plasmacytoid and spindle-like morphology, consistent with metastatic carcinoma, likely MTC. Serum calcitonin level was 102 pg/ml (normal <5.0 pg/mL) (Table 1).

Table 1. Laboratory results showing thyroid function tests and tumor markers

Test	Result	Reference interval
TSH	<0.05 mIU/L	0.4- 4.5 mIU/L
T4	11.5 µg/dL	4.5-12.5 µg/dL
T3	121 ng/dL	80-200 ng/dL
Calcitonin	102 pg/mL	<5.0 pg/mL
CEA (CLIA)	1.7 ng/mL	Non-smoker: 0.3-5 ng/mL Smoker: 0.4-8.5 ng/mL

TSH: thyroid stimulating hormone CEA: carcinoembryonic antigen

Patient underwent completion total thyroidectomy, central neck dissection, modified radical neck dissection. Also, thymectomy was performed, as the thymus was ectopic and located along the dissection pathway, so the surgical team decided to remove it intraoperatively.

Post-operative histopathological examination of the left thyroid lobe remnants showed a lesion measured 1.5 x1 cm with papillary pattern, lined by tumoral cells with nuclear grooves, inclusions and ground glass nuclei, consistent with papillary thyroid carcinoma. The PTC was classic type with no evidence of lymphovascular or perineural invasion (Figure 1).

The right thyroid lobe contained a 0.7 × 0.5 cm lesion characterized by complex branching papillae with fibrovascular cores, lined by tumoral cells with nuclear groove, inclusions, nuclear overlapping, ground glass nuclei, and psammoma bodies, consistent with papillary thyroid carcinoma, classic type. The lesion had clear margins and showed no lymphovascular, perineural, or extrathyroidal invasion (Figure 1). The background thyroid parenchyma showed nodular hyperplasia. Microscopic examination of the entire thyroid tissue was performed to identify a primary MTC; however, no primary MTC was identified.

Two out of two central neck lymph nodes were involved by a distinct neoplasm with solid and nested pattern, composed of spindle to polygonal cells with focal amyloid deposition, consistent with a diagnosis of medullary thyroid carcinoma (Figure 2). Lateral neck lymph nodes (levels III-V) were reactive with no tumor involvement. Thymus showed no evidence of tumoral involvement. Immunohistochemistry (IHC) showed positive staining for calcitonin, synaptophysin, and chromogranin and negative staining for thyroglobulin (TG) in MTC (Figure 3). Carcinoembryonic antigen (CEA) level was within the normal range (Table 1).

After surgery, patient had no complications and was discharged. The patients was followed up once every three months for 12 months and showed no signs of recurrence on follow up visits. Follow up is ongoing and is now scheduled for once every 6 months.

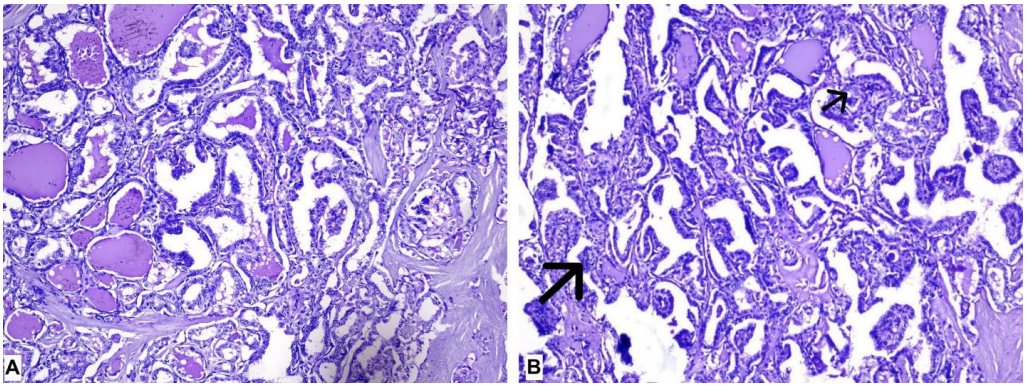

Fig. 1. Classic papillary thyroid carcinoma shows papillary and follicular structures composed of cells with ground-glass nuclei (arrows in figure B), nuclear grooves, and intranuclear inclusions (A, B: x10).

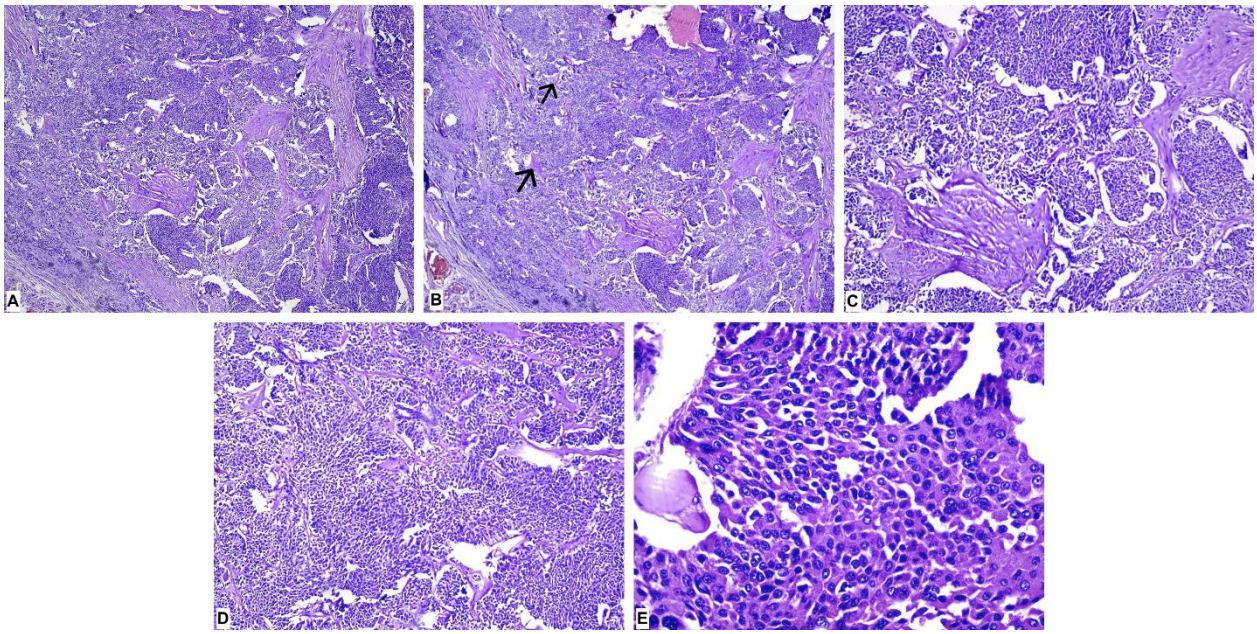

Fig. 2. Medullary thyroid carcinoma. (A, B: x4): plasmacytoid, polygonal, or spindle cells in nests and cords. (C, D: x10 and E: x40): round nuclei with finely stippled to coarsely clumped chromatin and indistinct nucleoli, occasional nuclear pseudoinclusion, eosinophilic to amphophilic granular cytoplasm due to secretory granules, and generally low mitotic figures. Stroma has amyloid deposits (arrows in figure B), derived from calcitonin.

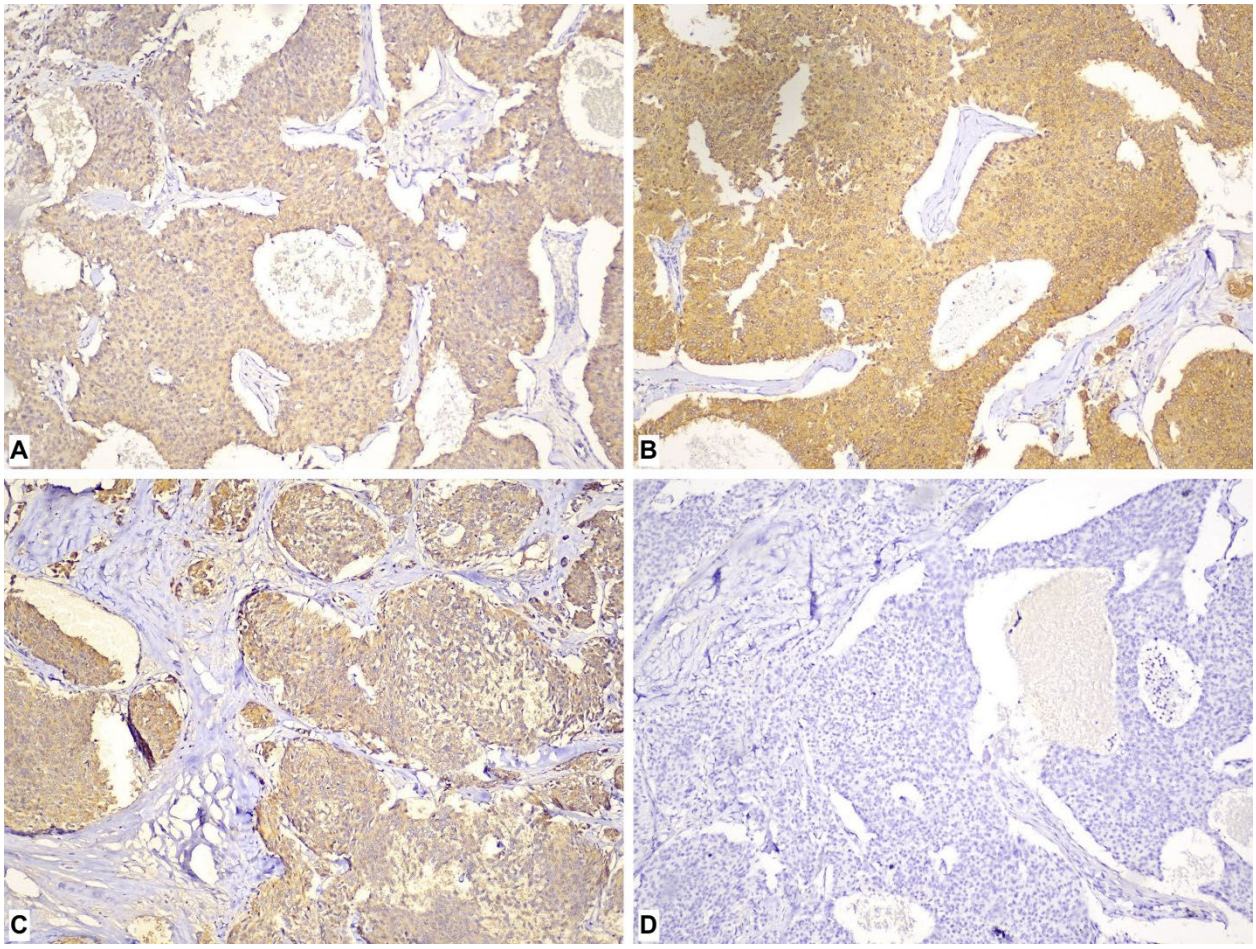

Fig. 3. Positive immunohistochemical staining for calcitonin (A), synaptophysin (B), and chromogranin (C) and negative staining for thyroglobulin (D) in MTC (A, B, C, D: x10).

Discussion

A collision tumor refers to the presence of two independent tumors with distinct histological features, that are separated by normal thyroid tissue (8). In contrast, a mixed tumor is a single neoplasm that contains different cell types, all of which arise from a common origin (9). In our case, PTC was present in the right thyroid lobe and remnants of the left lobe, while MTC was found only in the central lymph nodes. The background thyroid parenchyma showed nonneoplastic changes and nodular hyperplasia. Therefore, the present case is classified as a collision tumor.

This presentation is unusual, as most reported thyroid collision tumors occur simultaneously in the same thyroid lobe or in different lobes, with or without lymph node metastasis (3,11,12). A possible explanation is that a small, undetectable PTC and/or MTC may have been present at the time of the patient's benign multinodular goiter diagnosis in 2016. Over time, this occult MTC may have metastasized to the central lymph nodes and then regressed. In this case, microscopic examination of the entire thyroid tissue showed no primary MTC.

The coexistence of occult thyroid carcinoma within multinodular goiter has been previously reported in the literature (13). Amin et al. reported that PTC is the most prevalent type of cancer in multinodular goiter cases (14). Similarly, Semerci et al. found not only papillary thyroid microcarcinoma but also medullary thyroid microcarcinoma in thyroidectomy specimens of patients with benign multinodular goiter (15). Another study showed that over 60% of patients who underwent subtotal thyroidectomy for multinodular goiter had microscopic pathological changes in the remaining thyroid tissue including micronodules, thyroiditis, and papillary thyroid microcarcinoma (16). Therefore, long-term monitoring of the residual thyroid long-term after subtotal thyroidectomy or thyroid lobectomy is important to detect any potential pathological changes.

Carcinomas found in lymph nodes should be examined using a broad IHC panel to determine their origin. Since thyroid transcription factor-1 (TTF-1), which is expressed by follicular and parafollicular thyroid cells, is a valuable marker for confirming thyroid origins in lymph node metastases (17). Calcitonin and CEA are reliable markers for the diagnosis of MTC. Therefore, the combination of calcitonin, CEA, thyroglobulin, and TTF-1 is necessary to confirm that tumors in lymph nodes are metastases from MTC (18). However, in this study, TTF-1 and mCEA could not be performed due to financial limitations.

The strength of this study is that it discusses a rare presentation of the PTC/MTC thyroid collision tumor, which contributes to clinical awareness of the physicians and supports their decision-making. Although this study presents a rare case of a thyroid collision tumor, it has several limitations and weaknesses. One limitation is the partial availability of the patient's surgical records from eight years earlier. Another limitation, as mentioned previously, is that we were unable to perform TTF-1 and mCEA. We suggest that future studies include TTF-1 and mCEA testing to improve diagnostic accuracy.

Conclusion

In this study, we reported a rare presentation of a thyroid collision tumor in which PTC was detected in thyroid lobes and MTC was present only in the central lymph nodes of a patient with prior history of benign multinodular goiter. Pathologists should carefully assess specimens after thyroidectomy and consider the possibility of a thyroid collision tumor, as identifying one type of thyroid malignancy does not rule out the coexistence of another. Also, long-term follow-up after thyroid lobectomy is important for patients with multinodular goiter to monitor for potential changes in the residual thyroid tissue.

Acknowledgments

The authors would like to thank the Department of Pathology at Mashhad University of Medical Sciences and the team of clinicians involved in the patient's treatment.

Authors' Contributors

All authors contributed equally to the conceptualization, design, and execution of this study.

Data Availability

The datasets generated and analyzed during the current study are not publicly available; however, the data can be shared for research and authentication purposes upon reasonable request.

Funding

This research received no specific grant from any funding agency in the public, commercial, or not-for-profit sectors.

Ethics Approval

All identifying patient information was removed to protect privacy. Written informed consent for publication (text and images) was obtained from the patient.

Conflict of Interest

The authors declared no conflict of interest.

References

1. Hu S, Wu X, Jiang H. Trends and projections of the global burden of thyroid cancer from 1990 to 2030. J Glob Health. 2024 May 17;14:04084. [DOI:10.7189/jogh.14.04084] [PMID] [PMCID]

2. Pstrąg N, Ziemnicka K, Bluyssen H, Wesoły J. Thyroid cancers of follicular origin in a genomic light: in-depth overview of common and unique molecular marker candidates. Mol Cancer. 2018 Dec;17(1):116. [DOI:10.1186/s12943-018-0866-1] [PMID] [PMCID]

3. Kawasaki K, Kai K, Tanaka N, Kido S, Ibi A, Minesaki A, et al. Collision tumor of a papillary and follicular thyroid carcinoma: a case report. Thyroid Res. 2023 Aug 7;16(1):24. [DOI:10.1186/s13044-023-00167-3] [PMID] [PMCID]

4. Haghzad T, Khorsand B, Razavi SA, Hedayati M. A computational approach to assessing the prognostic implications of BRAF and RAS mutations in patients with papillary thyroid carcinoma. Endocrine. 2024 Jun 17;86(2):707-22. [DOI:10.1007/s12020-024-03911-3] [PMID]

5. Prete A, Borges De Souza P, Censi S, Muzza M, Nucci N, Sponziello M. Update on Fundamental Mechanisms of Thyroid Cancer. Front Endocrinol. 2020 Mar 13;11:102. [DOI:10.3389/fendo.2020.00102] [PMID] [PMCID]

6. Pacini F, Castagna MG, Cipri C, Schlumberger M. Medullary Thyroid Carcinoma. Clinical Oncology. 2010 Aug;22(6):475-85. [DOI:10.1016/j.clon.2010.05.002] [PMID]

7. Appetecchia M, Lauretta R, Barnabei A, Pieruzzi L, Terrenato I, Cavedon E, et al. Epidemiology of Simultaneous Medullary and Papillary Thyroid Carcinomas (MTC/PTC): An Italian Multicenter Study. Cancers. 2019 Oct 9;11(10):1516. [DOI:10.3390/cancers11101516] [PMID] [PMCID]

8. Paixão JGMD, Tabosa GVBDS, Silva CAM. Thyroid collision tumor: a case report of three histological types in the same patient. Arch Head Neck Surg. 2023;52:e20230002. [DOI:10.4322/ahns.2023.0002]

9. Ma T, Wang R, Zhou X, Liu L, Pan A, Wang H, et al. Case reports of collision and composite carcinomas of the thyroid: an insight into their origin and clinical significance. BMC Endocr Disord. 2023 Aug 14;23(1):173. [DOI:10.1186/s12902-023-01409-z] [PMID] [PMCID]

10. Ari M. Abdullah, Aras J. Qaradakhy, Rawa M. Ali, Rebaz M. Ali, Yousif M. Mahmood, Sami S. Omar, et al. Thyroid Collision Tumors: A Systematic Review. Barw Medical Journal [Internet]. 2024 Jun 28 [cited 2025 Aug 25]; Available from: https://www.barwmedical.com/index.php/BMJ/article/view/94 [DOI:10.58742/bmj.v2i2.94]

11. Dikbas O, Duman AA, Guvendi GF. Medullary Thyroid Carcinoma and Papillary Thyroid Carcinoma in the Same Patient as a Collision Tumour. Case Reports in Endocrinology. 2019 Mar 12;2019:1-4. [DOI:10.1155/2019/4038628] [PMID] [PMCID]

12. Thomas A, Mittal N, Rane SU, Bal M, Patil A, Ankathi SK, et al. Papillary and Medullary Thyroid Carcinomas Presenting as Collision Tumors: A Case Series of 21 Cases at a Tertiary Care Cancer Center. Head and Neck Pathol. 2021 Dec;15(4):1137-46. [DOI:10.1007/s12105-021-01323-7] [PMID] [PMCID]

13. Permekerlis A, Tepelidis C, Gemousakaki E, Fotiadis P. The Coexistence of Occult (Latent) Thyroid Cancer and Multinodular Goiter After Total Thyroidectomy: A Retrospective Study. Cureus [Internet]. 2024 Jun 14 [cited 2025 Nov 13]; Available from: https://www.cureus.com/articles/163085-the-coexistence-of-occult-latent-thyroid-cancer-and-multinodular-goiter-after-total-thyroidectomy-a-retrospective-study [DOI:10.7759/cureus.62386]

14. Amin A, Amjad A, Farman G, Khaliq SU, Amin L, Khan M. Frequency and Type of Thyroid Carcinoma in Patients With Multinodular Goiter. Cureus [Internet]. 2023 Apr 21 [cited 2025 Nov 13]; Available from: https://www.cureus.com/articles/144702-frequency-and-type-of-thyroid-carcinoma-in-patients-with-multinodular-goiter [DOI:10.7759/cureus.37921]

15. Semerci O, Gucer H. The Significance of Unsampled Microscopic Thyroid Carcinomas in Multinodular Goiter. Endocr Pathol. 2023;34(1):119-28. [DOI:10.1007/s12022-022-09743-z] [PMID]

16. Karakoyun R, Bülbüller N, Koçak S, Habibi M, Gündüz U, Erol B, et al. What do we leave behind after neartotal and subtotal thyroidectomy: just the tissue or the disease? Int J Clin Exp Med. 2013;6(10):922-9.

17. Ordóñez NG. Value of Thyroid Transcription Factor-1 Immunostaining in Tumor Diagnosis: A Review and Update. Applied Immunohistochemistry & Molecular Morphology. 2012 Oct;20(5):429-44. [DOI:10.1097/PAI.0b013e31825439bc] [PMID]

18. Beiriger J, McCrary HC, Carpenter P, Witt BL, Abraham D, Monroe MM. Medullary thyroid cancer arising from a thyroid rest: a case report. Journal of Surgical Case Reports. 2025 Aug 3;2025(8):rjaf613. [DOI:10.1093/jscr/rjaf613] [PMID] [PMCID]