Iranian Journal of Pathology | ISSN: 2345-3656

Intraosseous Angiolipoma of the Mandible: A Rare Case Report

Hamid Mojtahedi[1], Mohamadreza Yegane[2], Katayoun Amirzadegan[2], Pouyan Aminishakib[3]

1. *Oral and Maxillofacial Surgery Department, Craniomaxillofacial Research Center, Tehran University of Medical Sciences, Tehran, Iran*
2. *School of Dentistry, Tehran University of Medical Sciences, Tehran, Iran*
3. *Oral and Maxillofacial Pathology Department, Cancer Institute Hospital, Tehran University of Medical Sciences, Tehran, Iran*

KEYWORDS

Angiolipoma, intraosseous, mandible, lipoma

Scan to discover online

Main Subjects:
Head and Neck Pathology

Received 17 Nov 2025;
Accepted 07 Feb 2026;
Published Online 25 Feb 2026;

10.22034/ijp.2026.2073701.3563

ABSTRACT

Background & Objective: We report the case of an extremely rare intraosseous adipocytic tumor of the mandible. Angiolipoma is a unique variant of lipoma composed of mature fat cells with proliferating capillaries.

Case Report: An asymptomatic 63-year-old patient attended a dental check-up, and a bordered radiolucency was incidentally found on the lower left side of the mandibular body. Conservative enucleation was performed with significant intraoperative bleeding. The preliminary diagnosis was central giant cell granuloma (CGCG). Histological analysis revealed that the lesion consisted of lobules of mature adipocytes interspersed with numerous vascular spaces. These findings were consistent with the diagnosis of intraosseous angiolipoma of the mandible. To the best of our knowledge, this represents the eighth case to be reported in the literature, showcasing the rarity of this lesion.

Conclusion: The diagnosis of intraosseous angiolipoma in the jaws poses numerous difficulties and requires detailed histopathological examination. It is essential for oral pathologists to be familiar with such rare lesions to guarantee an accurate diagnosis. Conservative surgical enucleation of the lesion is usually the preferred treatment approach. Recognizing these atypical variants will assist pathologists in optimizing patient care through a precise and timely diagnosis and intervention.

Corresponding Information: **Mohamadreza Yegane,** School of Dentistry, Tehran University of Medical Sciences, Tehran, Iran.
Email: MR-yegane@student.tums.ac.ir

Copyright © 2026. This is an open-access article distributed under the terms of the **Creative Commons Attribution 4.0 International License (CC BY 4.0)**, which permits unrestricted use, distribution, and reproduction in any medium, provided the original work is properly cited. The license also allows users to adapt, remix, transform, and build upon the material for any purpose, including commercial use.

Introduction

Angiolipomas are benign, slow-growing tumors composed of mature adipose tissue with a prominent vascular component. They represent 5%–17% of all lipomas found in the oral cavity (1).

Although the underlying mechanisms of angiolipoma development are still unclear, previous studies have highlighted several factors that may contribute to their formation, including trauma, hormonal changes during puberty, fatty degeneration of pre-existing hemangiomas, and vascular proliferation within congenital lipomas (2).

Angiolipomas are primarily found on the forearms, trunk, and upper arms, and they rarely occur in the head and neck region (3). Oral angiolipomas are relatively uncommon and mainly involve the major salivary glands, buccal mucosa, lip, tongue, vestibule, and floor of the mouth (1, 4-9).

Since the first case reported by Polte et al. in 1976 (4), only six mandibular intraosseous angiolipomas have been documented in the literature (1, 4-9), reflecting how infrequently this lesion is observed.

Here, we present an additional case of intramandibular angiolipoma and discuss its clinical, radiographic, and histopathologic features to contribute further to the limited understanding of this unusual entity.

Case Report

Clinical and Radiographic Findings: Incidentally, a radiolucent lesion in the mandible was identified on the panoramic radiograph (Fig. 1); however, no clinical evidence of mandibular volumetric expansion or neurological abnormalities was observed. Marked by well-defined corticated borders, the radiolucent lesion was located on the lower left side of the mandibular body. It extended from the mesial root of the first molar to the distal aspect of the root of the canine and from the apical part of the roots to the lower border of the mandible. Moreover, CBCT imaging did not reveal any signs of cortical perforation.

Surgical Procedure: An intraoral approach was employed to surgically assess the lesion; an excisional biopsy was performed through a vestibular incision, with preservation of the inferior alveolar nerve. Along with significant intraoperative hemorrhage, a brownish, friable, vascularized mass was removed from the bone

cavity (Fig. 2). The preliminary differential diagnosis included central giant cell granuloma (CGCG).



Fig. 1. Preoperative panoramic radiograph, revealing a well-defined radiolucent lesion in the left posterior mandibular body region, extending from the mesial root of the first molar to the canine root, with no signs of cortical perforation.

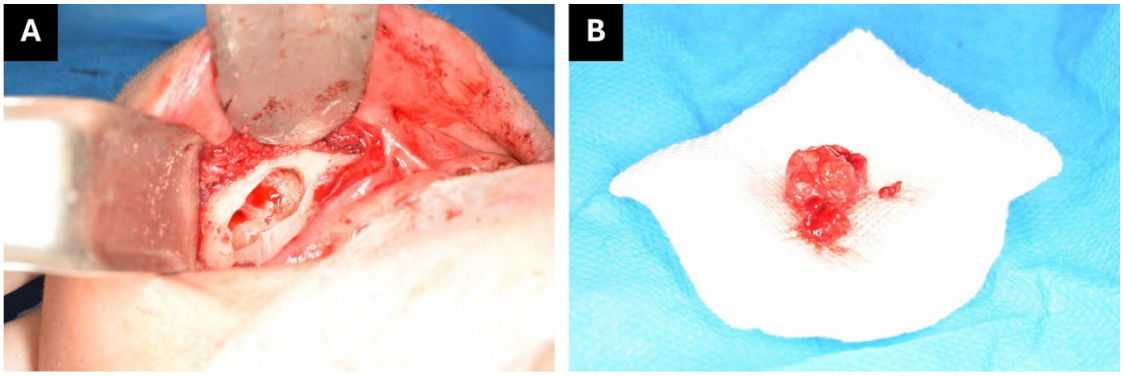

Fige 2. Intraoperative images. (A) Intraoral approach with vestibular incision exposing the bone cavity during enucleation. (B) A brownish, friable, highly vascularized mass (measuring approximately 21 × 16 × 8 mm) was removed from the bone cavity.

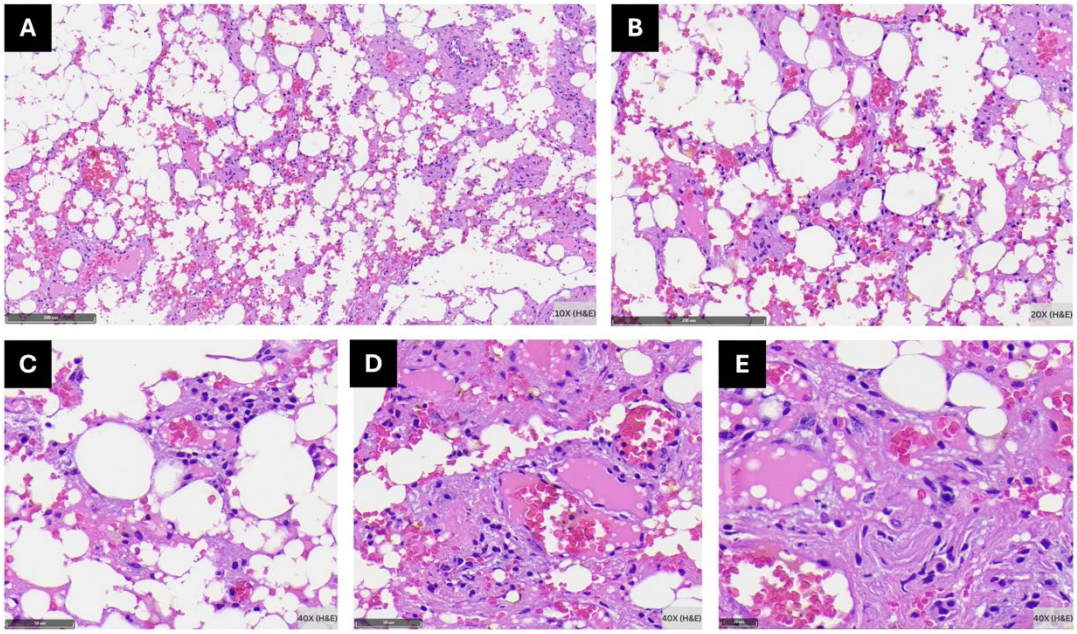

Fig. 3. Histopathologic features of the lesion. (A–B) Low-power views (10×, 20×) showing mature adipocytes interspersed with vascular spaces. (C–E) High-power views (40×) highlighting endothelium-lined vessels containing red blood cells and fibrin thrombi, scattered mast cells, and surrounding fibrous connective tissue (H&E stain).

Histopathological Analysis: Histopathology using hematoxylin and eosin (H&E) staining revealed that the lesion consisted of well-defined lobules of neoplastic adipocytes interspersed with fibrous tissue and numerous endothelium-lined spaces, which were surrounded by mast cells and contained erythrocytes along with abundant fibrinous microthrombi (Fig. 3). The presence of these characteristics was consistent with a diagnosis of angiolipoma.

Follow-up: At six months, panoramic radiographs demonstrated progressive bone regeneration (Fig. 4); there were no clinical indications of recurrence.

Table 1. Reported cases of intraosseous angiolipoma of the mandible in the literature, summarizing patient demographics, lesion location, clinical presentation, diagnostic features, management, and follow-up.

Author, year	Age, sex	Location	Clinical features	Radiographic presentation	Provisional diagnosis	Treatment	Follow-up
Polte et al., 1976 (4)	39, M	Left body of the mandible	Hypesthesia of the left lower lip and chin for one week's duration	Well-circumscribed radiolucency	Myxoma or a lipoma (Based on intraoperative findings)	Conservative surgical removal of the mass	8 months with no signs of recurrence
Lewis et al., 1980 (5)	50, F	Left body of the mandible	Asymptomatic	Multilocular radiolucency with nondistinct borders	Ameloblastoma or a multilocular odontogenic cyst	Incisional biopsy, no further treatment	Not reported
Manganaro et al., 1994 (6)	51, M	Left mandibular ramus	Asymptomatic	Moderately well-defined, mixed radiolucent/radiopaque area	Not reported	Incisional biopsy, no further treatment	1 year with no change in the size of the lesion
Hemavaty et al., 2012 (7)	21, F	Left body of the mandible	Painless fixed swelling	Ground glass radiolucency with distinct borders	Vascular malformation, hemangioma, and central giant cell granuloma	Excision followed by reconstruction	Not reported
Tomo et al., 2020 (8)	62, M	Right body of	Asymptomatic	Unilocular well-defined radiolucency	Periapical cyst, odontogenic keratocyst,	Conservative surgical	1 year with no recurrence

Author, year	Age, sex	Location	Clinical features	Radiographic presentation	Provisional diagnosis	Treatment	Follow-up
		the mandible			uncystic ameloblastoma	removal of the mass	
Nor et al., 2022 (9)	58, F	Extending from the right mandibular body to the mid portion of the right mandibular ramus	Asymptomatic	Localized, multilocular radiolucency, with scalloped borders	Ameloblastoma	Conservative enucleation	Not reported
Agnone et al., 2023 (1)	66, M	Right body of the mandible	Asymptomatic	Well-defined radiolucency	Odontogenic keratocyst, odontogenic myxoma, early benign cemento-osseous lesion, hemangiomas, and central giant cell granuloma	Conservative enucleation	1 year with no radiographic or clinical signs of recurrence
Present Case	63, F	Left body of the mandible	Asymptomatic	Well defined radiolucency with distinct borders	Central giant cell granuloma	Excisional biopsy	6 months with no recurrence

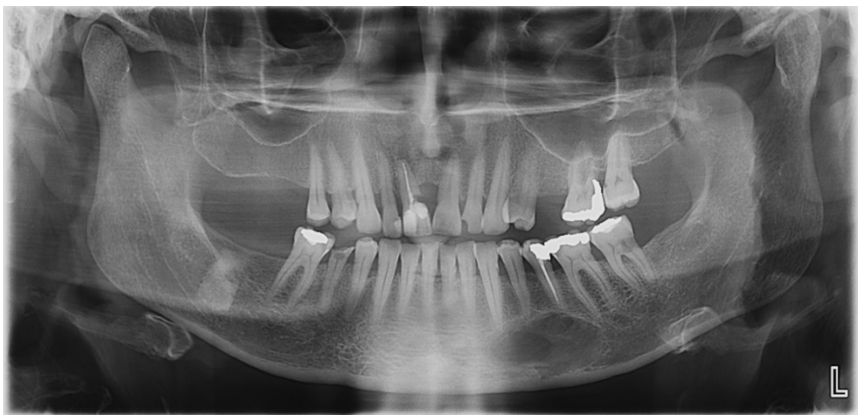

Fig. 4. Follow-up panoramic radiograph taken six months postoperatively. Radiographic evidence of bone regeneration in the previously affected area is evident.

Discussion

Lipoma is a slow-growing benign tumor of adipose tissue that can occur in nearly any part of the body. Soft-tissue lipoma is a relatively common tumor, whereas intraosseous lipoma is extremely rare despite the presence of adipocytes in the bone marrow (10). When the vascular component within a lipoma is prominent, the tumor is more accurately classified as an angiolipoma (7). Angiolipomas are benign lipomatous lesions that account for 6%–17% of all lipomas (1).

Intraosseous angiolipoma of the mandible is an exceptionally rare entity, with the present case, to the best of our knowledge, representing the eighth reported in the literature (Table 1). In total, there were four cases in men and four in women. The patients' ages ranged from 21 to 66 years. Including the current case, there were a total of four diagnoses in the left body of the mandible, two in the right mandibular body, one in the left mandibular ramus, and one extending from the right mandibular body to the right mandibular ramus. From a clinical standpoint, most cases, including the present one, were asymptomatic. However, intraosseous lipomas of the jaw can sometimes cause symptoms such as paresthesia or swelling, depending on their location and size.

The etiology of intraosseous angiolipomas is not fully understood. Several theories have been proposed, including a history of trauma, hormonal changes leading to the development of fatty tissue during puberty, fatty degeneration within pre-existing hemangiomas, and vascular proliferation within pre-existing lipomas. These

factors may all play a role in the development of intraosseous angiolipomas (2).

Most adipocytic tumors exhibit characteristic or specific genetic abnormalities, which are known or presumed to be strong driver mutations. However, little is known about nucleotide-level mutations and the potential impact on the biology of these tumors (11). In a study using whole-exome sequencing, Hovfander et al. discovered that 80% of angiolipomas, unlike other conventional benign adipocytic neoplasms, harbored mutations in the protein kinase D2 (PRKD2) gene. This finding suggests that altered PRKD2 signaling in adipocytic cells drives tumorigenesis and, consistent with its critical role in angiogenesis, promotes the vascular proliferation that is characteristic of angiolipomas (11).

The clinical and radiographic features of intraosseous mandibular angiolipomas resemble those of various odontogenic tumors and cysts, including central giant cell granuloma (CGCG), odontogenic keratocyst, cemento-osseous lesions, odontogenic myxoma, hemangioma, arteriovenous malformations, aneurysmal bone cyst, and hemorrhagic bone cyst (1).

The macroscopic surgical features observed in all previous cases included a friable (jelly-like), yellowish tumoral mass with potential bleeding, which may suggest the diagnosis of angiolipoma. However, these characteristics are not specific to the tumor. We suggest that in such cases, surgeons consider angiolipoma as a differential diagnosis. However, due to its rarity and similar radiographic features to odontogenic tumors and cysts, it should not be the primary clinical diagnosis (8).

Histological findings are essential for diagnosing intraosseous angiolipomas. Microscopic analysis typically reveals four key features that would favor an angiolipoma diagnosis: (i) mature neoplastic adipocytes, (ii) numerous vascular spaces filled with erythrocytes, and (iii) fibrinous microthrombi, surrounded by (iv) fibrous tissue that contains mast cells.

Conservative enucleation and curettage remain the treatment of choice, as recurrence is highly unlikely despite limited reported follow-up (1).

Acknowledgments

The authors would like to express their gratitude to the Department of Oral and Maxillofacial Pathology, School of Dentistry, Tehran University of Medical Sciences, for their valuable technical assistance in slide scanning.

Authors' Contributors

All authors contributed equally to the conceptualization, design, and execution of this study.

Data Availability

The datasets generated and analyzed during the current study are not publicly available; however, the data can be shared for research and authentication purposes upon reasonable request.

Funding

This research received no specific grant from any funding agency in the public, commercial, or not-for-profit sectors.

Ethics Approval

All identifying patient information was removed to protect privacy. Written informed consent for publication (text and images) was obtained from the patient.

Conflict of Interest

The authors declared no conflict of interest.

References

1. Agnone AM, Boffano P, Cavarra F, Andreis M, Ruga E, Zanellato I, et al. Intraosseous angiolipoma of the mandible. J Stomatol Oral Maxillofac Surg. 2023; 124(1s):101329. [DOI:10.1016/j.jormas.2022.11.005] [PMID]
2. Arenaz Búa J, Luáces R, Lorenzo Franco F, García-Rozado Á, Crespo Escudero JL, Fonseca Capdevila E, et al. Angiolipoma in head and neck: report of two cases and review of the literature. International Journal of Oral and Maxillofacial Surgery. 2010;39(6):610-5. [DOI:10.1016/j.ijom.2009.12.021] [PMID]
3. Bhuyan SK, Bhuyan R, Debta P, Debta FM. Non-Infiltrating Angiolipoma of Floor of Mouth-A Rare Case Report and Literature Review. J Clin Diagn Res. 2017;11(2):Zd03-zd5. [PMID] [PMCID] [DOI:10.7860/JCDR/2017/22407.8964]
4. Polte HW, Kolodny SC, Hooker SP. Intraosseous angiolipoma of the mandible. Oral Surg Oral Med Oral Pathol. 1976;41(5):637-43. [DOI:10.1016/0030-4220(76)90316-9] [PMID]
5. Lewis DM, Brannon RB, Isaksson B, Larsson A. Intraosseous angiolipoma of the mandible. Oral Surg Oral Med Oral Pathol. 1980;50(2):156-9. [DOI:10.1016/0030-4220(80)90204-2] [PMID]
6. Manganaro AM, Hammond HL, Williams TP. Intraosseous angiolipoma of the mandible: a case report and review of the literature. J Oral Maxillofac Surg. 1994;52(7):767-9. [DOI:10.1016/0278-2391(94)90498-7] [PMID]

7. Hemavathy S, Roy S, Kiresur A. Intraosseous angiolipoma of the mandible. J Oral Maxillofac Pathol. 2012;16(2):283-7. [DOI:10.4103/0973-029X.99091] [PMID] [PMCID]

8. Tomo S, Armelin AML, Miyahara GI, Stefanini AR, Bortoluzo PH, Simonato LE. Intraosseous angiolipoma of the mandible: An unexpected diagnosis. J Stomatol Oral Maxillofac Surg. 2020;121(4):463-5. [DOI:10.1016/j.jormas.2020.03.007] [PMID]

9. Nor DF, Cuellar DJPC, Timmons DS, Wongpattaraworakul DW, Steward-Tharp DS, Austin DB, et al. Intraosseous angiolipoma of the mandible: case report of a rare entity. Oral Surgery, Oral Medicine, Oral Pathology and Oral Radiology. 2022;133(5):e152. [DOI:10.1016/j.oooo.2021.12.091]

10. Oringer MJ. Lipoma of the mandible. Oral Surg Oral Med Oral Pathol. 1948;1(12):1134. [DOI:10.1016/0030-4220(48)90035-8] [PMID]

11. Hofvander J, Arbajian E, Stenkula KG, Lindkvist-Petersson K, Larsson M, Nilsson J, et al. Frequent low-level mutations of protein kinase D2 in angiolipoma. J Pathol. 2017;241(5):578-82. [DOI:10.1002/path.4865] [PMID]