Iranian Journal of Pathology | ISSN: 2345-3656

Synchronous Diffuse Large B-Cell Lymphoma Identified During Retroperitoneal Lymph Node Dissection for Stage III Clear Cell Renal Cell Carcinoma: A Case Report

Reihane Chegini[1], Mandana Rahimi[2], Mohammad Eslami[3]*

1. *Department of Pathology, School of Medicine, Shahid Beheshti University of Medical Sciences, Tehran, Iran*
2. *Department of Pathology, Hasheminejad Kidney Center, School of Medicine, Iran University of Medical Sciences, Tehran, Iran*
3. *Department of Pathology, Emam Hossein Educational Hospital, Shahid Beheshti University of Medical Sciences, Tehran, Iran*

KEYWORDS

diffuse large B-cell lymphoma; clear cell renal cell carcinoma; synchronous malignancies; retroperitoneal lymph node dissection; immunohistochemistry; R-CHOP; pembrolizumab

Scan to discover online

Main Subjects:
Neuropathology

Received 30 Sep 2025;
Accepted 07 Feb 2026;
Published Online 25 Feb 2026;

10.22034/ijp.2026.2072118.3540

ABSTRACT

Background & Objective: Non-Hodgkin lymphoma (NHL) and renal cell carcinoma (RCC) are common malignancies, and survivors of either are at increased risk of second primary cancers. Synchronous presentation of diffuse large B-cell lymphoma (DLBCL) with clear cell RCC (ccRCC) is rare.

Case Report: An 82-year-old man presented with right flank pain and gross hematuria. Imaging showed an 11.3 × 8.0 cm enhancing right renal mass with extension into the renal vein and inferior vena cava and multiple para-aortic lymphadenopathies. He underwent radical right nephrectomy with perirenal and retroperitoneal lymph-node dissection. Kidney histology showed ccRCC, ISUP grade 4, with extension to the renal sinus and renal pelvis. Retroperitoneal nodes were infiltrated by large atypical B-cells positive for CD20 and PAX5 and negative for CD3, CD15, and CD30, with Ki-67 ~50%, consistent with DLBCL. A post-operative whole-body PET/CT showed no residual malignancy. Treatment and outcome: He received six cycles of R-CHOP for DLBCL and adjuvant pembrolizumab for high-risk ccRCC. He remains in complete remission four years after diagnosis.

Conclusion: This case illustrates the possibility of synchronous primary DLBCL in patients undergoing surgery for RCC. Routine pathological evaluation of dissected nodes can change staging and management.

Corresponding Information: **Mohammad Eslami,** Department of Pathology, Emam Hossein Educational Hospital, Shahid Beheshti University of Medical Sciences, Tehran, Iran. Email: mohammadeslami@sbmu.ac.ir

Copyright © 2026. This is an open-access article distributed under the terms of the **Creative Commons Attribution 4.0 International License (CC BY 4.0)**, which permits unrestricted use, distribution, and reproduction in any medium, provided the original work is properly cited. The license also allows users to adapt, remix, transform, and build upon the material for any purpose, including commercial use.

Introduction

Kidney cancer is among the most commonly diagnosed cancers, with clear cell RCC (ccRCC) accounting for approximately 80% of renal malignancies. NHL represents over 4% of annual cancer diagnoses. Survivors of RCC or NHL have an elevated risk of second primary malignancies. Although the coexistence of RCC and NHL in the same patient is higher than expected compared with the general population, this is often attributed to tumor- or treatment-related immunosuppression. In contrast, truly synchronous presentation of DLBCL with RCC is rare (1–6).

Case Report

An 82-year-old Iranian man presented with three months of progressively worsening right flank pain and gross hematuria, accompanied by dysuria and increased urinary frequency. He denied fever, night sweats, weight loss, anorexia, or fatigue. He had no known medical history, took no medications, and denied tobacco, alcohol, or illicit drug use.

On examination, he had a soft, nondistended abdomen with mild right costovertebral angle tenderness and no palpable organomegaly or peripheral lymphadenopathy. Digital rectal examination revealed a smooth, nontender prostate without nodules.

Laboratory evaluation showed mild anemia (hemoglobin 10.9 g/dL; reference range, 13.0–17.0 g/dL), with normal leukocyte and platelet counts, electrolytes, liver and renal function tests, coagulation parameters, inflammatory markers, and prostate-specific antigen (PSA). Urinalysis confirmed hematuria.

Color Doppler ultrasound revealed a large heterogeneous right renal mass with tumor thrombus (43 × 18 mm) propagating through the renal vein into

the inferior vena cava (IVC). Contrast-enhanced abdominopelvic MRI showed an 11.3 × 8.0 cm enhancing right anteromedial renal mass with perirenal extension into the IVC and multiple para-aortic lymphadenopathies. Multiple bilateral renal cortical cysts were present; the largest (7.5 cm) was in the lower pole of the left kidney. No hepatic or splenic lesions or ascites were noted.

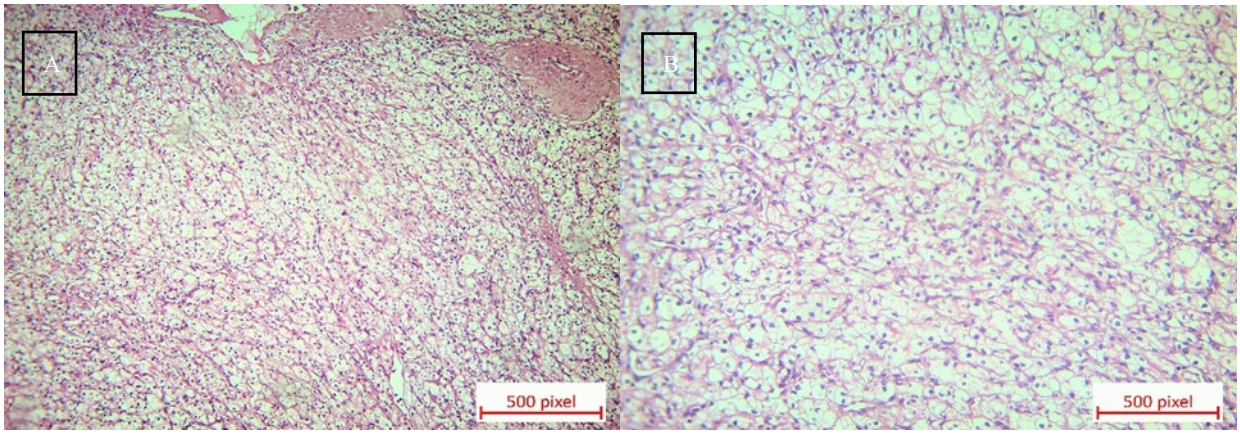

Fig. 1. (A) and (B) Histological examination of the kidney (hematoxylin & eosin). Tumor cells with hyperchromatic nuclei, clear cytoplasm, distinct cell borders, and a richly vascular stroma, consistent with clear cell renal cell carcinoma (ISUP grade 4).

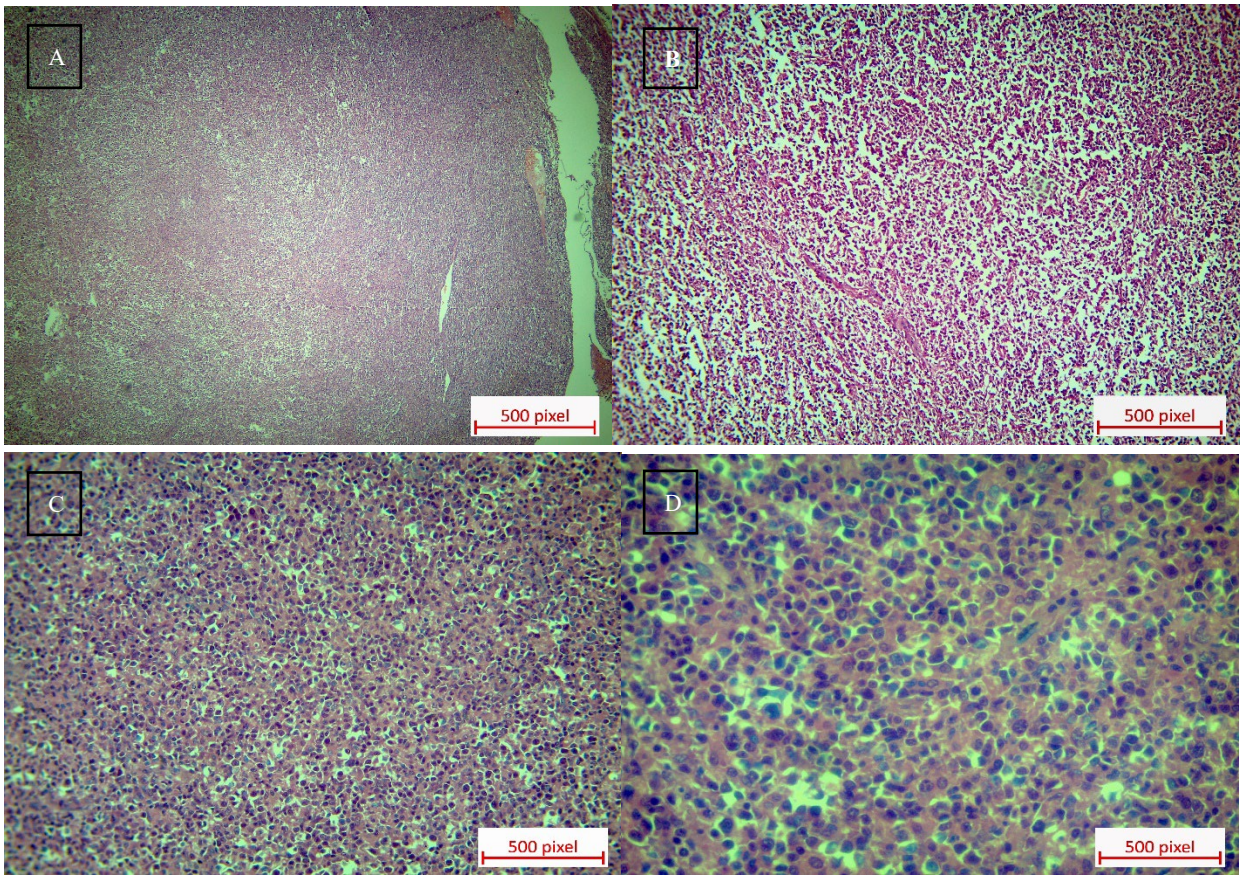

Fig. 2. A-D. Histological examination of retroperitoneal lymph nodes (hematoxylin & eosin). Diffuse effacement by medium to large atypical lymphoid cells with pleomorphic oval to round nuclei, fine chromatin, and scant cytoplasm.

The patient underwent radical right nephrectomy with perirenal and retroperitoneal lymph node dissection (RPLND). Histopathology of the renal mass demonstrated neoplastic cells with hyperchromatic nuclei, clear cytoplasm, distinct cell borders, and a richly vascular stroma, consistent with ccRCC, ISUP grade 4, with extension to the renal sinus and renal pelvis (Figure 1).

Histopathology of the dissected nodes showed effacement by sheets of medium- to large-sized atypical

lymphoid cells with fine chromatin, irregular nuclear contours, inconspicuous nucleoli, and scant basophilic cytoplasm, intermixed with mature lymphocytes and plasma cells (Figure 2). IHC showed that the neoplastic cells were CD20+ and PAX5+, CD3–, CD15–, and CD30–, with Ki-67 positivity in approximately 50% of tumor cells (Figure 3). These findings supported a diagnosis of high-grade DLBCL. There was no histologic evidence of metastatic ccRCC within the nodes, consistent with pT3aN0M0 (at least stage III) ccRCC. Because of the very limited amount of nodal tissue remaining after routine histologic processing, only a basic immunohistochemical panel could be performed. The available material was insufficient for additional markers such as CD10, BCL6, MUM1, or BCL2/MYC.

A whole-body PET/CT revealed no residual malignancy. He received six cycles of rituximab, cyclophosphamide, doxorubicin, vincristine, and prednisolone (R-CHOP) for DLBCL, alongside adjuvant pembrolizumab for high-risk ccRCC. He achieved complete clinical remission that has persisted for four years since diagnosis.

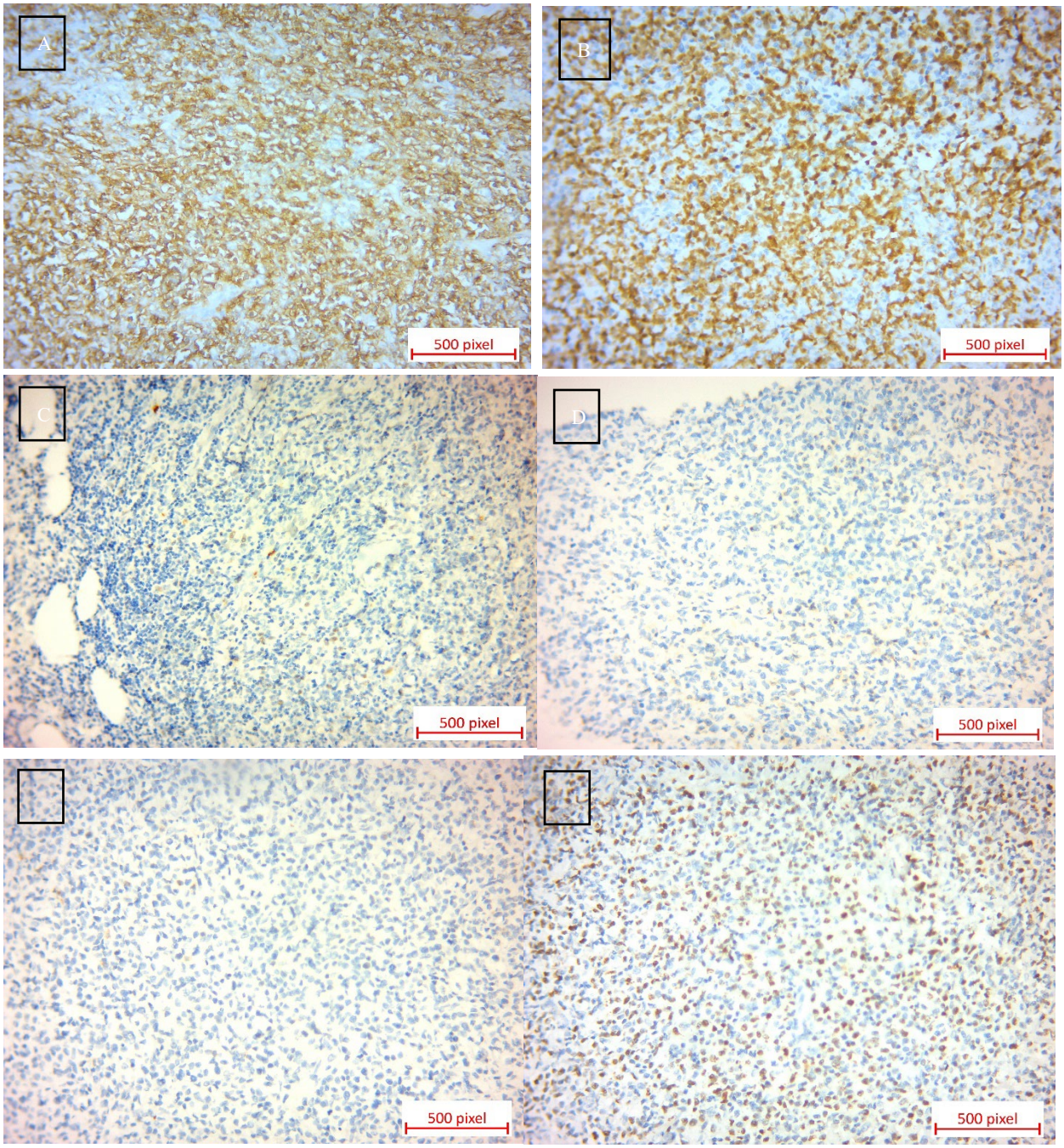

Fig. 3. Immunohistochemistry of lymph nodes. (A) CD20 positive; (B) PAX5 positive; (C–E) CD3, CD30, and CD15 negative; (F) Ki-67 positive in ~50% of neoplastic lymphoid cells.

Discussion

DLBCL is the most common NHL subtype, typically presenting with rapidly enlarging lymph nodes and B symptoms; extranodal involvement of the kidneys, adrenals, central nervous system, bone, and soft tissues is well recognized (7).

Both RCC and NHL are common neoplasms, and both are curable when diagnosed and treated in the early stages (8). Patients with either RCC or NHL are at an increased risk of developing secondary malignancies (9,10). The secondary cancers frequently associated with RCC include solid tumors of the bladder, prostate, rectum, and lung (9–12). Similarly, patients with NHL are at an increasingly higher risk of developing secondary malignancies, including an unexpectedly elevated risk of developing RCC (13). However, this correlation is generally attributed to the immunosuppressive effects caused by cancer, chemotherapy, and radiation therapy, or to underlying immunodeficiency disorders, which lead to a subsequent risk of developing malignancy (14–16). Although secondary malignancies are increasingly seen after NHL, the occurrence of DLBCL and RCC simultaneously in one patient is unexpected (9–11). Furthermore, as seen in our patient, the simultaneous development of intra-abdominal DLBCL and RCC is an extraordinarily rare clinical phenomenon with an elusive mechanism and pathogenesis.

A literature review revealed multiple previous studies on the correlation between RCC and NHL. Nishikubo et al. reported a 63-year-old man who developed RCC eight years after successful treatment for NHL (17). Rabbani et al. also found a positive correlation between RCC and the subsequent development of NHL (18). In a longitudinal cohort study of 763 patients with early-stage RCC who underwent surgical resection of the tumor, 209 patients developed a second primary malignancy (27.4%) within 10 years of their operation, 19 of whom developed NHL: eight as antecedent, eight simultaneously, and three as metachronous cancers (18).

Tihan et al. also examined the potential coexistence of RCC and NHL in a study that included 1252 RCC patients and 1660 NHL patients (19). They found 15 patients with co-occurring primary neoplasms in three different patterns. The first and most common pattern was the incidental finding of low-grade renal cancer in patients with NHL. The second most common pattern was the incidental diagnosis of low-grade NHL in patients who underwent surgical resection of a renal mass. In the third pattern, RCC and NHL developed several years apart. The study concluded that common predisposing factors in these patients included underlying immunodeficiency disorders or genetic mutations leading to familial cancer predisposition (19).

Shields et al., in a study of nine patients with concurrent RCC and NHL, reported four patients who were simultaneously diagnosed with both cancers. The study highlighted the role of immune system dysregulation in patients with both RCC and NHL. They suggested that the first neoplasm induces an immunomodulatory effect, predisposing the patient to the second malignancy (20).

Generally, studies have shown that despite the sporadic nature of concurrent RCC and NHL, particularly DLBCL, their association is greater than in the general population, indicating that there may be an underlying similarity in their etiology and pathogenesis that has yet to be fully elucidated (6,20). The etiology of the simultaneous occurrence of RCC and NHL is likely multifactorial, including a combination of genetic predisposition, immunodeficiency disorders, and environmental factors (20,21). Prior studies have shown that various genetic mutations increase the risk of a second primary malignancy in NHL patients, which may occur either simultaneously or asynchronously (22). Deletions of 3p are described in 95%–98% of sporadic subtypes of ccRCC, while mutations in 11p, 13p, and deletions in 17p have been found in 33% of older RCC patients. These RCC-associated chromosomal deletions (3p, 11p, 13p, 17p) are distinct from the molecular alterations typically implicated in DLBCL pathogenesis, which more commonly involve dysregulation of MYC, BCL2, or BCL6. This distinction suggests that the coexistence of RCC and DLBCL in our patient is unlikely to arise from a shared genetic background and is more consistent with immunologic or coincidental mechanisms (22–24). Our patient had no history of chemotherapy and was not using any immunosuppressive medications, which renders the possibility of treatment-related immunosuppression inapplicable. Furthermore, he had no known immunodeficiency diseases and no history of familial cancer syndromes.

While RPLND is recommended for a subset of patients with RCC, obtaining multiple biopsies of metastatic lesions is generally not considered standard practice (2,7). However, given the potential for the concurrent presence of two primary neoplasms, it may be prudent for clinicians to obtain biopsies from both the primary tumor and the metastatic lymph nodes. This practice would increase the likelihood of detecting tumor components not present at the primary tumor site, with significant ramifications for the patient's diagnosis, treatment, and expected prognosis. This was clearly demonstrated in the case of our patient, who was found to have DLBCL simultaneously with RCC in the absence of any constitutional symptoms.

In this study, we reported incidentally found DLBCL in the retroperitoneal lymph nodes after RPLND and biopsy sampling for renal cancer. The coexistence of RCC and DLBCL is rare but not unexpected. Previous reports have shown associations of lymphoid neoplasms with solid tumors, but they have usually described secondary forms of cancer related to chemotherapy (22). To the best of our knowledge, this is a rarely reported case of simultaneous RCC and DLBCL in a patient with no history of immunodeficiency diseases, familial

cancer syndromes, or use of immunosuppressive medications.

Conclusion

Synchronous primary DLBCL can be discovered incidentally during surgery for RCC. Pathologic confirmation of nodal disease is indispensable when staging RCC. Awareness of this rare association may prevent misclassification and ensure that patients receive appropriate, potentially curative, disease-specific therapy.

Acknowledgments

The authors thank the Department of Pathology at Iran University of Medical Sciences for their support.

Authors' Contributors

All authors contributed equally to the conceptualization, design, and execution of this study.

Data Availability

The datasets generated and analyzed during the current study are not publicly available; however, the data can be shared for research and authentication purposes upon reasonable request.

Funding

This research received no specific grant from any funding agency in the public, commercial, or not-for-profit sectors.

Ethics Approval

All identifying patient information was removed to protect privacy. Written informed consent for publication (text and images) was obtained from the patient.

Conflict of Interest

The authors declared no conflict of interest.

References

1. Sheets SSF. Kidney and renal pelvis cancer. Bethesda (MD): National Cancer Institute; 2015.
2. Rini BI, Campbell SC, Escudier B. Renal cell carcinoma. Lancet. 2009 Mar 28;373(9669):1119-32. [DOI:10.1016/S0140-6736(09)60229-4] [PMID]
3. Siegel RL, Miller KD, Fuchs HE, Jemal A. Cancer statistics, 2022. CA Cancer J Clin. 2022 Jan;72(1):7-33. [DOI:10.3322/caac.21708] [PMID]
4. Travis LB, Curtis RE, Glimelius B, Holowaty E, van Leeuwen FE, Lynch CF, et al. Second cancers among long-term survivors of non-Hodgkin's lymphoma. J Natl Cancer Inst. 1993 Dec 1;85(23):1932-7. [DOI:10.1093/jnci/85.23.1932] [PMID]
5. Tihan T, Filippa DA. Coexistence of renal cell carcinoma and malignant lymphoma. A causal relationship or coincidental occurrence? Cancer. 1996 Jun 1;77(11):2325-31. [DOI:10.1002/(SICI)1097-0142(19960601)77:113.0.CO;2-Y]
6. Fernandez-Pello S, Rodriguez Villamil L, Gonzalez Rodriguez I, Venta V, Cuervo J, Menéndez CL. Lymph node non-Hodgkin's lymphoma incidentally discovered during a nephrectomy for renal cell carcinoma. World J Clin Cases. 2013 Jun 16;1(3):121-3. [DOI:10.12998/wjcc.v1.i3.121] [PMID] [PMCID]
7. Liu Y, Barta SK. Diffuse large B-cell lymphoma: 2019 update on diagnosis, risk stratification, and treatment. Am J Hematol. 2019 May;94(5):604-16. [DOI:10.1002/ajh.25460] [PMID]
8. Ohsawa M, Hashimoto M, Yasunaga Y, Shingu N, Aozasa K. Characteristics of non-Hodgkin's lymphoma complicated by renal cell malignancies. Oncology. 1998 Sep-Oct;55(5):482-6. [DOI:10.1159/000011899] [PMID]
9. Greenberg RS, Rustin ED, Clark WS. Risk of genitourinary malignancies after cancer of the prostate. Cancer. 1988 Jan 15;61(2):396-401. [DOI:10.1002/1097-0142(19880115)61:23.0.CO;2-F] [PMID]
10. Pirani M, Marcheselli R, Marcheselli L, Bari A, Federico M, Sacchi S. Risk for second malignancies in non-Hodgkin's lymphoma survivors: a meta-analysis. Ann Oncol. 2011 Sep;22(9):1845-58. [DOI:10.1093/annonc/mdq697] [PMID]
11. Kantor AF, McLaughlin JK, Curtis RE, Flannery JT, Fraumeni JF Jr. Risk of second malignancy after cancers of the renal parenchyma, renal pelvis, and ureter. Cancer. 1986 Sep 1;58(5):1158-61. [DOI:10.1002/1097-0142(19860901)58:53.0.CO;2-V] [PMID]

12. Begg CB, Zhang ZF, Sun M, Herr HW, Schantz SP. Methodology for evaluating the incidence of second primary cancers with application to smoking-related cancers from the Surveillance, Epidemiology, and End Results (SEER) program. Am J Epidemiol. 1995 Sep 15;142(6):653-65. [DOI:10.1093/oxfordjournals.aje.a117689] [PMID]

13. Anderson CM, Pusztai L, Palmer JL, Cabanillas F, Ellerhorst JA. Coincident renal cell carcinoma and non-Hodgkin's lymphoma: The M. D. Anderson experience and review of the literature. J Urol. 1998;159(3) :714-7. [DOI:10.1016/S0022-5347(01)63708-X] [PMID]

14. Zabrocka E, Chłosta P, Gomuła A, Bryniarski P, Dębiński P, Drewniak T, et al. Simultaneous occurrence of non-Hodgkin lymphoma, renal cell carcinoma and oncocytoma: A case report. Mol Clin Oncol. 2016 Oct;5(4):455-7. [DOI:10.3892/mco.2016.970] [PMID] [PMCID]

15. Tabacu E, Galiē N, Mitrea M, Stoicescu I, Zăvoianu C. Cancere primitive multiple cu diferite localizări și tipuri histologice. Caz clinic [Multiple primary cancers with different localizations and histologic types. Clinical case]. Pneumologia. 2003;52(1):51-3. Romanian.

16. Márquez AM, Mañas JU, Amores FR, Aguilar RC, Ortega MJ, Leiva CV, et al. Carcinoma renal cromófobo y linfoma centrocítico sincrónicos [Synchronous chromophobe renal carcinoma and centrocytic lymphoma]. Arch Esp Urol. 2003 May;56(4):415-7. Spanish.

17. Nishikubo CY, Kunkel LA, Figlin R, Belldegrun A, Rosen P, Elashoff R, et al. An association between renal cell carcinoma and lymphoid malignancies. A case series of eight patients. Cancer. 1996;78(11):2421-6. [DOI:10.1002/(SICI)1097-0142(19961201)78:113.0.CO;2-1]

18. Rabbani F, Reuter VE, Katz J, Russo P. Second primary malignancies associated with renal cell carcinoma: influence of histologic type. Urology. 2000;56(3):399-403. [DOI:10.1016/S0090-4295(00)00682-8] [PMID]

19. Tihan T, Filippa DA. Coexistence of renal cell carcinoma and malignant lymphoma: a causal relationship or coincidental occurrence? Cancer. 1996;77(11):2325-31. [DOI:10.1002/(SICI)1097-0142(19960601)77:113.0.CO;2-Y]

20. Shields LB, Rezazadeh Kalebasty A. Concurrent renal cell carcinoma and hematologic malignancies: Nine case reports. World J Clin Oncol. 2020;11(8):644-54. [DOI:10.5306/wjco.v11.i8.644] [PMID] [PMCID]

21. Kunthur A, Wiernik PH, Dutcher JP. Renal parenchymal tumors and lymphoma in the same patient: case series and review of the literature. Am J Hematol. 2006 Apr;81(4):271-80. [DOI:10.1002/ajh.20533] [PMID]

22. Uz B, Dolasik I, Ucer O, Dagli AF, Simsek S. Chronic lymphocytic lymphoma and concomitant renal cell carcinoma (Clear Cell Type): Review of the literature. Leuk Res Rep. 2016;6:8-10. [DOI:10.1016/j.lrr.2016.06.002] [PMID] [PMCID]

23. Anglard P, Tory K, Brauch H, Weiss G, Latif F, Merino M, et al. Molecular analysis of genetic changes in the origin and development of renal cell carcinoma. Cancer Res. 1991;51(4):1071-7.

24. Gnarra JR, Tory K, Weng Y, Schmidt L, Wei MH, Li H, et al. Mutations of the VHL tumour suppressor gene in renal carcinoma. Nat Genet. 1994;7(1):85-90. [DOI:10.1038/ng0594-85] [PMID]