Iranian Journal of Pathology | ISSN: 2345-3656

Immunohistochemical Expression of HLA Classes I and II in Neonatal Cholestatic Liver Disease

Doha Maher Taie[1*], Salma Abdel Megeed Nagi[2,3], Sally Waheed Elkhadry[4], Yahya Fayed[5], Mohamed Mohamady [1], Walaa Gaber El Gendy [1]

1. *Department of Pathology, National Liver Institute, Menoufia University, Egypt*
2. *Pediatric Hepatology, Gastroenterology, and Nutrition Department, National Liver Institute, Menoufia University, Shebin El-Kom, Egypt*
3. *Faculty of Medicine, King Salman International University, El Tor Branch, Sahely Road, South Sinai, Egypt*
4. *Department of Epidemiology and Preventive Medicine, National Liver Institute, Menoufia University, Egypt*
5. *Hepatopancreaticobiliary surgery, National Liver Institute, Menoufia University, Egypt*

KEYWORDS

Neonatal cholestasis, Biliary atresia, Progressive familial intrahepatic cholestasis, Idiopathic neonatal hepatitis.

Scan to discover online

Main Subjects:
GI, Liver & Pancreas Pathology

Received 11 Aug 2025;
Accepted 02 Jan 2026;
Published Online 26 Feb 2026;

10.22034/ijp.2025.2068085.3503

ABSTRACT

Background & Objective: Neonatal cholestasis (NC) is a significant clinical condition involving hepatobiliary dysfunction, often accompanied by immunological alterations regardless of etiology. Human leukocyte antigens (HLA) molecules, particularly classes I and II, play roles in autoimmune liver diseases. Previous studies showed inconsistent results regarding their expression in hepatocytes and cholangiocytes under normal and pathological conditions. This study aimed to evaluate immunohistochemical expression of HLA I and II in NC.

Methods: A retrospective analysis included 45 pediatric NC cases: 27 with biliary atresia (BA), 13 with progressive familial intrahepatic cholestasis (PFIC), and 5 with idiopathic neonatal hepatitis (INH). Twenty normal liver samples from adult transplant donors served as controls. Immunohistochemistry was used to evaluate HLA I and II expression in hepatocytes and cholangiocytes.

Results: Control livers lacked detectable HLA I and II expression. In NC cases, HLA I was expressed in hepatocytes (84.4%) and all cholangiocytes, while HLA II was expressed in both cell types across all cases. BA cases showed significantly higher cholangiocyte expression of HLA I ($p = 0.001$) and II ($p < 0.001$) compared to PFIC and INH. HLA I expression was linked to cholangiocyte proliferation ($p = 0.005$) and inversely with lobular inflammation ($p = 0.027$). Strong HLA II expression in hepatocytes correlated with severe portal inflammation ($p = 0.048$), while in cholangiocytes, to proliferation, neutrophilic cholangitis ($p = 0.05$), and mild lobular inflammation ($p = 0.043$).

Conclusion: HLA I and II are upregulated in NC, especially in BA, which correlates with disease severity, suggesting a role in pathogenesis.

Corresponding Information: **Doha Maher Taie**, Department of pathology, National Liver Institute, Menoufia University, Egypt. Email: dr_dohamaher@yahoo.com

Copyright © 2026. This is an open-access article distributed under the terms of the **Creative Commons Attribution 4.0 International License (CC BY 4.0)**, which permits unrestricted use, distribution, and reproduction in any medium, provided the original work is properly cited. The license also allows users to adapt, remix, transform, and build upon the material for any purpose, including commercial use.

Introduction

Neonatal cholestasis (NC) is an important hepatobiliary disorder in infancy characterized by impaired bile excretion and conjugated hyperbilirubinemia (1,2). It encompasses several etiologies including biliary atresia (BA), progressive familial intrahepatic cholestasis (PFIC), and idiopathic neonatal hepatitis (INH), which represent the most common subtypes (3–5). The underlying mechanisms of these conditions remain complex and multifactorial, involving genetic, infectious, and immune-mediated processes that lead to chronic bile duct injury and hepatocellular inflammation (6–8). The immune response, particularly the expression of human leukocyte antigens (HLA), plays a pivotal role in modulating hepatic inflammation. HLA molecules are encoded on chromosome 6 and are crucial for antigen presentation to T cells. HLA class I molecules are expressed on all nucleated cells, whereas class II molecules have more restricted expression and typically require activation by cytokines such as interferon-γ (IFN-γ) (9). Class I molecules are crucial for recognizing and eliminating virally infected or transformed cells, whereas class II molecules orchestrate adaptive immune responses (9-11). Previous research on hepatic HLA expression has yielded conflicting results. Calmus et al. demonstrated that cholestasis itself can trigger aberrant HLA class I expression on hepatocytes even in the absence of immune activation (12). Conversely, Barnes et al. and studies using the rotavirus-induced (RRV) biliary

atresia model reported cytokine-driven upregulation of both HLA classes I and II in cholangiocytes, implicating an immune-mediated mechanism (13). These inconsistencies highlight the need for clarification of HLA expression patterns in neonatal cholestatic diseases based on human liver tissue. Therefore, the present study aimed to investigate the immunohistochemical expression of HLA classes I and II in different subtypes of neonatal cholestasis and to correlate their expression with histopathological features, to better understand the immunopathological basis and potential prognostic relevance of HLA upregulation in these conditions.

Materials and Methods

This retrospective study analyzed consecutive 45 liver tissue samples from pediatric patients diagnosed with NC alongside 20 normal liver specimens serving as a control group (11). Control group were obtained from potential adult liver transplant donors (age range: 18-45 years; sex distribution: 12 males, 8 females) as neonatal donor tissues are not available in our setting for ethical and practical reasons.

All specimens were liver biopsies previously obtained through a Tru-cut needle 14-gauge (G) by ultrasound guidance for diagnostic or management reasons. All specimens were retrieved from the Pathology Department's archives between 2022 and 2024. Complete blood count, liver function tests and abdominal ultrasonography (US) findings were retrieved from patient's medical records. Formalin fixed, paraffin embedded blocks were sectioned and stained for histopathological assessment. Two independent histopathologists evaluated the histological features, including cholangiocyte proliferation, portal tract inflammation, portal fibrosis and lobular necroinflammation, in accordance with the criteria established by Russo et al (14). The study protocol was approved by the National Liver Institute, Menoufia university ethical committee (IRB number 00748/2025). Inclusion criteria involved patients under 18 years of age with biopsy-confirmed NC (BA, PIFC, INH). Each case was included in the overall analysis; however, only the variable with incomplete data was omitted for the particular case. Other subtypes of NC (e.g. α1-antitrypsin deficiency, tyrosinemia, bile acid synthesis defects, and Alagille syndrome) were also excluded from the analysis due to their low incidence and the limited availability of biopsy-confirmed cases in our national liver institute.

Sample size estimation: A formal sample size calculation was not feasible due to the rarity of the condition (n=45, represents all available neonatal cholestasis cases with adequate biopsy material during the study period at our institution (15).

In case of disagreement between the two independent histopathologists, a consensus was reached through joint review.

Immunohistochemical technique and interpretation:

Immunohistochemical staining was performed using a streptavidin-biotin amplification method. Sections were incubated with monoclonal mouse antibodies targeting HLA class I (Abcam, Cambridge, UK; Ref; ab70328; dilution 1:100) and HLA class II (Santa Cruz Biotechnology, Texas, USA; Ref; sc-53302; dilution 1:150). After tissue deparaffinization and rehydration, antigen retrieval was carried out using high PH EDTA solution (Dako, Ref K8000, Glostrup, Denmark), followed by cooling at room temperature, 20 minutes for each step. The slides were incubated with the primary antibodies overnight at 4°C. Secondary antibody using Ultravision detection system, anti-polyvalent HRP/DAB, ready-to-use, Neomarker was applied for 30 minutes. The staining was visualized using DAB chromogen substrate and Mayer's hematoxylin as a counterstain. All control and patient tissues were processed and stained in parallel using identical protocols (fixation time, paraffin embedding, section thickness, antigen retrieval, antibody batches, and detection reagents). Positive controls (tonsil tissue for HLA-II; lymph node for HLA-I) and negative controls (omitting the primary antibody) were included in each run.

Expression was considered positive when cytoplasmic staining was present in ≥ 10 % of hepatocytes or cholangiocytes. Staining intensity was graded on a four-point scale: 0 = negative, 1 = faint, 2 = moderate, and 3 = strong, in accordance with previously established criteria (16).

Statistics

statistical analysis was conducted using SPSS version 20.0 (IBM, Armonk, NY). Categorical variables were presented as frequencies and percentages. To compare categorical variables between two groups, the Chi-square test was applied; however, if more than 20% of expected cell counts were below 5, the Fisher's Exact Test was utilized instead. The distribution of continuous variables was evaluated using the Kolmogorov-Smirnov test to determine normality. Continuous variables were described using the range, mean, standard deviation, and median as appropriate. For comparing two sets of normally distributed continuous variables, the independent samples t-test was used. In cases involving more than two groups with non-normally distributed data, the Kruskal-Wallis test was conducted. Statistical significance was considered at a p-value less than 0.05.

Results

Clinicopathological characteristics of the studied groups

This study comprised 45 NC cases: 27 (60%) cases of BA, 13 (28.9%) cases of PFIC, and 5 (11.1%) cases of INH. Statistically significant differences were observed among these groups regarding age, with PFIC cases occurring in relatively older children (p=0.026). laboratory investigations revealed elevated serum

levels of AST and ALT predominantly in PFIC patients (p=0.023 and p=0.03, respectively), whereas GGT levels were markedly elevated in BA group (p=0.001). Histopathological evaluation demonstrated that BA cases were significantly associated with extensive cholangiocyte proliferation, the presence of neutrophilic cholangitis, and advanced stages of fibrosis (p=0.001 for all). Conversely, lobular inflammation was more pronounced in the INH group compared to the other NC subtypes (p < 0.001). Comparison of the clinicopatholoical characteristics among the studied NC subtypes were summarized in Table 1.

Table 1. Comparison of the clinicopathological characteristics among the NC subtypes studied

Variables	BA (N=27)	PFIC (N=13)	INH (N=5)	p-value	Effect Size
Age (months), Mean ± SD	2.65 ± 1.05	3.92 ± 2.24	2.2 ± 0.45	0.026*	η^2 = 0.127
Gender, n (%)				0.185	Cramer's V = 0.274
Male	9 (33.3%)	8 (61.5%)	3 (60.0%)		
Female	18 (66.7%)	5 (38.5%)	2 (40.0%)		
Total bilirubin (mg/dL), Mean ± SD	9.05 ± 4.12	10.96 ± 4.92	8.99 ± 1.77	0.259	η^2 = 0.017
Direct bilirubin (mg/dL), Mean ± SD	5.88 ± 3.26	6.5 ± 2.49	5.63 ± 2.06	0.442	η^2 -0.009
AST (U/L), Mean ± SD	223 ± 136.78	374.54 ± 208.66	350.2 ± 157.5	0.023*	η^2 = 0.131
ALT (U/L), Mean ± SD	128.44 ± 71.14	265.77 ± 199.76	207.2 ± 143.57	0.03*	η^2 = 0.119
GGT (U/L), Mean ± SD	924.67 ± 452.93	370.77 ± 490.8	222.2 ± 167.28	0.001*	η^2 = 0.369
Cholangiocyte proliferation, n (%)				0.001*	Cramer's V = 0.584
Absent	1 (3.7%)	2 (15.4%)	4 (80.0%)		
Mild	2 (7.4%)	6 (46.2%)	1 (20.0%)		
Moderate	17 (63.0%)	2 (15.4%)	0 (0.0%)		
Marked	7 (25.9%)	3 (23.0%)	0 (0.0%)		
Portal inflammation, n (%)				0.220	Cramer's V = 0.249
Mild	8 (29.6%)	7 (53.8%)	4 (80.0%)		
Moderate	17 (63.0%)	5 (38.5%)	1 (20.0%)		
Marked	2 (7.4%)	1 (7.7%)	0 (0.0%)		
Neutrophilic cholangitis, n (%)				0.001*	Cramer's V = 0.546
Absent/mild	9 (34.6%)	11 (84.6%)	5 (100.0%)		
Moderate/marked	17 (65.4%)	2 (15.4%)	0 (0.0%)		
Fibrosis, n (%)				0.001*	Cramer's V = 0.574
Mild	0 (0.0%)	5 (38.5%)	5 (100.0%)		
Moderate	15 (55.6%)	7 (53.8%)	0 (0.0%)		
Marked	12 (44.4%)	1 (7.7%)	0 (0.0%)		
Lobular inflammation, n (%)				< 0.001*	Cramer's V = 0.513
Absent	7 (25.9%)	3 (23.0%)	0 (0.0%)		
Mild	18 (66.7%)	5 (38.5%)	0 (0.0%)		
Moderate	1 (3.7%)	5 (38.5%)	5 (100.0%)		
Marked	1 (3.7%)	0 (0.0%)	0 (0.0%)		

Abbreviations: N: number; NC: neonatal cholestasis; BA: Biliary atresia; PFIC: Progressive familial intrahepatic cholestasis; INH: Idiopathic neonatal hepatitis; SD: Standard deviation; AST: Aspartate aminotransferase; ALT: Alanine aminotransferase; GGT: Gamma-glutamyl transferase; η^2: Eta squared. *Statistically significant ($p \leq 0.05$)

Notes:

- Statistical tests used include Kruskal-Wallis, Fisher's Exact, and Chi-square tests.
- All 45 cases were included in the analysis. Any variation in totals or percentages is due to missing data for specific parameters.

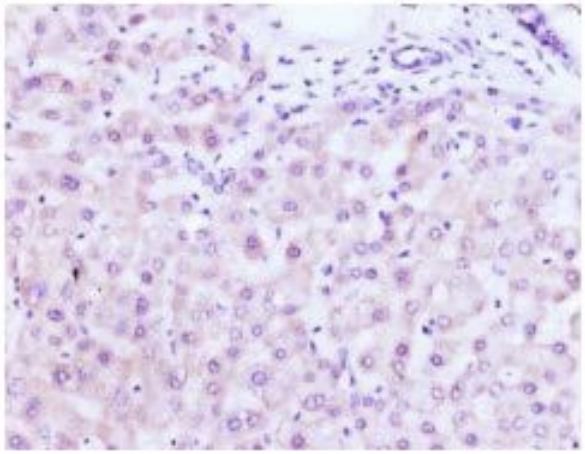

Fig.1. Negative expression of MHC class I in cholangiocytes and hepatocyte in control normal liver tissue (IHC. X200).

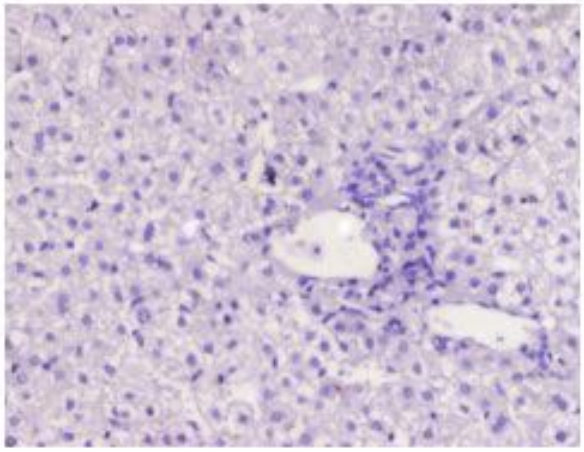

Fig. 2. Negative expression of MHC class II in cholangiocytes and hepatocyte in control normal liver tissue (IHC. X200).

Table 2. Comparison of immunohistochemical expression patterns of HLA class I and II in studied NC cases

Variables	Total NC (N=45)	BA (N=27)	PFIC (N=13)	INH (N=5)	p-value	Cramer's V
HLA I in hepatocytes, n (%)					0.416	0.249
Negative	7 (15.6%)	2 (7.4%)	4 (30.8%)	1 (20.0%)		
Faint	18 (40.0%)	12 (44.4%)	3 (23.0%)	3 (60.0%)		
Moderate	17 (37.8%)	11 (40.8%)	5 (38.5%)	1 (20.0%)		
Strong	3 (6.6%)	2 (7.4%)	1 (7.7%)	0 (0.0%)		
HLA I in cholangiocytes, n (%)					0.001*	0.407
Negative	0 (0.0%)	0 (0.0%)	0 (0.0%)	0 (0.0%)		
Faint	8 (17.8%)	2 (7.4%)	4 (30.8%)	2 (40.0%)		
Moderate	14 (31.1%)	5 (18.5%)	7 (53.8%)	2 (40.0%)		
Strong	23 (51.1%)	20 (74.1%)	2 (15.4%)	1 (20.0%)		
HLA II in hepatocytes, n (%)					0.189	0.274
Negative	0 (0.0%)	0 (0.0%)	0 (0.0%)	0 (0.0%)		
Faint	10 (22.2%)	4 (14.8%)	3 (23.2%)	3 (60.0%)		
Moderate	22 (48.9%)	13 (48.1%)	8 (61.4%)	1 (20.0%)		
Strong	13 (28.9%)	10 (37.1%)	2 (15.4%)	1 (20.0%)		
HLA II in cholangiocytes, n (%)					<0.001*	0.461
Negative	0 (0.0%)	0 (0.0%)	0 (0.0%)	0 (0.0%)		
Faint	7 (15.6%)	2 (7.4%)	4 (30.8%)	1 (20.0%)		
Moderate	18 (40.0%)	6 (22.2%)	9 (69.2%)	3 (60.0%)		
Strong	20 (44.4%)	19 (70.4%)	0 (0.0%)	1 (20.0%)		

Abbreviations: N: number; %: percentage; NC: neonatal cholestasis; BA: Biliary atresia; PFIC: Progressive familial intrahepatic cholestasis; INH: Idiopathic neonatal hepatitis; HLA: Major histocompatibility complex.

**Statistically significant ($p \leq 0.05$)

Notes:

- Tests used were Fisher's Exact and Chi-square tests.
- All 45 cases were included in the analysis. Any variation in totals or percentages is due to missing data or specific parameters rather than case exclusion.

Immunohistochemical expression of HLA class I and II

In the control group (normal liver tissue), both antigens of class I and II showed negative expression in hepatocytes and cholangiocytes (Fig. 1,2). In contrast, among NC cases, HLA class I was detected in hepatocytes in 38 cases (84.4 %) of patients and was uniformly expressed in cholangiocytes across all cases. Furthermore, HLA class II was positively expressed in both hepatocyte and cholangiocytes in 45 (100%) of the NC cases. Details regarding staining intensity were summarized in Table 2.

Comparison between NC subgroups

BA patients exhibited significantly stronger expression of both HLA class I and II in cholangiocytes (Fig. 3,4) compared to PFIC and INH cases (p= 0.001 and p<0.001, respectively; Table 2) (Fig. 5, 6).

Association between HLA class I expression and histopathological features:

The degree of HLA class I staining in cholangiocytes was significantly associated with increased cholangiocyte proliferation (p=0.005) (Fig.3). Interestingly, this expression was inversely related to the severity of lobular inflammation, being more prominent in cases with mild inflammation (p=0.027). No significant association was noted between HLA I intensity in hepatocytes and other pathological features (Table 3).

Association between HLA class II expression and histopathological features

Regarding, HLA class II, higher expression in hepatocytes was a significantly linked to severe portal tract inflammation (p=0.048) (Fig. 4). Meanwhile, in cholangiocytes, higher HLA class II expression associated with both moderate/marked cholangiocyte proliferation (Fig.4) and moderate/marked neutrophilic cholangitis (p=0.05 for both). A significant association was also observed with mild lobular inflammation (p=0.043). (Table 4).

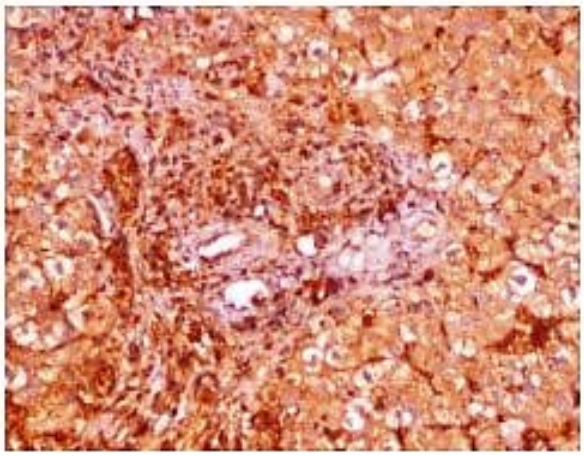

Fig.3. Strong expression of MHC class I in cholangiocytes and hepatocyte in cases of biliary atresia representing marked bile ductular proliferation and mild lobular inflammation (IHC. X200).

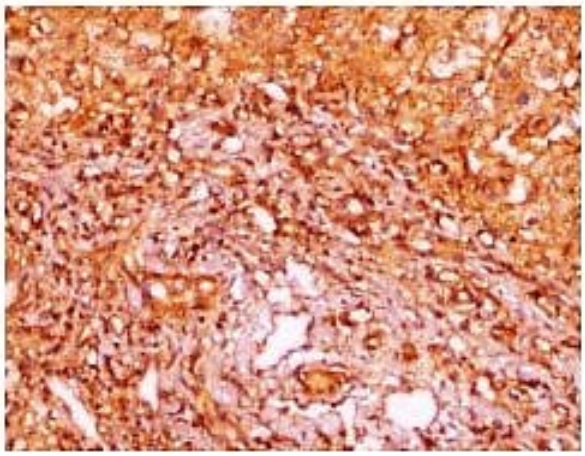

Fig.4. Strong expression of MHC class II in cholangiocytes and hepatocytes in biliary atresia associated with marked bile duct proliferation and severe portal tract inflammation (IHC. X200).

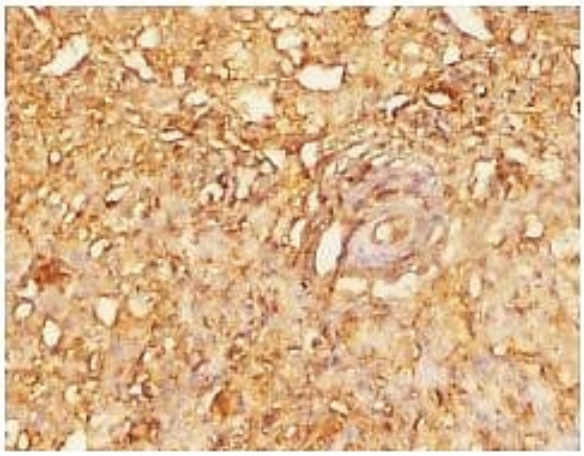

Fig.5. Milder expression of MHC class I in cholangiocytes and hepatocytes in cases of Progressive familial intrahepatic cholestasis, PFIC (IHC. X200).

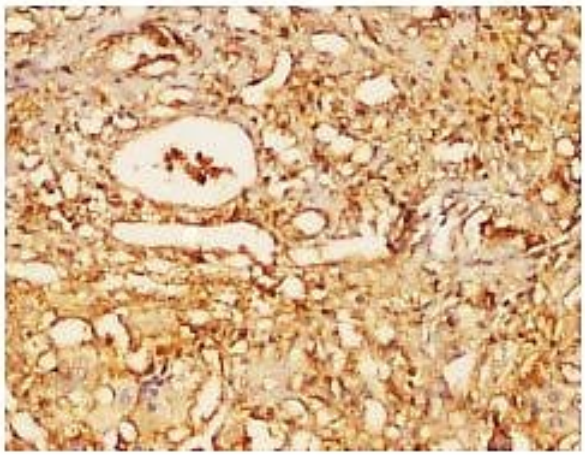

Fig.6. Milder expression of MHC class II in cholangiocytes and hepatocytes in cases of Idiopathic neonatal hepatitis, INH (IHC. X200).

Table 3. Correlation between HLA I expression intensity in hepatocytes and cholangiocytes and the histopathological features of the studied cases

	HLA I expression intensity in hepatocytes						HLA I expression intensity in cholangiocytes					
	-ve	Faint	Moderate	Strong	P value	Cramer's V	-ve	Faint	Moderate	Strong	P value	Cramer's V
Cholangiocyte proliferation					**0.655**	**0.217**					**0.005***	**0.422**
Absent	2	1	3	1			0	3	3	1		
Mild	1	6	2	0			0	1	6	2		
Moderate	2	8	8	1			0	2	5	12		
Marked	2	4	3	1			0	2	0	8		
Portal inflammation					**0.752**	**0.178**					**0.886**	**0.115**
Mild	4	6	7	2			0	4	6	9		
Moderate	3	11	8	1			0	3	7	13		
Marked	0	2	1	0			0	1	1	1		
Neutrophilic infiltrate					**0.217**	**0.272**					**0.348**	**0.215**
Absent/mild	5	10	8	3			0	5	10	11		
Moderate/ marked	2	9	8	0			0	3	4	12		
Fibrosis					**0.274**	**0.268**					**0.113**	**0.285**
Mild	2	6	2	0			0	2	6	2		
Moderate	3	9	7	3			0	5	5	12		
Severe	2	4	7	0			0	1	3	9		
Lobular inflammation					**0.671**	**0.302**					**0.027***	**0.382**
Absent	0	5	4	1			0	1	2	7		
Mild	5	9	8	1			0	2	7	14		
Moderate	2	5	3	1			0	5	5	1		
Severe	0	0	1	0			0	0	0	1		

Abbreviations: -ve: negative; Mod: moderate; HLA: Major histocompatibility complex.

* Statistically significant ($p \leq 0.05$).

Notes:

- Statistical tests used were Fisher's Exact and Chi-square tests.
- All 45 cases were included in the analysis. Any variation in totals is due to missing data or specific parameters rather than case exclusion.

Table 4. Correlation between HLA II expression intensity in hepatocytes and cholangiocytes and the histopathological features of the studied cases

	HLA II expression intensity in hepatocytes						HLA II expression intensity in cholangiocytes					
	-ve	Faint	Moderate	Strong	P value	Cramer's V	-ve	faint	Moderate	Strong	P value	Cramer's V
Cholangiocyte proliferation					**0.133**	**0.319**					**0.05***	**0.357**
Absent	0	3	2	2			0	1	5	1		
Mild	0	4	4	1			0	3	5	1		
Moderate	0	1	10	8			0	2	5	12		
Marked	0	2	6	2			0	1	3	6		
Portal inflammation					**0.255**	**0.231**					**0.489**	**0.199**
Mild	0	4	9	6			0	3	10	6		
Moderate	0	4	13	6			0	3	7	13		
Marked	0	2	0	1			0	1	1	1		
Neutrophilic infiltrate					**0.234**	**0.254**					**0.05***	**0.351**

	HLA II expression intensity in hepatocytes						HLA II expression intensity in cholangiocytes					
Absent/mild	0	7	14	5			0	4	14	8		
Moderate/marked	0	3	8	8			0	3	4	12		
Fibrosis					**0.048***	**0.295**					**0.120**	**0.269**
Mild	0	4	4	2			0	2	7	1		
Moderate	0	4	14	4			0	3	7	12		
Severe	0	2	4	7			0	2	4	7		
Lobular inflammation					**0.139**	**0.342**					**0.043***	**0.365**
Absent	0	1	7	2			0	2	2	6		
Mild	0	3	11	9			0	4	7	12		
Moderate	0	5	4	2			0	1	9	1		
Severe	0	1	0	0			0	0	0	1		

Abbreviations: -ve: negative; Mod: moderate; HLA: Major histocompatibility complex.

* Statistically significant ($p \leq 0.05$).

Notes:

- Statistical tests used were Fisher's Exact and Chi-square tests.
- All 45 cases were included in the analysis. Any variation in totals is due to missing data or specific parameters rather than case exclusion.

Discussion

Research investigating HLA expression patterns in pediatric cholestatic liver diseases remains limited and has produced inconsistent findings. The current study highlights a clear upregulation of HLA class I and II molecules in NC cases, particularly in BA, indicating an immunological contribution to disease progression and severity.

In the present study, in healthy liver tissue, neither hepatocytes nor cholangiocytes exhibited immunohistochemical expression of HLA class I and II antigens, consistent with prior recent reports indicating that baseline HLA expression in normal liver tissue is minimal (16-18). Notably, Lobo-Yeo et al found HLA class I expression without concurrent class II detection in 9 normal liver tissue samples analyzed by ultraviolet microscopy and flow cytometry (19). According to Bertolino et al, hepatocytes are capable of assembling HLA class I complexes at levels sufficient to engage lymphocytes and influence the activity of natural killer (NK) cells and T cells (21). The discrepancies among studies have been attributed primarily to methodological limitations, particularly the low sensitivity of earlier detection techniques (eg, IHC vs flow cytometry), rather than true biological differences (20). Some studies suggest that reduced or altered HLA antigen presentation by hepatocytes may serve a protective role, maintaining hepatic immune tolerance and preventing unnecessary immune-mediated damage (21).

In the current study, HLA class I was detected in hepatocytes in the majority of NC cases and was consistently expressed in cholangiocytes across all samples. Similarly, HLA class II expression was observed uniformly in both hepatocytes and cholangiocytes among the studied cohort. However, previous reports have shown variable findings. For example, Lobo-Yeo et al reported hepatocytic HLA class I expression in all studied cases but limited HLA class II expression to only 10.5% of samples (27), and others reported HLA class II expression mainly in cholangiocytes in all cases of BA and PSC, and in two-thirds of PBC cases (17,22,23). Conversely, hepatocytic HLA class II expression has been more frequently linked to inflammatory hepatitic conditions rather than cholestatic disorders (24). Notably, our results differ from those of Lobo-Yeo et al, who observed stronger HLA class I expression in INH and absent HLA class II expression in BA (20). The precise mechanisms driving the overexpression of HLA class I and II molecules in cholestatic liver diseases remain incompletely understood. Evidence from Calmus et al suggests that cholestasis itself, independent of immune mechanisms, may induce abnormal hepatocytic class I HLA expression (25). Their findings indicated that HLA class I antigens localize to both the cytoplasm and membranes of hepatocytes in cholestatic conditions, even in the absence of corresponding class II expression (25).

Our findings diverge from earlier reports, particularly those by Lobo-Yeo et al and Calmus et al, who described limited or absent HLA class II expression in hepatocytes (25,27). These discrepancies may reflect both technical and biological factors. Earlier studies often employed less sensitive detection methods such as ultraviolet microscopy or early-generation immunohistochemistry, possibly underestimating HLA expression (26). Differences in disease stage, degree of inflammation, and patient age

can strongly influence inducible HLA expression (27). In our study, both hepatocytes and cholangiocytes showed cytoplasmic staining of HLA class I and II, which likely reflects intracellular synthesis, trafficking, or pathologic retention of HLA molecules during cholestatic injury rather than surface antigen presentation. Similar cytoplasmic localization has been previously described in cholestatic and inflammatory liver diseases (24,25).

The local cytokine milieu, especially elevated IFN-γ and TNF-α levels, may upregulate HLA molecules in cholangiocytes and hepatocytes, leading to the broader expression pattern observed in BA (25,28,29). These pro-inflammatory cytokines act synergistically to enhance antigen presentation and perpetuate local immune activation. In addition, epigenetic regulation via microRNAs, particularly miR-155, has been implicated in modulating HLA expression by influencing antigen processing and inflammatory signaling. Increased hepatic miR-155 expression reported in BA correlates with enhanced immune cell infiltration and fibrosis (30,31). Collectively, cytokine and microRNA pathways likely underlie the exaggerated HLA expression seen in our cohort.

The concurrent expression of both HLA class I and II in hepatocytes and cholangiocytes observed in the present study may reflect immune system activation rather than a therapeutic effect. Similar co-expression has been reported in immune-mediated liver diseases, such as autoimmune hepatitis (AIH) and PSC (26). Inflammatory cytokines, particularly IFN-γ and TNF-α, are known to upregulate HLA class I and II molecules, promoting antigen presentation and increasing hepatocyte susceptibility to cytotoxic T lymphocyte–mediated injury (26,35). The distribution of HLA class II antigens also appears to mirror the pattern of liver injury—hepatocytic in inflammatory diseases such as viral hepatitis and AIH, and cholangiocytic in cholestatic diseases such as primary biliary cholangitis (PBC) and PSC (31). This aberrant antigen presentation may activate CD4+ helper T cells and contribute to bile duct or hepatocyte injury, reflecting ongoing immune-mediated pathology. In the present study, HLA class I expression in cholangiocytes correlated with mild lobular inflammation and cholangiocyte proliferation, indicating local immune activation and possible contribution to ductal injury and remodeling. Homozygous expression of HLA alleles has been linked to reduced CTL diversity, immune dysregulation, and prolonged disease progression (36). Aberrant HLA class II expression in bile duct microvilli in BA has been linked to poorer surgical outcomes (29), supporting its role in ongoing bile duct injury and immune-mediated pathology.

Limitations

This study has several limitations. First, the control liver tissues were obtained from adult transplant donors rather than age-matched neonates. This limitation was due to ethical and practical constraints in acquiring normal neonatal liver samples. Given that HLA, particularly class II expression, can vary with age and immune maturation, this difference should be considered when interpreting our findings. Second, the relatively small sample size may limit the statistical power to detect subtle differences among subgroups, reflecting the rarity of neonatal cholestatic liver diseases. Third, the retrospective design may introduce inherent selection bias and restrict control over clinical or technical variables. Finally, the immunohistochemical evaluation, while providing valuable localization data, is semi-quantitative in nature and could be complemented by molecular analyses in future studies to validate protein expression levels.

Conclusion

Our findings demonstrate that individuals with NC exhibited elevated levels of class I and II HLA expression on both hepatocytes and cholangiocytes. This increased expression appears to correlate with indicators of disease severity. These findings underscore the need for further research to explore specific HLA allele variants that may influence disease development and progression. Additionally, further investigations are warranted into the potential integration of HLA related pathways within interactome-based models to support the discovery of new therapeutic agents.

Acknowledgments

The authors would like to express their sincere gratitude to the medical and technical staff of the Pathology Department for their invaluable assistance in sample collection, preparation, and analysis. Special thanks are extended to the laboratory team for their support and dedication throughout the immunohistochemical procedures. The authors are also grateful to the patients and their families for their cooperation, without which this research would not have been possible..

Authors' Contributors

All authors contributed equally to the conceptualization, design, and execution of this study.

Data Availability

The datasets generated and analyzed during the current study are not publicly available; however, the data can be shared for research and authentication purposes upon reasonable request.

Funding

This research received no specific grant from any funding agency in the public, commercial, or not-for-profit sectors.

Ethics Approval

The study protocol was conducted in accordance with the Declaration of Helsinki of the World Medical Association.

Conflict of Interest

The authors declared no conflict of interest.

References

1. Lim YS, Kim WR. The global impact of cholestatic liver diseases: recent insights from systematic reviews. Hepatology. 2019;70(4):1441-52.
2. Tanaka H, Suzuki T, Nakayama M. HLA class I and II expression in liver diseases: an updated systematic review. Front Immunol. 2020;11:1650.
3. Ghazy RM, Khedr MA. Neonatal cholestasis: recent insights. Egypt Pediatr Assoc Gaz. 2019;67(1):9. [DOI:10.1186/s43054-019-0009-3]
4. Vij M, Rela M. Biliary atresia: pathology, etiology and pathogenesis. Future Sci OA. 2020;6(5):FSO466. [DOI:10.2144/fsoa-2019-0153] [PMID] [PMCID]
5. Spiroglou K, Chatziparasidis G, Karagiozoglou-Lamboudi T, Xinias I, Demertzidou V, Patsiaoura K. Idiopathic neonatal hepatitis: a long term follow-up study. Ann Gastroenterol. 2001;14(2):112-7.
6. Hertel PM, Hawthorne K, Kim S, Finegold MJ, Shneider BL, Squires JE, et al. Presentation and outcomes of infants with idiopathic cholestasis: a multicenter prospective study. J Pediatr Gastroenterol Nutr. 2021;73(4):478-84. [PMID] [PMCID] [DOI:10.1097/MPG.0000000000003248]
7. Gunaydin M, Bozkurter Cil AT. Progressive familial intrahepatic cholestasis: diagnosis, management, and treatment. Hepat Med. 2018;10:95-104. [DOI:10.2147/HMER.S137209] [PMID] [PMCID]
8. Goldberg A, Mack CL. Inherited cholestatic diseases in the era of personalized medicine. Clin Liver Dis (Hoboken). 2020;15(3):105-9. [DOI:10.1002/cld.872] [PMID] [PMCID]
9. Holling TM, van Eggermond MCJA, Jager MJ, van den Elsen PJ. Epigenetic silencing of HLA2TA transcription in cancer. Biochem Pharmacol. 2006;72(11):1570-6. [DOI:10.1016/j.bcp.2006.06.034] [PMID]
10. van den Elsen PJ. Expression regulation of major histocompatibility complex class I and class II encoding genes. Front Immunol. 2011;2:48. [DOI:10.3389/fimmu.2011.00048] [PMID] [PMCID]
11. Xu HC, Huang J, Pandyra AA, Pandey P, Wang R, Zhang Z, et al. Single MHC-I expression promotes virus-induced liver immunopathology. Hepatol Commun. 2022;6(7):1620-33. [DOI:10.1002/hep4.1913] [PMID] [PMCID]
12. Calmus Y, Gane P, Rouger P, Poupon R. Hepatic expression of class I and class II major histocompatibility complex molecules in primary biliary cirrhosis and primary sclerosing cholangitis. Gastroenterology. 1992;102(4 Pt 1):1351-7. [DOI:10.1016/0016-5085(92)90778-W] [PMID]
13. Walther AE, Mohanty SK, Donnelly B, Coots A, McNeal M, Tiao GM. Role of myeloid differentiation factor 88 in Rhesus rotavirus-induced biliary atresia. J Surg Res. 2013;184(1):322-9. [DOI:10.1016/j.jss.2013.05.032] [PMID] [PMCID]
14. Russo P, Magee JC, Anders RA, Bove KE, Chung C, Cummings OW, et al. Key histopathologic features of liver biopsies that distinguish biliary atresia from other causes of infantile cholestasis and their correlation with outcome: a multicenter study. Am J Surg Pathol. 2016;40(12):1601-15. [PMID] [PMCID] [DOI:10.1097/PAS.0000000000000755]
15. Dupont WD, Plummer WD. Power and sample size calculations: a review and computer program. Control Clin Trials. 1990;11(2):116-28. [DOI:10.1016/0197-2456(90)90005-M] [PMID]
16. Rajanayagam J, Kelly DA, Davenport M. Biliary atresia: advances in understanding immune mechanisms through systematic reviews. J Hepatol. 2021;75(3):632-45.
17. Kim S, Choi YH, Kim Y, Yi NJ, Lee JM, Lee SK, et al. Correlation of immune markers with outcomes in biliary atresia. Hepatol Commun. 2019;3(6):792-804. [DOI:10.1002/hep4.1332] [PMID] [PMCID]
18. Bezerra JA, Wells RG, Mack CL, Karpen SJ, Hoofnagle JH, Doo E, et al. Biliary atresia: clinical and research challenges for the 21st century. Hepatology. 2018;68(3):1163-73. [DOI:10.1002/hep.29905] [PMID] [PMCID]
19. Lei H, Wang C, Ye J, Wang X, Zhao W, Wei L. Mechanisms of immune tolerance in liver transplantation. Front Immunol. 2019;10:2520. [DOI:10.3389/fimmu.2019.02667] [PMID] [PMCID]
20. Chen M, Tabaczewski P, Truscott SM, Van Kaer L, Stroynowski I. Hepatocytes express abundant surface class I HLA and efficiently use transporter associated with antigen processing, tapasin, and low molecular weight polypeptide proteasome subunit components of antigen processing and presentation pathway. J Immunol. 2005;175(2):1047-55. [DOI:10.4049/jimmunol.175.2.1047] [PMID]
21. Bertolino P, Bowen DG, McCaughan GW, Fazekas de St Groth B. Antigen-specific primary activation of CD8+ T cells within the liver. J Immunol. 2001;166(9):5430-8. [DOI:10.4049/jimmunol.166.9.5430] [PMID]
22. Feng J, Li M, Gu W, Tang H, Yu S. The aberrant expression of HLA-DR in intrahepatic bile ducts in patients with biliary atresia: an immunohistochemistry and immune electron microscopy study. J Pediatr Surg. 2004;39(11):1658-62. [DOI:10.1016/j.jpedsurg.2004.07.010] [PMID]

23. Wu J, Zhang H, Zhao B. Role of microRNAs and immune regulation in biliary atresia: a systematic review. World J Gastroenterol. 2022;28(10):1063-78.

24. Lu JG, Ji P, French SW. The major histocompatibility complex class II-CD4 immunologic synapse in alcoholic hepatitis and autoimmune liver pathology: the role of aberrant major histocompatibility complex class II in hepatocytes. Am J Pathol. 2020;190(1):25-32. [DOI:10.1016/j.ajpath.2019.09.019] [PMID] [PMCID]

25. Calmus Y, Arvieux C, Gane P, Boucher E, Nordlinger B, Rouger P, Poupon R. Cholestasis induces major histocompatibility complex class I expression in hepatocytes. Gastroenterology. 1992 Apr;102(4 Pt 1):1371-7. [DOI:10.1016/0016-5085(92)90778-W] [PMID]

26. Shi SR, Key ME, Kalra KL. Antigen retrieval in formalin-fixed, paraffin-embedded tissues: an enhancement method for immunohistochemical staining based on microwave oven heating of tissue sections. J Histochem Cytochem. 1991;39(6):741-748. [DOI:10.1177/39.6.1709656] [PMID]

27. Lobo-Yeo A, Senaldi G, Portmann B, Mowat AP, Vergani D, Mieli-Vergani G. Class I and class II major histocompatibility complex antigen expression on hepatocytes: a study in children with liver disease. Hepatology. 1990;12(2):224-32. [DOI:10.1002/hep.1840120208] [PMID]

28. Chen XM, O'Hara SP, Nelson JB, et al. The immunobiology of cholangiocytes: cytokine modulation of epithelial immune responses, including upregulation of adhesion molecules and MHC class I/II by pro-inflammatory cytokines such as IFN-γ and TNF-α. Clin Immunol. 2008;128(1):110-120.

29. Barnes BH, Tucker RM, Wehrmann F, Mack DG, Ueno Y, Mack CL. Cholangiocytes as immune modulators in rotavirus-induced murine biliary atresia: Th1 cytokine milieu including IFN-γ and TNF-α is associated with increased MHC class I and II expression on cholangiocytes in BA models. Liver Int. 2009;29(8):1253-1261. [DOI:10.1111/j.1478-3231.2008.01921.x] [PMID] [PMCID]

30. Zhao R, Dong R, Yang Y, Wang Y, Ma J, Wang J, Li H, Zheng S. MicroRNA-155 modulates bile duct inflammation by targeting the suppressor of cytokine signaling 1 in biliary atresia. Pediatr Res. 2017;82(6):1007-1016 [DOI:10.1038/pr.2017.87] [PMID]

31. Bertolino P, McCaughan GW, Bowen DG. Role of primary intrahepatic T-cell responses in the 'liver tolerance effect'. J Hepatol. 2002;37(4):507-16.

32. Calmus Y, Gane P, Rouger P, Poupon R. Hepatic expression of class I and class II major histocompatibility complex molecules in primary biliary cirrhosis: effect of ursodeoxycholic acid. Hepatology. 1990;11(1):12-5. [DOI:10.1002/hep.1840110104] [PMID]

33. Wang ZL, Jin R, Hao M, Xie YD, Liu ZC, Wang XX, et al. Treatment of ursodeoxycholic acid with glucocorticoids and immunosuppressants may improve the long-term survival rate in primary biliary cholangitis patients. Medicine (Baltimore). 2022;101(46):e31818. [DOI:10.1097/MD.0000000000031395] [PMID] [PMCID]

34. Böttcher JP, Schanz O, Wohlleber D, Abdullah Z, Debey-Pascher S, Staratschek-Jox A, et al. Liver-primed memory T cells generated under noninflammatory conditions provide anti-infectious immunity. Cell Rep. 2013;3(3):779-95. [DOI:10.1016/j.celrep.2013.02.008] [PMID]

35. Massa C, Wang Y, Marr N, Seliger B. Interferons and resistance mechanisms in tumors and pathogen-driven diseases-focus on the major histocompatibility complex (MHC) antigen processing pathway. Int J Mol Sci. 2023;24(7):6736. [DOI:10.3390/ijms24076736] [PMID] [PMCID]