Iranian Journal of Pathology | ISSN: 2345-3656

Primary Signet Ring Cell Carcinoma Bilateral Breast: An Exceptional Occurrence

Garima Dhull[1], Mukta Pujani[1], Varsha Chauhan[1], Aniruna Dey[1], Neha Garg[1], Neha Raghav[1], Sonali Madaan[2], Kartik Kaul[2]

1. *Dept. of Pathology, ESIC Medical College and Hospital, Faridabad, Haryana, India*
2. *Dept. of Radiodiagnosis, ESIC Medical College and Hospital, Faridabad, Haryana, India*

KEYWORDS

Signet Ring Cell Carcinoma, Breast, Bilateral, Primary

Scan to discover online

Main Subjects:

Breast Pathology

Received 27 Aug 2025;

Accepted 05 Feb 2025;

Published Online 25 Feb 2026;

10.22034/ijp.2026.2069045.3521

ABSTRACT

Signet ring cell carcinoma (SRCC) of the breast is an exceptionally rare subtype accounting for only 0.04% to 2.7% of all breast cancers. Pure SRCC is characterized by the presence of >90% signet ring cells and exhibits an aggressive clinical profile often associated with higher histologic grade, lympho-vascular invasion, hormone receptor positivity, and low HER2 expression. Differentiating primary mammary SRCC from metastases from gastrointestinal primary, especially in elderly patients with bilateral presentations is of prime importance. Immunohistochemistry plays a crucial role in this regard with primary breast SRCCs displaying ER, GATA3 and CK7 positivity and CK20 and CDX2 negativity. We report a case of bilateral signet ring cell carcinoma breast in an 82 year-old female. This case highlights the significance of recognising SRCC breast as a distinct pathological entity and thorough evaluation in case of bilateral presentation as it is exceptionally uncommon and poses diagnostic and therapeutic challenges.

Corresponding Information: **Mukta Pujani**, Dept. of Pathology, ESIC Medical College and Hospital, Faridabad, Haryana, India. Email: drmuktapujani@gmail.com

Copyright © 2026. This is an open-access article distributed under the terms of the **Creative Commons Attribution 4.0 International License (CC BY 4.0)**, which permits unrestricted use, distribution, and reproduction in any medium, provided the original work is properly cited. The license also allows users to adapt, remix, transform, and build upon the material for any purpose, including commercial use.

Introduction

Signet ring cell carcinoma (SRCC) of the breast is an exceptionally rare and poorly understood subtype of invasive breast carcinoma, defined by the presence of intracytoplasmic mucin displacing the nucleus peripherally, giving the characteristic “signet ring” appearance in >90% of tumor cells (1). Initially, this entity was historically viewed as a variant of mucin-producing carcinomas. However, the 2019 WHO classification now includes SRCC within the spectrum of invasive lobular carcinoma (ILC), recommending the descriptive term “carcinoma with signet ring cell differentiation” to account for its morphological heterogeneity and biological behavior (2).

SRCC is reported to comprise only 0.04% to 2.7% of all breast cancers, with most cases presenting in the sixth decade of life and showing a marked female predilection (3). It typically exhibits an aggressive course, often associated with higher histologic grade, lymphovascular invasion, hormone receptor positivity, and low HER2 expression (4). Its diagnosis is often challenging because of overlapping features with metastatic gastrointestinal SRCC, requiring careful correlation with immunohistochemical (IHC) markers such as ER, GATA3, CK7, CK20, and CDX2 to establish the primary origin (5).

While most breast SRCCs are unilateral, bilateral presentation is exceedingly rare, with very few such cases reported in the literature (6). Here, we report a unique case of bilateral signet ring cell carcinoma of the breast in an 82-year-old woman, highlighting its clinical, histological, and immunophenotypic features.

Case report

An 82-year-old female presented to the surgical outpatient department with complaints of bilateral breast lumps associated with intermittent dull pain for the past 4–5 years. The lumps had gradually increased in size over time. At presentation, both breasts showed stony hard, fixed masses with excoriated overlying skin. The lump in the right breast was retroareolar in location and measured approximately 9 × 7 cm. The left-sided lump, located in the upper outer quadrant, measured 9 × 8 cm. There was no history of nipple discharge, constitutional symptoms, or family history of malignancy. Ultrasonography classified both lesions as BI-RADS V, suggestive of malignancy (Figure 1). PET scan showed increased FDG uptake in both breasts. No abnormal FDG uptake was noted in cervical, axillary, mediastinal, or abdominal lymph nodes, nor in the GIT, including the stomach and colon,

and no uptake was seen in the liver, spleen, lungs, or bones.

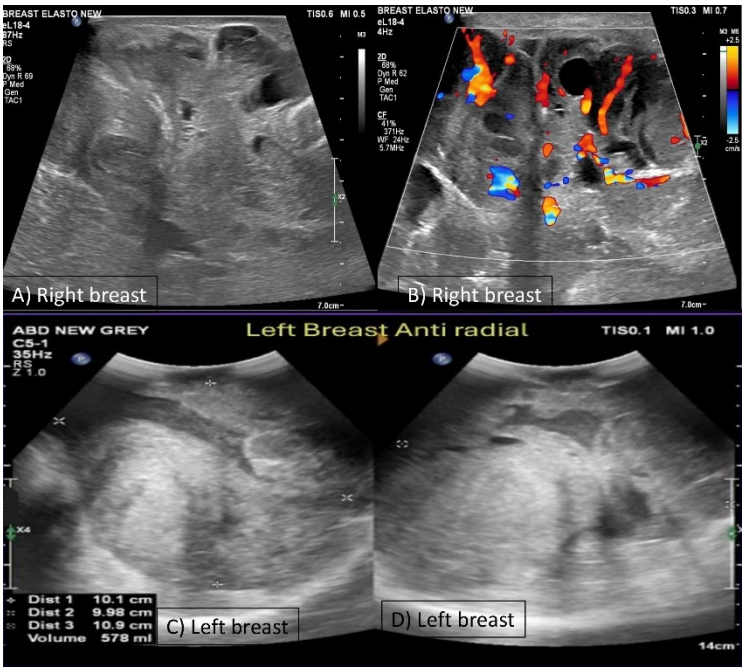

Fig. 1. Ultrasonography images of Bilateral breast lesions, Figure A and B showing Large bulky right breast lesion m/a 7 x 9 cm (AP x TR), predominantly solid with variable cystic areas, iso to hypoechoic, with color flow on CDFI and no macrocalcifications occupying most of breast involving nipple areola complex. USG BIRADS 5. Images C and D show Large bulky left breast lesion m/a 8 x 9 cm (AP x TR), USG BIRADS 5.

Core needle (Tru-Cut) biopsies were performed on both lesions. Microscopic examination of the right breast biopsy (Figure 2) revealed tumor infiltration in four out of six cores. The tumor cells were arranged in nests and lobules, with moderate pleomorphism, clear to pale eosinophilic cytoplasm, and eccentrically placed nuclei—giving them a characteristic signet ring appearance. Signet ring cells comprised over 90% of the tumor cell population. Occasional atypical mitotic figures were also observed. The left breast biopsy (Figure 3) showed similar morphology across all four cores. Mitotic activity was low (1–2 mitoses per high-power field).

Immunohistochemistry (Figures 1 and 2) showed estrogen receptor (ER) positivity (Allred score 8/8) and progesterone receptor (PR) positivity (Allred score 8/8), HER2/neu negativity, and a low Ki-67 proliferation index (4%–5%) bilaterally. To rule out metastases from a gastrointestinal primary, CDX2 was also performed, which was negative. GATA3 was positive in both biopsies, suggesting origin from the breast.

Based on histomorphology and immunoprofile, a diagnosis of bilateral invasive ductal carcinoma with a predominant signet ring cell component was rendered. The high percentage of signet ring cells raised the possibility of pure signet ring cell carcinoma.

On follow-up, the patient is not willing to undergo any active intervention (surgery/ chemotherapy); therefore, she is undergoing palliative management.

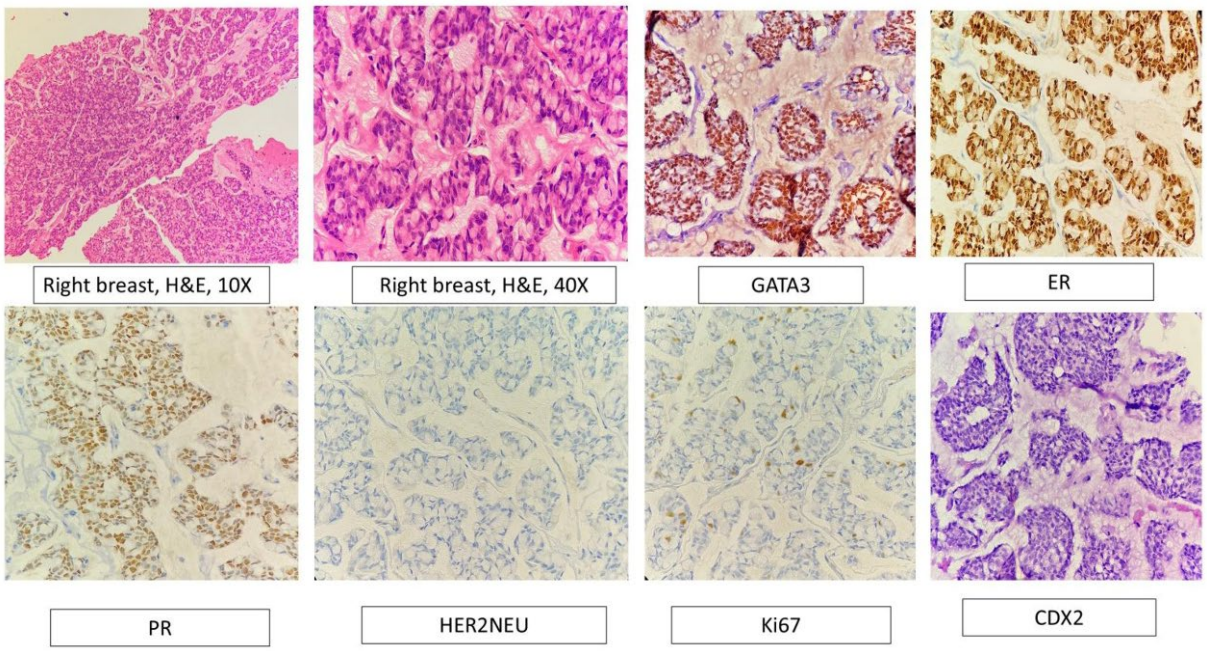

Fig 2. Trucut biopsy from Right breast showed tumour cells were arranged in nests and lobules, with moderate pleomorphism, clear to pale eosinophilic cytoplasm, and eccentrically placed nuclei—giving them a characteristic signet ring appearance (> 90% of the tumour cells)(H&E, 10x and 40x); IHC revealed positivity for GATA3, ER, PR while CDX2, Her2neu were negative, Ki-67 was 4-5%

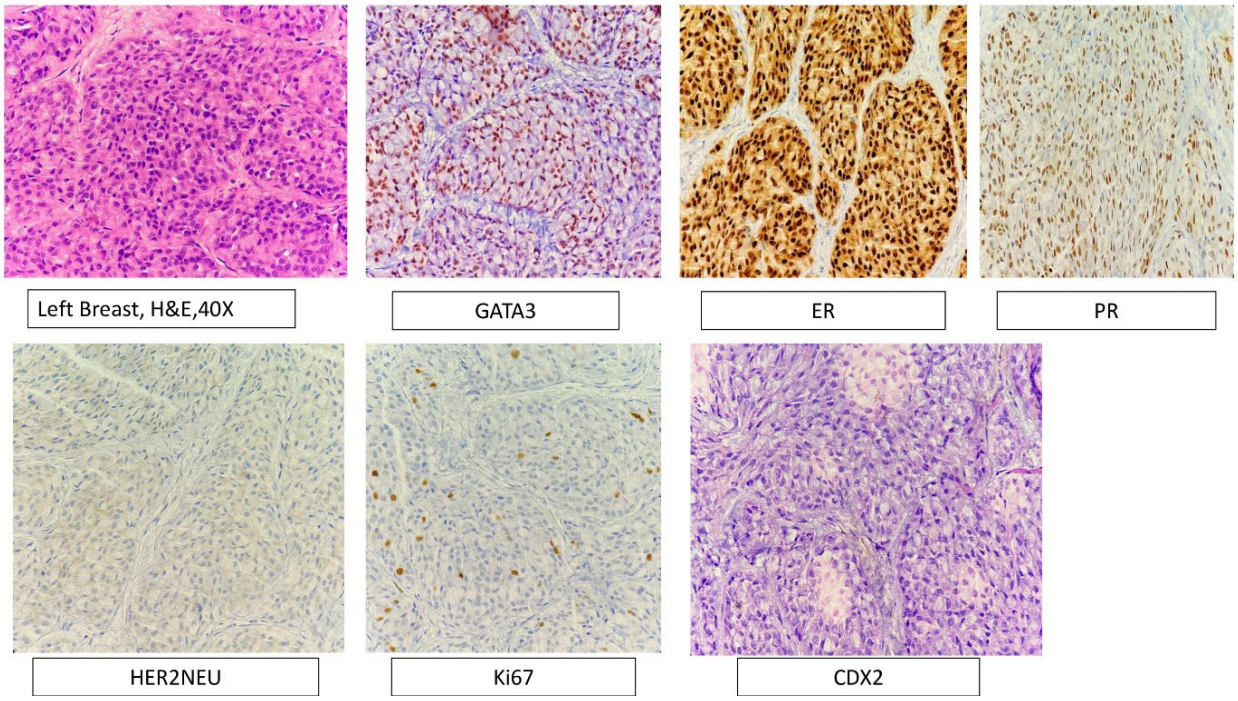

Fig. 3. Trucut biopsy from Left breast also showed signet ring cells accounting for > 90% of the tumour cells(H&E,40x); IHC revealed positivity for GATA3, ER, PR while CDX2, Her2neu were negative, Ki-67 was 4-5%

Discussion

Signet ring cell carcinoma (SRCC) of the breast represents a rare and aggressive histologic subtype of invasive carcinoma. The bilateral involvement, as seen in the present case, is extremely uncommon, with very few documented reports in the literature (6). Clinically, these tumors may mimic inflammatory carcinoma because of rapid enlargement and involvement of the overlying skin, often presenting with peau d'orange, ulceration, or nipple retraction (7). Our patient also presented with bilateral stony hard lumps and excoriated skin, which raised suspicion of an advanced-stage malignancy.

Histologically, pure SRCC is defined by the presence of >90% signet ring cells, which was evident in the biopsies in the present case. These tumors frequently exhibit hormone receptor positivity, low HER2 expression, and a low to moderate Ki-67 index—a profile consistent with our case (4). The low Ki-67 index (4%–5%) may correlate with a less proliferative biology, although paradoxically, SRCCs have a poor prognosis and show chemoresistance (8,9).

It is important to differentiate primary mammary SRCC from metastases from other sites, such as the gastrointestinal tract, ovary, or bladder, especially in elderly patients and in bilateral presentations. Immunohistochemistry plays a pivotal role: primary breast SRCCs are usually ER and GATA3 positive, CK7 positive/CK20 negative, and CDX2 negative (5). The strong ER and PR positivity and CDX2 negativity, in combination with typical morphology and bilateral breast involvement without gastrointestinal symptoms, strongly supported a primary breast origin.

Management of SRCC is similar to that of other invasive breast carcinomas because of the lack of subtype-specific guidelines. Most patients undergo modified radical mastectomy because of tumor size, multifocality, or skin involvement. Systemic therapy includes anthracycline-taxane regimens, with hormone therapy for ER-positive cases. However, SRCC has demonstrated a tendency toward early recurrence and resistance to chemotherapy and radiation (9).

This case highlights several important points. First, SRCC should be recognized as a distinct pathologic entity, especially when the signet ring component is dominant. Second, bilateral presentation must lead to thorough evaluation and exclusion of metastasis. Third, the discrepancy between hormone receptor positivity and poor prognosis, as seen in SRCC, requires further investigation at the molecular level.

Conclusion

Signet ring cell carcinoma of the breast is a rare and aggressive variant of invasive carcinoma, with unique histopathologic and immunohistochemical features. Bilateral presentation, as seen in our case, is exceptionally uncommon and poses diagnostic and therapeutic challenges. Accurate diagnosis requires careful histologic evaluation and immunoprofiling to exclude metastatic disease, particularly from the gastrointestinal tract. Given its poor prognosis despite hormone receptor positivity, early recognition and documentation of such cases are crucial. This case highlights the importance of thorough reporting and further molecular studies to better understand the biological behavior of breast SRCC and guide tailored treatment options.

Acknowledgments

None

Authors' Contributors

Idea, design: Dr Varsha Chauhan, Dr Mukta Pujani**;** Data acquisition: Dr Garima Dhull, Dr. Neha Garg, Dr Kartik Kaul**;** Analysis: Dr Aniruna Dey, Dr Sonali Madaan, Dr Neha Raghav**;** Interpretation of findings: Dr. Neha Raghav, Dr Sonali Madaan, Dr. Neha Garg**;** Preparation of manuscript: Dr Garima Dhull, Dr Kartik Kaul**;** Critical revision: Dr Mukta Pujani, Dr Varsha Chauhan, Dr Aniruna Dey

Data Availability

The datasets generated and analyzed during the current study are not publicly available; however, the data can be shared for research and authentication purposes upon reasonable request.

Funding

This research received no specific grant from any funding agency in the public, commercial, or not-for-profit sectors.

Ethics Approval

All individuals who contributed samples to this study voluntarily provided their informed consent to participate. They were thoroughly briefed on the research's objectives and potential advantages. Participants were guaranteed the right to withdraw at any point without facing any repercussions. Written consent was secured from all participants before their inclusion in the study. This study was conducted in accordance with the ethical principles outlined in the Declaration of Helsinki. Ethical approval was obtained from the ethics committee of IEC, ESIC Medical College & Hospital, Faridabad with DHR Registration no. EC/NEW/INST/2023/HR/0307.

Conflict of Interest

The authors declared no conflict of interest.

References

1. Efthimiou P, Kontzias A, Hur P, Rodha K, Ramakrishna GS, Nakasato P. Adult-onset Still's disease in focus: clinical manifestations, diagnosis, treatment, and unmet needs in the era of targeted therapies. Semin Arthritis Rheum. 2021;51(4):858-74. [DOI:10.1016/j.semarthrit.2021.06.004] [PMID]
2. Jeon YK, Paik JH, Park SS, Park SO, Kim YA, Kim JE, et al. Spectrum of lymph node pathology in adult onset Still's disease; analysis of 12 patients with one follow up biopsy. J Clin Pathol. 2004;57(10):1052-6. [PMID] [PMCID] [DOI:10.1136/jcp.2004.018010]
3. Soy M, Ergin M, Paydas S. Lymphadenopathy in adult-onset Still's disease mimicking peripheral T-cell lymphoma. Clin Rheumatol. 2004;23(1):81-2. [DOI:10.1007/s10067-003-0826-y] [PMID]
4. Kim HA, Kim YH, Jeon YK, Yang WI, Kwon JE, Han JH. Histopathology and expression of the chemokines CXCL10, CXCL13, and CXCR3 and the endogenous TLR-4 ligand S100A8/A9 in lymph nodes of patients with adult-onset Still's disease. Sci Rep. 2019;9(1):7517. [DOI:10.1038/s41598-019-44032-6] [PMID] [PMCID]
5. Paul M, Paul P, Dey D, Safdar S, Ramos J. Adult-onset Still's disease with extensive lymphadenopathy mimicking lymphoproliferative malignancy. Cureus. 2021; 13(7):e16163. [DOI:10.7759/cureus.16163]
6. Huang Z, Xu H, Min Q, Li Z, Bi J, Liu L, et al. Adult-onset Still's disease with multiple lymphadenopathy: a case report and literature review. Diagn Pathol. 2021;16(1):97. [DOI:10.1186/s13000-021-01159-3] [PMID] [PMCID]
7. Lee SW, Park MC, Kim H, Park YB, Lee SK. Dermatopathic lymphadenopathy in a patient with adult onset Still's disease. Clin Exp Rheumatol. 2007;25(2):312-4.
8. Donaire-Castaños JC, Demelo-Rodríguez P, Ordieres-Ortega L, Pardo-Sánchez S, Galeano-Valle F. Overlap of adult-onset Still disease and Kikuchi-Fujimoto disease: a case report and literature review. Cureus. 2024;16(11):e73283. [DOI:10.7759/cureus.73283] [PMID] [PMCID]
9. Griffin G, Shenoi S, Hughes GC. Hemophagocytic lymphohistiocytosis: an update on pathogenesis, diagnosis, and therapy. Best Pract Res Clin Rheumatol. 2020;34(4):101515. [DOI:10.1016/j.berh.2020.101515] [PMID]
10. Henter JI, Horne A, Aricó M, Egeler RM, Filipovich AH, Imashuku S, et al. HLH-2004: diagnostic and therapeutic guidelines for hemophagocytic lymphohistiocytosis. Pediatr Blood Cancer. 2007;48(2):124-31. [DOI:10.1002/pbc.21039] [PMID]