Iranian Journal of Pathology | ISSN: 2345-3656

Adult-Onset Still's Disease and Secondary Hemophagocytic Lymphohistiocytosis: Diagnostic Pitfalls in Lymph Node Histology

Saikat Mitra[1*], **Keshao Nagpure**[2]

1. *Department of Pathology, All India Institute of Medical Sciences, Nagpur, Plot-2, Sector-20, MIHAN, Nagpur, Maharashtra, India*
2. *Department of General Medicine, All India Institute of Medical Sciences, Nagpur, Plot-2, Sector-20, MIHAN, Nagpur, Maharashtra, India*

KEYWORDS

Adult-onset Still's disease, Hemophagocytic lymphohistiocytosis, Reactive lymphadenopathy, T-cell lymphoma, Immunohistochemistry

Scan to discover online

Main Subjects:
Immunology and Serology

Received 31 Jul 2025;
Accepted 21 Jan 2026;
Published Online 25 Feb 2026;

10.22034/ijp.2026.2067545.3498

ABSTRACT

Background & Objective: Adult-onset Still's disease (AOSD) is a rare systemic autoinflammatory disorder characterized by high spiking fevers, evanescent rash, arthritis, and systemic inflammation. Its diagnosis is challenging due to the lack of specific biomarkers and clinical overlap with infections, malignancies, and autoimmune diseases.

Case Report: We present the case of a 20-year-old female with a two-year history of recurrent fever, polyarthritis, and erythematous rash, accompanied by generalized lymphadenopathy and splenomegaly. Initial workup revealed severe anemia, leukocytosis, markedly elevated serum ferritin, and abnormal liver function tests. Infectious and malignant etiologies were excluded. Lymph node biopsies initially suggested dermatopathic lymphadenitis, but subsequent histology showed paracortical hyperplasia with features mimicking peripheral T-cell lymphoma. Immunohistochemistry revealed a polyclonal T-cell population and hemophagocytosis, leading to a revised diagnosis of reactive lymphadenopathy associated with AOSD. The patient fulfilled criteria for secondary hemophagocytic lymphohistiocytosis (HLH), a life-threatening hyperinflammatory syndrome. High-dose corticosteroid therapy resulted in significant clinical and biochemical improvement.

Conclusion: This case highlights the diagnostic complexities of AOSD with secondary HLH, particularly when lymph node histology mimics malignancy. Awareness of the varied lymph node patterns in AOSD and integration of clinical, laboratory, and immunohistochemical data are crucial for accurate diagnosis and timely management, preventing unnecessary interventions and improving outcomes.

Corresponding Information: **Saikat Mitra**, Department of Pathology, All India Institute of Medical Sciences, Nagpur, Plot-2, Sector-20, MIHAN, Nagpur, Maharashtra, India. Email: saikatmitra123@gmail.com

Copyright © 2026. This is an open-access article distributed under the terms of the **Creative Commons Attribution 4.0 International License (CC BY 4.0)**, which permits unrestricted use, distribution, and reproduction in any medium, provided the original work is properly cited. The license also allows users to adapt, remix, transform, and build upon the material for any purpose, including commercial use.

Introduction

Adult-onset Still's disease (AOSD) is a rare autoinflammatory condition characterized by high spiking fevers, evanescent salmon-colored rash, arthritis, and systemic inflammation (1). The etiology remains poorly understood, and diagnosis is often delayed due to the lack of disease-specific biomarkers and overlapping features with infections, malignancies, and other autoimmune disorders. The disease can present with generalized lymphadenopathy and hepatosplenomegaly, which can mimic hematolymphoid malignancies. A severe and potentially life-threatening complication of AOSD is secondary hemophagocytic lymphohistiocytosis (HLH), a hyperinflammatory syndrome driven by excessive activation of T lymphocytes and macrophages. The lymph node histology in AOSD can show wide spectrum of patterns, dramatic change in histological pattern over disease course and often closely mimic peripheral T-cell lymphoma (2,3). Here we report a case of a young female with AOSD and HLH, which created significant diagnostic and therapeutic dilemma in clinicians and pathologists.

Case report

A 20-year-old lady with no known comorbidities presented with a two-year history of recurrent high-grade fever, bilateral knee and small joint polyarthritis, and an erythematous rash predominantly involving the bilateral upper limbs, chest, and neck. The rash exhibited a waxing and waning course and intensified during febrile episodes. She reported no history of significant weight loss, tuberculosis exposure, or prior autoimmune disease. On clinical examination, she was

febrile (temperature > 39.5 ^{0}C) with tachycardia, had marked pallor, and generalized lymphadenopathy involving the cervical, axillary, and inguinal nodes. Splenomegaly was also noted on abdominal palpation.

Initial investigations revealed severe anemia with a hemoglobin of 4.6 g/dL, leukocytosis with neutrophilic predominance, thrombocytosis, and an elevated C-reactive protein of 340 mg/L. Liver function tests showed a total bilirubin of 4.2 mg/dL and elevated transaminases. The serum ferritin level was markedly elevated at more than 100,000 ng/mL. Infectious causes including tuberculosis, HIV, hepatitis B and C, Epstein-Barr virus, and bacterial infections were ruled out through serological testing and cultures. Antinuclear antibody (ANA) was positive at a titer of 1:320, but ANA blot was negative. Patient had history of multiple inpatient hospitalisations, received multiple courses of broad-spectrum antibiotics and empirical antitubercular treatment which was stopped due to antitubercular treatment induced Hepatitis.

On the basis of clinical & laboratory evaluation a diagnosis of AOSD was suspected based on fulfilment of the Yamaguchi criteria [Fever ≥39 degrees Celsius persisting for ≥1 week, Arthralgia/arthritis persisting for ≥2 weeks, Typical rash, White blood cell count ≥10×10^9/L (>80% neutrophils), Lymphadenopathy and/or splenomegaly, Increased serum aminotransferase or lactate dehydrogenase levels]. She was started on prednisolone (1mg/kg) , methotrexate hydroxychloroquine and non-steroidal anti-inflammatory therapy, with dramatic resolution of fever ,rash & joint pain . Upon cessation of steroids prior to a scheduled PET-CT scan, the patient experienced a resurgence of symptoms including high-grade fever, joint pain, and a facial rash.

The patient had persistent cervical lymphadenopathy, and she underwent lymph node excision twice within a span of two months. The initial cervical lymph node excision showed mostly preserved nodal architecture with mild paracortical expansion and proliferation of the sinus histiocytes and dendritic cells, which were loaded with melanin pigment and stained with S-100 on immunohistochemistry (IHC) (**Fig. 1**).

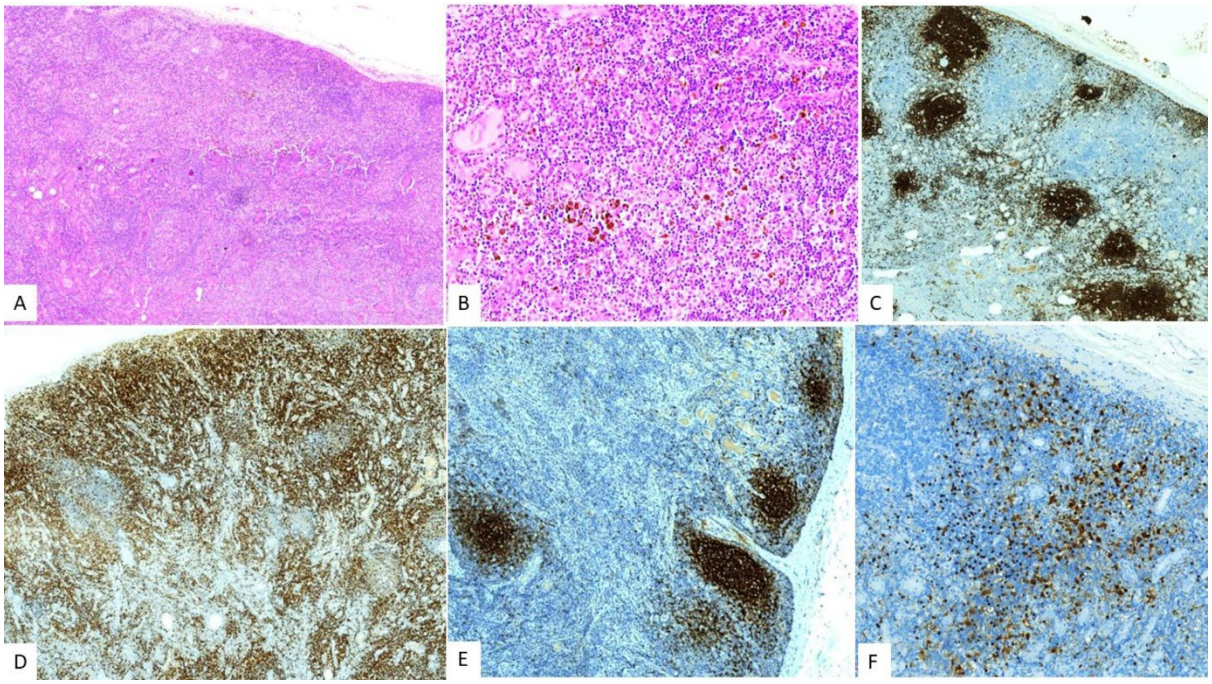

Fig. 1. A: (H&E, 40x) Lymph node excision biopsy shows maintained follicular architecture and expansion of interfollicular zone B: (H&E, 100x)-The sinusoidal histiocytes are filled with melanin pigment C: CD20 IHC- B-lymphocytes in reactive follicles are highlighted C: CD3 IHC- The expanded interfollicular zone is filled with CD3 positive T-lymphocytes E: CD23 IHC shows maintained follicular dendritic cell meshwork F: S-100 IHC: The pigment laden sinusoidal histiocytes are highlighted.

A possibility of dermatopathic lymphadenitis was considered. A repeat sampling from an enlarged cervical lymph node performed after two month showed dramatic changes in the microscopic features. There was marked effacement of the nodal architecture, extensive paracortical hyperplasia, proliferation of high-endothelial venules, enlarged lymphoid cells with increased mitotic activity. Hence, a diagnosis of T-cell Non-Hodgkin Lymphoma was provided initially. On further review, a prominent sinus histiocyte proliferation was noted, with many macrophages showing features of hemophagocytosis. On IHC, the paracortical area showed predominant population of T-lymphocytes, which were stained with CD3 stain. There was equal proportion of CD4 and CD8 positive T-lymphocytes. The germinal centres were attenuated, with preserved follicular meshwork. CD20 positive B-lymphocytes were noted in the

germinal centers. CD68 highlighted the macrophages (**Fig. 2**). No Reed-Sternberg cells or atypical lymphoid cells were identified. Based on histopathologic findings, the diagnosis was revised to paracortical reactive T-cell hyperplasia with hemophagocytosis. PET-CT showed generalized lymphadenopathy with minimal to absent FDG uptake and diffuse marrow and splenic hypermetabolism, consistent with systemic inflammation. A prompt work-up was initiated to look for HLH criteria. The patient met several diagnostic criteria for HLH [fever, splenomegaly, hypertriglyceridemia, hyperferricemia, low fibrinogen level, histologic evidence of hemophagocytosis and transaminitis]. A diagnosis of secondary HLH was confirmed and the patient was initiated on high-dose intravenous dexamethasone at 10 mg/m² body surface area as per HLH protocol along with hydroxychloroquine and methotrexate. Her condition improved clinically and biochemically, with gradual normalization of serum ferritin and C-reactive protein (Table-1). She was discharged in stable condition on a tapering dose of corticosteroids with close outpatient follow-up.

Table 1. Gradual trend of biochemical parameters after initiation of intravenous dexamethasone

Parameters	Day-1	Day-7	Day-14
CRP (mg/dl)	198	64	12
Ferritin (ng/ml)	100000	9450	2000
AST/ALT (U/L)	212/38	32/34	28/26
Bilirubin (total/direct) mg/dl	4.2/2.5	0.78/0.56	0.56/0.40

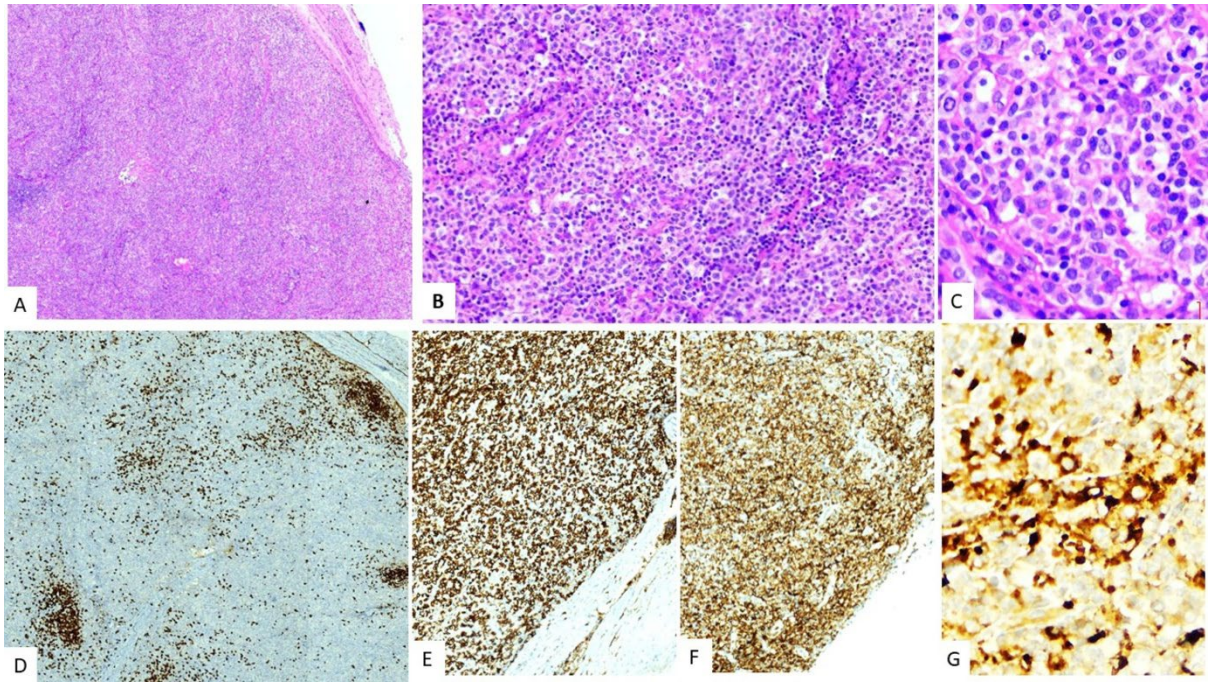

Fig 2. A: (H&E, 40x) Effacement of normal nodal architecture with markedly expanded interfollicular zone and attenuated follicles B: (H&E, 100x)- The interfollicular zone is filled with medium sized lymphocytes, plasma cells and proliferating high endothelial venules C: (H&E, 400x) The expanded sinusoidal spaces are filled with macrophages demonstrating hemophagocytosis D: CD20 IHC- the attenuated follicles containing B-lymphocytes are highlighted. E: CD4 IHC and F: CD8 IHC highlights the interfollicular proliferating T-lymphocytes. Note the equal population of CD4+ and CD8+ t-lymphocytes G: CD68 IHC- The sinusoidal macrophages with engulfed leukocytes are highlighted

Discussion

Lymphadenopathy is a frequent clinical manifestation in Adult-Onset Still's Disease (AOSD), seen in up to 65% of cases. Although often reactive and self-limiting, lymphadenopathy in AOSD can mimic infectious or neoplastic disorders both clinically and histologically (3). The accurate interpretation of lymph node biopsies in this context is essential, as misdiagnosis can lead to inappropriate treatment. Histologic examination of lymph nodes in AOSD shows a range of reactive patterns (4). These include follicular pattern, showing follicular hyperplasia; paracortical pattern, with proliferation and expansion of the paracortical areas and only a few small remnants of lymphoid follicles; diffuse pattern, characterized by diffuse hyperplasia of the

paracortical areas, with no lymphoid follicular structures observed; necrotic pattern, characterized by proliferative expansion of the paracortical areas with focal necrosis and karyorrhexis; and mixed pattern (4). Our case showed marked paracortical hyperplasia due to proliferation of T-immunoblasts, small lymphocytes, plasma cells, and dendritic cells. Germinal centers are often atrophic or inconspicuous, as was seen in our case. The paracortical expansion may be so pronounced as to mimic peripheral T-cell lymphoma (3,5). A major diagnostic challenge lies in distinguishing AOSD-related reactive lymphadenopathy from lymphomas, especially angioimmunoblastic T-cell lymphoma (AITL) or anaplastic large cell lymphoma (ALCL). In AOSD, the cytologic features of atypia are usually mild, and IHC reveals a polyclonal population of CD4 positive and CD8 positive T-cells. We performed CD30 and Anaplastic lymphoma kinase (ALK) IHC to exclude ALCL. AITL usually affects elderly individuals and show spectrum of histologic pattern which is difficult to distinguish from reactive lymphadenopathy (6). However, a distorted follicular dendritic cell meshwork (highlighted on CD21 and CD23) and expression of T-follicular helper cell markers (CD10, CXCL13, PD-1) and EBV-LMP or EBER-in-situ hybridization are characteristically noted in the atypical lymphoid cells in AITL, which were not seen in our case.

A common histologic mimic of AOSD lymphadenitis is dermatopathic lymphadenitis (DLN), especially in cases where rash is a dominant feature (7). DLN is characterized by pigment-laden interdigitating dendritic cells and Langerhans cells in the paracortex. S-100 and CD1a can help confirm this diagnosis. In our case, initial lymph node biopsies revealed key features including sinus histiocytosis, pigment-laden dendritic cells with S-100 positivity. However, the absence of epidermotropic infiltrates and clinical context helped exclude cutaneous lymphoproliferative diseases.

Rarely, AOSD can present with histologic features resembling Kikuchi-Fujimoto disease (KFD), also known as histiocytic necrotizing lymphadenitis. This condition is more common in young women and features patchy necrosis, karyorrhexis, and crescentic histiocytes without neutrophils. Few cases have shown overlap of AOSD and KFD, suggesting a common pathogenic link (8).

HLH is a rare, life-threatening immunological syndrome characterized by the uncontrolled activation of cytotoxic lymphocytes and macrophages, resulting in cytokine-mediated tissue injury and multiorgan dysfunction (9). Secondary HLH is driven primarily by acquired factors, such as chronic inflammation, infection, or malignancy. Typical laboratory abnormalities include pancytopenia, increased levels of ferritin, liver enzymes, lactate dehydrogenase, triglycerides, D-dimers, and soluble IL-2 receptor α (also known as soluble CD25 (sCD25)), and decreased fibrinogen levels (9). HLH diagnostic criteria (i.e., HLH 94 and HLH 2004) were developed to diagnose the condition (10). Secondary HLH, when associated with rheumatologic conditions, is characterized histologically by widespread hemophagocytosis, particularly in the lymph nodes, bone marrow, and spleen. Early recognition and prompt initiation of immunosuppressive therapy are essential to reduce morbidity and mortality. In our case, timely diagnosis of HLH and prompt treatment prevented morbidity and mortality.

Conclusion

This case underscores the diagnostic challenges in AOSD, particularly when accompanied by generalized lymphadenopathy and secondary HLH. Pathologists should be aware of the varied morphologies in lymph node biopsy in AOSD. Careful review of lymph node histology with proper clinical context and comprehensive immunohistochemistry are instrumental in confirming the diagnosis and guiding in proper treatment.

Acknowledgments

None

Authors' Contributors

Idea & design-SM, KN. Data acquisition-SM and KN. Interpretation of findings: SM and KN. Preparation of manuscript: SM, KN. Critical revision: SM, KN.

Data Availability

The datasets generated and analyzed during the current study are not publicly available; however, the data can be shared for research and authentication purposes upon reasonable request.

Funding

This research received no specific grant from any funding agency in the public, commercial, or not-for-profit sectors.

Ethics Approval

Informed patient consent was obtained before preparing the manuscript. All patient-related data are anonymised.

Conflict of Interest

The authors declared no conflict of interest.

References

1. Efthimiou P, Kontzias A, Hur P, Rodha K, Ramakrishna GS, Nakasato P. Adult-onset Still's disease in focus: clinical manifestations, diagnosis, treatment, and unmet needs in the era of targeted therapies. Semin Arthritis Rheum. 2021;51(4):858-74. [DOI:10.1016/j.semarthrit.2021.06.004] [PMID]
2. Jeon YK, Paik JH, Park SS, Park SO, Kim YA, Kim JE, et al. Spectrum of lymph node pathology in adult onset Still's disease; analysis of 12 patients with one follow up biopsy. J Clin Pathol. 2004;57(10):1052-6. [PMID] [PMCID] [DOI:10.1136/jcp.2004.018010]
3. Soy M, Ergin M, Paydas S. Lymphadenopathy in adult-onset Still's disease mimicking peripheral T-cell lymphoma. Clin Rheumatol. 2004;23(1):81-2. [DOI:10.1007/s10067-003-0826-y] [PMID]
4. Kim HA, Kim YH, Jeon YK, Yang WI, Kwon JE, Han JH. Histopathology and expression of the chemokines CXCL10, CXCL13, and CXCR3 and the endogenous TLR-4 ligand S100A8/A9 in lymph nodes of patients with adult-onset Still's disease. Sci Rep. 2019;9(1):7517. [DOI:10.1038/s41598-019-44032-6] [PMID] [PMCID]
5. Paul M, Paul P, Dey D, Safdar S, Ramos J. Adult-onset Still's disease with extensive lymphadenopathy mimicking lymphoproliferative malignancy. Cureus. 2021;13(7):e16163. [DOI:10.7759/cureus.16163]
6. Huang Z, Xu H, Min Q, Li Z, Bi J, Liu L, et al. Adult-onset Still's disease with multiple lymphadenopathy: a case report and literature review. Diagn Pathol. 2021;16(1):97. [DOI:10.1186/s13000-021-01159-3] [PMID] [PMCID]
7. Lee SW, Park MC, Kim H, Park YB, Lee SK. Dermatopathic lymphadenopathy in a patient with adult onset Still's disease. Clin Exp Rheumatol. 2007;25(2):312-4.
8. Donaire-Castaños JC, Demelo-Rodríguez P, Ordieres-Ortega L, Pardo-Sánchez S, Galeano-Valle F. Overlap of adult-onset Still disease and Kikuchi-Fujimoto disease: a case report and literature review. Cureus. 2024;16(11):e73283. [DOI:10.7759/cureus.73283] [PMID] [PMCID]
9. Griffin G, Shenoi S, Hughes GC. Hemophagocytic lymphohistiocytosis: an update on pathogenesis, diagnosis, and therapy. Best Pract Res Clin Rheumatol. 2020;34(4):101515. [DOI:10.1016/j.berh.2020.101515] [PMID]
10. Henter JI, Horne A, Aricó M, Egeler RM, Filipovich AH, Imashuku S, et al. HLH-2004: diagnostic and therapeutic guidelines for hemophagocytic lymphohistiocytosis. Pediatr Blood Cancer. 2007;48(2):124-31. [DOI:10.1002/pbc.21039] [PMID]