Iranian Journal of Pathology | ISSN: 2345-3656

Clinical Association of Delayed Villous Maturation in Gestational Diabetes Mellitus Pregnancy: A Prospective Study

Supriya NovelTony [1*], Shilpa M Bhimalli [2], Ganga S Pilli [3], Hemalatha K R[4], Prajna K Shetty [5]

1. *Department of Anatomy, KLE Jagadguru Gangadhar Mahaswamigalu Moorusavirmath Medical College and Hospital, Hubballi, KLE Academy of Higher Education and Research, Deemed to be University , Belagavi, Karnataka, India- 59010, Faculty of Medicine, KLE Academy of Higher Education and Research, Deemed to be University, Belagavi, Karnataka, India- 590010, Hubballi, India*
2. *Department of Anatomy, J.N Medical College and Hospital, Belagavi, Faculty of Medicine, KLE Academy of Higher Education and Research, Deemed to be University, Belagavi, Karnataka, India- 590010, Belagavi, India*
3. *Department of Pathology, Zydus Medical College and Hospital, Dahod, Faculty of Medicine, Shri Govind Guru University, Godhra, Gujarat, India*
4. *Department of Obstetrics and Gynecology, Karnataka Medical College and Research Institute, Hubballi, Faculty of Medicine, Rajiv Gandhi University of Health Sciences, Bangalore, Hubballi, India*
5. *Department of Pathology, KLE Jagadguru Gangadhar Mahaswamigalu Moorusavirmath Medical College and Hospital, Hubballi, KLE Academy of Higher Education and Research, Deemed to be University, Belagavi, Karnataka, India- 590010, Hubballi, India*

KEYWORDS

Gestational diabetes, placental pathology, placental immaturity, pregnancy outcomes

Scan to discover online

Main Subjects:
Diagnostic Pathology

Received 02 Sep 2025;
Accepted 03 Feb 2026;
Published Online 25 Feb 2026;

10.22034/ijp.2026.2074182.3559

ABSTRACT

Background & Objective: Delayed Villous Maturation (DVM) is a histological hallmark in Gestational Diabetes Mellitus (GDM) pregnancies commonly observed after 36 weeks of gestation. It is associated with perinatal morbidity and mortality. Our study aims to assess DVM in the term placentas of GDM pregnancies and its association with its perinatal outcomes compared to normal pregnancies.

Methods: A total of 120 term placentae from GDM and normal pregnancies were collected from the Obstetrics and Gynaecology Department for one year and subjected to histopathological examination to evaluate DVM and its association with placental morphology and perinatal outcomes.

Results: The current study found statistically significant increased presence of DVM in GDM placentas and its association with placental weight, diameter, maternal weight, glycated haemoglobin and foetal weight. The present study also observed presence of DVM with chorangiosis in a GDM placenta.

Conclusion: The present study has found a statistically significant association of DVM in GDM pregnancies with its perinatal outcomes compared to normal pregnancies. There is no antenatal ultrasound marker to detect placental DVM and adverse foetal outcomes caused due to it. Since there is risk of reoccurrence of DVM and type 2 diabetes in future pregnancies, identification of DVM in GDM pregnancies and its clinical association with foetal outcomes should be considered clinically important. This may explain the cause of intrauterine foetal deaths and adverse neonatal outcomes in the current pregnancy and indicating a need for comprehensive maternal care in future pregnancies to prevent perinatal outcomes by implementing Rescue by birth.

Corresponding Information: **Supriya NovelTony**, Department of Anatomy, Assistant Professor, Faculty of Medicine, KLE Jagadguru Gangadhar Mahaswamigalu Moorusavirmath Medical College and Hospital, Hubballi, KLE Academy of Higher Education and Research, Deemed to be University, Belagavi, Karnataka, India- 59010, Hubballi, 580028, India. Email: supriyapremkumar21@gmail.com

Copyright © 2026. This is an open-access article distributed under the terms of the **Creative Commons Attribution 4.0 International License (CC BY 4.0)**, which permits unrestricted use, distribution, and reproduction in any medium, provided the original work is properly cited. The license also allows users to adapt, remix, transform, and build upon the material for any purpose, including commercial use.

Introduction

The placenta is the vital organ for the growth and development of the foetus (1). The combined function of maternal, foetal and placental components determines the outcome of foetal growth (2). Gestational Diabetes Mellitus (GDM) is described as glucose intolerance of varying degree with the onset of first recognition during pregnancy (3). In GDM placentas, Delayed Villous Maturation (DVM) is a common histopathological finding. It is a placental maturation defect also known as villous immaturity or

Distal villous immaturity (DVI) or villous dysmaturity (4-8). The present study prefers to use the term DVM as it is recommended by Yee Khong T et al. (8). In DVM, there is no or lesser maturation of the terminal placental villi, and it is associated with Diabetes mellitus and gestational diabetes mellitus with increased perinatal mortality and morbidity (5,6). DVM complicates up to 2-5% of all pregnancies with a risk of 10% recurrence in future pregnancies and in 2% of pregnancies DVM may cause stillbirth (9). DVM is commonly seen in more than 36 weeks and less than 34 weeks of gestation (8). Since DVM results in adverse perinatal outcomes with a risk of reoccurrence, the present study aims to assess DVM with its perinatal outcomes in the term placentas of GDM pregnancies. Identification of DVM in GDM pregnancies and its association with placental morphology and pregnancy outcomes will help to prevent its reoccurrence, reduce stillbirth and adverse perinatal outcomes in future pregnancies.

Materials and Methods

Study Setting

The present study was a prospective, comparative cross-sectional study, conducted at Obstetrics and Gynaecology Department, Karnataka Medical College and Research Institute (KMC-RI) and Department of Anatomy, KLE JGMM Medical College and Hospital Hubballi, for the period of one year from September 2024 to September 2025. After Human ethics committee approval with reg no: ECR/486/Inst/KA/2013/RR-16-04:2023-2024 and the Clinical Trials Registry India (CTRI) No: CTRI/2024/09/073403. Informed consent from the mother was obtained before the collection of placentas.

Study population

The GDM was diagnosed according to The Diabetes in Pregnancy Study Group India (DIPSI) criteria (10). The term placentas with gestational age from 37 to 42 weeks, either by vaginal or caesarean section were collected from both GDM and normal pregnancies. The confirmed cases of GDM pregnant females who were on treatment with diet, oral or insulin were included as the study group. And the placentas of pregnant women without any medical issues before pregnancy were included as a control group in the study. Women with overt diabetes, Rh-isoimmunization, hypertension, thyroid disorders and anaemia were excluded from the study.

Gross Examination

A total of 120 placentae, 60 placentae from normal and 60 placentae from GDM pregnancies were collected soon after the delivery. Membranes were trimmed, the umbilical cord was cut, gross examination of weight and diameter was obtained according to Saha S et al. (11). According to Amsterdam criteria (8), a full thickness of placental tissue from the central two-thirds of the placenta was obtained; excess maternal blood was washed away from the tissue and transferred in to an air tight container with 10% of formalin. Perinatal data was collected. The tissue was fixed for up to 24 hours, subjected to routine histological processing, 5-micron thickness of tissue was sectioned by a rotary microtome and was subjected to Haematoxylin and Eosin staining.

Histopathological Examination

The slides were evaluated for presence of DVM lesion by two blinded pathologists according to standard Amsterdam criteria (8). DVM is defined as a monotonous population of at least 10 villi with the presence of centrally placed capillaries, reduced vasculosyncytial membranes and continuous cytotrophoblastic layer. Common observations of DVM from both pathologists were recorded in GDM and normal placentas and its association with perinatal outcomes were assessed.

Statistical analysis

The data collected was entered in MS Office Excel 2019 and imported into SPSS software of version 25. The outcomes were presented in mean and standard deviation, numbers and percentage. Chi Square test and Fisher's Exact test were applied to find the association between DVM and perinatal outcomes. A Comparison between the two groups was done. The Shapiro-Wilk test was used to test normality. For qualitative data, the Chi Square test and Fisher's Exact test were applied, and for quantitative data, the Independent Sample t-test, Welch t-test and Mann-Whitney U test were applied. P value < 0.05 will be considered statistically significant.

Results

In the present study, out of 60 GDM placentas, 39 placentas and out of 60 normal placentas, 16 placentas were associated with DVM. DVM was observed more in GDM placentas compared to normal placentas, with statistically significant differences between both the groups (Table 1). The current study found an association of DVM with placental morphology like weight, diameter (Table 2) and maternal conditions and foetal outcomes like Maternal weight, Glycated Haemoglobin% and foetal weight with statistically significant differences between GDM and normal groups. Intrauterine foetal death, respiratory distress, foetal distress and NICU admissions were found in the GDM group but were not statistically significant compared to the normal group. No cases of foetal neurological or cardiac complication were found associated with DVM in both groups (Table 3).

Table 1. Delayed villous maturation in the GDM and normal placentas.

PARAMETER	GDM (60) %	NORMAL (60) %	p-value
DVM lesion	39 (65.0%)	16(26.7%)	0.000*

Note: Out of 60 placentas in each group, the presence of Delayed villous maturation (DVM) was found in 39 (65.0%) cases in Gestational Diabetes Mellitus (GDM) placentas and 16(26.7%) cases in normal placentas. Increased DVM was found in GDM placentas compared to normal placentas and were represented in numbers and percentage. The Chi Square test and Fisher's Exact test were applied for proportion. *P=< 0.05 was considered as statistically significant.

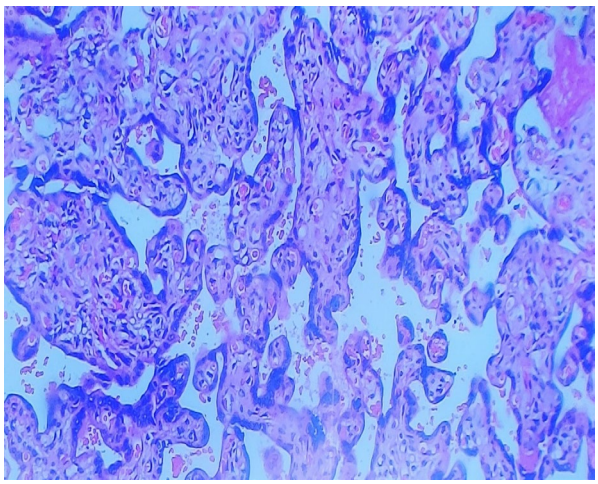

Fig. 1. Delayed Villous Maturation (DVM) in Gestational Diabetes Mellitus (GDM) placenta with predominance large immature villi, centrally placed capillaries and continuous cytotrophoblastic layer (H&E, 10x).

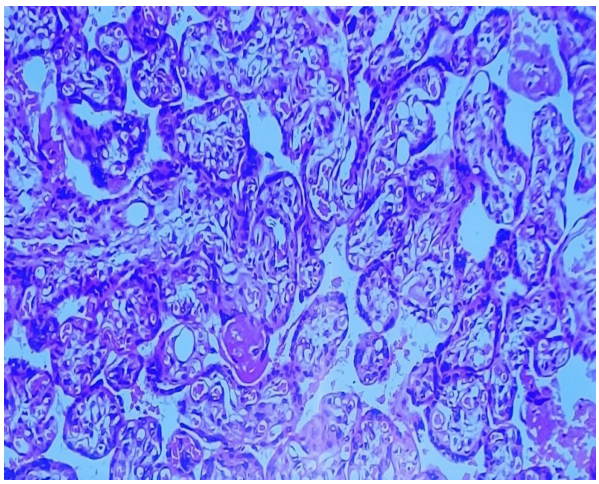

Fig. 2. Normal placenta with a predominance of mature terminal villi (H&E, 10x).

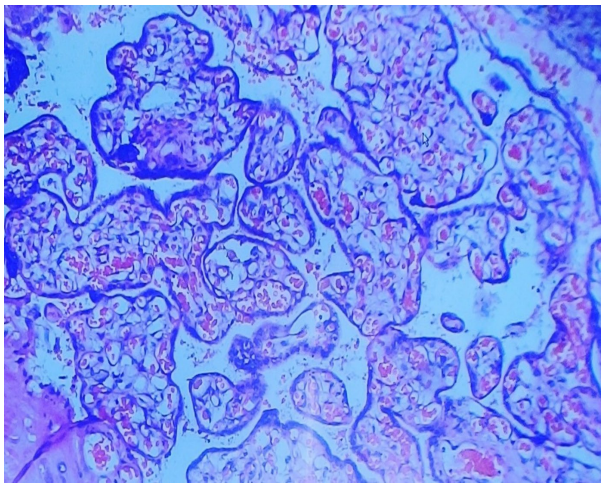

Fig. 3. Delayed Villous Maturation in Gestational Diabetes Mellitus (GDM) placenta associated with chorangiosis-increased number of capillaries in terminal villi (H&E, 10x).

Table 2. The association of DVM with the placental morphology in GDM and Normal pregnancy groups

PLACENTAL MORPHOLOGY	GDM (39 cases)	NORMAL (16 cases)	P value
Placental Weight(gms)	521.49 (67.98)	478.06 (94.82)	0.031*
Placental Diameter(cm)	21.17 (2.97)	18.59 (6.75)	0.000*

Note: 39 Delayed villous maturation (DVM) cases of Gestational Diabetes Mellitus (GDM) group and 16 DVM cases of Normal group were associated with placental morphology. The quantitative data like placental weight in grams and placental diameter in cm were represented with mean and standard deviation. The Independent Sample t-test, and Welch t-test for parametric data, and Mann-Whitney U test for non-parametric data were applied. DVM was found to be associated with increased placental weight and diameter in GDM placentas compared to normal placentas. *P=< 0.05 was considered as statistically significant.

Table 3. The association of DVM with maternal conditions and foetal outcomes in GDM and Normal pregnancy Groups

MATERNAL CONDITIONS	GDM (39 cases)	Normal (16 cases)	P value
Maternal Age (years)	27.64 (4.22)	25.31 (3.14)	0.052
Maternal weight (Kg)	68.77 (9.69)	59.50 (6.45)	0.000*
Gestational age (weeks)	37.90 (1.41)	38.06 (0.68)	0.883
Primi	13 (33.3%)	02 (12.5%)	0.184
Gravida	26 (66.7%)	14 (87.5%)	0.184
Normal delivery	09 (23.1%)	04 (25.0%)	1.000
Caesarean section	30 (76.9%)	12 (75.0%)	1.000
Glycated Haemoglobin%	5.31 (0.65)	4.61 (0.50)	0.001*
Diet	26 (66.7%)	-	
Oral	09 (23.1%)	-	
Insulin	04 (10.3%)	-	
FOETAL OUTCOMES			
Foetal weight (Kg)	3.17 (0.60)	2.80 (0.52)	0.006*
Apgar score at 1min	7.13 (1.99)	8.06 (1.24)	0.086
Apgar score at 5min	7.69 (1.79)	8.38 (1.09)	0.151
Alive	38 (97.4%)	16 (100.0%)	1.000
IUFD	01 (2.6%)	00 (0.0%)	1.000
High birth weight	01 (2.6%)	00 (0.0%)	1.000
Appropriate birth weight	31 (79.5%)	13 (81.2%)	1.000
Low birth weight	07 (17.9%)	03 (18.8%)	1.000
Respiratory distress	01 (2.6%)	00 (0.0%)	1.000
Foetal distress	14 (35.9%)	03 (18.8%)	0.336
IUGR	00 (0.0%)	01 (6.3%)	0.291
Congenital Anomalies	00 (0.0%)	01 (6.3%)	0.291
Male babies	18(46.2%)	11(68.8%)	0.127
Female babies	21(53.8%)	05(31.3%)	0.127
NICU admission	22 (56.4%)	08 (50.0%)	0.769

Note: 39 Delayed villous maturation (DVM) cases of Gestational Diabetes Mellitus (GDM) group and 16 DVM cases of the Normal group were associated with maternal condition and foetal outcomes. The Chi Square test and Fisher's Exact test were applied to find an association between the DVM and perinatal outcomes. A comparison between the two groups was done. The Shapiro-Wilk test was used to test normality. The quantitative data like maternal age, maternal weight, gestational age, glycated Haemoglobin, foetal weight and Apgar score at 1min and 5min were represented in mean and standard deviation. The Independent Sample t-test, and Welch t-test for parametric data, and Mann-Whitney U test for nonparametric data were applied. DVM was found to be associated with increased maternal weight, glycated haemoglobin, foetal weight in the Gestational Diabetes Mellitus (GDM) group with statistically significance compared to normal group. The qualitative data like primi, gravida, normal delivery, caesarean section, diet, oral, insulin, alive, Intra uterine foetal death (IUFD), high birth weight, appropriate birth weight, low birth weight, respiratory distress, foetal distress, Intrauterine growth retardation (IUGR), congenital anomalies, male babies, female babies and Newborn intensive care unit (NICU) admission were represented in numbers and percentage. The Chi Square test and Fisher's Exact test were used for proportions. DVM was found to be associated with foetal death in one of the cases of the GDM group, respiratory distress, foetal distress and NICU admissions were more in numbers in the GDM group but were not statistically significant compared to the normal group. No cases of foetal neurological or cardiac complication associated with DVM in both normal and GDM placentas were found. *P value < 0.05 was considered as statistically significant.

Discussion

The current study found an association of DVM with GDM placentas. Improper function of insulin receptors results in GDM, affecting placental morphology like weight and diameter, syncytial knots, villous oedema, chorangiosis and villous immaturity (12,3,4). Insulin resistance in GDM causes maternal complications like preterm labour, perinatal loss, type 2 diabetes, cardiovascular diseases, endothelial/vascular dysfunction and obesity (3,13). Foetal hyperglycaemia in GDM results in neonatal complication like IUGR, NICU admissions and foetal deaths (3).

Accelerated and Delayed Villous Maturation are two types of structural placental villi maturation

defects in which delayed villous maturation is a placental abnormality with varying range of severity (14,15). It is clinically associated with maternal diabetes (ranges between 81% -16.6%) obesity, increased weight gained during pregnancy, preterm infants, hypercoiling of the umbilical cord, congenital, chromosomal abnormalities, poor neurological outcome, neonatal hypoxic-ischemic encephalopathy, foetal growth retardation, foetal chronic disease, central nervous system disorders in both children and adults, intrauterine hypoxia and foetal death with an increased risk of recurrence in the future pregnancies (16,17). There is an increased chances of DVM occurrence in GDM than in prediabetes pregnancies. It is a histological hallmark in GDM placentas and is found to be increased up to six holds higher in GDM pregnancies (18,19,20).

The cause and pathophysiology of DVM is still not clear. It is believed that Hyperglycaemia, hyperinsulinemia in diabetic pregnancies and an increase in placental growth factors, maternal obesity, vascular changes and chromosomal abnormalities may result in the occurrence of DVM (21,22,7). DVM result into increased distance for diffusion making transplacental exchange of gas by passive diffusion. Thus, the placenta with DVM is inefficient at term because it is unable to meet the oxygen demand of a growing fetus (16). DVM is found to be often associated with chorangiosis and has similar histopathological features of villous oedema and foetal vascular malperfusion (9). Since DVM is associated with GDM and neonatal complications, it is important to identify the DVM in GDM placentas.

The present study found statistically significant increased DVM in GDM placentas compared to normal placentas (Table1 and Fig. 1 and Fig. 2), in line with us similar finding was found by Schafer-Graf UM et al. (23), Daskalakis G et al. (24), Madazli R et al. (25), Higgins M et al. (6), Giacometi C et al. (19) , Lai YM et al. (26), Dasgupta S et al. (27), El-Tarhouny SA et al. (28). DVM was also found in the non-GDM placentas of foetal death, spontaneous preterm labour, spontaneous preterm labour delivery with intact membranes and chronic foetal hypoxia. (29,30,31,32)

The present study noted, a statistically significant increased placental weight was associated with DVM in GDM placentas compared to normal placentas (Table 2), in agreement with us Sethy PP et al. (33) and Anjum S et al. (13) found similar finding in GDM placentas but without DVM. Whereas Higgins M et.al (6), found similar association in non GDM placentas with DVM compared to normal placentas without DVM. The association of DVM with increased placental weight results into utilization of nutrients and gases by the enlarged placenta itself leaving less availability of nutrients and oxygen for growing foetus this results into decreased capacity in foetus to withstand hypoxia in third trimester (7).

The current study observed, a statistically significant increased placental diameter was associated with DVM in GDM placentas compared to normal placentas (Table 2). Similar association was found by RafahHadyLateef et al. (34) and Anjum S et al. (13) in GDM placentas but without DVM, whereas Sethy PP et al. (33) found no statistically significant increase placental diameter between GDM and normal placentas.

The current study found a statistically significant increased maternal weight was associated with DVM in the GDM group compared to the normal group (Table 3). In Harmony with us similar finding was found by Tayel SM. et al. (35) in the GDM group of placentas without DVM. Whereas O' Hare CB et al. (36) found, association of DVM with increase maternal weight in foetal congenital heart disease. On contrary Krstevska SS et al. (37) did not find a statistically significant increase in maternal weight between GDM and Normal groups. The association of DVM with maternal diabetes and obesity will result in addition metabolic stress, causing foetus to have reduced capacity to withstand hypoxia in the last trimester and intrapartum period (7).

The present study found a statistically significant increase in Glycated Haemoglobin and was associated with DVM in the GDM group compared to the normal group (Table No. 3). In Harmony with us, similar finding was found by El-Tarhouny SA et al. (28) and Arizawa M et al. (38) Whereas Edu A et al. (39) also found similar finding in GDM group of placentas but without DVM. Higgins MF et al. (22) states that, occurrence of DVM in diabetic pregnancies may be due to hyperglycaemia.

The current study found an association of DVM in GDM mothers who were on diet, oral and medication treatment. In agreement with us, Giacometi C et al. (19) and Natarajan L et al. (40) found similar findings. Arshad R et al. (41) suggested that treating the GDM condition with metformin will result in better outcomes than treating with diet and exercise.

The present study found a statistically significant increase in foetal weight was associated with DVM in GDM groups compared to the normal group (Table No. 3). In line with us, Venkatesh MK et al. (42) and Sethy PP et al. (33) found similar findings in GDM placentas but without DVM. In agreement with our study, Higgins M et al. (6) found a similar association of increased foetal weight with DVM placentas without GDM condition. In contrast to our findings, Al-Adnani M et al. (16) states that there is active transport of glucose and amino acids across the placenta to facilitate diffusion, because of this diffusion, there is sufficient growth of fetus in the placentas with DVM.

In addition to the above finding, the present study observed DVM with chorangiosis in a GDM placenta (Fig. 3) and is in agreement with Soni S et al. (9).

Higgins M et al. (6) states that, not all pregnancies complicated with Diabetes Mellitus will show DVM. DVM occurs in late pregnancy and poses a threat if the

foetus remains in utero after 37 weeks of gestation (43). There is no ultrasound marker for detection of DVM and no safe methods for prenatal detection of children at risk. Adverse foetal effects caused due to DVM cannot be detected using Apgar score or cord pH, thus making early diagnosis a great clinical challenge (6,44,6). In cases of DVM, the foetus may be saved by early induction of the mother. Rescue by birth can be a better option to prevent newborn complications (44). Soni S et al. (9) states, the current management can only provide clinical practices for the following pregnancies. The present study agrees with the clinical implication of the DVM suggested by Matsika A (45) that, the pregnant woman should be screened for maternal diabetes, review of her previous test report and in her future pregnancy, obesity should be avoided, foetal movements should be monitored in her third trimester, special obstetric care, if required early delivery to avoid adverse foetal morbidity and mortality.

The strength of our study is that it is a rare study among North Karnataka population that found DVM and its association with placental morphology and perinatal outcomes in the GDM compared to normal placentas, unlike previous studies where only the presence of DVM without its association with placental morphology and perinatal outcomes in GDM placentas were recorded. Use of standard Amsterdam criteria for assessing DVM makes our results to be compared with results of other international studies with the same criteria. The limit of our study is small sample size and less literature availability on DVM in GDM placentas.

Conclusion

The present study found a statistically significant increased presence of DVM in GDM placentas and its association with placental weight, diameter, maternal weight, glycated haemoglobin and foetal weight compared to normal placentas. In addition, the current study also found presence of DVM with chorangiosis in a GDM placenta. Intrauterine foetal death, respiratory distress, foetal distress and NICU admissions were found in placentas of the GDM group but were not statistically significant compared to placentas normal group.

Postnatal placental evaluation of DVM can provide information pertaining to a current GDM pregnancy and its outcomes. Considering the risk of reoccurrence of DVM and type 2 diabetes in the future, it should be essentially reported in the routine histopathological placental examination. Presence of DVM in GDM placentas suggests of suboptimal hyperglycaemia and placental insufficiency. This may explain the cause of intrauterine foetal deaths and adverse neonatal outcomes in the current pregnancy and in future pregnancies it indicates a need for comprehensive maternal care and helps in prediction and prevention of adverse perinatal outcomes by implementing Rescue by birth. Our study clinically implies that obstetricians should identify the DVM in GDM pregnancies and its associations with placental, maternal and foetal outcomes. Since there is no antenatal ultrasound marker to detect placental DVM and no safe methods for prenatal detection of adverse neonatal outcomes caused due to DVM in GDM pregnancies, thus our current study highlights that timely diagnosis and intervention of GDM may reduce the occurrence of DVM.

Acknowledgments

None

Authors' Contributors

1st: Conception and design of the study, Interpretation of slides, review of literature, data analysis, results and writing the manuscript; 2nd: Revision of the manuscript; 3rd: Interpretation of slides and revision of the manuscript; 4th: Revision of the manuscript, 5th: Interpretation of slides and revision of the manuscript.

Data Availability

The datasets generated and analyzed during the current study are not publicly available; however, the data can be shared for research and authentication purposes upon reasonable request.

Funding

This research received no specific grant from any funding agency in the public, commercial, or not-for-profit sectors.

Ethics Approval

Informed patient consent was obtained before preparing the manuscript. All patient-related data are anonymised. The present study was a prospective, comparative cross-sectional study, conducted at Obstetrics and Gynecology Department, Karnataka Medical College and Research Institute (KMC-RI) and Department of Anatomy, KLE JGMM Medical College and Hospital Hubballi, for the period of one year from September 2024 to September 2025. After Human ethics committee approval with reg no: ECR/486/Inst/KA/2013/RR-16-04:2023-2024 and the Clinical Trials Registry India (CTRI) No: CTRI/2024/09/073403. Informed consent from the mother was obtained before the collection of placentas.

.

Conflict of Interest

The authors declared no conflict of interest.

References

1. Abdelghany AH, Eissa TM, Idris S. Study of the ultrastructure of the placenta in gestational diabetes mellitus. Int J Anat Var. 2018;11(1):4-10.

2. Sundari Amirthakatesan A, Devi Chandramohan S, Gurusamy U. The histomorphological spectrum of placenta in growth restricted fetuses in a tertiary care centre in South India. Iran J Pathol. 2023;18(1):12-23. [DOI:10.30699/ijp.2023.551426.2867] [PMID] [PMCID]

3. Dharmalingam M, Murugan T, Rajamani P. Placental abnormalities and neonatal outcomes in gestational diabetes: a case-control study in northeast Tamil Nadu. SSR Inst Int J Life Sci. 2024;10(5):6145-54. [DOI:10.21276/SSR-IIJLS.2024.10.5.5]

4. Ehlers E, Talton OO, Schust DJ, Schulz LC. Placental structural abnormalities in gestational diabetes and when they develop: a scoping review. Placenta. 2021;116:58-66. [DOI:10.1016/j.placenta.2021.04.005] [PMID] [PMCID]

5. Korteweg FJ, Erwich JJ, Holm JP, Ravise JM, van der Meer J, Veeger NJ, et al. Diverse placental pathologies as the main causes of fetal death. Obstet Gynecol. 2009;114(4):809-17. [DOI:10.1097/AOG.0b013e3181b72ebe] [PMID]

6. Higgins M, McAuliffe FM, Mooney EE. Clinical associations with a placental diagnosis of delayed villous maturation: a retrospective study. Pediatr Dev Pathol. 2011;14(4):273-9. [DOI:10.2350/10-07-0872-OA.1] [PMID]

7. Redline RW. Distal villous immaturity. Diagn Histopathol. 2012;18(5):189-94. [DOI:10.1016/j.mpdhp.2012.02.002]

8. Khong TY, Mooney EE, Ariel I, Balmus NC, Boyd TK, Brundler MA, et al. Sampling and definitions of placental lesions: Amsterdam placental workshop group consensus statement. Arch Pathol Lab Med. 2016;140(7):698-713. [DOI:10.5858/arpa.2015-0225-CC] [PMID]

9. Soni S, Stevens A, Batra G, Heazell AE. Characterising delayed villous maturation: a narrative literature review. Placenta. 2024;158:48-56. [DOI:10.1016/j.placenta.2024.09.020] [PMID]

10. Seshia V, Balaji V, Balaji MS, Sekar A, Sanjeevi CB, Green A. One step procedure for screening and diagnosis of gestational diabetes mellitus. J Obstet Gynecol India. 2005;55(6):525-9.

11. Saha S, Biswas S, Mitra D, Adhikari A, Saha C. Histologic and morphometric study of human placenta in gestational diabetes mellitus. Ital J Anat Embryol. 2014;119(1):1-9.

12. Shao J, Catalano PM, Yamashita H, Ruyter I, Smith S, Youngren J, et al. Decreased insulin receptor tyrosine kinase activity and plasma cell membrane glycoprotein-1 overexpression in skeletal muscle from obese women with gestational diabetes mellitus (GDM): evidence for increased serine/threonine phosphorylation in pregnancy and GDM. Diabetes. 2000;49(4):603-10. [DOI:10.2337/diabetes.49.4.603] [PMID]

13. Anjum S. Histomorphological alterations of placenta in normal vs gestational diabetes mellitus subjects: a case-control study. Int J Anat Radiol Surg. 2021;10(4):AO20-5. [DOI:10.7860/IJARS/2021/48786:2698]

14. Seidmann L, Suhan T, Unger R, Gerein V, Kirkpatrick CJ. Imbalance of expression of bFGF and PK1 is associated with defective maturation and antenatal placental insufficiency. Eur J Obstet Gynecol Reprod Biol. 2013;170(2):352-7. [DOI:10.1016/j.ejogrb.2013.06.045] [PMID]

15. Treacy A, Higgins M, Kearney JM, McAuliffe F, Mooney EE. Delayed villous maturation of the placenta: quantitative assessment in different cohorts. Pediatr Dev Pathol. 2013;16(2):63-6. [DOI:10.2350/12-06-1218-OA.1] [PMID]

16. Al-Adnani M, Marnerides A, George S, Nasir A, Weber MA. Delayed villous maturation in placental reporting: concordance among consultant pediatric pathologists at a single specialist center. Pediatr Dev Pathol. 2015;18(5):375-9. [DOI:10.2350/12-02-1604-OA.1] [PMID]

17. Turowski G, Vogel M. Review and view on maturation disorders in the placenta. APMIS. 2018;126(7):602-12. [DOI:10.1111/apm.12858] [PMID]

18. Huynh J, Yamada J, Beauharnais C, Wenger JB, Thadhani RI, Wexler D, et al. Type 1, type 2 and gestational diabetes mellitus differentially impact placental pathologic characteristics of uteroplacental malperfusion. Placenta. 2015;36(10):1161-6. [DOI:10.1016/j.placenta.2015.08.004] [PMID] [PMCID]

19. Giacometi C, Ludwig K, Guidi M, Colantuono E, Coracina A, Rigano M, et al. Gestational diabetes-placental expression of human equilibrative nucleoside transporter 1 (heNT1): is delayed villous maturation an adaptive pattern? Diagnostics (Basel). 2023;13(1):12. [DOI:10.3390/diagnostics13122034] [PMID] [PMCID]

20. Arcot A, Walker RE, Gallagher K, Goldstein JA, Gernand AD. Gestational diabetes mellitus and vascular malperfusion lesions in the placenta: a systematic review and meta-analysis. Int J Gynaecol Obstet. 2025;170:1071-83. [DOI:10.1002/ijgo.70127] [PMID] [PMCID]

21. Seidmann L, Suhan T, Unger R, Gerein V, Kirkpatrick CJ. Transient CD15-positive endothelial phenotype in the human placenta correlates with physiological and pathological fetoplacental immaturity. Eur J Obstet Gynecol Reprod Biol. 2014;180:172-9. [DOI:10.1016/j.ejogrb.2014.06.022] [PMID]

22. Higgins MF, Russell NM, Mooney EE, McAuliffe FM. Clinical and ultrasound features of placental maturation in pre-gestational diabetic pregnancy. Early Hum Dev. 2012;88(11):817-21. [DOI:10.1016/j.earlhumdev.2012.06.001] [PMID]

23. Schafer-Graf UM, Dupak J, Vogel M, Dudenhausen JW, Kjos SL, Buchanan TA, et al. Hyperinsulinism, neonatal obesity and placental immaturity in infants born to women with one abnormal glucose tolerance test value. J Perinat Med. 1998;26(1):27-36. [DOI:10.1515/jpme.1998.26.1.27] [PMID]

24. Daskalakis G, Marinopoulos S, Krielesi V, Papapanagiotou A, Papantoniou N, Mesogitis S, et al. Placental pathology in women with gestational diabetes. Acta Obstet Gynecol Scand. 2008;87(4):403-7. [DOI:10.1080/00016340801908783] [PMID]

25. Madazli R, Tuten A, Calay Z, Uzun H, Uludag S, Ocak V. The incidence of placental abnormalities, maternal and cord plasma malondialdehyde and vascular endothelial growth factor levels in women with gestational diabetes mellitus and nondiabetic controls. Gynecol Obstet Invest. 2008;65(4):227-32. [DOI:10.1159/000113045] [PMID]

26. Lai YM, Tan GC, Shah SA, Rahman RA, Saleh MFM, Mansor S, et al. Non-hypertensive gestational diabetes mellitus: placental histomorphology and its association with perinatal outcomes. Placenta. 2024;147:21-7. [DOI:10.1016/j.placenta.2024.01.012] [PMID]

27. Dasgupta S, Banerjee U, Mukhopadhyay P, Maity P, Saha S, Das B. Clinicopathological study and immunohistochemical analysis of expression of annexin A5 and apelin in human placentae of gestational diabetes mellitus. Diabetes Metab Syndr. 2022;16(3):102435. [DOI:10.1016/j.dsx.2022.102435] [PMID]

28. El-Tarhouny SA, Almasry SM, Elfayomy AK, Baghdadi H, Habib FA. Placental growth factor and soluble Fms-like tyrosine kinase 1 in diabetic pregnancy: a possible relation to distal villous immaturity. Histol Histopathol. 2014;29(2):259-72.

29. Jaiman S, Romero R, Pacora P, Jung E, Bhatti G, Yeo L, et al. Disorders of placental villous maturation in fetal death. J Perinat Med. 2020;48(4):345-68. [DOI:10.1515/jpm-2020-0030] [PMID] [PMCID]

30. Jaiman S, Romero R, Pacora P, Erez O, Jung E, Tarca AL, et al. Disorders of placental villous maturation are present in one-third of cases with spontaneous preterm labor. J Perinat Med. 2021;49(4):412-30. [DOI:10.1515/jpm-2020-0138] [PMID] [PMCID]

31. Jaiman S, Romero R, Bhatti G, Jung E, Gotsch F, Suksai M, et al. The role of the placenta in spontaneous preterm labor and delivery with intact membranes. J Perinat Med. 2022;50(5):553-66. [DOI:10.1515/jpm-2021-0681] [PMID] [PMCID]

32. Jaiman S, Romero R, Pacora P, Jung EJ, Kacerovsky M, Bhatti G, et al. Placental delayed villous maturation is associated with evidence of chronic fetal hypoxia. J Perinat Med. 2020;48(5):516-8. [DOI:10.1515/jpm-2020-0014] [PMID] [PMCID]

33. Sethy PP, Ghosh S, Nanda S, Sahu M. Clinicopathological comparison of histopathology of placentae in GDM compared with that of uncomplicated pregnancy and perinatal outcome in GDM mothers in different interventions in pregnancy. J Popul Ther Clin Pharmacol. 2024;31(5):1285-94.

34. Lateef RH, AbdAlzahra JM. Placental vasculogenesis and angiogenesis related to GDM and the possible affect on the placenta and the fetus outcome. Med Legal Update. 2020;20(4):1962-9.

35. Tayel SM, Zaki MG, Metwally ES. Morphometric and structural changes of the placenta of gestational diabetics. Am J Clin Anat Physiol. 2021;3(1):5-9.

36. O'Hare CB, Mangin-Heimos KS, Gu H, et al. Placental delayed villous maturation is associated with fetal congenital heart disease. Am J Obstet Gynecol. 2023;228(2):231.e1-231.e11. [DOI:10.1016/j.ajog.2022.08.013] [PMID] [PMCID]

37. Krstevska SS, Nakova VV, Samardziski I, Bosku AA, Todorovska I, Sima A, et al. Perinatal outcome in gestational diabetes mellitus vs normoglycemic women. Biomed J Sci Tech Res. 2020;26(2):19882-8. [DOI:10.26717/BJSTR.2020.26.004338]

38. Arizawa M, Nakayama M, Kidoguchi K. Correlation of placental villous immaturity and dysmaturity with clinical control of maternal diabetes. Nihon Sanka Fujinka Gakkai Zasshi. 1991;43(6):595-602.

39. Edu A, Teodorescu C, Dobjanschi CG, Socol ZZ, Teodorescu V, Matei A, et al. Placenta changes in pregnancy with gestational diabetes. Rom J Morphol Embryol. 2016;57(2):507-12.

40. Natarajan L, Maheswari GU. Gestational hyperglycemia on diet and medication: impact on placental pathology and pregnancy outcomes. Int J Reprod Contracept Obstet Gynecol. 2019;8(8):3350-6. [DOI:10.18203/2320-1770.ijrcog20193564]

41. Arshad R, Kanpurwala MA, Karim N, Hassan JA. Effects of diet and metformin on placental morphology in gestational diabetes mellitus. Pak J Med Sci. 2016;32(6):1522-7. [DOI:10.12669/pjms.326.10872] [PMID] [PMCID]

42. Venkatesh MK, Shetty SK, Chaithra GV. Morphological and histopathological features of placenta in women with gestational diabetes mellitus and its association with perinatal outcome. J South Asian Feder Obs Gynae. 2024;16(S1):S1-6. [DOI:10.5005/jp-journals-10006-2389]

43. Marijnen MC, Ganzevoort W, Gordijn SJ, van der Meeren LE. Delayed villous maturation with and without fetal demise: a case report of three successive pregnancies. J Obstet Gynaecol Res. 2025;51(5):1-7. [DOI:10.1111/jog.16308] [PMID] [PMCID]

44. Stallmach T, Hebisch G, Meier K, Dudenhausen JW, Vogel M. Rescue by birth: defective placental maturation and late fetal mortality. Obstet Gynecol. 2001;97(4):505-9. [DOI:10.1097/00006250-200104000-00005] [PMID]

45. Matsika A. Clinical correlates of histopathological entities of the placenta. Aust J Gen Pract. 2021;50(1-2):62-9. [DOI:10.31128/AJGP-11-19-5154] [PMID]