Iranian Journal of Pathology | ISSN: 2345-3656

Prognostic Impact of CD8+ and CD4+ Tumor-Infiltrating Lymphocytes and Perineural/Vascular Invasion in Laryngeal Squamous Cell Carcinoma

Maryam Lotfi[1], Mina Majdi[1], Parin Tanzifi[2], Tahereh Yousefi[1], Elham Nazar[3], Aysan Nozheh[4*]

1. *Department of Pathology, Amir-Alam Hospital Complex, Tehran University of Medical Sciences, Tehran, Iran*
2. *Department of Pathology, Douglass Hanly Moir Pathology, New South Wales, Australia*
3. *Department of Pathology, Sina Hospital, Tehran University of Medical Sciences, Tehran, Iran*
4. *Department of Pathology, Cancer Institute, Imam Khomeini Hospital Complex, Tehran University of Medical Sciences, Tehran, Iran*

KEYWORDS

Laryngeal squamous cell carcinoma, CD4+, CD8+, T lymphocytes, lymph node metastasis, histologic grading

Scan to discover online

Main Subjects:
Head and Head and Neck Pathology

Received 24 Jul 2025;
Accepted 03 Feb 2026;
Published Online 20 Feb 2026;

10.22034/ijp.2026.2066899.3493

ABSTRACT

Background & Objective: Squamous cell carcinoma (SCC) is characterized by infiltration of CD4+ and CD8+ T lymphocytes, which represent an early host immune response against malignant cells. This immune response may inhibit tumor progression and suppress malignancy. This study aimed to evaluate the density of CD4+ and CD8+ lymphocytes and their ratio within tumor nests and surrounding stroma in conventional laryngeal SCC. It also examined associations with prognostic factors such as regional lymph node metastasis, tumor histologic differentiation, vascular invasion, and perineural invasion.

Methods: This retrospective study analyzed 54 laryngeal SCC samples from patients who underwent total laryngectomy and cervical lymph node dissection without prior neoadjuvant chemoradiation therapy. Immunohistochemistry was used to assess CD4+ and CD8+ T lymphocytes in tumor nests and surrounding stroma. Statistical analyses evaluated correlations between lymphocyte infiltration and prognostic factors, including lymph node metastasis, histologic differentiation, vascular invasion, and perineural invasion.

Results: A significant association was found between high intratumoral CD8+ T lymphocyte density and a lower incidence of vascular and perineural invasion (mean, 10.9 cells/HPF vs 4.5 cells/HPF; p = 0.03). No significant correlations were observed between lymphocyte density and lymph node metastasis or tumor histologic differentiation.

Conclusion: High intratumoral CD8+ T-cell infiltration correlates with reduced vascular and perineural invasion in laryngeal SCC, suggesting a protective role in limiting tumor invasiveness. These findings highlight the prognostic significance of CD8+ T lymphocytes and warrant further research into immune mechanisms affecting SCC progression and patient outcomes.

Corresponding Information: **Aysan Nozheh**, Department of Pathology, Cancer Institute, Imam Khomeini Hospital Complex, Tehran University of Medical Sciences, Tehran, Iran. Email: a-nozheh@razi.tums.ac.ir

Copyright © 2026. This is an open-access article distributed under the terms of the **Creative Commons Attribution 4.0 International License (CC BY 4.0)**, which permits unrestricted use, distribution, and reproduction in any medium, provided the original work is properly cited. The license also allows users to adapt, remix, transform, and build upon the material for any purpose, including commercial use.

Introduction

Laryngeal squamous cell carcinoma is one of the most common smoking-related head and neck cancers, which accounts for significant mortality and morbidity in the 5th decade of life, with a higher frequency in men. In the United States, laryngeal SCC accounts for 2.2% of male cancers and 0.4% of female cancers (1, 2). Laryngeal cancer, a prevalent malignancy of the upper respiratory tract, has consistently presented significant challenges to global public health (3, 4). More than 95% of malignancies in the larynx are squamous cell carcinomas (5).

Smoking and alcohol, as with other malignancies in the head and neck region, play important roles as major risk factors for laryngeal cancer (6-8), although in our country, opium addiction associated with smoking is a prevalent risk factor (9). Patients affected by laryngeal SCC are also at risk of a second malignancy in the upper aerodigestive tract or lung (9). In a retrospective study performed on the epidemiology of laryngeal SCC in Tehran at Imam Khomeini Hospital, the peak incidence was found in the 6th and 7th decades of life. SCC was the most common type of cancer, and the larynx was the second most common location of malignancy after the oral cavity in the head and neck region (9, 10). The most common site of metastasis of laryngeal SCC is the regional lymph nodes and subsequently the lung. Tumor TNM staging, site, microscopic grade, size, and number of metastatic lymph nodes are the most

important prognostic factors. Other factors include p53 overexpression and survivin, which are considered poor prognostic factors (11-20). On histologic examination, the presence of tumor-infiltrating lymphocytes as the first-line host reaction against tumor cells and disease progression is an important finding; however, this response is often insufficient (21).

In this regard, the main populations of tumor-infiltrating lymphocytes are CD4+ and CD8+ T cells and other various subsets (e.g., CD56+ NK cells, Foxp3+ immunosuppressive regulatory T cells) (16). The balance between effector and regulatory T cells has prognostic significance in the outcome of head and neck cancers (22). Most solid tumors present MHC class I and subsequently are targets for CD8+ T cells as the main effector cells in the host immune reaction against malignancy; although both CD4+ and CD8+ T cells are needed for efficient immunity against tumors (23, 24). CD4+ T cells play roles as initiators of differentiation, expansion, and trafficking of CD8+ T cells (25). Also, CD4+ lymphocytes, by production of cytokines, augment the cytotoxic activity of CD8+ T cells and other inflammatory cells (26, 27). A distinct subset of CD4+ T cells called regulatory T cells leads to poor prognosis and disease progression in patients with laryngeal squamous cell carcinoma by deregulation of the immune system (28); however, a study showed increased CD4+ T cells and also CD8+ T cells associated with response to definitive chemotherapy in head and neck cancers (29).

Despite recent improvements in surgical techniques and the use of adjuvant therapies, there has been no significant decrease in the mortality and morbidity of laryngeal SCC (30). The characterization of tumor-infiltrating lymphocytes (TILs) and other immune cell populations has emerged as a promising prognostic approach in this regard. Recent evidence suggests that the density of TILs and CD66b+ neutrophils may help predict the prognosis of patients with laryngeal squamous cell carcinoma after surgery (31).

Recent studies highlight the prognostic significance of the immune microenvironment in laryngeal carcinoma, demonstrating that increased CD3+, CD20+, and CD4+ lymphocyte infiltration correlates with improved survival outcomes (32). Evidence from a large cohort analysis of 283 laryngeal squamous cell carcinoma cases showed that higher tumor-infiltrating lymphocyte (TIL) density—particularly in node-positive patients—was independently associated with reduced risks of relapse and death, underscoring TIL density as a significant prognostic marker in LSCC (33).

Our purpose is to determine the association between tumor-infiltrating lymphocytes and tumor prognostic factors such as histologic grade, lymph node metastasis, and vascular/perineural invasion in laryngeal SCC.

Materials and Methods

It was retrospectively analyzed in 54 patients who suffered from glottic, supraglottic, subglottic, and transglottic conventional SCC of the larynx and underwent total laryngectomy and lymph node dissection. Patients who received chemoradiation or had distant metastasis were excluded. Paraffin blocks were collected from the Pathology Department databases of Amir-Alam and Imam Khomeini Hospitals, Medical College of Tehran University, between March 2011 and June 2013. After review of the prepared slides by two board-certified pathologists, all cases were histopathologically classified into subgroups. Among the 54 studied cases, 29 were diagnosed as well-differentiated squamous cell carcinoma, 24 as moderately differentiated, and 1 case as poorly differentiated. Subsequently, the presence or absence of vascular/perineural invasion or lymph node metastasis was recorded.

All paraffin blocks were sectioned at 3-µm thickness, and after deparaffinization and dehydration, immunohistochemical staining for primary anti-CD4 (mouse monoclonal antibody CD4 [clone 4B12], Biogenex) (Figure 1) and anti-CD8 (mouse monoclonal antibody CD8 [clone 1A5], Novocastra) (Figure 2), based on the company's instruction protocol, was performed.

Tonsillar tissue was used as a positive control.

The total number of labeled CD4+ and CD8+ T cells in 10 microscopic fields at a magnification of ×400 in tumor islands and intervening stroma was counted twice, and then the mean value was obtained.

Statistical calculations were performed using SPSS version 17 for Windows. Qualitative data were reported as percentages with 95% confidence intervals, and quantitative data were reported as mean values and standard deviations of TILs among the groups. Qualitative data among the groups were compared using an independent-samples t test.

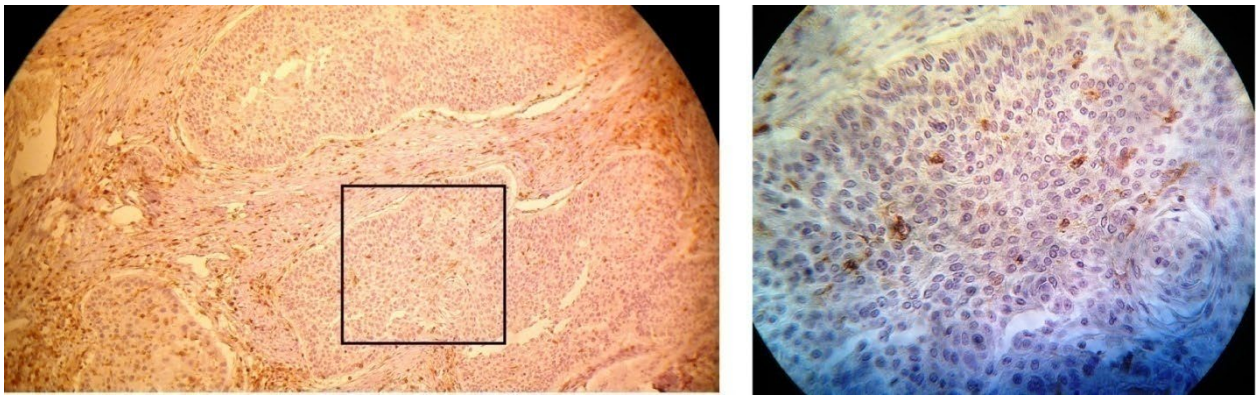

Fig. 1. Intratumoral immunostaining for CD4 (brown) using x400 magnification in the right panel, low power field of intratumoral and stromal CD4 staining in the left panel

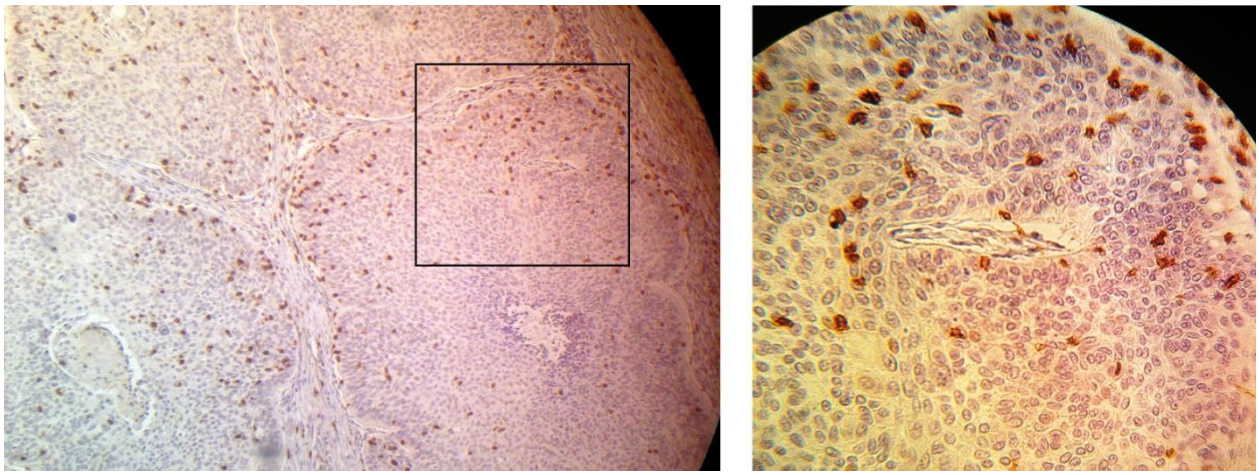

Fig. 2. Intratumoral immunostaining for CD8 (brown) using x400 magnification in the right panel, low power field of intratumoral and stromal CD8 staining in the left panel

Results

Among 54 patients, 53 cases were male (98.2%) and one case was female (1.8%). So gender predilection in this study and its correlation with prognostic factors did not have any statistical significance.

The age range was between 39 and 84 years, with a mean value of 59.85 years.

29 cases (53.7%) of the total 54 studied cases, diagnosed as well-differentiated SCC, 24 cases (44.5%) as moderate, and one case was diagnosed as poorly differentiated. Since the comparison of one patient with poorly differentiated SCC against 29 and 24 cases in other groups did not have statistical significance, this case was excluded from the comparison of tumor grading with other variables, and all analyses were performed on two groups of well- and moderately differentiated SCC.

In 12 cases (22.2%), a metastatic tumor in dissected lymph nodes was observed, and in the remaining 42 cases (77.8%), no lymph node involvement was seen.

In 7 cases (13%), perineural invasion was found in the stroma, and one case (1.8%) showed vascular invasion. 46 remaining cases did not show any vascular or perineural invasion.

Since placing one case with vascular invasion in a separate group against 7 and 46 cases in other groups did not worth statistical, so we analyzed cases in two groups as “with “and “without vascular/perineural invasion”.

In 32 cases (59.3%) tumor extended trans glottis, 16 (29.6%) supraglottic, 5 cases in the glottis region (9.3%), and one case (1.8%) was located in the subglottic area.

According to the calculated P-value of each group, there is no significant difference between the mean value of CD4+, CD8+ TIL, and also CD4+/CD8+ ratio in tumor nest and stroma with tumor location in the larynx.

The mean ± SD value of CD4+ intratumoral and stromal lymphocytes in 12 cases with metastatic lymph nodes (22.2%) was 5.39±9.25 and 32.50±44.8, respectively, and in 42 cases (77.7%) without metastatic lymph nodes was 3.09±3.59 and 34.4±26.12, respectively. Although the mean number of intratumoral CD4+ was higher in patients with metastatic lymph nodes, and stromal CD4+ lymphocytes were higher in non-metastatic nodes, there was no significant difference between the two

groups (P-value=0.416 and 0.887, respectively). (Figure 3-4)

The mean ± SD values of CD8+ intratumoral and stromal lymphocytes were 8.86±12.56 and 49.82±26.98 in 12 cases with metastatic lymph nodes (22.2%), and 11.26±10.30 and 51.05±26.26 in 42 cases (77.7%) without metastatic lymph nodes, respectively. However, the mean number of stromal and intratumoral CD8+ lymphocytes was higher in non-metastatic nodes; there was no statistical significance between the two groups (P-value=0.706 and 0.88, respectively). (figure 5-6)

The mean value of CD4+/CD8+ lymphocytes in tumoral nests and stroma in 12 cases with metastatic lymph nodes (22.2%) was 1.62±3.91 and 0.562±0.536, respectively, and in 42 cases (77.7%) without metastatic lymph nodes was 0.736±0.904 and 0.797±0.677, respectively.

Nevertheless, there was no significant difference between the two groups (P-value=0.453 and 0.292, respectively).

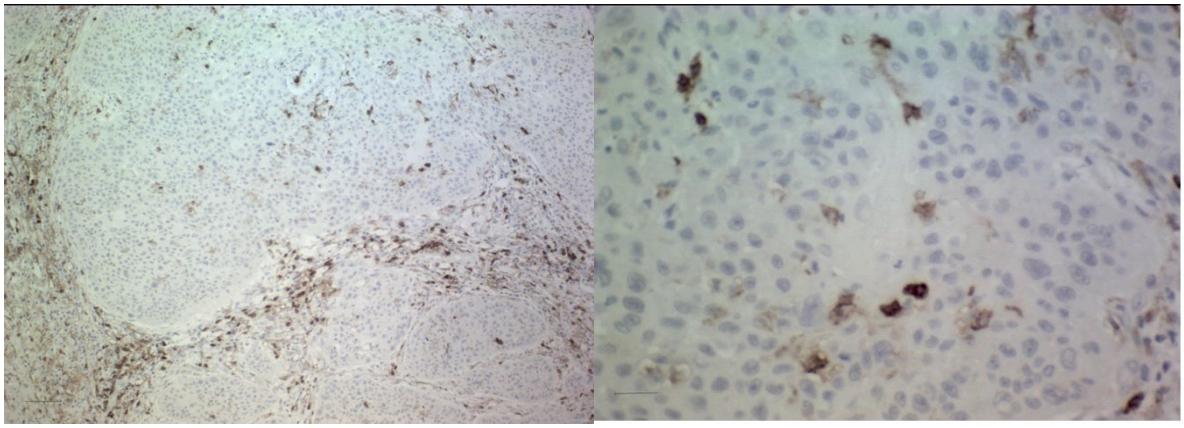

Fig. 3. Intratumoral immunostaining for CD4 (brown) using x400 magnification in the right panel, low power field of intratumoral and stromal CD4 staining in the left panel, in a case without metastatic lymph nodes.

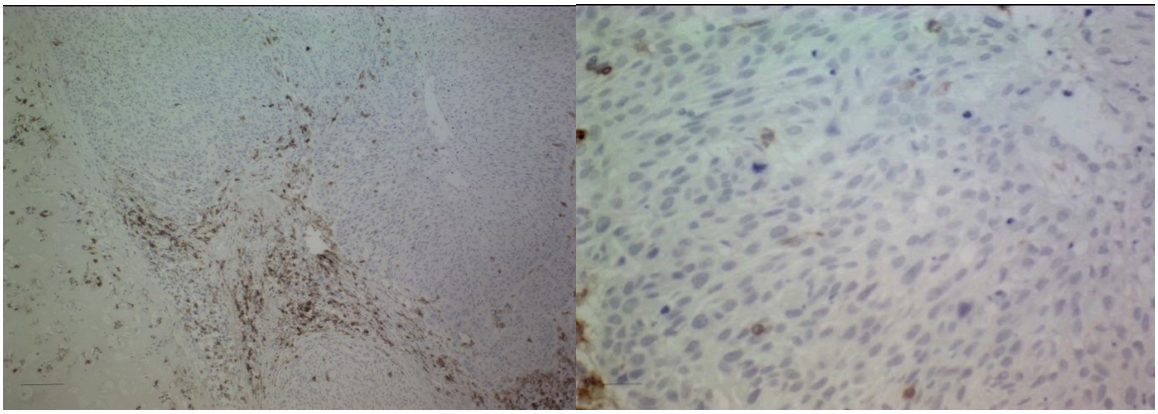

Fig. 4. Intratumoral immunostaining for CD4 (brown) using x400 magnification in the right panel, low power field of intratumoral and stromal CD4 staining in the left panel, in a case with metastatic lymph nodes.

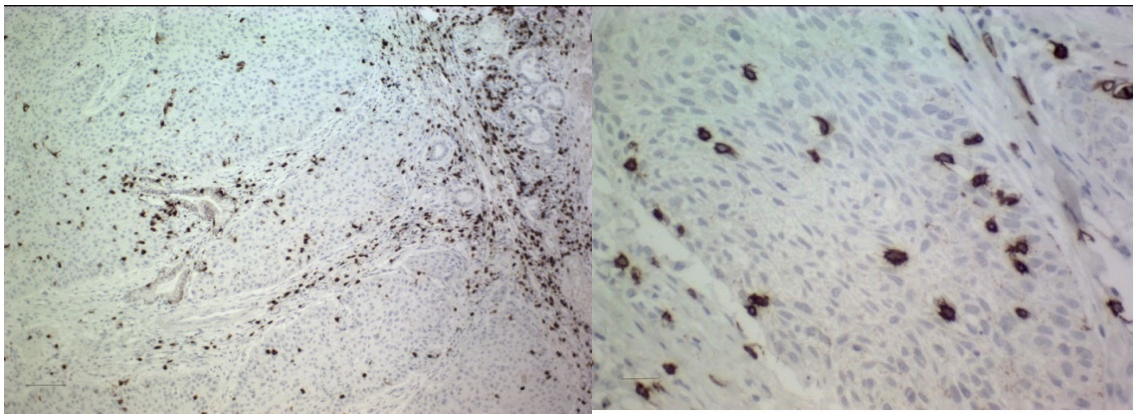

Fig. 5. Intratumoral immunostaining for CD8 (brown) using x400 magnification in the right panel, low power field of intratumoral and stromal CD8 staining in the left panel, in a case without metastatic lymph nodes.

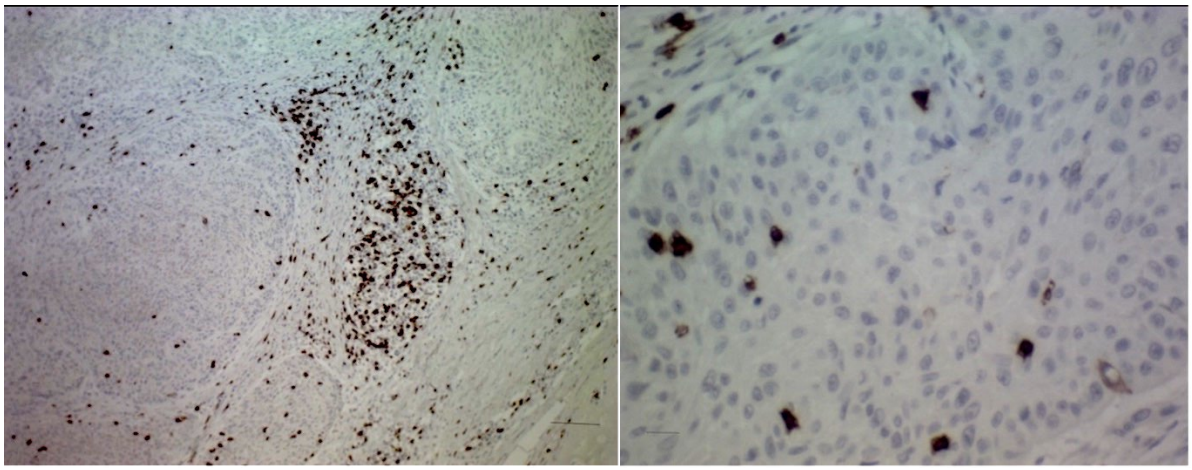

Fig. 6. Intratumoral immunostaining for CD8 (brown) using x400 magnification in the right panel, low power field of intratumoral and stromal CD8 staining in the left panel, in a case with metastatic lymph nodes.

Table 1 and Figure 7 show a comparison of CD4+, CD8+, and CD4+/CD8+ ratio count in tumor nest and stroma and their correlation with lymph node metastasis.

Table 1. Comparison of CD4+, CD8+, and CD4+/CD8+ ratio count in tumor nest and stroma and their correlation with lymph node metastasis.

	LN metastasis		N	Mean	Std. Deviation	
CD4 nest	dimension1	-	42	3.093	3.5976	.416
		+	12	5.392	9.2570	
CD4 stroma	dimension1	-	42	34.471	26.1215	.887
		+	12	32.508	44.8773	
CD8 nest	dimension1	-	42	10.302	11.2679	.706
		+	12	8.867	12.5674	
CD8 stroma	dimension1	-	42	51.052	26.2697	.888
		+	12	49.825	26.9811	
CD4/CD8 nest	dimension1	-	42	.736	.9041	.453
		+	12	1.622	3.9135	
CD4/CD8 stroma	dimension1	-	42	.797	.6700	.292
		+	12	.562	.5361	

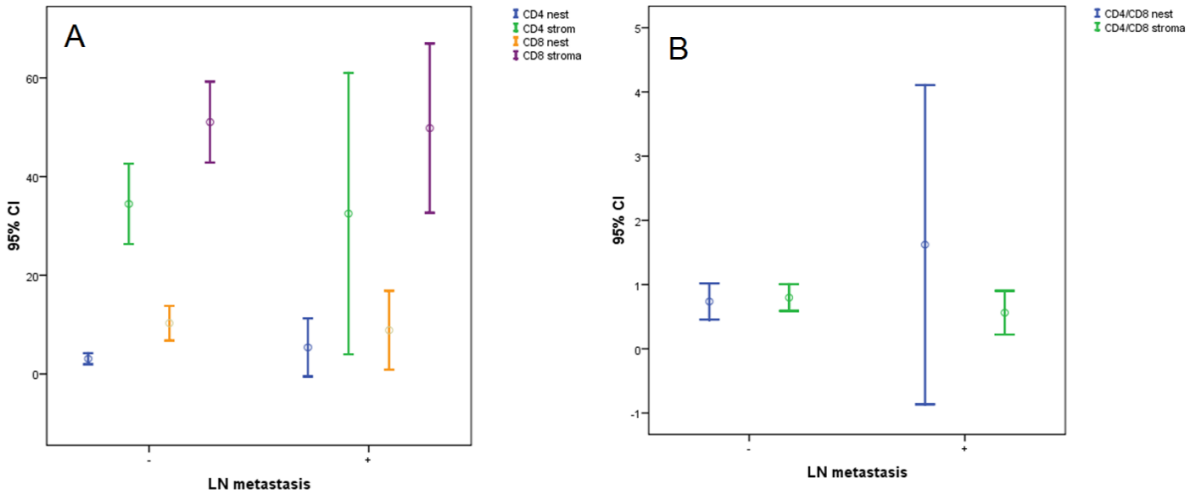

Fig. 7. A: Comparison of CD4+ and CD8+ values in tumor nest and stroma and their correlation with lymph node metastasis. *B*: Comparison of CD4+/CD8+ ratio value in tumor nest and stroma and their correlation with lymph node metastasis.

The mean value of intratumoral and stromal CD4+ T cells in 29 cases (53.7%) of well-differentiated SCC was 4.186±5.279 and 38.103±31.479, respectively, and in 24 cases (46.29%) of moderately differentiated SCC was 3.017±5.584 and 30.408±29.97, respectively. Although the mean number of CD4+ intratumoral and stromal lymphocytes was higher in well-differentiated SCC, there was no significant difference between the two groups, statistically (P-value=0.438 and 0.370, respectively).

The mean value of intratumoral and stromal CD8+ T cells in 29 cases (53.7%) of well-differentiated SCC was 10.797±11.460 and 54.503±27.98, respectively, and in 24 cases (46.29%) of moderately differentiated SCC was 9.38±11.74 and 48.23±22.48, respectively. However, the mean number of intratumoral and stromal CD8+ lymphocytes was higher in well-differentiated SCC, but no noticeable statistical difference was identified between the two groups (P-value=0.661 and 0.380, respectively).

The mean value of CD4+/CD8+ ratio of T cell lymphocytes in tumoral nests and stroma in 29 cases of well-differentiated SCC was 1.33±2.65 and 0.811±0.69, respectively, and in 24 cases of moderately differentiated SCC was 0.44±0.309 and 0.662±0.605, respectively. Although the mean number of CD4+/CD8+ ratio of intratumoral and stromal lymphocytes was higher in well-differentiated SCC, no significant difference was found between the two groups (P-value 0.084 and 0.453, respectively).

The mean value and SD of CD4+, CD8+ TIL, and their ratio in tumor nest and stroma, as well as their correlation with tumor histologic grade, are shown in Table 2 and Figure 8.

Table 2. Comparison of CD4+, CD8+, and CD4+/CD8+ ratio count in tumor nest and stroma and their correlation with tumor differentiation

	grade	N	Mean	Std. Deviation	
CD4 nest	Well	29	4.186	5.2759	**.438**
	Moderate	24	3.017	5.5842	
CD4 stroma	Well	29	38.103	31.4798	**.370**
	Moderate	24	30.408	29.9749	
CD8 nest	Well	29	10.797	11.4609	**.661**
	Moderate	24	9.388	11.7407	
CD8 stroma	Well	29	54.503	27.9821	**.380**
	Moderate	24	48.237	22.4844	
CD4/CD8 nest	Well	29	1.332	2.6502	**.084**
	Moderate	24	.443	.3096	
CD4/CD8 stroma	Well	29	.811	.6907	**.453**
	Moderate	24	.662	.6052	

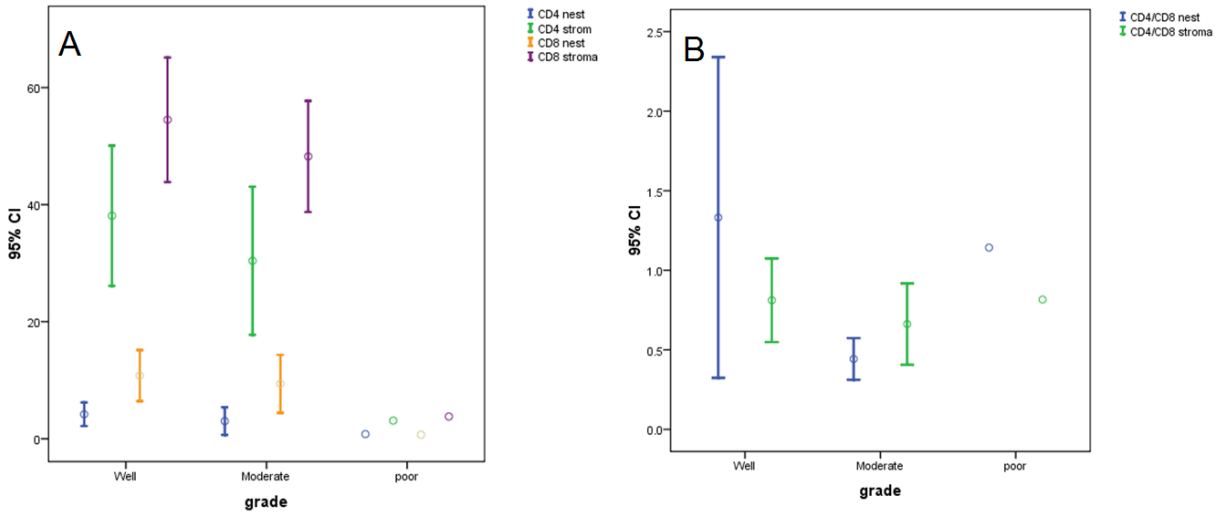

Fig.8. A: Comparison of CD4+ and CD8+ count in tumor nest and stroma and their correlation with tumor differentiation. *B:* Comparison of CD4+and CD8+ count in tumor nest and stroma and their correlation with tumor differentiation

The mean value of intratumoral and stromal CD4+ T cells in 8 cases (14.81%) with vascular/perineural invasion was 1.52±1.61 and 20.23±28.36, respectively and in 46 cases (85.18%) without vascular/perineural invasion was 3.96±5.70 and 36.43±30.82, respectively.

Although the mean number of CD4+ intratumoral and stromal lymphocytes was higher in cases without vascular/perineural invasion, there was no considerable difference between the two groups (P-value=0.238 and 0.172, respectively).

The mean value of intratumoral and stromal CD8+ T cells in 8 cases (14.81%) with vascular/perineural invasion was 4.55±6.02 and 37.71±27.30, respectively and in 46 cases (85.18%) without vascular/perineural invasion was 10.92±11.95 and 53.05±25.60, respectively.

The mean value of intratumoral CD8+ T cells was significantly higher in cases without vascular/perineural invasion (P-value=0.03).

Although the mean value of stromal CD8+ T cells was higher in cases without vascular/perineural invasion, there was no significant difference between the two groups (P-value=0.127)

The mean value of CD4+/CD8+ lymphocytes in tumoral nests and stroma in 8 cases with vascular/perineural invasion was 0.77±0.84 and 0.621±0.433, respectively, and in the remaining cases without invasion was 0.96±2.12 and 0.767±0.677, respectively.

However, the mean number of CD4+/CD8+ ratio of intratumoral and stromal lymphocytes was higher in cases without vascular/perineural invasion; no noticeable difference was noted between the two groups (P-value=0.81 and 0.45, respectively).

The mean value and SD of CD4+, CD8+ TIL, and their ratio in tumor nest and stroma, as well as their correlation with vascular/perineural invasion, are shown in Table 3 and *Figure 9*.

In this study, there was no significant difference between patient age and studied variables (P-value >0.05).

Table 3. The mean value and SD of CD4+, CD8+ T cells and CD4+/CD8+ ratio in tumor nest and stroma, and their correlation with vascular/perineural invasion

	v/p invason		N	Mean	Std. Deviation	
CD4 nest	dimension1	-	46	3.965	5.7031	**.238**
		+	8	1.525	1.6184	
CD4 stroma	dimension1	-	46	36.435	30.8205	**.172**
		+	8	20.237	28.3644	
CD8 nest	dimension1	-	46	10.928	11.9541	**.033**
		+	8	4.550	6.0290	
CD8 stroma	dimension1	-	46	53.052	25.6001	**.127**
		+	8	37.712	27.3099	
CD4/CD8 nest	dimension1	-	46	.960	2.1294	**.813**
		+	8	.778	.8470	
CD4/CD8 stroma	dimension1	-	46	.767	.6770	**.452**
		+	8	.621	.4333	

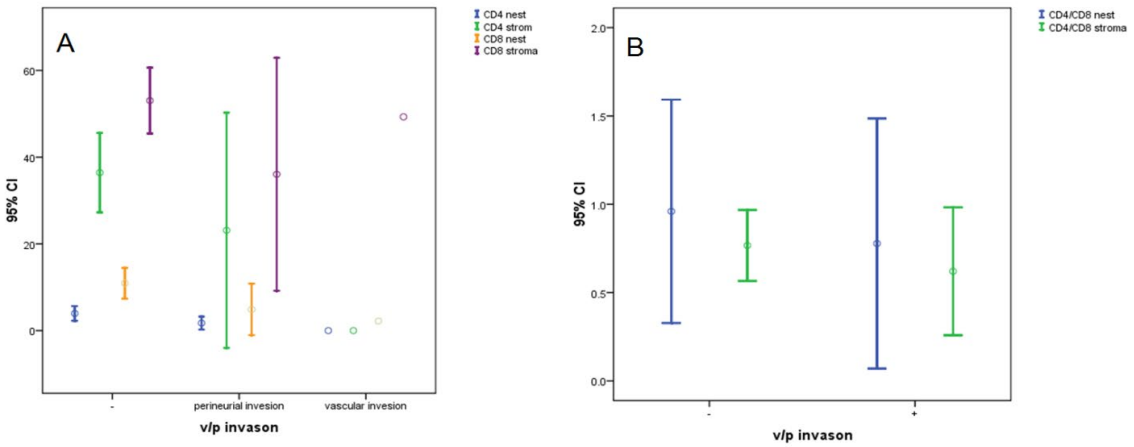

Fig. 9. A Comparison of CD4+ and CD8+ values in tumor nest and stroma and their correlation with vascular/perineural invasion. *B:* Comparison of CD4+/CD8+ ratio in tumor nest and stroma and their correlation with vascular/perineural invasion

Discussion

As we mentioned previously, the immune host reaction against malignancy includes different pathways, for example, induction of apoptosis by T cells (34), decreased expression of HLA type I (35), expression of Galectin-1 by tumor cells (36), and Treg CD4+CD25+ cells (37). Up to now, various studies have been performed on the role of CD4+ and CD8+ TILs as the most effective and important host reaction in squamous cell carcinoma of the head and neck overall. In this study, we analyzed the number of CD4+ and CD8+ TILs and their ratio in the stroma and tumor nests of laryngeal SCC and their association with prognostic factors.

With regard to the number of intratumoral and stromal CD4+ and CD8+ T cells, we did not find any significant association between the number of infiltrating lymphocytes and lymph node metastasis or tumor differentiation. We observed a significant correlation between increased numbers of intratumoral CD8+ T cells and absence of vascular/perineural invasion ($P = 0.03$). Watanabe Y and colleagues found that a lower number of stromal and intratumoral CD8+ T cells is correlated with decreased survival in oral SCC (16). T Chiba confirmed the role of intratumoral CD8+ T cells as an independent prognostic factor and main effector cells for suppression of the primary tumor and its micrometastasis by long-term follow-up of 371 patients who were affected by colorectal cancer (38).

In other studies on end-stage urothelial cancers (39), cervical (40), and ovarian cancers (41), increased numbers of CD8+ TILs were associated with disease-free survival and favorable prognosis.

Santos and colleagues in 2014 found a correlation between higher numbers of CD8+ TILs and a lower rate of metastasis as well as better tumor differentiation (21), and subsequently better survival was seen in the low-risk group of oral and hypopharyngeal SCC with higher numbers of intraepithelial CD8+ TILs in the study of Distel LV et al (42). Like our findings, Ahmed Ali and colleagues did not find any association between CD8+ and CD4+ TILs and tumor differentiation in oral SCC (24).

In our study, like another study (21), higher numbers of CD8+ T cells were seen in cases with more favorable prognostic factors (cases without lymph node metastases, without vascular/perineural invasion, and patients with better tumor histologic grade). These findings indicate the probable positive prognostic role and the main antitumor activity of these cells; although we could not prove it statistically, except for intratumoral CD8+ T cells and vascular/perineural invasion. In this regard, a decreased number of CD8+ T cells in patients with metastatic lymph nodes compared with patients without metastasis may be caused by dysfunction of the regulatory effect of CD4+ T cells in malignancy (43).

Although infiltration of CD4+ and CD8+ T cells in metastatic lymph node tissue in different studies revealed various findings—for example, Heinz A in Germany found that numbers of CD4+ and CD8+ T cells in metastatic foci are higher compared with the primary tumor (44)—we could not find any association between CD4+ TILs and prognostic factors in this study. An increased number of intratumoral CD4+ T cells was observed in cases with metastatic lymph nodes, and increased CD4+ T cells were seen in tumor nests and stroma of well-differentiated neoplasms, but this was not statistically significant. Like our study, Santos and colleagues in 2014 (21) and Ahmed Ali in 2012 (24) did not find any association between increased numbers of CD4+ T cells in tumoral tissue and tumor differentiation or metastasis.

Unlike our results, increased numbers of intratumoral CD4+ T cells were associated with a higher survival rate in head and neck SCC in the study of Wolf GT (45).

An increased ratio of CD4+/CD8+ T cells in the tumoral nest and intervening stroma could not confirm our hypothesis about the correlation of this ratio with patient prognosis. Like our result, da Silveira and coworkers could not find a correlation between CD4+/CD8+ and metastasis or anatomic location of the tumor (46). In contrast to our findings, Santos in Brazil found a correlation between an increased CD4+/CD8+ ratio and absence of metastasis and better tumor differentiation (21). Synderman and colleagues determined that a CD4/CD8 ratio of greater than 1 may be a useful prognostic factor for cervical lymph node metastases (47). In this regard, a study by Chen W in 2006 in China on patients with hypopharyngeal SCC revealed that the levels of CD4 lymphocyte subsets, CD4/CD8 ratio, and NK activity were lower in the carcinoma group than in the control group, but the CD8 lymphocyte level was higher in the carcinoma group. The levels of CD4 lymphocyte subsets, CD4/CD8 ratio, and NK activity were lower in the T3-4 group than in the T1-2 group and lower in the N+ group than in the N0 group. The levels of CD4 lymphocyte subsets and CD4/CD8 ratio were decreased in carcinoma with moderate or low differentiation ($P < 0.05$) (48).

As mentioned, our study could not statistically confirm the clinical significance of CD4+ and CD8+ TILs as prognostic factors except for a greater number of intratumoral CD8+ T cells and absence of vascular/perineural invasion.

Since perineural invasion in laryngeal SCC is associated with increased local recurrence and decreased survival rate, it can be mentioned as an independent prognostic factor (49, 50).

As noted in previous studies, increased numbers of intratumoral CD8+ TILs in cases without perineural invasion may be used as an independent prognostic factor for patients suffering from laryngeal SCC. The

study performed by Vesa and colleagues in 2005 on 188 patients affected by prostatic cancer showed that increased TILs were associated with perineural invasion and capsular invasion, and decreased numbers of them were associated with local disease and better tumor behavior (51). On the other hand, like our result, Huh JW in 2012, by studying 546 patients with colorectal cancer, revealed that a lower number of intratumoral lymphocytes was associated with less tumor differentiation and more perineural invasion (52).

In addition to the mentioned factors in this study, Treg lymphocytes are introduced as a therapeutic confounder that acts via immune suppression against tumoral antigens (53). Alhamarneh O in 2008 studied the role of Treg lymphocytes in the progression of head and neck cancers via T cell–mediated immune suppression against malignant cells (53). These cells can also be used in targeted therapy in an immunotherapeutic regimen (54). The current study could not evaluate the association between Treg lymphocytes and prognostic factors in laryngeal SCC. We recommend focusing on the role of Treg cells and their subtypes in the prognosis of head and neck SCC and also suggest further research on the application of our data in the management of patients with laryngeal SCC.

Conclusion

In conclusion, this study highlights the potential prognostic significance of tumor-infiltrating lymphocytes (TILs), particularly CD8+ T cells, in laryngeal squamous cell carcinoma (SCC). While we observed a significant correlation between increased intratumoral CD8+ T cells and favorable prognostic factors, such as the absence of vascular/perineural invasion, statistical confirmation of their broader clinical relevance remains limited. The findings align with prior studies suggesting that elevated CD8+ TILs are associated with improved survival and disease-free outcomes in various cancers, including oral SCC and colorectal cancer.

Conversely, the role of CD4+ T cells and the CD4+/CD8+ ratio in prognosis remains inconclusive. Although increased intratumoral CD4+ T cells were noted in cases with lymph node metastases and well-differentiated tumors, these associations were not statistically significant. Similarly, the hypothesized correlation between the CD4+/CD8+ ratio and patient prognosis could not be validated in this study.

Given the importance of immune modulation in cancer progression, further research is warranted to explore the therapeutic implications of TILs, particularly regulatory T cells (Tregs), and their impact on immune suppression in head and neck SCC. Future studies should focus on leveraging these findings for targeted immunotherapy approaches to improve patient outcomes in laryngeal SCC.

Acknowledgments

None.

Authors' Contributors

Dr. Maryam Lotfi. Conceptualization, Methodology, Project administration, Supervision, Writing - original draft. Dr. Mina Majdi, Data curation, Resources, Validation, Writing - review & editing. Dr. Parin Tanzifi, Investigation, Resources, Validation, Writing - review & editing. Dr. Tahereh Yousefi. Investigation, Resources, Validation, Writing - review & editing. Dr. Elham Nazar, Data curation, Resources, Validation, Writing - review & editing. Dr. Aysan Nozheh (Corresponding Author). Data curation, Formal analysis, Software, Writing - original draft, Writing - review & editing.

Data Availability

The datasets generated and analyzed during the current study are not publicly available; however, the data can be shared for research and authentication purposes upon reasonable request.

Funding

This research received no specific grant from any funding agency in the public, commercial, or not-for-profit sectors.

Ethics Approval

All individuals who contributed samples to this study voluntarily provided their informed consent to participate. They were thoroughly briefed on the research's objectives and potential advantages. Participants were guaranteed the right to withdraw at any point without facing any repercussions. Written consent was secured from all participants before their inclusion in the study. This study was conducted in accordance with the ethical principles outlined in the Declaration of Helsinki. Ethical approval was obtained from the ethics committee of Tehran University of Medical Sciences.

Conflict of Interest

The authors declared no conflict of interest.

References

1. Lee SS, Luna MA, Batsakis JC. Squamous cell carcinoma of the larynx in young adults. Semin Diagn Pathol. 1987;4(2):150-2.
2. Mendez P Jr, Main JJ, Panje WR. Squamous cell carcinoma of the head and neck in patients under 40 years of age. Arch Otolaryngol. 1985;111(11):762-4. [DOI:10.1001/archotol.1985.00800130094013] [PMID]
3. Divakar P, Davies L. Trends in incidence and mortality of larynx cancer in the US. JAMA Otolaryngol Head Neck Surg. 2023;149(1):34-41. [DOI:10.1001/jamaoto.2022.3636] [PMID] [PMCID]
4. Gumbarewicz E, Tylżanowski P, Łuszczki J, Kałafut J, Czerwonka A, Szumiło J, et al. Differential molecular response of larynx cancer cell lines to combined VPA/CDDP treatment. Am J Cancer Res. 2021;11(6):2821-37.
5. Marioni G, Molinari RR, Cartei G, Marchese F, Staffieri A. Current opinion in diagnosis and treatment of laryngeal carcinoma. Cancer Treat Rev. 2006;32(7):504-15. [DOI:10.1016/j.ctrv.2006.07.002] [PMID] [PMCID]
6. Muscat JE, Wynder EL. Tobacco, alcohol, asbestos, and occupational risk factors for laryngeal cancer. Cancer. 1992;69(9):2244-51. [DOI:10.1002/1097-0142(19920501)69:93.0.CO;2-O] [PMID]
7. Rafferty MA, Fenton JE, Jones AS. The history, aetiology and epidemiology of laryngeal carcinoma. Clin Otolaryngol Allied Sci. 2001;26(6):442-6. [DOI:10.1046/j.1365-2273.2001.00507.x] [PMID]
8. Han D, Lee HL, Oung QW, Lee CH. Global, regional, and national mortality of larynx cancer from 1990 to 2021: results from the global burden of disease study. World J Surg Oncol. 2025;23(1):76. [DOI:10.1186/s12957-025-03720-6] [PMID] [PMCID]
9. Saedi B, Rezabeigi E, Sadeghi M, Mojtahed M, Mojtahed A. The epidemiology of laryngeal cancer in a country on the esophageal cancer belt. Indian J Otolaryngol Head Neck Surg. 2009;61(3):213-7. [DOI:10.1007/s12070-009-0069-6] [PMID] [PMCID]
10. Fitzmaurice C, Abate D, Abbasi N, Abbastabar H, Abd-Allah F, Abdel-Rahman O, et al. Global, regional, and national cancer incidence, mortality, years of life lost, years lived with disability, and disability-adjusted life-years for 29 cancer groups, 1990 to 2017: a systematic analysis for the Global Burden of Disease Study. JAMA Oncol. 2019;5(12):1749-68. [PMID] [PMCID] [DOI:10.1001/jamaoncol.2019.2996]
11. Barona de Guzman R, Martorell MA, Basterra J, Armengot M, Alvarez-Valdes R, Garin L. Prognostic value of histopathological parameters in 51 supraglottic squamous cell carcinomas. Laryngoscope. 1993;103(5):538-40. [DOI:10.1288/00005537-199305000-00011] [PMID]
12. Gallo O, Libonati GA, Gallina E, Fini-Storchi O, Giannini A, Urso C, et al. Langerhans cells related to prognosis in patients with laryngeal carcinoma. Arch Otolaryngol Head Neck Surg. 1991;117(9):1007-10. [DOI:10.1001/archotol.1991.01870210079015] [PMID]
13. Manni JJ, Terhaard CH, de Boer MF, Croll GA, Hilgers FJ, Annyas AA, et al. Prognostic factors for survival in patients with T3 laryngeal carcinoma. Am J Surg. 1992;164(6):682-7. [DOI:10.1016/S0002-9610(05)80734-2] [PMID]
14. Nakashima T, Yano G, Itoh K, Katsuta Y. Epithelial membrane antigen and S-100 protein-labeled cells in primary and metastatic laryngeal carcinomas. Head Neck. 1992;14(6):445-51. [DOI:10.1002/hed.2880140604] [PMID]
15. Narayana A, Vaughan AT, Gunaratne S, Kathuria S, Waller SA, Reddy SP. Is p53 an independent prognostic factor in patients with laryngeal carcinoma? Cancer. 1998;82(2):286-91. https://doi.org/10.1002/(SICI)1097-0142(19980115)82:2<286::AID-CNCR7>3.0.CO;2-P [DOI:10.1002/(SICI)1097-0142(19980115)82:23.0.CO;2-P]
16. Pizem J, Cor A, Gale N. Survivin expression is a negative prognostic marker in laryngeal squamous cell carcinoma and is associated with p53 accumulation. Histopathology. 2004;45(2):180-6. [DOI:10.1111/j.1365-2559.2004.01925.x] [PMID]
17. Westerbeek HA, Mooi WJ, HFBG, Begg AC, Balm AJ. Ploidy status and the response of T1 glottic carcinoma to radiotherapy. Clin Otolaryngol Allied Sci. 1993;18(2):98-101. [DOI:10.1111/j.1365-2273.1993.tb00537.x] [PMID]
18. Wiernik G, Millard PR, Haybittle JL. The predictive value of histological classification into degrees of differentiation of squamous cell carcinoma of the larynx and hypopharynx compared with the survival of patients. Histopathology. 1991;19(5):411-7. [DOI:10.1111/j.1365-2559.1991.tb00230.x] [PMID]
19. Johnson DE, Burtness B, Leemans CR, Lui VWY, Bauman JE, Grandis JR. Head and neck squamous cell carcinoma. Nat Rev Dis Primers. 2020;6(1):92. [DOI:10.1038/s41572-020-00224-3] [PMID] [PMCID]
20. Agrawal N, Frederick MJ, Pickering CR, Bettegowda C, Chang K, Li RJ, et al. Exome sequencing of head and neck squamous cell carcinoma reveals inactivating mutations in NOTCH1. Science. 2011;333(6046):1154-7. [DOI:10.1126/science.1206923] [PMID] [PMCID]
21. Santos Pereira JD, da Costa Miguel MC, Guedes Queiroz LM, da Silveira EJ. Analysis of CD8+ and CD4+ cells in oral squamous cell carcinoma and their association with lymph node metastasis and histologic grade of malignancy. Appl Immunohistochem Mol Morphol. 2015;23(4):270-5. [DOI:10.1097/PAI.0b013e31828df3c9] [PMID]
22. Watanabe Y, Katou F, Ohtani H, Nakayama T, Yoshie O, Hashimoto K. Tumor-infiltrating lymphocytes, particularly the balance between CD8(+) T cells and CCR4(+) regulatory T cells, affect the survival of patients with oral squamous cell carcinoma. Oral Surg Oral Med Oral Pathol Oral Radiol Endod. 2010;109(5):744-52. [DOI:10.1016/j.tripleo.2009.12.015] [PMID]
23. Kumar V, Abbas AK, Aster JC. Robbins basic pathology. 9th ed. Philadelphia (PA): Elsevier Saunders; 2013.

24. Ahmed AA, et al. Differential infiltration of CD4, CD8 and macrophages in oral SCC. J Bagh Coll Dentistry. 2012;24(3):54-8.

25. Bos R, Sherman LA. CD4+ T-cell help in the tumor milieu is required for recruitment and cytolytic function of CD8+ T lymphocytes. Cancer Res. 2010;70(21):8368-77. [DOI:10.1158/0008-5472.CAN-10-1322] [PMID] [PMCID]

26. Marzo AL, Kinnear BF, Lake RA. Tumor-specific CD4+ T cells have a major 'post-licensing' role in CTL mediated anti-tumor immunity. J Immunol. 2000;165(11):6047-55. [DOI:10.4049/jimmunol.165.11.6047] [PMID]

27. Borst J, Ahrends T, Bąbała N, Melief CJM, Kastenmüller W. CD4+ T cell help in cancer immunology and immunotherapy. Nat Rev Immunol. 2018;18(10):635-47. [DOI:10.1038/s41577-018-0044-0] [PMID]

28. Sun W, Liu W, Fu QL, Wu CY, Lin JZ, Zhu XL, et al. Functionally distinct subsets of CD4+ regulatory T cells in patients with laryngeal squamous cell carcinoma are indicative of immune deregulation and disease progression. Oncol Rep. 2015;33(1):354-62. [DOI:10.3892/or.2014.3553] [PMID]

29. Balermpas P, Michel Y, Wagenblast J, Seitz O, Weiss C, Rödel F, et al. Tumour-infiltrating lymphocytes predict response to definitive chemoradiotherapy in head and neck cancer. Br J Cancer. 2014;110(2):501-9. [DOI:10.1038/bjc.2013.640] [PMID] [PMCID]

30. Uppaluri R, Dunn GP, Lewis JS Jr. Focus on TILs: prognostic significance of tumor infiltrating lymphocytes in head and neck cancers. Cancer Immun. 2008;8:16.

31. Zhang D, Tang D, Heng Y, Zhu XK, Zhou L, Tao L, et al. Prognostic impact of tumor-infiltrating lymphocytes in laryngeal squamous cell carcinoma patients. Laryngoscope. 2021;131(4):E1249-55. [DOI:10.1002/lary.29196] [PMCID]

32. Tevetoğlu F, Çomunoğlu N, Yener HM. The impact of the tumor immune microenvironment and tumor-infiltrating lymphocyte subgroups on laryngeal cancer prognosis. Sci Prog. 2024;107(3):368504241266087. [DOI:10.1177/00368504241266087] [PMID] [PMCID]

33. Chatzopoulos K, Kotoula V, Manoussou K, Markou K, Vlachtsis K, Angouridakis N, et al. Tumor infiltrating lymphocytes and CD8+ T cell subsets as prognostic markers in patients with surgically treated laryngeal squamous cell carcinoma. Head Neck Pathol. 2020;14(3):689-700. [DOI:10.1007/s12105-019-01101-6] [PMID] [PMCID]

34. Gastman BR, Atarashi Y, Reichert TE, Saito T, Balkir L, Rabinowich H, et al. Fas ligand is expressed on human squamous cell carcinomas of the head and neck, and it promotes apoptosis of T lymphocytes. Cancer Res. 1999;59(20):5356-64.

35. Ferris RL, Whiteside TL, Ferrone S. Immune escape associated with functional defects in antigen-processing machinery in head and neck cancer. Clin Cancer Res. 2006;12(13):3890-5. [DOI:10.1158/1078-0432.CCR-05-2750] [PMID]

36. Saussez S, Cucu AI, Toubeau G, Kiss R. Galectins as modulators of tumor progression in head and neck squamous cell carcinomas. Head Neck. 2007;29(9):874-84. [DOI:10.1002/hed.20559] [PMID]

37. Strauss L, Bergmann C, Gooding W, Johnson JT, Whiteside TL. The frequency and suppressor function of CD4+CD25highFoxp3+ T cells in the circulation of patients with squamous cell carcinoma of the head and neck. Clin Cancer Res. 2007;13(21):6301-11. [DOI:10.1158/1078-0432.CCR-07-1403] [PMID]

38. Chiba T, Ohtani H, Mizoi T, Naito Y, Sato E, Nagura H, et al. Intraepithelial CD8+ T-cell-count becomes a prognostic factor after a longer follow-up period in human colorectal carcinoma: possible association with suppression of micrometastasis. Br J Cancer. 2004;91(9):1711-7. [DOI:10.1038/sj.bjc.6602201] [PMID] [PMCID]

39. Sharma P, Shen Y, Wen S, Yamada S, Jungbluth AA, Gnjatic S, et al. CD8 tumor-infiltrating lymphocytes are predictive of survival in muscle-invasive urothelial carcinoma. Proc Natl Acad Sci U S A. 2007;104(10):3967-72. [DOI:10.1073/pnas.0611618104] [PMID] [PMCID]

40. Piersma SJ, Jordanova ES, van Poelgeest MI, Kwappenberg KM, van der Hulst JM, Drijfhout JW, et al. High number of intraepithelial CD8+ tumor-infiltrating lymphocytes is associated with the absence of lymph node metastases in patients with large early-stage cervical cancer. Cancer Res. 2007;67(1):354-61. [DOI:10.1158/0008-5472.CAN-06-3388] [PMID]

41. Sato E, Olson SH, Ahn J, Bundy B, Nishikawa H, Qian F, et al. Intraepithelial CD8+ tumor-infiltrating lymphocytes and a high CD8+/regulatory T cell ratio are associated with favorable prognosis in ovarian cancer. Proc Natl Acad Sci U S A. 2005;102(51):18538-43. [DOI:10.1073/pnas.0509182102] [PMID] [PMCID]

42. Distel LV, Fietkau R, Dietel K, Herrmann A, Iro H, Zenk J, et al. Tumour infiltrating lymphocytes in squamous cell carcinoma of the oro- and hypopharynx: prognostic impact may depend on type of treatment and stage of disease. Oral Oncol. 2009;45(10):e167-74. [DOI:10.1016/j.oraloncology.2009.05.640] [PMID]

43. Verastegui E, Morales R, Barrera JL, Müeller A, Guzman B, Meneses A, et al. Immunological approach in the evaluation of regional lymph nodes of patients with squamous cell carcinoma of the head and neck. Clin Immunol. 2002;102(1):37-47. [DOI:10.1006/clim.2001.5130] [PMID]

44. Horst HA, Horny HP. Tumor-infiltrating lymphoreticular cells. Histologic and immunohistologic investigations performed on metastasizing squamous cell carcinomas of the head and neck. Cancer. 1991;68(11):2397-402. https://doi.org/10.1002/1097-0142(19911201)68:11<2397::AID-CNCR2820681111>3.0.CO;2-N [DOI:10.1002/1097-0142(19911201)68:113.0.CO;2-N] [PMID]

45. Wolf GT, Hudson JL, Peterson KA, Miller HL, McClatchey KD. Lymphocyte subpopulations infiltrating squamous carcinomas of the head and neck: correlations with extent of tumor and prognosis. Otolaryngol Head Neck Surg. 1986;95(2):142-52. [DOI:10.1177/019459988609500203] [PMID]

46. da Silveira EJ, de Lima MC, de Lima KC, de Freitas RA, de Morais ML, Queiroz LM. Analysis of local immunity in squamous cell carcinoma of the tongue and lower lip. Exp Mol Pathol. 2010;88(1):171-5. [DOI:10.1016/j.yexmp.2009.11.009] [PMID]

47. Snyderman CH, Heo DS, Chen K, Whiteside TL, Johnson JT. T-cell markers in tumor-infiltrating lymphocytes of head and neck cancer. Head Neck. 1989;11(4):331-6. [DOI:10.1002/hed.2880110408] [PMID]

48. Chen WK, Shi M, Chen FJ, Guo ZM, He LR, Yan SL. [Analysis of serum T-lymphocyte subsets and NK cell activity in patients with hypopharyngeal squamous cell carcinoma]. Ai Zheng. 2006;25(10):1300-2. Chinese.

49. Fagan JJ, Collins B, Barnes L, D'Amico F, Myers EN, Johnson JT. Perineural invasion in squamous cell carcinoma of the head and neck. Arch Otolaryngol Head Neck Surg. 1998;124(6):637-40. [DOI:10.1001/archotol.124.6.637] [PMID]

50. Liebig C, Ayala G, Wilks JA, Berger DH, Albo D. Perineural invasion in cancer: a review of the literature. Cancer. 2009;115(15):3379-91. [DOI:10.1002/cncr.24396] [PMID]

51. Karja V, Aaltomaa S, Lipponen P, Isotalo T, Talja M, Mokka R. Tumour-infiltrating lymphocytes: a prognostic factor of PSA-free survival in patients with local prostate carcinoma treated by radical prostatectomy. Anticancer Res. 2005;25(6C):4435-8.

52. Huh JW, Lee JH, Kim HR. Prognostic significance of tumor-infiltrating lymphocytes for patients with colorectal cancer. Arch Surg. 2012;147(4):366-72. [DOI:10.1001/archsurg.2012.35] [PMID]

53. Alhamarneh O, Amarnath S, Stafford ND, Greenman J. Regulatory T cells: what role do they play in antitumor immunity in patients with head and neck cancer. Head Neck. 2008;30(2):251-61. [DOI:10.1002/hed.20739] [PMID]

54. Zou W. Regulatory T cells in the tumor microenvironment. Nat Rev Immunol. 2006;6(4):295-307. [DOI:10.1038/nri1806] [PMID] [PMCID]