Iranian Journal of Pathology | ISSN: 2345-3656

Study of Intraoperative Squash Cytology of Intracranial and Spinal Cord Lesions with Histopathological Correlation

Birundha Baskaran[1], Preethi Sri[2], Prema Devi[3]

1. *Department of Pathology, Aarupadai Veedu Medical College and Hospital, Vinayaka Mission's Research Foundation (Deemed to be University), Pondicherry, India*
2. *Department of Pathology, Madras Medical College, Chennai, India*
3. *Department of Pathology, Government Ariyalur Medical College and Hospital, Ariyalur, India*

KEYWORDS

Squash cytology, glial tumors, astrocytoma, CNS cytology, space-occupying lesion

Scan to discover online

Main Subjects:
Neuropathology

Received 02 Dec 2025;
Accepted 02 Feb 2026;
Published Online 20 Feb 2026;

10.22034/ijp.2026.2070253.3525

ABSTRACT

Background & Objective: Central nervous system (CNS) tumors display significant diversity in clinical behavior and morphology. Timely intraoperative diagnosis is critical for surgical decision-making. Squash cytology is a rapid, cost-effective tool for evaluating CNS lesions intraoperatively, especially where frozen section has limitations. This study aimed to assess the utility and diagnostic accuracy of squash cytology in the intraoperative diagnosis of intracranial and spinal cord space-occupying lesions, with correlation to histopathology.

Methods: This prospective study included 57 patients undergoing surgery for CNS lesions at Government Medical College from January 2019 to June 2020. Intraoperative squash smears were prepared and stained with rapid hematoxylin and eosin. The cytological diagnosis was compared with paraffin-embedded histopathology. Statistical analysis was performed to evaluate sensitivity, specificity, diagnostic accuracy, and concordance in tumor grading.

Results: Among the 57 cases, 91% were neoplastic and 9% were non-neoplastic. Meningioma (33.3%) and diffuse astrocytic/oligodendroglial tumors (28.1%) were the most common neoplasms. The diagnostic accuracy of squash cytology was 94.73%, with high sensitivity and specificity. Cytological grading matched histopathological grading in the majority of cases. Diagnostic errors were mainly observed in tumors with poor smearability, high cohesiveness, or crush artifacts.

Conclusion: Intraoperative squash cytology is a valuable diagnostic adjunct in CNS surgeries. It offers high accuracy and rapid turnaround and is particularly useful in resource-limited settings. While histopathology remains the gold standard, squash cytology significantly aids intraoperative decision-making.

Corresponding Information: **Birundha Baskaran**, Department of Pathology, Aarupadai Veedu Medical College and Hospital, Vinayaka Mission's Research Foundation (Deemed to be University), Pondicherry. Email: bvbrindha693@gmail.com

Copyright © 2026. This is an open-access article distributed under the terms of the **Creative Commons Attribution 4.0 International License (CC BY 4.0)**, which permits unrestricted use, distribution, and reproduction in any medium, provided the original work is properly cited. The license also allows users to adapt, remix, transform, and build upon the material for any purpose, including commercial use.

Introduction

The brain and spinal cord are enclosed by bone, and expansion of their contents by a space-occupying lesion (SOL) leads to compression and distortion of the tissues of the CNS (1). There are several types of SOLs within the CNS, including infections, vascular diseases, cerebral edema, and neoplastic and nonneoplastic lesions such as cysts and hamartomas. The incidence of central nervous system (CNS) tumors varies from 10-17/100 000 persons/year for intracranial tumors and 1-2/100 000 persons/year for intraspinal tumors. In India, the overall incidence of CNS tumors (2,3) is increasing, and it is about 2% in adults (4,5). Among the primary CNS neoplasms, glioblastomas and anaplastic astrocytomas account for 35%, astrocytomas 13%, meningiomas 17%, other neuroepithelial neoplasms 8%, nerve sheath tumors 8%, PNETs 3%, and others 16%. In children, the incidence is about 6.6%-19.8% in boys and 3%-16% in girls. Hence, CNS tumors are the second most frequently encountered tumors in children after leukemia.

Primary spinal cord tumors account for 4%-10% of all CNS tumors and are characterized based on their location as intramedullary (IMSCT), intradural extramedullary, and extradural. Approximately two-thirds of all spinal tumors are said to be IDEM, and 10% IMSCT (5). According to the SEER reports (6), the incidence of CNS tumors is increasing, with 4000 new cases diagnosed annually. Worldwide, the incidence rate of primary malignant tumors of the CNS ranges from 5.8 per 1 lakh person-years in males and 4.1 per 1 lakh person-years in females in developed countries. In

India, the incidence in adult males is 11.2/1 lakh and in adult females is 6.8/1 lakh. The age-adjusted mortality is 4.5/1 lakh (7-9). In adults, CNS tumors constitute the sixth most common form of tumor.

Diagnosing CNS lesions based solely on nonspecific symptoms is not possible. It involves integrated analysis by the neurophysician, neurosurgeon, radiologist, and pathologist. It is the pathologist who provides the final report, and treatment is based on the pathologist's report. Hence, it is of paramount importance to diagnose CNS lesions accurately. In the era of stereotactic biopsies, the amount of tissue fragment is very small, and intraoperative consultation is an important component in the surgical management of brain tumors (8-10). At the operating table, the neurosurgeon often wants to know whether the tissue taken for biopsy is from a representative site, and critical decisions regarding treatment and extent of surgical resection can depend on an appropriate intraoperative cytodiagnosis. Hence, pathologists need a technique that provides accurate results regarding cellular morphology and is quick and simple to perform. Therefore, it is necessary to know the efficacy of squash smears (10,11).

Dr William Cone was an early proponent of this technique, as were Dorothy Russell and Lucien Rubinstein. Small fragments of tissue are crushed between two slides and then pulled apart to produce thin, well-prepared smears (12,13).

In experienced hands, diagnosing a lesion from a small tissue sample within a brief period by the smear technique is possible and attains a high degree of accuracy. However, errors do occur, and in such cases, decisions should always be made on the basis of H&E-stained paraffin sections. Thus, even though squash cytology is a simple and safe procedure with advantages in terms of rapidity and timely patient management, histopathology remains the gold standard in the diagnosis of CNS tumors. This study was conducted to assess the utility and accuracy of squash smears in the intraoperative diagnosis of intracranial and spinal cord space-occupying lesions by correlating them with histopathological examination.

Materials and Methods

This was a prospective study conducted in the Department of Pathology at a Government Medical College for a period of 18 months from January 2019 to June 2020. The study was approved by the Institutional Ethics Committee. In this study, the sample size (n = 57) was determined by including all consecutive patients who underwent intraoperative squash cytology with available histopathological correlation during the study period. Several published series, such as Kar M et al (14), Journal of Cytology 2018, have used this approach based on the total number of eligible cases within the chosen timeframe. However, given the rarity and availability of eligible cases, and in accordance with precedent in similar studies (14), all consecutive cases were included to maximize data validity. Cases with insufficient tissue quantity to yield squash preparation; tissue with predominantly necrosis and hemorrhage; poorly spread smears with obscured cytological details; and tissue from areas that did not represent the tumor were excluded from the study. Bony and degenerative lesions of the spine were excluded.

After obtaining patient consent, on the day of surgery, a small amount of tissue, approximately 1-2 mm^2, was provided in a fresh state or in isotonic saline. It was inspected grossly for necrosis and hemorrhage, and only viable tissue was used for smear preparation and cytological examination. Viable tissue measuring 0.5-1 mm was placed at one end of a labeled slide. The smear was prepared by gently squashing it with another slide and pulling the slides away from each other to create a uniform tissue layer. The smears were then fixed in isopropyl alcohol for 10 minutes and rapidly stained with hematoxylin and eosin. The rest of the tissue was sent in 10% formalin to the department for histopathological examination. These tissues were processed using an automated tissue processor, embedded in paraffin wax, and stained with hematoxylin and eosin. The staining procedures for all cytological and histopathological specimens were standardized to ensure consistent and reproducible results (15,16).

To minimize interobserver variability, all squash cytology smears and corresponding histopathological slides were reviewed independently by three different pathologists. In cases of discordance, a joint review was conducted and a consensus diagnosis was established through discussion. This helped minimize subjective bias and enhance the reliability and reproducibility of diagnostic correlation. Frequencies, sensitivity, specificity, positive predictive value, and negative predictive value were calculated, and the diagnostic efficacy of squash cytology was evaluated.

Results

In this study, 60 cases of intracranial and spinal cord space-occupying lesions were assessed, which included both tumor and nontumor lesions. Three cases were excluded—in two cases, the specimen for HPE diagnosis was inadequate, so correlation could not be performed; another was a bony degenerative lesion of the spinal cord and hence was excluded. Out of 57 CNS lesions, 52 were neoplastic lesions, accounting for 91%, and the other 5 (9%) were nonneoplastic. Among the 57 cases, meningioma was the most common (33.3%), followed by diffuse astrocytic tumors (28.1%).

CNS lesions were more common among the age group between 51 and 60 years, with a mean age of 44.54 years. Patients younger than 10 years accounted for about 7% in our study. Among the sites of distribution of CNS tumors, the temporal and parietal lobes (28.1%) were the most common, followed by the

parietal lobe (10.5%), cerebellopontine angle (7%), and occipital lobe (3.5%) (Figure 1).

Discrepancies arise between histopathology and squash cytology in the diagnosis of CNS lesions due to various technical as well as morphological reasons. A case of gemistocytic astrocytoma was misdiagnosed as an inflammatory lesion because of similar morphology between gemistocytes and histiocytes, cells with abundant eosinophilic cytoplasm. Oligodendroglial tumors in smear cytology appear round and similar to astrocytes, without clear space around oligodendrocytes, which is appreciable in histopathology due to fixation artifact. Due to increased cellularity without any stromal matrix, pilomyxoid astrocytoma and pilocytic astrocytoma were diagnosed as diffuse astrocytoma only. Oligodendroglial tumors such as oligoastrocytoma and oligodendroglioma were diagnosed as astrocytoma, since the morphology of oligodendroglial cells and astrocytic cells appears similar in cytology (Table 1, Table 2).

In this study, cumulative diagnostic accuracy of astrocytic tumors is 95.8%. Diagnostic accuracy of other tumors such as schwannoma, meningioma and infective lesions tuberculoma, epidermoid cyst are 100% (Table 3).

Sensitivity in identifying tumor lesions by the squash method was 98.1%; therefore, this method is reliable in differentiating tumor and nontumor lesions such as infections and cysts. Specificity in identifying tumor lesions by the squash method was 100% (Table 6).

The squash smear findings were correlated with the histopathological diagnosis. The grading reported on squash smears also correlated with histopathological grading. Diagnoses that were concordant between squash cytology and histopathology accounted for about 91.2%, whereas diagnoses varied between the two in 8.8% of cases.

Regarding tumor grading, the same grade was assigned in 92.2% of cases, and 7.8% of cases showed variation in grading between squash cytology and histopathological diagnosis.

In astrocytic tumors grade correlation between squash and histopathology is 87.5% in grade 1 tumours, 83.3% in grade 2 tumours and 100% in high grade tumors (Table 4).

In this study, only 4 cases were found with grade discrepancies. All cases of glioblastoma multiforme were diagnosed as high-grade glioma on squash cytology. The overall diagnostic accuracy of tumor grading was 92.2% (Table 5).

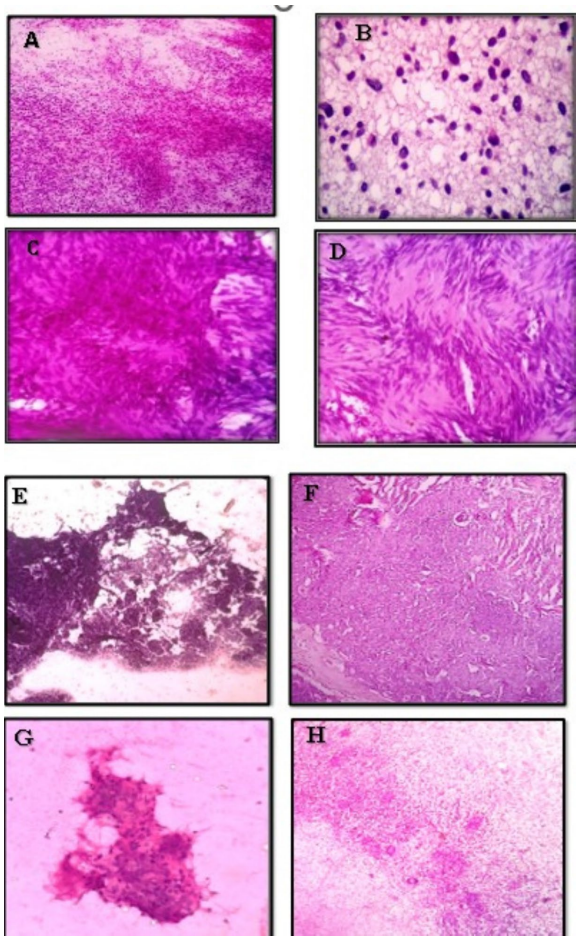

Fig. 1. Picture A depicts the squash cytology image of astrocytoma with sheets of astrocytes (hematoxylin and eosin [H&E], 10×). Picture B shows diffuse astrocytoma on histopathological examination (H&E, 40×). Picture C shows squash cytology of schwannoma depicting the palisading arrangement. Picture D shows the histopathological image of schwannoma (H&E, 40×). Picture E is the squash cytology image of meningioma showing whorling of cells and psammomatous calcification (H&E, 10×). Picture F shows the histopathological image of meningioma (H&E, 40×). Picture G is the squash cytology image of a granulomatous lesion (H&E, 40×), and Picture H is the histopathological image of a granulomatous lesion in the brain (H&E, 40×).

Table 1. Spectrum of CNS Lesions by Histopathological Diagnosis

S.NO	HISTOPATH DIAGNOSIS	HISTOPATH	SQUASH
1.	Astrocytoma	8 (14%)	**14(24.6%)**
2.	Gemistocytic astrocytoma	1 (1.8%)	-
3.	Pilocytic astrocytoma	8 (14%)	**8(14%)**
4.	Pilomyxoid astrocytoma	1 (1.8%)	-

S.NO	HISTOPATH DIAGNOSIS	HISTOPATH	SQUASH
5.	Pleomorphic xanthoastrocytoma	2 (3.5%)	**1 (1.8%)**
6.	Oligoastrocytoma	2 (3.5%)	-
7.	Oligodendroglioma	1 (1.8%)	-
8.	Ganglioglioma	1 (1.8%)	-
9.	Meningioma	17 (29.8%)	**17 (29.8%)**
10.	Atypical meningioma	1 (1.8%)	**2 (3.5%)**
12.	Papillary meningioma	1 (1.8%)	-
11.	Schwannoma	4 (7%)	-
12.	Glioblastoma multiforme	4 (7%)	-
13.	Epitheloid hemangioendothelioma	1 (1.8%)	-
14.	Granulomatous lesion probably TB	4 (7%)	**4 (7%)**
15.	Epidermoid cyst	1 (1.8%)	**1 (1.8%)**
	Total	**57**	**47**

Table 2. Diagnostic discrepancy between squash and histopathological diagnosis in variants of CNS lesions

S.NO	HISTOPATHOLOGICAL DIAGNOSIS	NO OF CASES	SQUASH DIAGNOSIS	REASON FOR MISDIAGNOSIS
1.	Gemistocytic astrocytoma	1	Inflammatory lesion	Low cellularity;presence of reactive glial cells
2.	Pilocytic astrocytoma	1	Diffuse astrocytoma	Overlapping features;lack of biphasic pattern on smear
3.	Pilomyxoid astrocytoma	1	Diffuse astrocytoma	Myxoid background missed;cellular features resembling diffuse type
4.	Pleomorphic xanthoastrocytoma	1	Diffuse astrocytoma	No evident pleomorphism
5.	Oligoastrocytoma	2	Diffuse astrocytoma	Loss of classic oligodendroglial nuclear features on Squash
6.	Oligodendroglioma	1	Diffuse astrocytoma	
7.	Ganglioglioma	1	Diffuse astrocytoma	Failure to recognize ganglion cells and more predominance of glial cells.

Table 3. Correlation of Squash Diagnosis With Histopathological Diagnosis

S.NO	HISTOPATHOLOGICAL DIAGNOSIS	SQUASH AND HPE CORRELATION		DIAGNOSTIC ACCURACY
		YES	NO	
1.	Astrocytic tumors	23	1	**95.8%**
2.	Oligodendroglial tumors	-	3	**0%**
3.	Ganglioglioma	-	1	**0%**
4.	Meningioma	19	-	**100%**
5.	Schwannoma	4	-	**100%**
6.	Epitheloid Hemangioendothelioma	1	-	**100%**
7.	Granulomatous lesion probably TB	4	-	**100%**
8.	Epidermoid cyst	1	-	**100%**
	Total	**52**	**5**	**91.2%**

Table 4. Grade Correlation in Astrocytic Tumors

S.NO	GRADE OF ASTROCYTOMA	CORRELATION WITH HPE		DIAGNOSTIC ACCURACY
		Yes	No	
1.	Grade 1	7	1	**87.5%**
2.	Grade 2	10	2	**83.3%**
3.	Grade 4	4	-	**100%**
	Total	**21**	**3**	**87.5%**

Table 5. Sensitivity and Specificity in Identifying CNS Tumor by Squash Diagnosis

DIAGNOSIS OF CNS TUMOUR BY SQUASH	DIAGNOSIS OF CNS TUMOUR BY HISTOPATHOLOGY		TOTAL
	YES	NO	
Yes	51	0	**51**
No	1	5	**6**
	52	5	**57**
Sensitivity (%)		**98.1**	
Specificity (%)		**100**	
Positive predictive value (%)		**100**	
Negative predictive value (%)		**83.3**	

Discussion

In our study, among the CNS tumors, astrocytic tumors were the most common, with an incidence of 42%, followed by meningioma with an incidence of 33.4%. This is similar to the study by Neglia et al (14, 15), which showed an incidence of astrocytic tumors of 36.02%, followed by meningioma at 16.2%. The study by Govindaraman et al (10) also showed the most common tumor as astrocytoma (33.5%), followed by meningioma (24%).

The worldwide incidence of CNS tumors also shows similar results, with astrocytoma being the most common, followed by meningioma, as stated by Nelson et al (17), Nigam et al (18), and Nori et al (19).

In our study, the most common age group involved was between 51 and 60 years, followed by 41 to 50 years. In other studies conducted by Govindaraman et al (10), Bajaj et al (1), Omer et al (20), and Patchel et al (21), the most common age group involved was 31 to 40 years, followed by 41 to 50 years.

Among astrocytomas, grade 2 tumors showed a wide age distribution, with the most common age range being 41 to 50 years. Grade 1 pilocytic astrocytoma was common in the pediatric age group comprising those younger than 10 years, similar to the studies by Lacruz et al (11), Ries et al (22), Roesseler et al (23), Sachin et al (24), and Schlehofer et al (25).

In meningioma, there was a wide age distribution between 30 and 75 years, with the most common cluster in the 51 to 60 years range. Other studies showed the mean age group involved was around 60 to 70 years (20). Govindaraman et al (10), Shah et al (26), Thomas et al (27), and Torres et al (28) in their studies stated that the diagnostic accuracy of squash cytology in diagnosing conditions such as astrocytoma, oligodendroglioma, glioblastoma, meningioma, schwannoma, granulomatous inflammation, and epidermoid cyst was about 100%, which correlated with our study. Nigam et al (18) stated that the diagnostic accuracy was about 84% for astrocytic tumors, 33.3% for oligodendroglioma, and 100% for meningioma, schwannoma, and epidermoid cyst. In our study, the overall diagnostic accuracy of squash cytology was about 91.2%, which correlated with the studies conducted by Roesseler et al (92.8%) (23), Sachin et al (93.4%) (24), Govindaraman et al (90.7%) (10), Bajaj et al (98.6%) (1), Nigam et al (89.3%) (18), Jamunarani et al (82%) (12), Torres et al (97.3%) (28), and Goel et al (83.2%) (8).

In our study, the overall diagnostic accuracy of squash cytology in grading the tumor was 92.2%. Grade 1 showed 96.6%, grade 2 showed 88.2%, grade 3 showed 0%, and grade 4 showed 100%, whereas Bajaj et al (1) reported a diagnostic accuracy of about 79%, and Brommeland et al (3) stated that the diagnostic accuracy was about 88%.

In our study, the sensitivity of diagnosing tumors was 98.1% and specificity was 100%, which means that nonneoplastic lesions were not interpreted as tumors in this study. These results were similar to the studies conducted by Bajaj et al (sensitivity, 98.6%; specificity, 100%) (1), Govindaraman et al (sensitivity, 98.7%; specificity, 97.4%) (10), and Sachin et al (sensitivity, 98.78%; specificity, 100%) (22). In this study, the incidence of CNS space-occupying lesions was 1.21%. The overall diagnostic accuracy of CNS space-occupying lesions by squash cytology was 91.2%, and the diagnostic accuracy of tumor grading was 92.2%. The sensitivity, specificity, positive predictive value, and negative predictive value for

diagnosing a CNS tumor were 98.1%, 100%, 100%, and 83.3%, respectively, which correlated with the findings of Wiemels et al (29), Agarwal et al (31), Philip et al (32), and Govindaraman et al (10). This concludes that the squash method is considered to be reliable in the intraoperative diagnosis of CNS space-occupying lesions.

Limitations

The study was conducted on only a limited number of cases, which may not be representative of all CNS lesions or other tumor types. Long-term follow-up and clinical outcome correlation were not included, restricting assessment of diagnostic accuracy in terms of patient prognosis.

Conclusion

The squash method is a rapid, simple, cost-effective method compared with frozen section and can also be used in intraoperative rapid diagnosis. In our country, it can be used as a preliminary method for rapid diagnosis in routine practice. However, it should never be used as a definitive diagnostic method for further management since histopathology is the gold standard. In the squash method, cell morphology is better preserved. It does not require special skills as in the cryostat technique. With better expertise in neuropathology cytology smears, the squash method is an accurate, rapid, and reliable method for diagnosing CNS lesions intraoperatively and aids neurosurgeons in deciding further management.

Acknowledgments

None.

Authors' Contributors

All authors contributed equally to the conceptualization, design, and execution of this study.

Data Availability

The datasets generated and analyzed during the current study are not publicly available; however, the data can be shared for research and authentication purposes upon reasonable request.

Funding

This research received no specific grant from any funding agency in the public, commercial, or not-for-profit sectors.

Ethics Approval

All procedures performed in the current study were approved by IRB and/or national research ethics committee (reference number and date) in accordance with the World Medical Association Declaration of Helsinki. IEC.NO – 53/2018 from institutional ethical committee.Informed consent was obtained from all individual participants included in the study.

Conflict of Interest

The authors declared no conflict of interest.

References

1. Bajaj NK, Somalwar SB, Nagamuthu EA, et al. Study of intraoperative squash cytology of intracranial and spinal cord lesions with histopathological and IHC study. J Evid Based Med Healthc. 2016;3(55):2820-5. [DOI:10.18410/jebmh/2016/616]
2. Betmouni S, Seth L. Pathology of space-occupying lesions of the CNS. Surgery (Oxford). 2004;22(3):i-iv. [DOI:10.1383/surg.22.3.i.33532]
3. Brommeland T, Lindal S, Straume B, et al. Does imprint cytology of brain tumours improve intraoperative diagnoses? Acta Neurol Scand. 2003;108(3):153-6. [DOI:10.1034/j.1600-0404.2003.00115.x] [PMID]
4. Dasgupta A, Gupta T, Jalali R. Indian data on central nervous tumors: a summary of published work. South Asian J Cancer. 2016;5(3):147-53. [DOI:10.4103/2278-330X.187589] [PMID] [PMCID]
5. Edwards MK, Terry JG, Montebello JF, et al. Gliomas in children following radiation therapy for lymphoblastic leukemia. Acta Radiol Suppl. 1986;369:651-3.
6. Firlik KS, Martinez A, Lunsford LD. Use of cytological preparations for the intraoperative diagnosis of stereotactically obtained brain biopsies: a 19-year experience and survey of neuropathologists. J Neurosurg. 1999;91(3):454-8. [DOI:10.3171/jns.1999.91.3.0454] [PMID]
7. Frosch MP, Anthony DC, De Girolami U. The central nervous system. In: Kumar V, Abbas AK, Aster JC, editors. Robbins & Cotran pathologic basis of disease. 9th ed. Philadelphia (PA): Elsevier; 2014. p. 1251-316.
8. Goel D, Sundaram C, Paul TR, et al. Intraoperative cytology (squash smear) in neurosurgical practice-pitfalls in diagnosis: experience based on 3057 samples from a single institution. Cytopathology. 2007;18(5):300-8. [DOI:10.1111/j.1365-2303.2007.00484.x] [PMID]
9. Ghosh A, Susoban S, et al. The first cross-sectional survey on intracranial malignancy in Kolkata, India:

reflection of the state of the art in southernwest Bengal. Asian Pac J Cancer Prev. 2004;5(3):259-67.

10. Govindaraman PK, Arumugam N, Ramasamy C, Prakasam G. Role of squash smear in intraoperative consultation of central nervous system tumors. J Sci Soc. 2017;44(1):7-14. [DOI:10.4103/jss.JSS_36_16]
11. Lacruz CR, Catalina-Fernández I, Bardales RH, et al. Intraoperative consultation on pediatric central nervous system tumors by squash cytology. Cancer Cytopathol. 2015;123(6):331-46. [DOI:10.1002/cncy.21537] [PMID]
12. Jamunarani S. Diagnostic accuracy of squash cytology for rapid intraoperative diagnosis in tumors of the nervous system. IOSR J Dent Med Sci. 2018;17(5):27-32.
13. Nair M, Varghese C, Swaminathan R. Cancer: current scenario, intervention strategies and projections for 2015. NCMH Background Papers. 2005.
14. Kar M, Sharma V, Agarwal A, Sharma A, Khanna V. Role of squash cytology in intraoperative diagnosis: cytohistopathological correlation of 57 cases of spinal space occupying lesions. J Cytol. 2018;35(4):227-32.
15. Jindal A, Diwan H, Kaur K, Sinha VD. Intraoperative Squash Smear in Central Nervous System Tumors and Its Correlation with Histopathology: 1 Year Study at a Tertiary Care Centre. J Neurosci Rural Pract. 2017 Apr-Jun;8(2):221-224. [DOI:10.4103/0976-3147.203811] [PMID] [PMCID]
16. Sunila, Kumarguru BN, Vasan TS, Manjunath GV, Sheeladevi CS. Role of squash cytology in central nervous system lesions: a cytomorphological study. Indian J Pathol Res Pract. 2017;6(3):574-84. [DOI:10.21088/ijprp.2278.148X.6317.12]
17. Neglia JP, Robison LL, Stovall M, et al. New primary neoplasms of the central nervous system in survivors of childhood cancer: a report from the Childhood Cancer Survivor Study. J Natl Cancer Inst. 2006;98(21):1528-37. [DOI:10.1093/jnci/djj411] [PMID]
18. Nelson JS, Burchfiel CM, Fekedulegn D, et al. Potential risk factors for incident glioblastoma multiforme: the Honolulu Heart Program and Honolulu-Asia Aging Study. J Neurooncol. 2012;109(2):315-21. [DOI:10.1007/s11060-012-0895-3] [PMID] [PMCID]
19. Nigam SN, Nilam M, Anand. Diagnostic accuracy of squash smear technique in brain tumors. J Evol Med Dent Sci. 2012;1(4):538-45. [DOI:10.14260/jemds/85]
20. Nori SNS, Rama Lakshmi PVB, Srikanth KVN, Teegala R. A study to determine the accuracy of cytological diagnosis of CNS lesions by squash smears and correlation with histopathology. MedPulse Int J Pathol. 2017;4(1):21-8.
21. Omerhodzic I. Primary epithelioid hemangioendothelioma in the cerebellum: case report with reference to drastic change in the WHO classification. Acta Clin Croat. 2018;57(3):570-6. [DOI:10.20471/acc.2018.57.03.21] [PMID] [PMCID]
22. Patchell RA. Primary central nervous system lymphoma in the transplant patient. Neurol Clin. 1988;6(2):297-303. [DOI:10.1016/S0733-8619(18)30871-5] [PMID]
23. Ries LAG, Smith MA, Gurney JG, et al., editors. Cancer incidence and survival among children and adolescents: United States SEER Program 1975-1995. Bethesda (MD): National Cancer Institute, SEER Program; 1999. NIH Pub. No. 99-4649.
24. Roessler K, Dietrich W, Kitz K. High diagnostic accuracy of cytological smears of CNS tumors: a 15-year experience based on 4,172 patients. Acta Cytol. 2002;46(4):667-74. [DOI:10.1159/000326973] [PMID]
25. Sachin RK, Sanjay N. Utility of squash smear cytology in intraoperative diagnosis of central nervous system lesions. Int J Sci Res. 2019;8(1):50-2.
26. Schlehofer B, Kunze S, Sachsenheimer W, et al. Occupational risk factors for brain tumors: results from a population-based case-control study in Germany. Cancer Causes Control. 1990;1(3):209-15. [DOI:10.1007/BF00117472] [PMID]
27. Shah AB, Muzumdar GA, Chitale AR, Bhagwati SN. Squash preparation and frozen section in intraoperative diagnosis of central nervous system tumours. Acta Cytol. 1998;42(5):1149-54. [DOI:10.1159/000332104] [PMID]
28. Thomas TL, Waxweiler RJ. Brain tumors and occupational risk factors. Scand J Work Environ Health. 1986;12(1):1-15. [DOI:10.5271/sjweh.2168] [PMID]
29. Torres LF, Noronha L, Gugelmin ES, et al. Accuracy of the smear technique in the cytological diagnosis of 650 lesions of the central nervous system. Diagn Cytopathol. 2001;24(5):293-5. [DOI:10.1002/dc.1062] [PMID]
30. Wiemels J, Wrensch M, Claus EB. Epidemiology and etiology of meningioma. J Neurooncol. 2010;99(3):307-14. [DOI:10.1007/s11060-010-0386-3] [PMID] [PMCID]
31. Agrawal M, Chandrakar SK, Lokwani D, Purohit MR. Squash cytology in neurosurgical practice: a useful method in resource-limited setting with lack of frozen section facility. J Clin Diagn Res. 2014;8(10):FC09-12.
32. Philip SA, Bai EL, Padmaja GJV, Kumari S. Analysis of intraoperative squash cytology of central nervous system lesions and its correlation with immunohistopathology and radiology. J Cytol. 2023;40(1):1-4. [DOI:10.4103/joc.joc_70_22] [PMID] [PMCID]