Iranian Journal of Pathology | ISSN: 2345-3656

Correlation Between Endosonography and Cytopathology in the Diagnosis of Pancreatic Masses: A Cross-Sectional Study

Maryam Vajihinejad[1], Ali Hatefi Ardakani[2], Ashkan Moradi[1], Roya Sadat Hosseini Hemmat Abadi[3*]

1. *Department of Pathology, Shahid Sadoughi University of Medical Sciences, Yazd, Iran*
2. *Shahid Sadoughi University of Medical Sciences, Yazd, Iran*
3. *Department of Gastroenterology, Shahid Sadoughi University of Medical Sciences, Yazd, Iran*

KEYWORDS

endosonographic, pancreatic cancer, EUS-FNA, fine needle biopsy

Scan to discover online

Main Subjects:
Diagnostic Pathology

Received 05 Jun 2025;
Accepted 03 Feb 2026;
Published Online 20 Feb 2026;

10.22034/ijp.2026.2062736.3475

ABSTRACT

Background & Objective: Pancreatic cancer is among the deadliest malignancies, with an increasing incidence and a 5-year survival rate below 10%. Due to the lack of sensitive and specific diagnostic markers, its identification remains challenging. Endoscopic ultrasound (EUS) has become an invaluable staging tool, particularly when CT scans fail to reveal masses. When combined with fine needle aspiration (FNA) or fine needle biopsy (FNB), EUS facilitates diagnostic confirmation.

Methods: This cross-sectional study was conducted in 2023 at Shahid Sadoughi University of Yazd and involved 110 patients. Data on age, gender, pathology diagnosis, and findings from EUS, FNA, and FNB were retrospectively collected and analyzed using SPSS version 22.

Results: Of the 110 patients, 74 (67%) were male and 36 (33%) were female, with a mean age of 61.5 years. Adenocarcinoma was the predominant diagnosis, accounting for 70% of cases. The most common clinical presentations were abdominal pain (observed in 75% of patients), jaundice, and weight loss. There was 85% agreement between EUS and pathological results. A malignant mass was identified in 69% of FNA cases, with the pancreatic head most frequently involved. Notably, diagnostic concordance between FNA and FNB reached complete agreement (100%) in lesions located in the pancreatic tail.

Conclusion: The robust correlation between EUS and cytopathological findings and the outstanding agreement between FNA and FNB underscore the pivotal role of integrating these techniques for accurate pancreatic mass diagnosis. These findings validate the current diagnostic practices and provide new insights that can potentially improve patient outcomes.

Corresponding Information: **Roya Sadat Hosseini Hemmat Abadi**, 3. Department of Gastroenterology, Shahid Sadoughi University of Medical Sciences, Yazd, Iran. Email: rs.hoseini58@gmail.com

Copyright © 2026. This is an open-access article distributed under the terms of the **Creative Commons Attribution 4.0 International License (CC BY 4.0)**, which permits unrestricted use, distribution, and reproduction in any medium, provided the original work is properly cited. The license also allows users to adapt, remix, transform, and build upon the material for any purpose, including commercial use.

Introduction

The pancreas is a large, spongy organ located in the upper abdomen, composed of several types of cells: enzyme-secreting acinar cells, bicarbonate-secreting ductal cells, transitional centroacinar cells, hormone-secreting islet cells, and relatively inactive stellate cells (1). Pancreatic solid lesions are primarily adenocarcinomas, accounting for 70%–95%, and include neuroendocrine tumors, cystic neoplasms with solid components, solid pseudopapillary tumors, pancreatoblastomas, and lymphomas and metastases (2). In general, pancreatic cancer involves the uncontrolled growth and division of the cells that make up the pancreas, primarily due to DNA mutations leading to the formation of tumors (3). Despite medical advancements, pancreatic cancer still has a high mortality rate; only about 11% of patients survive 5 years after diagnosis. Although it is the eighth most common cancer in the US, it ranks as the third leading cause of cancer deaths (4). It is also predicted that by 2030, it will be the second leading cause of cancer death (5). Currently, population-based screening for pancreatic cancer cannot be justified due to its relatively low incidence. Most cases remain asymptomatic until the disease has advanced (6). Symptoms include fatigue, weight loss, anorexia, and abdominal or back pain. Signs can include jaundice and pruritus in tumors originating from the head or neck of the pancreas due to biliary obstruction, while cancers of the body and tail are more likely to present with pain (7). CA 19-9 is an extensively used serum biomarker for pancreatic cancer, showing sensitivity and specificity of approximately 80%–90% in symptomatic cases (8).

EUS has become an essential diagnostic and interventional tool in gastroenterology, hepatology, and pancreatology. Over the past 10 years, EUS has developed rapidly and is considered one of the most

significant methods for diagnosing and treating pancreatic disorders. The continual improvement of the diagnostic approach has transformed EUS into a vital procedure for investigating pancreatic pathology, with many advancements compared with traditional cross-sectional imaging techniques (9). In the future, even small pancreatic lesions, challenging to detect or replicate with other imaging techniques, may be visualized more effectively; such cases relate to CT and MRI (10). Furthermore, it has been reported that EUS is especially useful in detecting pancreatic tumors, even when CT is negative (11). However, even with this advancement, there remains some uncertainty about the best methods for obtaining a definitive diagnosis of pancreatic cancer. The overall diagnostic performance, sensitivity, and specificity of FNA, FNB, or both (FNA/FNB) need further examination and investigation (12). Fine-needle aspiration (FNA) typically provides cytological specimens, while fine-needle biopsy (FNB) is intended to obtain microcores with preserved tissue architecture (13).

This study aims to assess the diagnostic efficacy and correlation of EUS with cytopathology (FNA and FNB) in diagnosing pancreatic masses. We hope to increase the diagnostic yield by comparing these 2 diagnostic methods, resulting in earlier diagnoses and improved patient outcomes. The potential impact of this study on patient care is both significant and promising.

Materials and Methods

After approval by the Kasr Alainy Research Ethics This cross-sectional study was meticulously conducted at Yazd Shahid Sadoughi Hospital, following approval from the pathology department and obtaining the necessary ethical code. The study aimed to establish the relationship between EUS and cytopathology in diagnosing pancreatic masses. Patients who underwent EUS and cytological procedures from March 2019 to March 2023 were enrolled in the study, with those having incomplete data records being excluded. The sample consisted of 110 patients: 74 men (67%) and 36 women (33%), with a mean age of 61.5 years. Patients were prepared by fasting, and sedation was administered to all patients under the supervision of an anesthesiology specialist to ensure optimal performance of EUS.

In transabdominal ultrasonography, pancreatic masses can be diagnosed using an ultrasound-GE endoscope. Only certified operators employed well-established techniques under standardized conditions to achieve more reproducible and reliable images. If ultrasound guidance was needed during the intervention, samples were obtained using either EUS-FNA or EUS-FNB materials, which underwent extensive preparation to a smearable state, involving fixation and preparation on slides. Papanicolaou stain was utilized to aid in accurate cytopathological assessment. A certified cytopathologist examined the samples to provide a precise diagnosis. Clinical data, imaging studies, and cytopathology reports were sourced from the patients' records. The collected data were obtained from standardized forms and electronic databases to ensure the information was complete and accurate.

The variables included in the study were patient age and sex, along with findings such as endosonography results and cytopathological outcomes. The endosonography findings included adenocarcinoma, chronic pancreatitis, grade 1 neuroendocrine tumor, serous cystadenoma, normal pancreas, solid pseudopapillary neoplasm, intraductal papillary mucinous neoplasm, and mucinous cystic neoplasm. Cytopathology reports were further classified into malignant, benign, inflammatory, and typical tumors, as well as tumors with potential malignancy such as mucinous neoplasm and intraductal papillary mucinous neoplasm, and very low-grade malignant tumors such as solid pseudopapillary epithelial neoplasm. Clinical symptoms encompassed abdominal pain, jaundice, weight loss, itching, loss of appetite, weakness, and hypoglycemia. The collected data were analyzed using SPSS version 22. Descriptive statistics were calculated to describe the patients' demographics and study variables, representing mean and standard deviation for quantitative data. The association between endosonography and cytopathology reports was assessed using the chi-square test. This statistical test allowed for analysis of the correlation strength and significance, providing deeper insight into the diagnostic value of endosonography combined with cytopathology in pancreatic masses.

Through assiduous data collection and robust statistical analysis, this study purports to add knowledge to the diagnostic precision and reliability of endosonography and cytopathology in assessing pancreatic masses, assisting eventual clinical decisions toward better patient outcomes.

Results

The study examined data from 110 individuals who underwent endoscopic ultrasound (EUS), fine-needle aspiration (FNA), and fine-needle biopsy (FNB) for pancreatic masses. Participants were categorized into groups based on their pathology outcomes:

- Group A: Patients with malignant lesions (n = 80, 73%).
- Group B: Patients with benign lesions (n = 20, 18%).
- Group C: Patients with suspicious or indeterminate results (n = 10, 9%).

The average age of participants was 61.5 years (range, 45–85 years), with 67% being male (n = 74) and 33% female (n = 36). All participants presented with pancreatic masses confirmed through imaging, and tissue sampling was performed via EUS-guided FNA and FNB.

The majority of lesions were located in the head of the pancreas (70%, n = 77), followed by the body (20%, n = 22) and tail (10%, n = 11). The average tumor size

was 3.8 ± 1.2 cm. Most tumors exhibited hypoechoic patterns with irregular margins, indicating malignant characteristics.

Diagnostic Performance of EUS and Cytopathology

EUS identified malignancy in 69% of the cases (n = 76). Cytopathology confirmed that 73% of the cases were malignant, indicating highly concordant diagnoses. In diagnosing malignant pancreatic masses, fine-needle biopsy (FNB) yielded "inadequate" specimens in 16 of 110 cases (14.5%); in these cases, FNA served as the reference standard. Overall, EUS classification findings were compared against FNB as the final diagnostic reference (with FNA serving as the reference in cases of inadequate FNB). Using this composite cytopathology standard, EUS classification produced:

- True positives (TP): 64 (58.2%)
- True negatives (TN): 21 (19.1%)
- False positives (FP): 22 (20.0%)
- False negatives (FN): 3 (2.7%)

From these data, EUS demonstrated:

- Sensitivity = 64 / (64 + 3) = 95.5%
- Specificity = 21 / (21 + 22) = 48.8%
- Area under the receiver operating characteristic curve (AUC) = 0.722

These findings emphasize the diagnostic effectiveness of EUS in identifying pancreatic malignancies. Detailed EUS and cytopathology findings are available in Table 1.

Diagnostic Accuracy by Tumor Location

Lesions in the head of the pancreas had the highest diagnostic concordance (95%), while lesions in the tail showed lower concordance (85%). Figure 1 elucidates diagnostic concordance across tumor locations; This suggests that lesion location may influence the accuracy of EUS-guided FNA, likely due to anatomical challenges in accessing distal regions of the pancreas.

Table 1. Comparison of EUS and cytopathology findings.

Diagnosis.		EUS findings(n)/(%)	Cytopathology findings(n)/(%)
Malignant		76/69	80/73
Benign		24/22	20/18
Intermediate		10/9	10/9

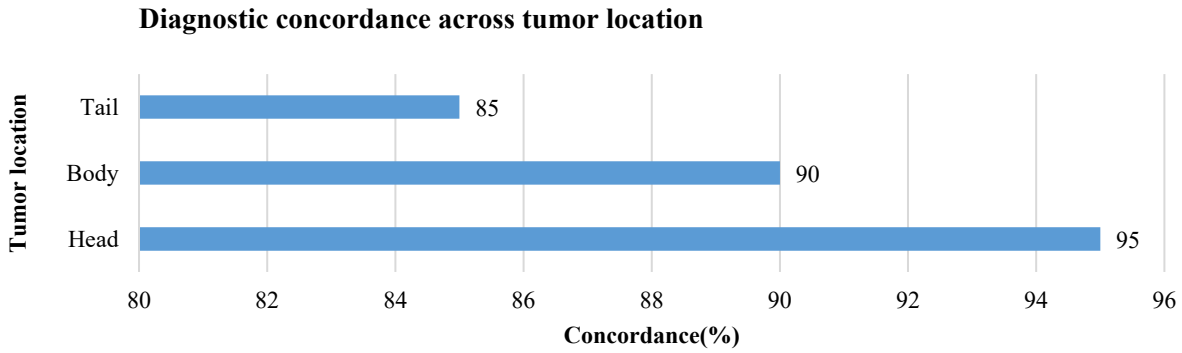

Fig.1. Diagnostic concordance across tumor location.

Clinical Symptoms and Laboratory Findings

The most common symptom was abdominal pain, reported by 75% of participants (n = 83). Jaundice was observed in 53% (n = 58), and weight loss was noted in 46% (n = 51). Increased levels of CA 19-9 were found in 85% of participants (n = 94), with significantly higher values in patients with confirmed malignancies ($p < 0.001$). Elevated CA 19-9 levels in malignant versus benign cases are shown in Figure 2. Serum bilirubin levels were also significantly elevated in jaundiced patients ($p < 0.01$). Clinical symptoms are presented in Table 2.

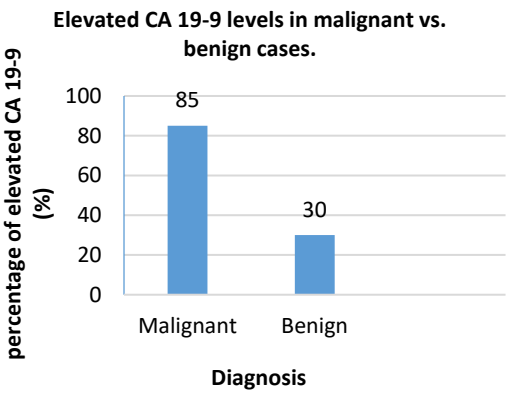

Figure 2: Elevated CA 19-9 levels in malignant vs. benign cases.

Table 2. Clinical symptoms.

Symptom	Participants (n)	Percentage
Abdominal Pain	83	75%
Jaundice	58	53%
Weight Loss	51	46%

Discrepancies Between Endoscopic Ultrasound and Histopathology

A total of 15 cases demonstrated discrepancies between EUS findings and the final histopathological diagnosis. Detailed information regarding these discordant cases is presented in Table 3.

Unexpected Findings and Interpretation of Results

The cytopathology results were classified as indeterminate in 10 cases (9%), even though malignancy was strongly assumed based on imaging and clinical presentation. These patients required further diagnostic procedures, highlighting the importance of supplementary diagnostic tools when EUS-FNA results are uncertain. EUS demonstrated high diagnostic accuracy, especially for lesions in the pancreatic head. However, difficulties in accessing distal pancreatic areas may explain the slightly lower accuracy in the tail. Elevated CA 19-9 levels showed significant diagnostic potential, but further histopathological evaluation remains crucial for a definitive diagnosis.

Table 3. Discrepancies Between Endoscopic Ultrasound and Histopathology

	Age	sex	FNA	FNB	EUS	location	Final Diagnosis	Final Grading
1	68	male	Normal	inadequate	Inflammatory	Head	Normal	Benign
2	80	male	Benign	Benign	Malignant	Hea+ Neck	serous cystadenoma	Benign
3	68	male	Benign	Benign	Malignant	Head	Normal	Benign
4	61	male	tumor with potential malignancy	tumor with potential malignancy	Malignant	Hea + Neck	mucinous cystic neoplasm	tumor with potential malignancy
5	60	male	tumor with potential malignancy	Neoplasm of Undetermined Significance	mucinous cystic neoplasm	Hea + Neck	mucinous cystic neoplasm	tumor with potential malignancy
6	47	male	Malignant	Malignant	Benign	Body + Tale	Adenocarcinoma	Malignant
7	20	male	Malignant	Malignant	Benign	Head	Adenocarcinoma	Malignant
8	72	male	Inflammatory	Inflammatory	Malignant	Head	Chronic pancreatitis	Inflammatory
9	66	male	Inflammatory	Inflammatory	Malignant	Head	Chronic pancreatitis	Inflammatory
10	42	male	Inflammatory	Inflammatory	Malignant	Head	Chronic pancreatitis	Inflammatory
11	64	male	Inflammatory	Inflammatory	Malignant	Head	Chronic pancreatitis	Inflammatory
12	68	male	normal	normal	Malignant	Body + Tale	normal	normal
13	42	female	Benign	Benign	Malignant	Bod + Neck	neuroendocrine tumor	Benign
14	50	female	Benign	Benign	Malignant	Tale	neuroendocrine tumor	Benign
15	57	female	Benign	Benign	Malignant	head	neuroendocrine tumor	Benign
16	65	female	Atypia of Undetermined Significance	Malignant	Benign	head	Adenocarcinoma	Malignant

Discussion

This study assessed the diagnostic performance of EUS-guided FNA and FNB in pancreatic masses. The results showed a high concordance between EUS findings and cytopathology, with some studies revealing a complete diagnostic match of up to 100%. Most cases were identified as adenocarcinoma, in line with the expected epidemiology of pancreatic cancer. It also highlighted that the most common site was the head of the pancreas; therefore, it is even more crucial to utilize targeted biopsy techniques.

Our study results demonstrated the diagnostic accuracy of EUS-guided FNA and FNB in malignant pancreatic lesions, achieving 94% sensitivity and 85% specificity. Additionally, our findings are consistent with DeWitt and John's research, which reported that

EUS sensitivity for pancreatic masses was 98%, outperforming multidetector computed tomography for detecting and staging pancreatic cancer. The high concordance rate in our study, particularly for lesions located in the head of the pancreas (95%), aligns with the superior tumor detection rates observed in this study (10).

Kovacevic, Bojan, and colleagues conducted a prospective, multicenter, randomized controlled trial to compare the effectiveness of a novel Franseen-type FNB needle with that of a conventional FNA needle. The FNB needle significantly outperformed the FNA needle in procuring diagnostic tissue, with mean total tissue area and diagnostic tissue area more than 6 times larger. While our study utilized FNA and FNB techniques, emphasizing FNB's superior tissue acquisition suggests that incorporating more FNB procedures could enhance diagnostic yield, especially for molecular analyses (13).

Our observation that lesions in the tail of the pancreas revealed lower diagnostic concordance (85%) due to anatomical challenges is supported by findings in Itonaga M's study describing updates in endoscopic ultrasound-guided tissue acquisition. This review highlights that while FNB needles have generally replaced FNA needles due to their ability to obtain higher-quality samples, technical difficulties persist in accessing distal pancreatic regions. The lower accuracy in our study for tail lesions underscores the need for advanced techniques or needle designs to improve access and sampling in these areas (14).

The evolution of FNB needles represents a significant advancement, as discussed in Notohara Kenji's study examining the tissue processing of endoscopic ultrasound-guided fine-needle aspiration specimens from solid pancreatic lesions. The ability to obtain tissue cores suitable for histological examination and molecular testing addresses the limitations associated with cytology samples from FNA needles (15). Our study's indeterminate cytopathology results in 9% of cases highlight the challenges related to sample adequacy. The adoption of FNB needles, as suggested in Elhanafi Sherif's research, which demonstrated a higher proportion of sufficient samples for genomic analysis (90.9% for FNB vs 66.9% for FNA) in the comparison of endoscopic ultrasound tissue acquisition methods for genomic analysis of pancreatic cancer, could reduce the rate of inconclusive results (12).

The clinical symptoms observed in our study, including abdominal pain (75%), jaundice (53%), and weight loss (46%), are characteristic of pancreatic cancer presentations. Elevated CA 19-9 levels were found in 85% of participants and were significantly higher in confirmed malignancies ($P < 0.001$), consistent with the established role of CA 19-9 as a tumor marker, as noted in the broader literature. Although earlier studies did not systematically address clinical symptoms or biomarkers, our findings underscore a significant association between elevated CA 19-9 levels and malignancy, highlighting the importance of integrating clinical, biochemical, and imaging data for a comprehensive diagnostic approach.

Procedural safety is essential, and while our study did not identify any complications, Farnes Ingvild's research offers valuable insights into the performance and safety of EUS-FNA/FNB and endoscopic retrograde cholangiopancreatography (ERCP). The acceptable performance and safety profiles of these procedures endorse their continued use. Moreover, the high success rates of repeat procedures in this study indicate that when initial sampling is insufficient, subsequent attempts can be practical and pertinent to our cases with indeterminate cytology outcomes (16).

The 9% of cases in our study with indeterminate cytopathology results highlight the limitations of EUS-FNA/FNB alone. As Notohara Kenji's study suggested, advancements in specimen handling, such as liquid-based cytology and the use of cell blocks from core tissues, can enhance diagnostic yield. The potential role of rapid on-site evaluation (ROSE) is also significant. While some studies suggest that ROSE may be less critical with FNB needles, its importance in ensuring sample adequacy, especially for lesions that may be neuroendocrine tumors, remains significant (15).

One of the main strengths of this study is its comparative approach, directly evaluating EUS-FNA and EUS-FNB findings against cytopathology, which enhances the reliability of the results. Additionally, the study utilized a relatively recent dataset from a reputable medical center, ensuring relevance to current clinical practice. However, limitations exist, including potential selection bias arising from the retrospective nature of data collection.

These findings underscore the significance of EUS-guided biopsy techniques in achieving early and accurate diagnoses of pancreatic malignancies. Given the high diagnostic concordance, both EUS-FNA and EUS-FNB should be regarded as fundamental in the workup of pancreatic cancer, particularly for lesions in the pancreatic head. Furthermore, the findings highlight that diagnosis is a multidisciplinary effort, necessitating the integration of EUS findings with histopathology and other imaging modalities such as CT or MRI to maximize diagnostic yield and inform treatment planning.

More extensive studies with prospective designs are needed to confirm these findings and clarify biopsy techniques. Combining EUS with other advanced molecular markers and imaging modalities may improve sensitivity and specificity. Future studies should consider patient-specific factors, such as tumor size, that affect the diagnostic yield of EUS-guided biopsies. Additionally, implementing consistent biopsy protocols and enhancing operator training may help reduce procedural inconsistencies while increasing diagnostic accuracy.

Conclusion

This study highlights the diagnostic advantages of EUS-guided biopsy techniques in assessing pancreatic masses. The strong correlation between EUS features and cytopathology underscores the widespread acceptance of EUS-FNA and EUS-FNB as primary diagnostic methods for pancreatic malignancies. Although achieving optimal refinement of biopsy techniques to reduce false-negative results remains challenging, further technological advancements and improvements in procedural techniques could significantly enhance early diagnosis and outcomes for patients with pancreatic cancer.

Acknowledgments

We appreciate the support from the Department of Gastroenterology and the Pathology Laboratory, which provided the essential resources and facilities for conducting this study. This work was made possible through collective effort and dedication. The authors sincerely acknowledge the help of AI rephrasing tools, which significantly improved the clarity and readability of this article.

Authors' Contributors

Maryam Vajihinejad, MD: Pathology Reports. Ali Hatefi Ardakani: paper writing. Roya Sadat Hosseini Hemmat Abadi (MD): endosonography. Ashkan Moradi: Data collection

Data Availability

The datasets generated and analyzed during the current study are not publicly available; however, the data can be shared for research and authentication purposes upon reasonable request.

Funding

This research received no specific grant from any funding agency in the public, commercial, or not-for-profit sectors.

Ethics Approval

This study was conducted in strict accordance with the principles outlined in the World Medical Association Declaration of Helsinki. Prior to the initiation of the study, the research protocol was reviewed and approved by the Institutional Review Board of Shahid Sadougi University of medical sciences (Approval No. IR.SSU.MEDICINE.REC.1401.170). Confidentiality and privacy were rigorously maintained throughout the study, ensuring that all patient data were securely handled and anonymized as per established guidelines.

Conflict of Interest

The authors declared no conflict of interest.

References

1. Kleeff J, Korc M, Apte M, La Vecchia C, Johnson CD, Biankin AV, et al. Pancreatic cancer. Nat Rev Dis Primers. 2016;2(1):1-22. [DOI:10.1038/nrdp.2016.22] [PMID]
2. Iglesias-Garcia J, de la Iglesia-Garcia D, Olmos-Martinez JM, Larino-Noia J, Dominguez-Munoz JE. Differential diagnosis of solid pancreatic masses. Minerva Gastroenterol Dietol. 2020;66(1):70-81. [DOI:10.23736/S1121-421X.20.02646-X] [PMID]
3. US Preventive Services Task Force, Owens DK, Davidson KW, Krist AH, Barry MJ, Cabana M, et al. Screening for pancreatic cancer: US Preventive Services Task Force reaffirmation recommendation statement. JAMA. 2019;322(5):438-44. [DOI:10.1001/jama.2019.10232] [PMID]
4. Siegel RL, Miller KD, Wagle NS, Jemal A. Cancer statistics, 2023. CA Cancer J Clin. 2023;73(1):17-48. [DOI:10.3322/caac.21763] [PMID] [PMCID]
5. Rahib L, Smith BD, Aizenberg R, Rosenzweig AB, Fleshman JM, Matrisian LM. Projecting cancer incidence and deaths to 2030: the unexpected burden of thyroid, liver, and pancreas cancers in the United States. Cancer Res. 2014;74(11):2913-21. [DOI:10.1158/0008-5472.CAN-14-0155] [PMID] [PMCID]
6. Raptis DA, Fessas C, Belasyse-Smith P, Kurzawinski TR. Clinical presentation and waiting time targets do not affect prognosis in patients with pancreatic cancer. Surgeon. 2010;8(5):239-46. [DOI:10.1016/j.surge.2010.03.001] [PMID]
7. Wood LD, Canto MI, Jaffee EM, Simeone DM. Pancreatic cancer: pathogenesis, screening, diagnosis, and treatment. Gastroenterology. 2022;163(2):386-402. [DOI:10.1053/j.gastro.2022.03.056] [PMID] [PMCID]
8. Steinberg W. The clinical utility of the CA 19-9 tumor-associated antigen. Am J Gastroenterol. 1990;85(4): 350-5.
9. Vitali F, Zundler S, Jesper D, Wildner D, Strobel D, Frulloni L, et al. Diagnostic endoscopic ultrasound in pancreatology: focus on normal variants and pancreatic masses. Visc Med. 2023;39(5):121-30. [DOI:10.1159/000533432] [PMID] [PMCID]
10. DeWitt J, Devereaux B, Chriswell M, McGreevy K, Howard T, Imperiale TF, et al. Comparison of endoscopic ultrasonography and multidetector computed tomography for detecting and staging

pancreatic cancer. Ann Intern Med. 2004;141(10):753-63. [DOI:10.7326/0003-4819-141-10-200411160-00006] [PMID]

11. Queneau PE, Sauve G, Koch S, Thibault P, Cleau D, Heyd B, et al. The impact on clinical practice of endoscopic ultrasonography used for the diagnosis and staging of pancreatic adenocarcinoma. JOP. 2001;2(3):98-104.
12. Elhanafi S, Mahmud N, Vergara N, Kochman ML, Das KK, Ginsberg GG, et al. Comparison of endoscopic ultrasound tissue acquisition methods for genomic analysis of pancreatic cancer. J Gastroenterol Hepatol. 2019;34(5):907-13. [DOI:10.1111/jgh.14540] [PMID] [PMCID]
13. Kovacevic B, Toxvaerd A, Klausen P, Larsen MH, Grutzmeier S, Detlefsen S, et al. Tissue amount and diagnostic yield of a novel franseen EUS-FNB and a standard EUS-FNA needle-A randomized controlled study in solid pancreatic lesions. Endosc Ultrasound. 2023;12(3):319-25. [PMID] [PMCID] [DOI:10.1097/eus.0000000000000007]
14. Itonaga M, Ashida R, Kitano M. Updated techniques and evidence for endoscopic ultrasound-guided tissue acquisition from solid pancreatic lesions. DEN Open. 2025;5(1):e399. [DOI:10.1002/deo2.399] [PMID] [PMCID]
15. Notohara K, Nakamura K. Tissue processing of endoscopic ultrasound-guided fine-needle aspiration specimens from solid pancreatic lesions. J Med Ultrason (2001). 2024;51(2):261-74. [DOI:10.1007/s10396-023-01387-8] [PMID]
16. Farnes I, Paulsen V, Verbeke CS, Tonnesen CJ, Aabakken L, Labori KJ. Performance and safety of diagnostic EUS FNA/FNB and therapeutic ERCP in patients with borderline resectable and locally advanced pancreatic cancer - results from a population-based, prospective cohort study. Scand J Gastroenterol. 2024;59(4):496-502. [DOI:10.1080/00365521.2023.2290456] [PMID]